

Ultrasound-Assisted Mental Nerve Block and Pulsed Radiofrequency Treatment for Intractable Postherpetic Neuralgia: Three Case Studies

Department of Anesthesiology and Pain Medicine, College of Medicine, Chung-Ang University, Seoul, Korea

Hae Gyun Park, Pyung Gul Park, Won Joong Kim, Yong Hee Park, Hyun Kang, Chong Wha Baek, Yong Hun Jung, Young Cheol Woo, Gill Hoi Koo, and Hwa Yong Shin

Postherpetic neuralgia (PHN) is one of the most difficult pain syndromes to treat. Invasive treatments may be considered when patients fail to obtain adequate pain relief from noninvasive treatment approaches. Here, we present three cases of PHN in the mandibular branch treated with ultrasound-assisted mental nerve block and pulsed radiofrequency treatment. None of the patients had adequate pain relief from the medical therapy, so we performed the mental nerve block on the affected side under ultrasound assistance. Two patients showed satisfactory pain relief continuously over 12 months without any further interventions, whereas one patient only had short-term pain relief. For the patient had short-term pain relief we performed pulsed radiofrequency treatment (PRFT) on the left mental nerve under ultrasound assistance. After PRFT, the patient had adequate pain relief for 6 months and there was no need for further management. (Korean J Pain 2014; 27: 81-85)

Key Words:

mental nerve, postherpetic neuralgia, pulsed radiofrequency treatment, ultrasound.

Postherpetic neuralgia (PHN) results from injury to the nervous system caused by the varicella zoster virus during shingles infection. It involves multiple mechanisms including neuroplasticity and sensitization of both peripheral and central neurons [1]. Treatment strategies for PHN are complex and largely depend on the type and characteristics of pain experienced by the individual patient [2]. PHN is often associated with severe pain and can seriously affect a patient's quality of life [3].

Several treatments have been suggested for PHN, including medication, botulinum toxin injections, nerve blocks, peripheral nerve stimulation, surgical intervention, pulsed radiofrequency treatment (PRFT) [4], and radiofrequency ablation [5]. Nerve localization for mental nerve block ideally relies on a landmark-based approach by palpating the foramina. However, it is occasionally challenging to identify the foramen by relying on palpation alone. Ultrasound (US) imaging is a safe simple non-invasive modality through

Received August 5, 2013. Revised October 16, 2013. Accepted October 16, 2013.

Correspondence to: Hwa Yong Shin

Department of Anesthesiology and Pain Medicine, College of Medicine, Chung-Ang University, 224-1 Heukseok-dong, Dongjak-gu, Seoul 156-755, Korea

Tel: +82-2-6299-3164, Fax: +82-2-6299-2585, E-mail: pain@cau.ac.kr

© This is an open-access article distributed under the terms of the Creative Commons Attribution Non-Commercial License (<http://creativecommons.org/licenses/by-nc/3.0/>), which permits unrestricted non-commercial use, distribution, and reproduction in any medium, provided the original work is properly cited.

Copyright © The Korean Pain Society, 2014

which soft tissues and nerve structures can be visualized and identified when combined with a thorough knowledge of regional anatomy [6]. Pulsed radiofrequency (PRF) is a novel therapeutic strategy that has been used by pain practitioners as a non or minimally neurodestructive technique, in which short bursts of high-frequency current are applied to nervous tissue [7].

Here, we present two cases of successful mental nerve block treatment under US assistance and one case by US-assisted PRFT.

CASE REPORT

1. Case 1

A 68-year-old woman presented the chief complaint of severe left perioral and chin pain. The patient had been diagnosed with PHN in the left V3 area 15 months ago. The left facial pain had continued for 1 year despite medical treatment. During this period, 1,200 mg gabapentin, 300 mg phenytoin, 30 mg duloxetine, and 300 mg hydantoin per day were administered but had little effect. She had paroxysmal, sharp, and lancinating pain in her left mandibular area. When the acute pain attack began, it continued for about 1 hour with eating difficulty. The pain was aggravated by touching the left mandibular area, brushing her teeth, and was associated with talking. Her pain severity was 10/10 on a visual analogue scale (VAS).

Hence, we started pain intervention for PHN in the left V3 area. We initially blocked the left mental nerve under US with a 10–12 MHz linear transducer (Vivid E; General Electronics, Fairfield, CT, USA) using a mixture of 2 ml 2% mepivacaine and 20 mg triamcinolone. This procedure decreased the pain immediately. Her pain severity 1 month after this intervention was 1–2/10 on the VAS, and 80–90% on a pain relief scale. Because pain relief was maintained continuously throughout the 2, 4, 6, and 12 months follow-ups after US-assisted mental nerve block, no additional treatment including medication was provided.

2. Case 2

A 45-year-old man visited our pain clinic with the chief complaint of right mandibular area pain. The patient had been diagnosed with facial herpes zoster in the right V3 area 9 months previously. The right facial pain had continued for 9 months despite medical treatment. During this period, 300 mg pregabalin, 10 mg amitriptyline, and

three 37.5 mg tramadol/375 mg acetaminophen combination tablets were administered *per os* daily but had little effect. He had paroxysmal, sharp, and shooting pain in the right mandibular area. The pain was aggravated by touching the right mandibular area, and palpation over the right mental foramen reproduced the pain. Pain severity was 10/10 on a VAS.

Hence, we started pain intervention for PHN in the left V3 area. We initially blocked the right mental nerve under US with a 10–12 MHz linear transducer using a mixture of 2 ml 2% mepivacaine and 20 mg triamcinolone. This procedure decreased the pain immediately, and pain severity was 0–1/10 on a VAS. One month after this intervention, his pain relief was >90%. Because relief was maintained continuously throughout the 2, 4, 6, and 12 months follow-ups after US-assisted mental nerve block, no additional treatment including medication was provided.

3. Case 3

A 26-year-old woman with PHN in the left V3 area for 1 month visited our pain clinic for treatment by injection. She had a cold, burning sensation on one her left teeth spreading to the left posterior ear. Her pain was aggravated by touching the left mandibular area, and palpation over the left mental foramen reproduced the pain. Pain severity was 10/10 on a VAS.

Hence, we started pain intervention for trigeminal PHN in the left V3 area. We initially blocked the left mental nerve under US with a 10–12 MHz linear transducer using a mixture of 2 ml 2% mepivacaine and 20 mg triamcinolone. This procedure decreased the pain immediately. When she returned to our pain clinic 1 month after the mental nerve block, the patient stated that the VAS score had decreased from 9 to 4 for about 2 weeks following the mental nerve block but that her symptoms had then returned to their previous state. Therefore, we tried the same additional US-assisted left mental nerve treatment, but the outcome was the same with the earlier one.

The US-assisted mental nerve blocks were effective, but the effects were only maintained for 2 weeks, so we decided to perform PRFT. After explaining the procedure, efficacy, and possible side effects of PRFT, the patient was placed in a supine position. The skin was aseptically draped with povidone-iodine. The ultrasound was prepared with a sterile transparent sheath and aseptic ultrasound gel. The transducer was applied transversely at the level of the

second premolar, midway between the upper and lower borders of the mandible. We scanned her mandible in the cephalad direction from the inferior border of the mandible and easily identified the mental foramen with a hypoechoic cleft (Fig. 1).

A radiofrequency needle (10 cm) insulated with a 5-mm active tip (22 G, SMK-C10; Radionics Inc, Burlington, MA, USA) was advanced slightly via the mental foramen under US assistance (Fig. 2). Confirmation of the needle position inside the mental foramen was achieved under fluoroscopy. Following negative aspiration, 0.5 ml of radio-contrast agent (Omnipaque GE Healthcare, Cork, Ireland) was injected to confirm no vascular uptake through the mental branch of the inferior alveolar artery (Fig. 2). Sensory stimulation using a 50 Hz, 0.3–0.5 V electrical current

showed paresthesia over the mandibular area. After confirming the needle position, we performed PRFT three times at 42°C for 120 seconds. The patient did not show any problems throughout PRFT.

Her pain severity was 1–2/10 on the VAS 1 month after PRFT, and her pain relief scale was 80–90%. Because this pain relief was maintained continuously throughout the 2, 4, and 6 months follow-ups after PRFT, no additional treatment including medication was provided.

DISCUSSION

Treatment for trigeminal PHN is controversial. However, in our cases, precisely performed US-assisted mental nerve block and US-assisted PRFT resulted in excellent outcomes

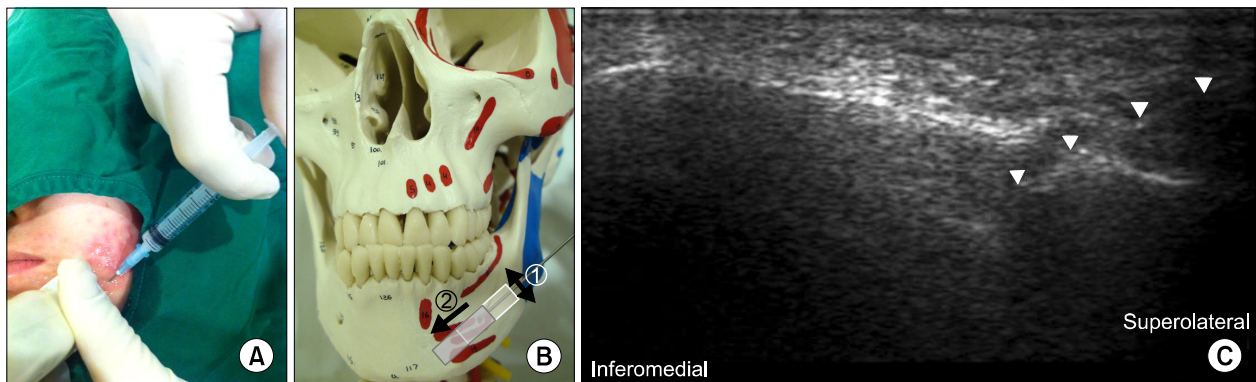


Fig. 1. A photograph of the needle placement in the mental foramen under ultrasound guidance (10–12 MHz linear transducer). (A) In the actual patient. (B) Anterior view in a human skull model, which is empirically depicted. The transducer (white box) was moved like ① for identifying the mental foramen and mental foramen was positioned at the end of transducer ②. (C) An ultrasound image of the radiofrequency needle in the mental foramen (10–12 MHz linear transducer, long-axis in-plane technique). The cleft within the hyperechoic line indicates the mental foramen. The radiofrequency needle has passed through the mental foramen and is indicated with arrow heads.

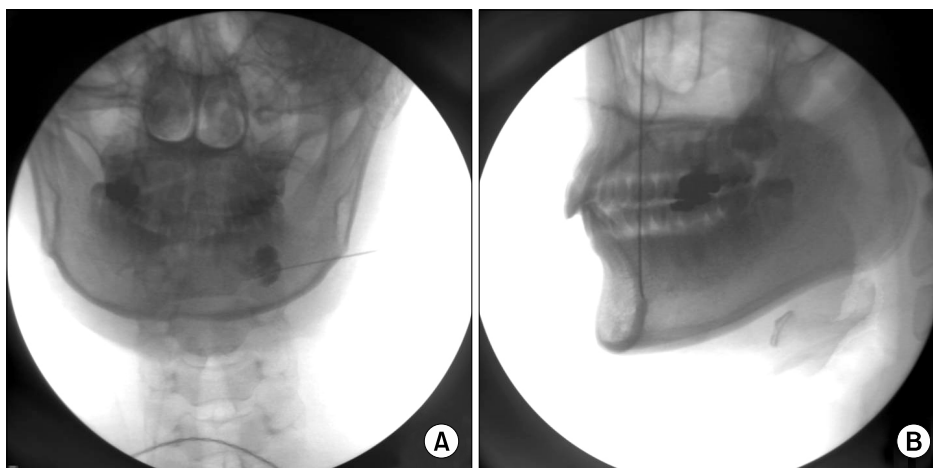


Fig. 2. Fluoroscopic images during pulsed radiofrequency treatment of the left mental nerve of the mandibular branch. (A) Anteroposterior view. (B) Lateral view. Fluoroscopic images show that the needle was in the mental foramen. No vascular uptake of radio-contrast agent was observed.

with no adverse effects.

Trigeminal PHN usually responds to pharmacotherapy, which should be employed before any intervention is attempted. Medical treatments result in good initial pain relief, but relief rates fall off dramatically over the long-term [8]. Cases refractory to medical management can be treated with minimally invasive procedures such as a nerve block. Nerve blocks with local anesthetics and steroids for the painful area are a reasonable next step if pharmacological modalities fail to control the pain. PHN impairs all sensory fiber groups such as C, A δ , and A β fibers that cause sharp pain, burning pain, allodynia and/or hypersensitivity. Inflammation, degeneration and activation of all these fibers leads to central sensitization. The exact mechanism of pain relief from neural blockade during treatment of PHN is unknown, but it may be related to modulating pain transmission [9].

Cohen et al. [10] reported that PRFT has repeatedly been demonstrated as a safe and effective procedure, even in instances where other treatment modalities have failed. Its use in a variety of conditions demonstrates the attractiveness of PRFT as a less invasive alternative to surgical intervention that may involve significant morbidity [11]. Microstructure research has indicated that PRF causes axonal changes more obviously in C fibers than that in A α or A β fibers, which is largely manifested within the mitochondria as micro-cytoskeletal edema, leading to an abnormality in ATP metabolism and ion channel and pump function, thereby blocking the pain transfer in relevant nerves [12]. A neuroanatomic study suggested that the abnormal neuron conduction properties and synaptic activity in the hippocampus induced by PRFT can be quickly restored, which is unique and different from conventional radiofrequency lesioning. PRFT can reversibly block propagation of nerve impulses from small unmyelinated nerve fibers [13]. Therefore, the acute effects of PRFT are more reversible and less destructive in nature than the classic conventional RF mode. The analgesic action of PRFT also involves enhancing noradrenergic and serotonergic descending pain inhibitory pathways. Although the precise mechanism is elusive, most studies suggest that the analgesia achieved by PRFT is through the pulse electric current and the biological effects induced thereby, including the effects on the DRG, c-fos gene expression regulation in the cornu dorsale medullae spinalis, and nerve fiber edema. Long-term analgesia of PRF is also closely con-

nected with the gene expression alteration of neurons [14].

According to Koscielniak-Nielsen [15], US-guided peripheral nerve block significantly shortens performance time and reduces the number of needle passages to the target. The occurrence of paresthesia during block is also reduced but not the incidence of short-lasting post-operative neuropraxia. However, limited information is available on the use of US for identifying bony structures.

Reported complications of blind injections for the treatment of trigeminal neuralgia include soreness, infection, swelling, dysesthesia, and headache [16]. Hence, complications related to mental nerve block can be reduced by US assistance. Definitive identification of osseous landmarks may be important when the target nerve of the block is unidentifiable with US due to its small size or imaging artifacts.

When we perform US-assisted mental nerve block, bone appears as a hyperechoic linear structure. During transverse scanning over the inferior portion of the mandible at the level of the second premolar and scanning in the cephalad direction until a hypoechoic cleft within the hyperechoic line indicates the mental foramen (Fig. 1C) [6]. Additionally, we confirmed pulsating arteries with Doppler. After we advanced the needle slightly into the mental canal, we checked the needle position with fluoroscopy. Then, we reconfirmed that there was no vascular uptake through the mental branch of the inferior alveolar artery with radio-contrast agent (Fig. 2).

The mental foramen, which lies inferior to the outer lip at the level of the second premolar, midway between the upper and lower borders of the mandible, is localized using a transverse scanning in a cephalad direction from the inferior border of the mandible [6]. The most common position of the mental foramen in relation with the teeth appears to be below the second premolar regardless of race or age [17]. It lies at the level of root of second premolar in about 50% of cases, between the two premolars in about 20–25% and posterior to the second premolar in about 24%. In approximately 1–2% of cases the mental foramen lies either anterior to the first premolar or posterior to the first molar [18].

In summary, our patient had been treated initially with medications for PHN. However, medications alone did not provide adequate pain relief. US-assisted mental nerve block seemed to be effective for reducing the pain. Its effect was sufficient for two patients, but was insufficient

for one patient. Thus, we decided to perform US-assisted PRFT of the mental nerve and gained excellent results.

Here, we have presented our experience of US-assisted mental nerve block and US-assisted PRFT, which are safer and more effective techniques than that of the landmark method. But, further randomized controlled studies will be needed to demonstrate the safety and efficacy of this treatment.

REFERENCES

1. Sampathkumar P, Drage LA, Martin DP. Herpes zoster (shingles) and postherpetic neuralgia. *Mayo Clin Proc* 2009; 84: 274–80.
2. Whitley RJ. A 70-year-old woman with shingles: review of herpes zoster. *JAMA* 2009; 302: 73–80.
3. Doth AH, Hansson PT, Jensen MP, Taylor RS. The burden of neuropathic pain: a systematic review and meta-analysis of health utilities. *Pain* 2010; 149: 338–44.
4. Lim SM, Park HL, Moon HY, Kang KH, Kang H, Baek CH, et al. Ultrasound-guided infraorbital nerve pulsed radiofrequency treatment for intractable postherpetic neuralgia – a case report –. *Korean J Pain* 2013; 26: 84–8.
5. Rahman M, Richter EO, Osawa S, Rhoton AL Jr. Anatomic study of the infraorbital foramen for radiofrequency neurotomy of the infraorbital nerve. *Neurosurgery* 2009; 64: 423–7.
6. Tsui BC. Ultrasound imaging to localize foramina for superficial trigeminal nerve block. *Can J Anaesth* 2009; 56: 704–6.
7. Cosman ER Jr, Cosman ER Sr. Electric and thermal field effects in tissue around radiofrequency electrodes. *Pain Med* 2005; 6: 405–24.
8. Haridas A, Mathewson C, Eljamel S. Long-term results of 405 refractory trigeminal neuralgia surgeries in 256 patients. *Zentralbl Neurochir* 2008; 69: 170–4.
9. Hall GC, Carroll D, McQuay HJ. Primary care incidence and treatment of four neuropathic pain conditions: a descriptive study, 2002–2005. *BMC Fam Pract* 2008; 9: 26.
10. Cohen SP, Van Zundert J. Pulsed radiofrequency: rebel without cause. *Reg Anesth Pain Med* 2010; 35: 8–10.
11. Park HL, Lim SM, Kim TH, Kang KH, Kang H, Jung YH, et al. Intractable hemifacial spasm treated by pulsed radiofrequency treatment. *Korean J Pain* 2013; 26: 62–4.
12. Vatanserver D, Tekin I, Tuglu I, Erbuyun K, Ok G. A comparison of the neuroablative effects of conventional and pulsed radiofrequency techniques. *Clin J Pain* 2008; 24: 717–24.
13. Cahana A, Vutskits L, Muller D. Acute differential modulation of synaptic transmission and cell survival during exposure to pulsed and continuous radiofrequency energy. *J Pain* 2003; 4: 197–202.
14. Perret D, Kim DS, Li KW, Luo ZD. Exposure of the dorsal root ganglion to pulsed radiofrequency current in a neuropathic pain model of peripheral nerve injury. *Methods Mol Biol* 2012; 851: 275–84.
15. Koscielniak-Nielsen ZJ. Ultrasound-guided peripheral nerve blocks: what are the benefits? *Acta Anaesthesiol Scand* 2008; 52: 727–37.
16. Shah SA, Khan MN, Shah SF, Ghafoor A, Khattak A. Is peripheral alcohol injection of value in the treatment of trigeminal neuralgia? An analysis of 100 cases. *Int J Oral Maxillofac Surg* 2011; 40: 388–92.
17. Shankland WE 2nd. The position of the mental foramen in Asian Indians. *J Oral Implantol* 1994; 20: 118–23.
18. Gabriel AC. Some anatomical features of the mandible. *J Anat* 1958; 92: 580–6.