



OPEN ACCESS

Management of complicated multirecurrent pterygia using multimicroporous expanded polytetrafluoroethylene

Kyoung Woo Kim, Jae Chan Kim, Jun Hyung Moon, Hyun Koo, Tae Hyung Kim, Nam Ju Moon

Department of Ophthalmology, Chung-Ang University Hospital, Seoul, Korea

Correspondence to

Professor Jae Chan Kim, Department of Ophthalmology, Chung-Ang University Hospital, #224-1, Heukseok-dong, Dongjak-gu, Seoul 156-755, Korea; jck50ey@kornet.net

Received 22 October 2012

Revised 16 January 2013

Accepted 23 February 2013

Published Online First

15 March 2013

ABSTRACT

Aims To evaluate the efficiency of multimicroporous expanded polytetrafluoroethylene (e-PTFE) insertion in complicated multirecurrent pterygia.

Methods A total of 62 eyes from 62 patients with a multirecurrent pterygium associated with symblepharon or motility restriction-related binocular diplopia were recruited. All eyes underwent pterygia excision followed by application of 0.033% mitomycin C, amniotic membrane transplantation and conjunctival limbal autograft. Multimicroporous e-PTFE was then inserted intraoperatively in 30 eyes between the transplanted amniotic membrane and the conjunctiva (group A), but not inserted in the other 32 eyes (group B). The main outcome measures were symblepharon formation, motility restriction, binocular diplopia, subjective score of conjunctival hyperaemia and postoperative pterygium recurrence.

Results In the mean follow-up period of 17.2 ±2.3 months, symblepharon formation, motility restriction, diplopia and conjunctival hyperaemia were significantly improved after surgery in group A patients ($p=0.000$, 0.000 , 0.008 and 0.000 , respectively). Postoperative symblepharon formation, motility restriction and conjunctival hyperaemia were significantly less in group A compared to group B ($p=0.024$, 0.027 and 0.000 , respectively). After surgery, corneal recurrence developed in one eye (3.3%) from group A, which was significantly lower than the eight eyes (25%) from group B ($p=0.027$).

Conclusions Multimicroporous e-PTFE insertion may provide a novel approach for treating intractable complicated multirecurrent pterygia.

INTRODUCTION

Challenges in treating recurrent pterygia include postoperative recurrence and associated complications such as symblepharon and motility restriction. In recurrent pterygia, fibrovascular ingrowth is more extensive than in primary pterygia.¹ As a result, there is a tendency for more aggressive or combined methods of removal for recurrent pterygium including mitomycin C (MMC) application,² conjunctival autograft,³ amniotic membrane transplantation (AMT)⁴ or AMT combined with conjunctival limbal autograft (CLAU).⁵ Despite these efforts, however, it is difficult to achieve a satisfactory result in eyes with aggressive recurrence and fibroproliferative tendency.

Expanded polytetrafluoroethylene (e-PTFE), widely known as Gore-Tex, is a fluoropolymer that has been used in a range of surgical devices and

demonstrates well established biocompatibility and biostability.⁶ e-PTFE's hydrophobicity can prevent the wound area from postoperatively adhering to adjacent tissues. Previous studies have shown that e-PTFE can promote epithelialisation, inciting little inflammatory response,⁷ and prevent recurrence of symblepharon in cicatricial ocular surface diseases.⁸

Our current approach for managing recurrent pterygia is to perform a pterygial excision with intraoperative insertion of multimicroporous e-PTFE into the subconjunctival space at the nasal caruncle. Specifically, we create multiple micropores in the e-PTFE to enable the passage of oxygen from the air to the surgical wound in order to prevent hypoxia-induced scar formation during the initial proliferative phase of wound healing. To the best of our knowledge, the clinical application of e-PTFE for complicated multirecurrent pterygia has not been previously reported. The goal of this prospective clinical trial is to evaluate the efficiency of using multimicroporous e-PTFE as a novel treatment option in cases of complicated multirecurrent pterygia treated combined with MMC application, AMT and CLAU.

METHODS

Subjects

A total of 62 eyes from 62 patients were enrolled in a prospective clinical trial at the Chung-Ang University Hospital, Seoul, Korea. The inclusion criteria were multirecurrent (≥ 2 recurrences) pterygia, T3 grade (fleshy) based on the grading system of Tan *et al*,⁹ and manifestation of either symblepharon or motility restriction-related binocular diplopia. These patients were assigned to receive e-PTFE insertion (group A; 30 eyes) or not (group B; 32 eyes). Before surgery, all patients were inquired to insert intraoperative multimicroporous e-PTFE, and patients who did not want were assigned to group B. Preoperatively, each patient underwent complete ocular examination, and patients with glaucoma, scleromalacia or previous history of refractory surgery in the same eye were not included. The study protocol and informed consent were approved by the institutional review board of the Chung-Ang University Hospital, and the study conformed to the tenets of the Declaration of Helsinki.

Preparation of multimicroporous e-PTFE

A 0.1-mm-thick e-PTFE sheet (GORE PRECLUDE Pericardial Membrane, Gore, Flagstaff, Arizona, USA) was cut to fit under the caruncle and



Open Access
Scan to access more
free content

To cite: Kim KW, Kim JC, Moon JH, *et al*. *Br J Ophthalmol* 2013;**97**:694–700.

conjunctiva nasally, and to a length temporally beyond the midpoint between the caruncle and nasal corneal limbus for group A patients. After cutting, multiple micropores were made for aeration by pricking the e-PTFE with a 30-gauge needle, passing half the length of the bevel through the sheet between 100 and 200 times depending on the size of the e-PTFE piece. Pricking was mainly performed in the area that was uncovered with the overlying conjunctiva and caruncle (figure 1A,B).

Surgical procedures

The key surgical steps are shown in figure 1. All patients were anaesthetised with a retrobulbar block. Symblepharon was released and fibrotic tissue was extensively dissected to expose the sclera and corneal stroma. The subconjunctival fibrovascular tissue, including Tenon's capsule, were thoroughly removed using scissors from the sclera and medial rectus muscle (MRM) at the area of the superior and inferior fornices and the nasal caruncle. A cryopreserved human amniotic membrane (AM) (AmniSite-Cornea, Bioland, Ochang, Korea) was then placed on the entire exposed bare sclera and MRM with the epithelial side facing upward, and secured with 10-0 nylon sutures. Weckel sponges soaked with 0.033% MMC were inserted into the gap covering the entire forniceal region for 2 min, followed by irrigation with 200 ml of balanced salt solution. For group A patients, a multimicroporous e-PTFE was then inserted and

fitted with the minimum dead space possible into the gap between the caruncle and the transplanted AM on the bare sclera. The edges of the e-PTFE sheet were then secured by 10-0 nylon sutures. Thereafter, CLAU was performed. Limbal tissue equal in arc length to that of the nasal bare limbus, but not exceeding 6 mm, was obtained from the superotemporal area of the contralateral eye. The tissue was placed on the AM and secured with 10-0 nylon sutures to the conjunctival edge superiorly and inferiorly, and to the temporal edge of e-PTFE nasally just beneath the e-PTFE. At the end of the surgery, an AM patch large enough to cover the entire excised area was placed with the stromal side facing upward and secured with 10-0 nylon sutures.

Postoperative management and evaluation

Postoperatively, topical 0.1% levofloxacin drops (Cravit, Santen, Osaka, Japan) were applied four times per day, dexamethasone 0.1% ointment mixed with 0.35% neomycin sulfate (Maxitrol, Alcon, Fort Worth, Texas, USA) was applied two times per day, and 40% autoserum drops were applied every 2 waking hours for 4 weeks. After 4 weeks, the use of levofloxacin was discontinued, and the ointment and autoserum applications were gradually reduced to one time and four times daily, respectively. The attached AM patch was removed after 1 week, and the sutures on the CLAU and AMT were removed 2 weeks after surgery. At

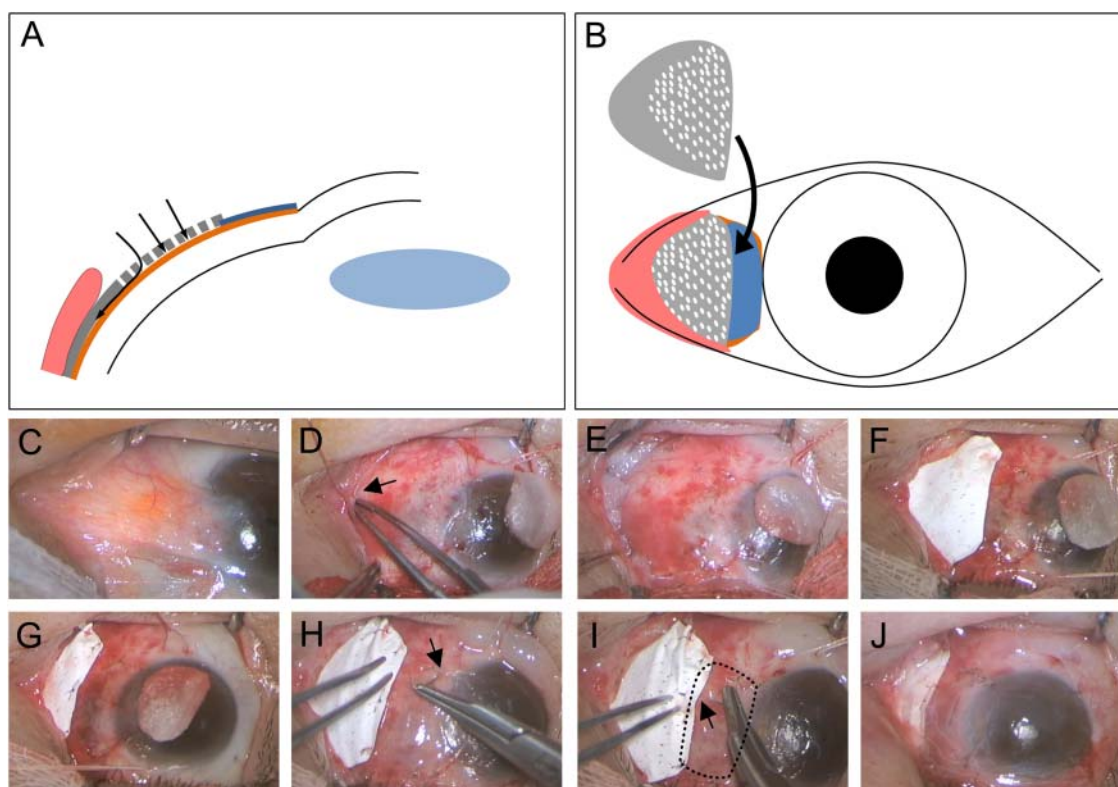


Figure 1 Intraoperative insertion of the multimicroporous expanded polytetrafluoroethylene (e-PTFE) and key surgical steps. (A,B) Multiple micropores were made to promote passage of air through the e-PTFE (arrows in (A)) at the caruncle. After pricking (white-coloured ovals), multimicroporous e-PTFE (grey colour) was inserted and well fitted nasally with the minimum dead space into the gap between the caruncle (pink colour) and amniotic membrane (AM) (orange colour) onto bare sclera. e-PTFE slightly covered the conjunctival limbal autograft (CLAU) site (blue colour) at its temporal edge to be secured. Note that pricking was not performed in the area to be covered with the overlying conjunctiva and caruncle. (C) In a case with nasal symblepharon and severely flattened caruncle, after thorough removal of subconjunctival fibrovascular tissue, (D) AM was transplanted on the bare sclera and to the under-caruncle (arrow in (D)). (E) Then, mitomycin C was applied into the gap covering the entire forniceal lesion. (F) Multimicroporous e-PTFE was inserted and fitted into the gap, (G) and was well secured and buried. (H,I) Thereafter, CLAU (black dotted line in (I)) was performed and secured to conjunctiva (arrow in (H)) and to e-PTFE (arrow in (I)). (J) At the end of the surgery, an AM patch large enough to cover the entire excised area was placed and secured with the stromal side facing upward.

3 to 4 weeks postoperatively, in group A, the inserted multimicroporous e-PTFE was extracted using forceps after removal of the sutures.

All patients were observed every 2 days for the first week, weekly for the first month, monthly for the next 3 months and every 2 months thereafter for 2 years postoperatively. Clinical outcome measures were further recurrence, resolution of symblepharon, ocular motility, binocular diplopia and subjective issues of hyperaemia. The presence or absence of symblepharon formation was recorded by using slit lamp biomicroscopy. In cases associated with diplopia, a double-vision chart test was performed. This test examined the area of diplopia within 40° from the central fixation point. The results were recorded semi-quantitatively using the criteria of Shimazaki *et al.*⁵ Restriction of ocular motility on the horizontal plane was graded on a scale of 0 to -4. Grade D1 of binocular diplopia and grade -1 of motility restriction were classified as mild forms, and the rest as severe forms. Recurrence of pterygia was determined by the grading system of Prabhasawat *et al* (table 1).⁴ To evaluate the perioperative change in the subjective issue of conjunctival hyperaemia, severity was estimated using a questionnaire asking patients to rate their symptoms according to a visual analogue scale (VAS), with 0 representing no discomfort and 10, unbearable symptoms.

Statistical analysis

Statistical analysis was performed using SPSS software V19.0 (SPSS, Inc, Chicago, Illinois, USA). All demographic data and surgical results between two groups were compared using the χ^2 test, Fisher's exact test and Mann-Whitney U test. Postoperative clinical improvements for patients in both groups were evaluated using the McNemar test and Wilcoxon signed rank test. A p value less than 0.05 was considered to be statistically significant.

Table 1 Clinical grading system for binocular diplopia, ocular motility restriction and postoperative recurrence

| Grade | Characteristic(s) |
|------------------------------------|---|
| Binocular diplopia | |
| D0 | No area of diplopia |
| D1 (mild) | Diplopia within 40°, but not within 20° |
| D2 (severe) | Diplopia present within 20°, without involvement of the central gazing point |
| D3 (severe) | Diplopia involving the gazing point |
| Ocular motility restriction | |
| 0 | No limitation of eye movement |
| -1 (mild) | 75% movement beyond the midline |
| -2 (severe) | 50% movement beyond the midline |
| -3 (severe) | 25% movement beyond the midline |
| -4 (severe) | No movement beyond the midline |
| Postoperative recurrence | |
| G1 | Normal appearance of the operated site |
| G2 | Presence of fine episcleral vessels in the excised area, extending to the limbus but without any fibrous tissue |
| G3 | Fibrovascular tissue in the excised area, reaching the limbus but not the cornea (conjunctival recurrence) |
| G4 | True corneal recurrence with fibrovascular tissue on the cornea |

RESULTS

A total of 62 eyes from 62 patients, in which a follow-up at least 14 months was achieved, were included in this study. The mean age was 49.7±2.4 years (range, 30–64 years) and the mean follow-up period was 17.3±2.4 months (range, 14–23 months). All eyes had undergone at least two previous pterygia excisions (mean, 2.5; range, 2–6). No statistically significant differences existed between the two groups in terms of demographics and preoperative clinical characteristics (table 2).

Symblepharon release, extensive subconjunctival fibrovascular tissue and Tenon's capsule removal, AMT, 0.033% MMC application for 2 min, CLAU and AM patch were undertaken in the same manner in all eyes, and no intraoperative complications were encountered. Postoperatively, epithelialisation of the AM-covered sclera was complete in 2 weeks in both groups. In group A, complete epithelialisation was observed below the sheet in all eyes when the e-PTFE was removed 3–4 weeks after surgery. Donor sites were promptly epithelialised with no or minimal scar formation. No postoperative complications were encountered in either group.

For group A, in the mean follow-up period, symblepharon was significantly improved after surgery ($p=0.000$) without further reformation (figure 2). The proportion of patients with

Table 2 Demographics and preoperative clinical characteristics of patients with multirecurrent pterygium underwent surgery with and without multimicroporous expanded polytetrafluoroethylene (e-PTFE) insertion

| | Group A (with e-PTFE insertion) | Group B (without e-PTFE insertion) | p Value |
|---------------------------------|---------------------------------|------------------------------------|---------|
| No. of eyes | 30 | 32 | |
| Age, years | 48.0±8.8 | 51.3±7.7 | 0.123* |
| Gender, male/female | 16/14 | 16/16 | 0.793† |
| Number of previous recurrences | 2.6±0.9 | 2.4±0.9 | 0.353* |
| Postoperative follow-up, months | 17.2±2.3 | 17.3±2.5 | 0.887* |
| Symblepharon | 20/30 (66.7%) | 16/32 (50.0%) | 0.184† |
| Ocular motility: | | | |
| Severity | | | 0.213† |
| None to mild | 15/30 (50%) | 21/32 (65.6%) | |
| Severe | 15/30 (50%) | 11/32 (34.4%) | |
| Grade | | | 0.066† |
| 0 | 0 (0%) | 0 (0%) | |
| -1 (mild) | 15 (50%) | 21 (65.6%) | |
| -2 (severe) | 7 (23.3%) | 9 (28.1%) | |
| -3 (severe) | 6 (20.0%) | 0 (0%) | |
| -4 (severe) | 2 (6.7%) | 2 (6.3%) | |
| Diplopia: | | | |
| Severity | | | 0.871† |
| None to mild | 21/30 (70%) | 23/32 (71.9%) | |
| Severe | 9/30 (30%) | 9/32 (28.1%) | |
| Grade | | | 0.859† |
| D0 | 0 (0%) | 0 (0%) | |
| D1 (mild) | 21 (70%) | 23 (71.9%) | |
| D2 (severe) | 6 (20%) | 7 (21.9%) | |
| D3 (severe) | 3 (10%) | 2 (6.3%) | |
| Conjunctival hyperaemia (VAS) | 8.1±1.4 | 7.7±1.4 | 0.214* |

*Mann-Whitney U test.

† χ^2 test.

VAS, visual analogue scale.

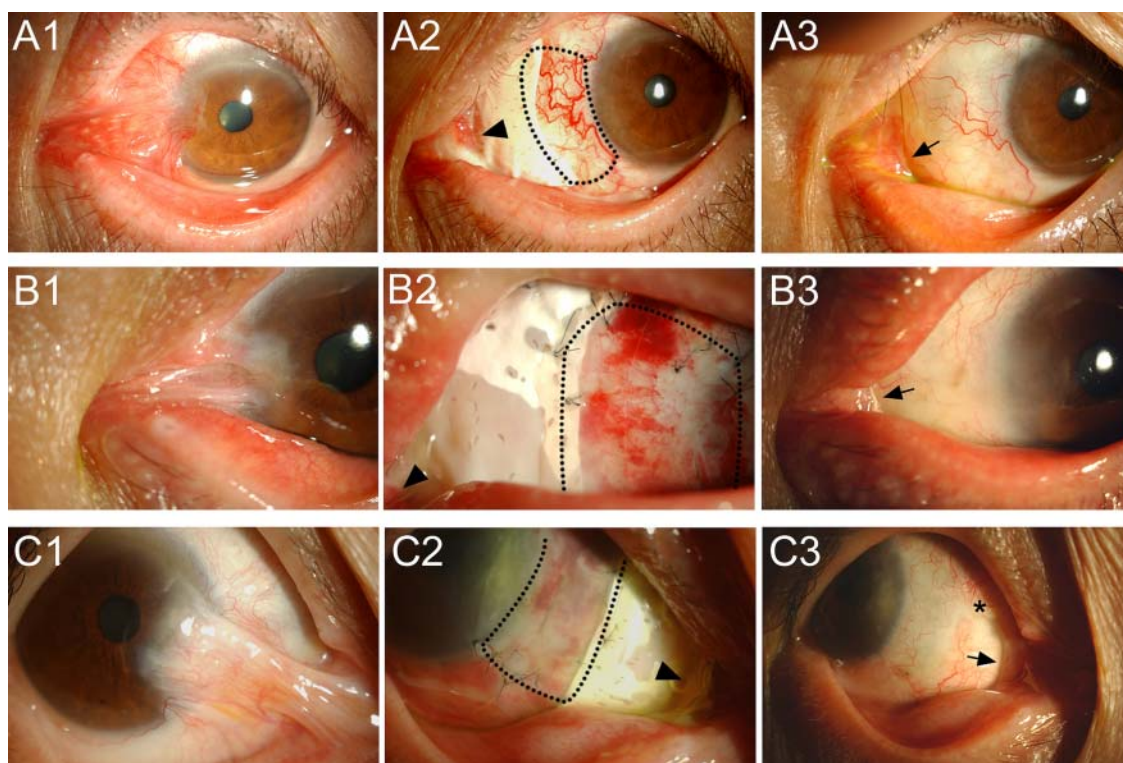


Figure 2 Preoperative and postoperative appearances of 3 eyes from 30 patients (group A) who underwent intraoperative insertion of the multimicroporous expanded polytetrafluoroethylene (e-PTFE). (A1,B1,C1) Preoperatively, the severe adhesion of the lower lid or caruncle to the cornea was noted with motility restriction. (A2,B2,C2) A multimicroporous e-PTFE was inserted and fitted into the gap (arrowhead) between the caruncle and the transplanted amniotic membrane on the bare sclera before its removal. Conjunctival limbal autograft tissue (black dotted line) was secured to the temporal edge of e-PTFE. (A3,B3,C3) In a maximal follow-up period after surgery, well formed nasal caruncle (arrow) without fibrovascular outgrowth or cicatrix formation is noted in contrast to the formation of caruncular adhesion (asterisk in (C3)) at the area in which e-PTFE had not inserted.

a severe form of motility restriction or binocular diplopia significantly decreased after surgery ($p=0.000$ and 0.008 , respectively). In all, 24 (80%) out of 30 patients achieved full motility with resolution of binocular diplopia after surgery. Subjective symptoms of conjunctival hyperaemia were significantly improved from an average VAS score of 8.1 ± 1.4 (range, 4–10) preoperatively to 2.5 ± 1.1 (range, 1–5) postoperatively at the maximal follow-up ($p=0.000$). For group B, symblepharon formation and subjective score of conjunctival hyperaemia were significantly improved ($p=0.002$ and 0.000 , respectively) in contrast to ocular motility and diplopia of which perioperative difference were not statistically significant ($p=0.549$ and 0.388 , respectively; table 3).

After surgery, symblepharon formation, severe forms of motility restriction and the subjective issue of conjunctival hyperaemia were significantly less in group A compared to group B ($p=0.024$, 0.027 and 0.000 , respectively). Postoperatively, there were fewer patients with the severe form of diplopia in group A, but this was not statistically significant ($p=0.197$; table 3).

One eye (3.3%) in group A demonstrated postoperative pterygium recurrence, which is corneal recurrence (G4) at 6 months; however, eight eyes (25%) showed corneal recurrence in group B—a significantly higher rate ($p=0.027$; table 3). The latter cases showed marked fibrovascular adhesion at conjunctival caruncle (figure 3) in contrast to group A patients who attained a well formed nasal caruncle and also avoided fibrovascular outgrowth or cicatrix formation (figure 2). The one patient with corneal recurrence in group A was left with residual D1 diplopia and -2 motility restriction grade, but did not require further

surgery because the corneal invasion was limited and stable during the maximal follow-up period (figure 3).

DISCUSSION

Multirecurrent pterygium is easily complicated due to the exaggerated proliferative tendency represented by active fibroplasia, wound contraction and angiogenic sprouting.¹ Two main perioperative strategies are essential to relax the exaggerated hyperproliferation in multirecurrent pterygia. The first is to minimise postoperative inflammation, which may prolong proliferation and angiogenesis. The second is to maximise the ablation of residual fibroblasts on the surgical wound area. Solomon *et al*¹⁰ emphasised the thorough removal of subconjunctival fibrovascular tissue before AMT in order to achieve a low recurrence rate. Tseng *et al*¹¹ demonstrated that AMT has a potent antifibrotic effect through suppression of the transforming growth factor (TGF) β signalling pathway in fibroblasts. As an option for reducing the postoperative recurrence rate, Nabawi *et al*¹² used MMC combined with CLAU, and reported no cases of postoperative recurrence in recurrent pterygia. We therefore attempted to thoroughly remove the subconjunctival fibrovascular tissue including Tenon's capsule, from the sclera and MRM, followed by the combination of AMT, 0.033% MMC application and CLAU before multimicroporous e-PTFE insertion.

To prevent postoperative recurrence of pterygium, restoring caruncle morphological characteristics is crucial because of the greater abundance of fibrovascular tissue in the caruncle. Hirst reported that the reconstruction of the semilunar fold contributed to a low recurrence rate of recurrent pterygium surgery, and

Table 3 Surgical results of patients with multirecurrent pterygium underwent surgery with and without multimicroporous expanded polytetrafluoroethylene (e-PTFE) insertion

| Outcome measure | Group A (n=30) (p Value*) (with e-PTFE insertion) | Group B (n=32) (p Value*) (without e-PTFE insertion) | p Value |
|-------------------------------|--|---|---------|
| Symblepharon | 0/30 (0%) (p=0.000†) | 6/32 (18.8%) (p=0.002†) | 0.024§ |
| Ocular motility: | | | |
| Severity | | | |
| None to mild | 29 (96.7%) | 24 (75%) | |
| Severe | 1 (3.3%) (p=0.000†) | 8 (25%) (p=0.549†) | 0.027§ |
| Grade | | | |
| 0 | 24 (80.0%) | 18 (56.2%) | |
| -1 (mild) | 50 (16.7%) | 6 (18.8%) | |
| -2 (severe) | 1 (3.3%) | 6 (18.8%) | |
| -3 (severe) | 0 (0%) | 2 (6.2%) | |
| -4 (severe) | 0 (0%) | 0 (0%) | |
| Diplopia: | | | |
| Severity | | | |
| None to mild | 29 (96.7%) | 27 (84.4%) | |
| Severe | 1 (3.3%) (p=0.008†) | 5 (15.6%) (p=0.388†) | 0.197§ |
| Grade | | | |
| D0 | 25 (83.3%) | 17 (53.1%) | |
| D1 (mild) | 4 (13.3%) | 10 (31.3%) | |
| D2 (severe) | 1 (3.3%) | 5 (15.6%) | |
| D3 (severe) | 0 (0%) | 0 (0%) | |
| Conjunctival hyperaemia (VAS) | 2.5±1.1 (p=0.000‡) | 4.4±1.9 (p=0.000‡) | 0.000¶ |
| Pterygium recurrence: | | | |
| G1 | 23 (76.7%) | 12 (37.5%) | |
| G2 | 5 (16.7%) | 7 (21.9%) | |
| G3 | 1 (3.3%) | 5 (15.6%) | |
| G4 (corneal recurrence) | 1 (3.3%) | 8 (25.0%) | 0.027§ |

*Postoperative improvement of clinical outcome measure.

†McNemar test.

‡Wilcoxon signed rank test.

§Fisher's exact test.

¶Mann-Whitney U test.

VAS, visual analogue scale.

also improved cosmetic appearance.¹³ For such a strategy, in addition, sealing the gap between the conjunctiva and the Tenon's capsule was proposed by Liu *et al*¹⁴ and led to a significantly preferable surgical outcome with low recurrence. This could create a strong barrier for emanating fibrovascular cicatrix in the caruncle, and furthermore could prevent fibrovascular tissue from adhering to the sclera. In a similar vein to the concept of sealing the gap, we inserted a well fitted e-PTFE sheet with minimum dead space to separate the wound at the caruncle from the sclera, avoiding tissue-to-tissue contact that might lead to cicatricial adhesion formation. Isolation of adjacent wound tissues was previously known to be important to avoid the cell-to-cell contact that contributes to tissue adhesion during the early phase of wound healing, characterised by fibroblast and myofibroblast proliferation.¹⁵

Because e-PTFE (Gore-Tex) is a chemically inert and non-antigenic material that is well tolerated in situ, it has been widely used in the ophthalmic area for various purposes. In cicatrising diseases such as severe alkali chemical injury or ocular pemphigoid, e-PTFE has been used as a spacer to prevent lid fusion and to reform the upper eyelid fornix,^{8, 16} and as a

substitute for the mucus membrane in patients with contracted anophthalmic sockets to separate raw apposed bulbar and palpebral surfaces to prevent recicatricialisation.¹⁷ In addition, due to its high level of biocompatibility, e-PTFE was also used as an encapsulator for Ahmed glaucoma valves for thinner adjacent fibrous capsule formation,¹⁸ and has also been used in strabismus surgery safely for muscle elongation to correct deviation.¹⁹

Likewise, e-PTFE was applied in our study to minimise the cicatrix formation at the caruncle and fornix especially during the early proliferative phase of wound healing. While e-PTFE can prevent reformation of symblepharon and scarring, a hypoxic environment might be created at the wound just beneath the e-PTFE. Falanga *et al*²⁰ reported that activity of TGFβ1, which is known to have relevance to pterygium pathogenesis, was elevated up to nine times higher under 2% oxygen. Falanga and Kirsner²¹ showed that cultured human dermal fibroblasts under 2% oxygen had a proliferative velocity 600 times faster than those under 20% oxygen. Assaad *et al*²² used hyperbaric oxygen in the management of recurrent pterygium, and reported a successful surgical outcome. However, the innate pores of e-PTFE are smaller than 1 µm in diameter, which is too small for oxygen to pass through enough. To overcome this, we used a 'multimicroporous' e-PTFE sheet. This new configuration was used to promote oxygenation under the inserted e-PTFE sheet during the early proliferative phase of wound healing. To block possible postoperative wound adhesion, the pricking was mainly confined to the uncovered area overlying the caruncle or conjunctiva to minimise cell-to-cell contact through the micropores.

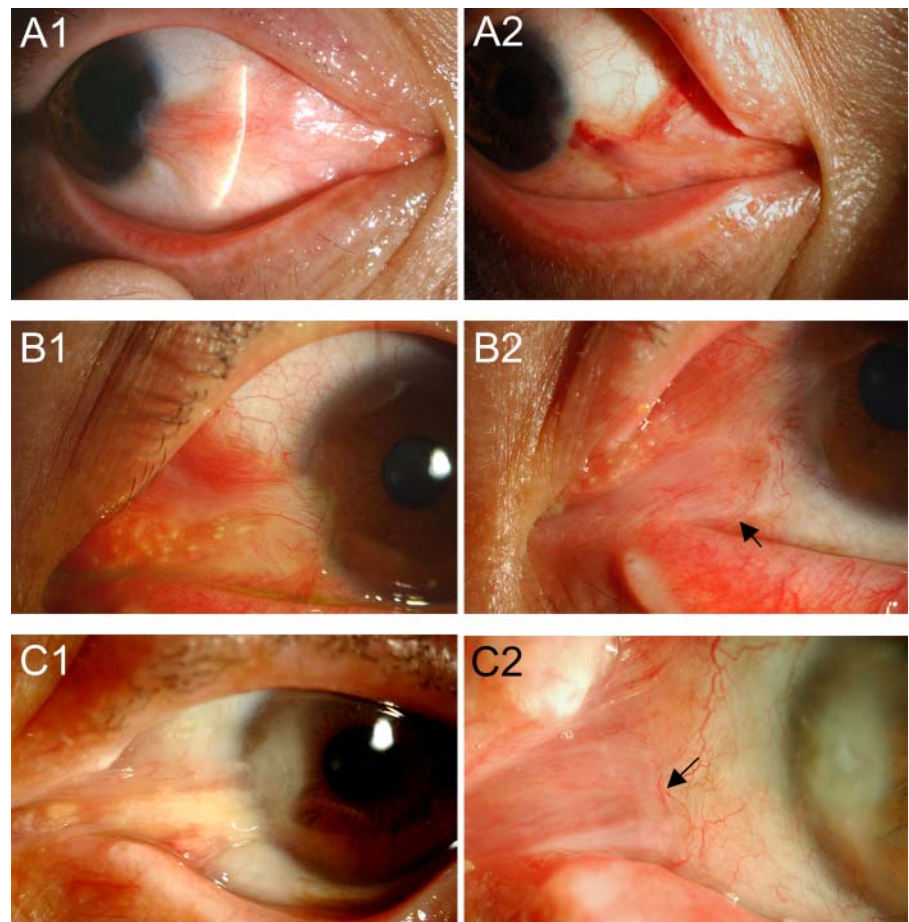
We used a 30-gauge needle with a 300 µm outer diameter, generally the smallest size available among needles frequently used and freely available in hospitals. Moreover, the needle was passed just half the length of the bevel to minimise the pore size to be one-third to one-quarter of the area of the 30-gauge needle shaft. The measured area of a pore was approximately $1.8 \times 10^4 \mu\text{m}^2$, which was equivalent to the size of a pore with 150–170 µm diameter. However, a small-aperture intracorneal inlay that has holes of 25 µm diameter was reported to allow oxygen and sufficient nutritional flow.²³ An intraoperative pricking technique each time may be quite cumbersome. To this end, predesigned e-PTFE with ready-made uniform smaller pores enabling free passage of oxygen could be tried in future studies.

During wound healing, the proliferative phase, which is signified by an abundance of fibroblasts and an accumulation of extracellular matrix (ECM), begins after the 2 to 3 days of the inflammatory phase and lasts for 3–6 weeks.²⁴ Therefore, we left the multimicroporous e-PTFE in place for 3 to 4 weeks after surgery to encompass the inflammatory and proliferative phases and to reduce and prevent the exaggeration of fibroplasia and angiogenesis.

In this study, our multimicroporous e-PTFE sheet insertion technique combined with conventional surgical methods showed a 3.3% recurrence rate, which was preferable to the 14.3% recurrence rate reported using MMC, AMT and/or CLAU for multirecurrent pterygia with symblepharon and motility restriction.²⁵ Although diverse surgical techniques were reported to be available to lower the recurrence rate for recurrent pterygium,^{13, 22} our study is not directly comparable because it was aimed at multirecurrent pterygia, which might display a tendency for more exaggerated proliferation. A relatively high recurrence rate of 25% in the group without e-PTFE insertion is also thought to be due to having enrolled patients with multipterygium.

In addition, there were no cases with delayed epithelial healing or recurrent epithelial defects, which may imply that

Figure 3 Postoperative cases with pterygium recurrence. (A) In one eye (3.3%) in group A (with e-PTFE insertion), pterygium recurrence developed after surgery. Appearance before surgery (A1), and at 6 months after surgery (A2) with shallow corneal invasion. (B,C) In group B (without e-PTFE insertion), 8 eyes (25.0%) from 32 patients demonstrated postoperative recurrences. (B2,C2) Prominent outgrowth of fibrovascular tissue from the caruncle and its adhesion to the conjunctiva (arrow) is noted after surgery (B1 and C1 show the same eyes before surgery).



contact of e-PTFE on the ocular surface itself does not interrupt the epithelialisation. Re-epithelialisation of the wound is thought to derive from the adjacent conjunctival edge and/or limbal graft, facilitated by underlying AMT (in the opinion of the authors).

Conjunctival hyperaemia is one of the most unbearable symptoms in patients with pterygia, so we graded the subjective issue of hyperaemia using a VAS system in all patients. Scores improved from 8.1 ± 1.4 (range, 4–10) preoperatively to 2.5 ± 1.1 (range, 1–5) postoperatively. This seems to be attributed to suppression of the production of angiogenic factors such as endothelin 1, vascular endothelial growth factor (VEGF) and TGF β via sufficient oxygenation through the micropores in the e-PTFE, added to the anti-inflammatory effect of AMT. Furthermore, e-PTFE insertion may possibly reduce the demand for subconjunctival corticosteroid injections, which can induce ocular hypertension and cost burden of subconjunctival VEGF injection.

Our study has several limitations. It was non-randomised and a longer follow-up is needed to evaluate the late complications of MMC, such as necrotising scleritis. However, this study is the first report of e-PTFE application in complicated multirecurrent pterygia with the purpose of improving complications and lowering recurrence. In addition, the postoperative follow-up in all cases was 14 months or more, which was long enough to evaluate recurrence. Although the several steps of surgical technique and postoperative removal of the implant may be inconvenient or unpopular to some surgeons, our favourable surgical outcomes are significant in terms of having targeted complicated multirecurrent pterygia that is essentially intractable to variable treatments.

In conclusion, intraoperative multimicroporous e-PTFE insertion, which can restore morphological characteristics of the caruncle effectively, seems to be a useful novel approach for treating intractable complicated multirecurrent pterygia, especially when accompanied by conventional combination treatments including MMC application, AMT and CLAU. Additionally, in the future, the use of multimicroporous e-PTFE insertion may be applicable for the treatment of various ocular surface disorders with severe scar formation, such as Stevens–Johnson syndrome, ocular cicatricial pemphigoid or chemical burns.

VAS, visual analogue scale.

Contributors KWK, JCK: involved in design of study; KWK, HK, THK, NJM, JCK: conduct of study; KWK, JHM: data collection; KWK, JCK: analysis and interpretation of data; NJM, JCK: review; JCK: approval of manuscript.

Funding This study was supported by the Basic Science Research Program through the National Research Foundation of Korea (NRF) funded by the Ministry of Education, Science and Technology (2012–0005222).

Competing interests None.

Patient consent Obtained.

Ethics approval The institutional review board of the Chung-Ang University Hospital.

Provenance and peer review Not commissioned; externally peer reviewed.

Open Access This is an Open Access article distributed in accordance with the Creative Commons Attribution Non Commercial (CC BY-NC 3.0) license, which permits others to distribute, remix, adapt, build upon this work non-commercially, and license their derivative works on different terms, provided the original work is properly cited and the use is non-commercial. See: <http://creativecommons.org/licenses/by-nc/3.0/>

REFERENCES

- Bradley JC, Yang W, Bradley RH, et al. The science of pterygia. *Br J Ophthalmol* 2010;94:815–20.

- 2 Lam DS, Wong AK, Fan DS, *et al.* Intraoperative mitomycin C to prevent recurrence of pterygium after excision: a 30-month follow-up study. *Ophthalmology* 1998;105:901–4; discussion 4–5.
- 3 Kenyon KR, Wagoner MD, Hettinger ME. Conjunctival autograft transplantation for advanced and recurrent pterygium. *Ophthalmology* 1985;92:1461–70.
- 4 Prabhasawat P, Barton K, Burkett G, *et al.* Comparison of conjunctival autografts, amniotic membrane grafts, and primary closure for pterygium excision. *Ophthalmology* 1997;104:974–85.
- 5 Shimazaki J, Kosaka K, Shimmura S, *et al.* Amniotic membrane transplantation with conjunctival autograft for recurrent pterygium. *Ophthalmology* 2003;110:119–24.
- 6 Batniji RK, Hutchison JL, Dahiya R, *et al.* Tissue response to expanded polytetrafluoroethylene and silicone implants in a rabbit model. *Arch Facial Plast Surg* 2002;4:111–13.
- 7 Karesh JW, Fabrega MA, Rodrigues MM. Interpositional polytetrafluoroethylene grafts. Conjunctival biocompatibility. *Ophthalm Plast Reconstr Surg* 1991;7:278–83.
- 8 Schmidt T, Kohler W. [Fornix reconstruction in ocular pemphigoid with Goretex surgical membrane]. *Ophthalmologie* 1997;94:321–3.
- 9 Tan DT, Chee SP, Dear KB, *et al.* Effect of pterygium morphology on pterygium recurrence in a controlled trial comparing conjunctival autografting with bare sclera excision. *Arch Ophthalmol* 1997;115:1235–40.
- 10 Solomon A, Pires RT, Tseng SC. Amniotic membrane transplantation after extensive removal of primary and recurrent pterygia. *Ophthalmology* 2001;108:449–60.
- 11 Tseng SC, Li DQ, Ma X. Suppression of transforming growth factor-beta isoforms, TGF-beta receptor type II, and myofibroblast differentiation in cultured human corneal and limbal fibroblasts by amniotic membrane matrix. *J Cell Physiol* 1999;179:325–35.
- 12 Nabawi KS, Ghonim MA, Ali MH. Evaluation of limbal conjunctival autograft and low-dose mitomycin C in the treatment of recurrent pterygium. *Ophthalmic Surg Lasers Imaging* 2003;34:193–6.
- 13 Hirst LW. Recurrent pterygium surgery using pterygium extended removal followed by extended conjunctival transplant: recurrence rate and cosmesis. *Ophthalmology* 2009;116:1278–86.
- 14 Liu J, Fu Y, Xu Y, *et al.* New grading system to improve the surgical outcome of multirecurrent pterygia. *Arch Ophthalmol* 2012;130:39–49.
- 15 Mahdavian Delavary B, van der Veer WM, van Egmond M, *et al.* Macrophages in skin injury and repair. *Immunobiology* 2011;216:753–62.
- 16 Kumar A, McCormick A, Bhargava JS. Temporary Gorex (polytetrafluoroethylene) spacer for the treatment of fornix shortening following severe alkali chemical injury. *Orbit* 2011;30:252–4.
- 17 Levin PS, Dutton JJ. Polytef (polytetrafluoroethylene) alloplastic grafting as a substitute for mucous membrane. *Arch Ophthalmol* 1990;108:282–5.
- 18 DeCroos FC, Ahmad S, Kondo Y, *et al.* Expanded polytetrafluoroethylene membrane alters tissue response to implanted Ahmed glaucoma valve. *Curr Eye Res* 2009;34:562–7.
- 19 Langmann A, Lindner S, Wackernagel W, *et al.* Polytetrafluoroethylene (Goretex) for muscle elongation in the surgical treatment of strabismus with restricted motility. *Acta Ophthalmol Scand* 2006;84:250–3.
- 20 Falanga V, Qian SW, Danielpour D, *et al.* Hypoxia upregulates the synthesis of TGF-beta 1 by human dermal fibroblasts. *J Invest Dermatol* 1991;97:634–7.
- 21 Falanga V, Kirsner RS. Low oxygen stimulates proliferation of fibroblasts seeded as single cells. *J Cell Physiol* 1993;154:506–10.
- 22 Assaad NN, Chong R, Tat LT, *et al.* Use of adjuvant hyperbaric oxygen therapy to support limbal conjunctival graft in the management of recurrent pterygium. *Cornea* 2011;30:7–10.
- 23 Dexl AK, Seyeddain O, Riha W, *et al.* Reading performance after implantation of a small-aperture corneal inlay for the surgical correction of presbyopia: Two-year follow-up. *J Cataract Refract Surg* 2011;37:525–31.
- 24 Su WH, Cheng MH, Lee WL, *et al.* Nonsteroidal anti-inflammatory drugs for wounds: pain relief or excessive scar formation? *Mediators Inflamm* 2010;2010:1–8.
- 25 Yao YF, Qiu WY, Zhang YM, *et al.* Mitomycin C, amniotic membrane transplantation and limbal conjunctival autograft for treating multirecurrent pterygia with symblepharon and motility restriction. *Graefes Arch Clin Exp Ophthalmol* 2006;244:232–6.