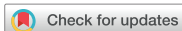

## Case Report



# Laparoscopic Hiatal Hernia Repair and Roux-en-Y Conversion for Refractory Duodenogastroesophageal Reflux after Billroth I Distal Gastrectomy

Joong-Min Park , Sung Jin Yoon , Jong Won Kim , Kyong-Choun Chi

Department of Surgery, Chung-Ang University College of Medicine, Seoul, Korea

## OPEN ACCESS

Received: May 18, 2020

Revised: Jun 18, 2020

Accepted: Jun 22, 2020

### Correspondence to

Joong-Min Park

Department of Surgery, Chung-Ang University  
College of Medicine, 102 Heukseok-ro,  
Dongjak-gu, Seoul 06973, Korea.  
E-mail: jmpark@cau.ac.kr

Copyright © 2020. Korean Gastric Cancer  
Association

This is an Open Access article distributed  
under the terms of the Creative Commons  
Attribution Non-Commercial License ([https://  
creativecommons.org/licenses/by-nc/4.0](https://creativecommons.org/licenses/by-nc/4.0))  
which permits unrestricted noncommercial  
use, distribution, and reproduction in any  
medium, provided the original work is properly  
cited.

### ORCID iDs

Joong-Min Park

<https://orcid.org/0000-0002-8582-6391>

Sung Jin Yoon

<https://orcid.org/0000-0002-1946-2219>

Jong Won Kim

<https://orcid.org/0000-0002-9556-7143>

Kyong-Choun Chi

<https://orcid.org/0000-0001-8703-5377>

### Author Contributions

Conceptualization: P.J.M.; Data curation:  
P.J.M.; Formal analysis: P.J.M.; Investigation:  
P.J.M., Y.S.J.; Writing - original draft: P.J.M.,  
Y.S.J.; Writing - review & editing: K.J.W., C.K.C.

### Conflict of Interest

No potential conflict of interest relevant to this  
article was reported.

## ABSTRACT

Distal gastrectomy with Billroth I or II reconstruction may cause duodenogastroesophageal reflux (DGER), thereby resulting in digestive or respiratory symptoms. The mainstay of treatment is medication with proton pump inhibitors. However, these drugs may have limited effects in DGER. Laparoscopic fundoplication has been proven to be highly effective in treating gastroesophageal reflux disease (GERD), but it cannot be performed optimally for GERD that develops after gastrectomy. We report the case of a 72-year-old man with a history of distal gastrectomy and Billroth I anastomosis due to early gastric cancer. GERD due to bile reflux occurred after surgery and was refractory to medical therapy. The patient underwent Roux-en-Y conversion from Billroth I gastroduodenostomy and hiatal hernia repair with only cruroplasty. Fundoplication was not performed. His symptoms improved significantly after the surgery. Therefore, laparoscopic hiatal hernia repair and Roux-en-Y conversion can be an effective surgical procedure to treat medically refractory DGER after Billroth I gastrectomy.

**Keywords:** Gastroesophageal reflux; Billroth reconstruction; Duodenogastroesophageal reflux; Roux-en-Y; Anti-reflux surgery

## INTRODUCTION

After distal gastrectomy for gastric cancer, reconstruction of the gastrointestinal tract is necessary. There are various methods of reconstruction, such as Billroth I, Billroth II, and Roux-en-Y [1-3]. Billroth I or II anastomosis is the most commonly performed procedure because it is simpler than Roux-en-Y anastomosis [4]. However, reflux of duodenal contents into the gastric remnant and esophagus, termed as duodenogastroesophageal reflux (DGER), can occur in patients who have undergone Billroth I or II reconstruction. This can cause serious complications and decrease the quality of life of these patients [2].

DGER is usually treated with medications. Proton pump inhibitors (PPIs) are considered the principal treatment for gastroesophageal reflux disease (GERD) but have shown limited effects for DGER [5]. As a surgical option, laparoscopic fundoplication is an effective and standard treatment modality for GERD. However, fundoplication is not feasible for the remnant stomach because the condition of the blood supply to and size of the remnant stomach differ from those

of the normal stomach. Therefore, Roux-en-Y conversion is an alternative surgical option for treating DGER [6,7]. Here, we aimed to describe the procedure and outcomes of laparoscopic anti-reflux surgery in a patient with intractable DGER after Billroth I reconstruction.

## CASE REPORT

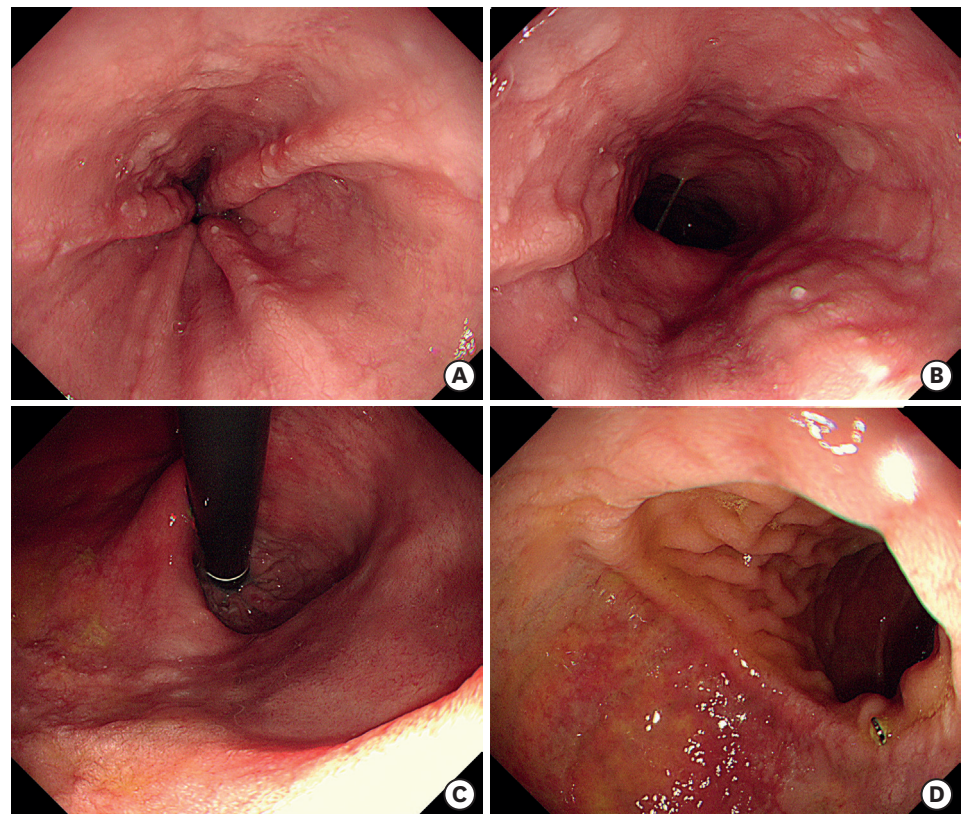
### Patient history and evaluation

A 72-year-old man was admitted for the treatment of heartburn and regurgitation that have been ongoing for 2 years. The patient had undergone laparoscopy-assisted distal gastrectomy with Billroth I reconstruction using a circular stapler for early gastric cancer 16 years ago. He complained of heartburn, acid regurgitation, and upper abdominal pain for the last 2 years. Although he took PPIs, prokinetic drugs, and bile acid-binding agents, his symptoms remained severe and appeared refractory to medical treatment.

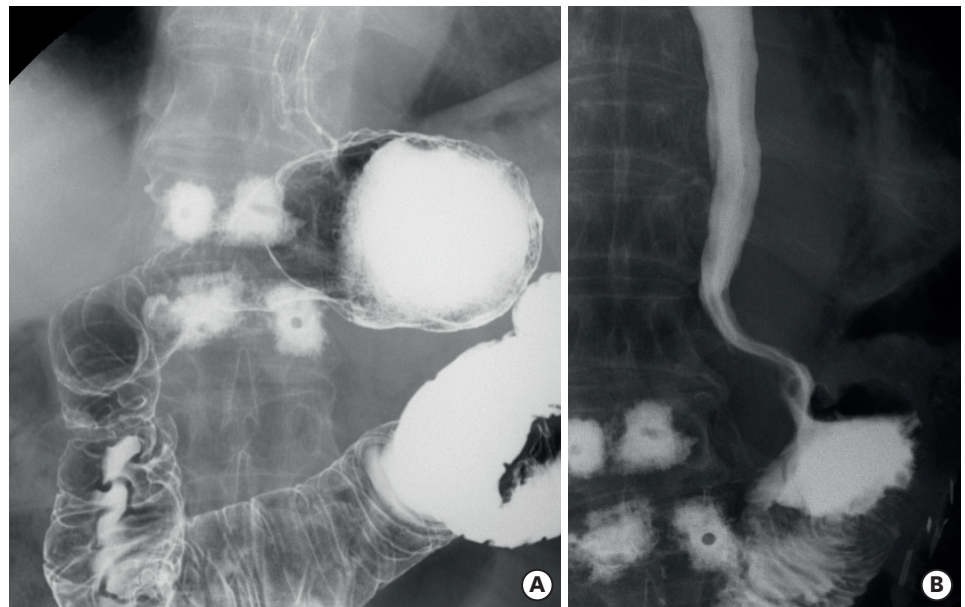
He underwent several tests for the evaluation of these symptoms.

Esophagogastroduodenoscopy revealed reflux esophagitis of Los Angeles classification grade B. There were mucosal breaks from the mid-esophagus to the gastroesophageal junction.

A type 1 sliding hiatal hernia was noted on the retroflexed view. There were no abnormal findings in the remnant stomach and anastomosis site (**Fig. 1**). Barium esophagogastrography did not demonstrate radiologic reflux, esophageal stricture, or stenosis but showed a normal passage after Billroth I reconstruction (**Fig. 2A**). On esophageal manometry, the pressure of

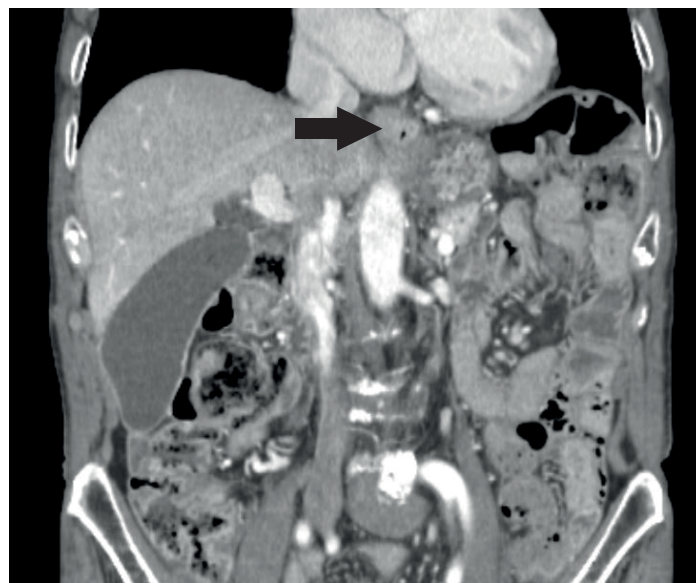

**Fig. 1.** Preoperative upper gastrointestinal endoscopy. Linear mucosal breaks longer than 5 mm in length are observed in the distal esophagus just proximal to the esophagogastric junction (A, B). Hiatal hernia on the retroflexed view (C) and gastroduodenal anastomosis (D).



**Fig. 2.** Preoperative barium swallow esophagogastrography (A) and postoperative gastrografin swallow esophagogastrography (B).

the lower esophageal sphincter was within normal limits (20 mmHg, normal limits: 10-45 mmHg), and esophageal motility was normal (100% of normal distal contractile integral). Ambulatory esophageal impedance pH monitoring test showed no evidence of significant pathologic acid reflux (0% of acid exposure time), but alkaline reflux was suspected because of a high symptom-reflux correlation (97.5% of symptom association probability for weakly alkaline reflux). An abdominal computed tomography scan revealed hiatal hernia of the proximal stomach (**Fig. 3**). However, there was no evidence of local tumor recurrence or metastasis. Following a multidisciplinary collaboration, we scheduled a laparoscopic Roux-en-Y conversion and repair of hiatal hernia for the treatment of DGER.



**Fig. 3.** An abdominal computed tomography scan shows the hiatal hernia of the proximal stomach (arrow).

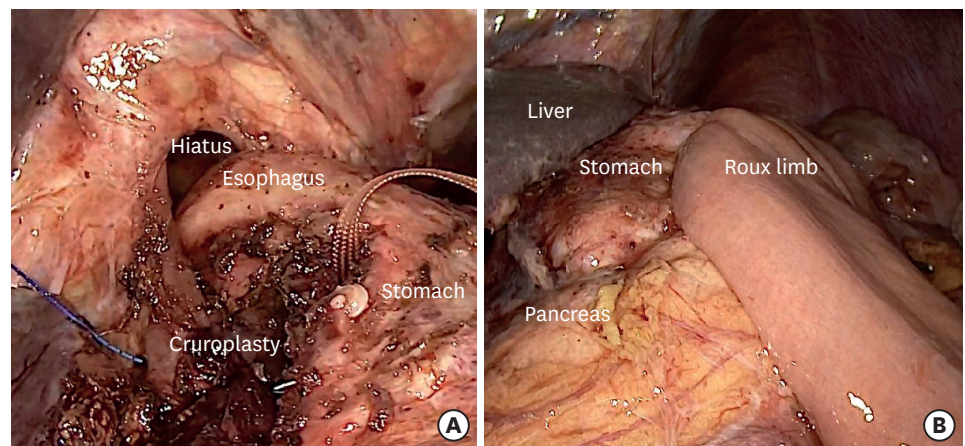
### Surgical technique

The patient was placed in the reverse Trendelenburg position. The first trocar (for the camera) was inserted transumbilically using the open technique. A 12-mm trocar (to provide access for the surgeon's right hand) and a 5-mm trocar (to provide access for the surgeon's left hand) were inserted on the right side. An additional 5-mm trocar was inserted on the left side for the assistant surgeon. The previous gastroduodenostomy site was dissected, and the duodenum, which was 1 cm distal to the anastomosis, was transected using a laparoscopic linear stapler (Endo-GIA™ with Tri-Staple™ Technology, 60 mm long and Tan cartridge; Medtronic, Mansfield, MA, USA). The remaining part of the stomach containing the gastroduodenal anastomosis was removed using another linear stapler (Endo-GIA™ with Tri-Staple™ Technology, 60 mm long and Purple cartridge; Medtronic). Subsequently, circumferential mobilization of the esophagus was performed with careful dissection using ultrasonic shears (Harmonic scalpel ACE™; Ethicon Endosurgery, Cincinnati, OH, USA) to obtain a length of at least 4 cm of the esophagus into the abdomen. We performed full dissection of the hiatal hernia sac from the mediastinum, with complete reduction of the sac contents into the abdomen. Short gastric vessels that are routinely divided during fundoplication in conventional laparoscopic anti-reflux surgery were preserved in this case. Hiatus defects were repaired with continuous sutures using a non-absorbable barbed suture thread (V-Loc™ PBT 2-0; Medtronic), anchored by clips (Lapra-ty™; Ethicon Endosurgery) and a pledget. Fundoplication was not performed.

As a final step, anastomosis was performed to complete the Roux-en-Y conversion. The jejunum was divided 20 cm distal to the ligament of Treitz, and gastrojejunostomy and jejunojejunostomy were performed intra-corporeally using linear staplers. The length of the Roux limb was 40 cm (**Fig. 4**).

### Postoperative course

The patient was allowed to drink a small amount of water immediately after the surgery, and a soft diet was introduced on postoperative day 2. PPI medication was stopped after surgery. The patient showed complete remission of heartburn, regurgitation, and other DGER-related symptoms. However, the patient complained of difficulty in swallowing solid food till postoperative day 20. Therefore, esophagogastrography was performed, which did not reveal any unusual findings such as esophagogastric passage disturbance, narrowing of esophagogastric junction, or recurrent hiatal hernia (**Fig. 2B**). Subsequently, the patient was relieved of this adverse symptom, and he was discharged on postoperative day 23.



**Fig. 4.** Operative findings of the hiatal hernia repair (A) and Roux-en-Y anastomosis (B).

## DISCUSSION

Multiple methods are available to reconstruct the gastrointestinal tract after distal gastrectomy. Typical reconstruction techniques include Billroth I, Billroth II, and Roux-en-Y [1,2]. Each reconstruction method has its own advantages and disadvantages [2]. Although Billroth I has advantages such as shorter operation time and fewer surgical complications than Roux-en-Y, it also has a major disadvantage of causing reflux symptoms [2,8,9]. The stronger anti-reflux capability of Roux-en-Y anastomosis has been demonstrated to contribute to a higher patient quality of life by reducing reflux-related gastritis and esophagitis [2,3,9].

DGER occurs when the bile refluxes into the gastric remnant and esophagus, and it may be accompanied by gastric acid reflux. Similar to general GERD, esophageal symptoms, such as heartburn and regurgitation, in addition to extraesophageal symptoms, such as globus sensation, coughing, and hoarseness, are common in patients with DGER [1,10]. Reflux symptoms can occur not only continuously after gastrectomy but also after more than 30 years [7]. In our case, the reflux symptoms appeared and worsened 14 years after the patient underwent Billroth I gastrectomy, which was likely related to the development of the hiatal hernia. The diagnosis is usually made by evaluation of the past surgical history and symptoms. Although there is no diagnostic gold standard test, several tests to evaluate bile reflux have been suggested such as endoscopy, ambulatory pH monitoring tests, esophageal impedance test, hepatobiliary scintigraphy, and gastroesophageal fluid analysis [11,12].

DGER is usually treated using medications such as PPIs, bile acid-binding agents, and/or kinetic agents [5]. However, the effectiveness of medical therapy for treating DGER has been shown to be inferior to that for treating typical GERD. Consequently, patients with symptoms refractory to medical treatment may need surgical treatment [12].

In sleeve gastrectomy, which is associated with the development of postoperative GERD, as in Billroth I surgery, conversion to Roux-en-Y gastric bypass has been shown to be effective in treating GERD [6]. However, reoperative surgery for GERD after distal gastrectomy for gastric cancer has been rarely reported [7]. The curative impact of surgical intervention in DGER after distal gastrectomy and Billroth I reconstruction remains unclear. Moreover, the surgical method that should be utilized remains uncertain. The surgical methods that can be used for GERD after distal gastrectomy include conversion to Roux-en-Y anastomosis, fundoplication, and hiatal hernia repair. Although laparoscopic fundoplication with crural repair is a very effective surgical procedure for the treatment of primary GERD, the most effective method among these three procedures is Roux-en-Y conversion, which can stop bile reflux definitively. Additionally, fundoplication and hiatal hernia repair can be considered as subsequent procedures that can be added depending on the situation.

Hu et al. [7] performed laparoscopic Dor fundoplication plus Roux-en-Y conversion in six patients who had undergone Billroth I or II reconstruction and had DGER refractory to medical treatment, and reported excellent symptomatic improvement in 5 out of 6 patients. This is the only report that described anti-reflux surgery after distal gastrectomy. However, they followed a different procedure from our surgery.

We performed laparoscopic Roux-en-Y conversion along with repair of hiatal hernia in our case. We did not perform fundoplication because the gastric remnant was not suitable for

fundoplication. Since the entire fundus remained after distal gastrectomy, it was thought that the size of the remnant stomach would be sufficient for fundoplication. However, in reality, a large part of the gastric body had been removed when distal gastrectomy was performed. As a result, the redundancy of the entire remnant stomach was notably reduced; hence, fundoplication seemed difficult to perform on the remnant stomach, although the size of fundus was the same as that in a normal stomach.

In addition, division of the short gastric vessels to mobilize the fundus was not available for the remnant stomach because the lesser curvature of the stomach had been already devascularized during primary distal gastrectomy.

If a case fulfills the indications for the Dor fundoplication without division of the short gastric vessels, it may be performed together with Roux-en-Y conversion. However, fundoplication alone does not solve the problem of duodenogastric reflux. Therefore, fundoplication does not seem to be an essential part of anti-reflux surgery for GERD after gastrectomy. Instead of fundoplication, sufficient lengthening of the intra-abdominal esophagus and repair of hiatal hernia were the important anti-reflux mechanisms in this case.

In our patient, the symptoms related to DGER were completely alleviated after surgery; therefore, medication for DGER was stopped. Our case study suggests Roux-en-Y conversion and hiatal hernia repair as promising options for the treatment of refractory DGER that develops after distal gastrectomy and Billroth reconstruction. However, as with anti-reflux surgery for primary GERD, not all patients will benefit from this type of surgery [13]. Therefore, it is very important to define surgical indications to select patients who can potentially benefit from this surgery.

To determine possible good candidates, based on the experience of anti-reflux surgery for patients with primary GERD, patients with typical esophageal symptoms seem to be more suitable for surgery than patients whose major symptoms include gastritis. Moreover, non-acid reflux should be objectively identified using an impedance pH monitoring test because acid is not a main component of the refluxate. In addition, the outcome of surgery is expected to be better for patients with hiatal hernia. However, determining the indications for this surgery will be possible only after further accumulation of experience regarding the treatment, such as this case report.

## REFERENCES

1. Guideline Committee of the Korean Gastric Cancer Association (KGCA), Development Working Group & Review Panel. Korean practice guideline for gastric cancer 2018: an evidence-based, multi-disciplinary approach. *J Gastric Cancer* 2019;19:1-48.  
[PUBMED](#) | [CROSSREF](#)
2. Yang K, Zhang WH, Liu K, Chen XZ, Zhou ZG, Hu JK. Comparison of quality of life between Billroth-I and Roux-en-Y anastomosis after distal gastrectomy for gastric cancer: a randomized controlled trial. *Sci Rep* 2017;7:11245.  
[PUBMED](#) | [CROSSREF](#)
3. Ma Y, Li F, Zhou X, Wang B, Lu S, Wang W, et al. Four reconstruction methods after laparoscopic distal gastrectomy: a systematic review and network meta-analysis. *Medicine (Baltimore)* 2019;98:e18381.  
[PUBMED](#) | [CROSSREF](#)
4. Information Committee of Korean Gastric Cancer Association. Korean Gastric Cancer Association nationwide survey on gastric cancer in 2014. *J Gastric Cancer* 2016;16:131-140.  
[PUBMED](#)

5. Gasiorowska A, Navarro-Rodriguez T, Wendel C, Krupinski E, Perry ZH, Koenig K, et al. Comparison of the degree of duodenogastroesophageal reflux and acid reflux between patients who failed to respond and those who were successfully treated with a proton pump inhibitor once daily. *Am J Gastroenterol* 2009;104:2005-2013.  
[PUBMED](#) | [CROSSREF](#)
6. Parmar CD, Mahawar KK, Boyle M, Schroeder N, Balupuri S, Small PK. Conversion of sleeve gastrectomy to Roux-en-Y gastric bypass is effective for gastro-oesophageal reflux disease but not for further weight loss. *Obes Surg* 2017;27:1651-1658.  
[PUBMED](#) | [CROSSREF](#)
7. Hu ZW, Wang ZG, Yan C, Tian SR, Deng CR, Wu JM. Laparoscopic Dorfundoplication plus Roux-en-Y diversion for intractable duodenogastroesophageal reflux after Billroth reconstruction. *Clin Surg* 2016;1:1015.
8. Fukuhara K, Osugi H, Takada N, Takemura M, Higashino M, Kinoshita H. Reconstructive procedure after distal gastrectomy for gastric cancer that best prevents duodenogastroesophageal reflux. *World J Surg* 2002;26:1452-1457.  
[PUBMED](#) | [CROSSREF](#)
9. Kim CH, Song KY, Park CH, Seo YJ, Park SM, Kim JJ. A comparison of outcomes of three reconstruction methods after laparoscopic distal gastrectomy. *J Gastric Cancer* 2015;15:46-52.  
[PUBMED](#) | [CROSSREF](#)
10. Pääkkönen M, Aukee S, Syrjänen K, Mäntyjärvi R. Gastritis, duodenogastric reflux and bacteriology of the gastric remnant in patients operated for peptic ulcer by Billroth I operation. *Ann Clin Res* 1985;17:32-36.  
[PUBMED](#)
11. Eldredge TA, Myers JC, Kiroff GK, Shenfine J. Detecting bile reflux-the enigma of bariatric surgery. *Obes Surg* 2018;28:559-566.  
[PUBMED](#) | [CROSSREF](#)
12. McCabe ME 4th, Dilly CK. New causes for the old problem of bile reflux gastritis. *Clin Gastroenterol Hepatol* 2018;16:1389-1392.  
[PUBMED](#) | [CROSSREF](#)
13. Park JM, Kim BJ, Kim JG, Chi KC. Factors predicting outcomes of laparoscopic Nissen fundoplication for gastroesophageal reflux disease: experience at a single institution in Korea. *Ann Surg Treat Res* 2017;92:184-190.  
[PUBMED](#) | [CROSSREF](#)