

Clinical Article



Comparison of Postoperative Surgical-Site Infection and Symptomatic Intracranial Hemorrhage between Staged and Simultaneous Cranioplasty with Ventriculoperitoneal Shunt Placement: A Meta-Analysis

Hoonkyo Jung , Kyoung Min Jang , Hyun Ho Choi, Taek Kyun Nam , Yong-Sook Park , and Jeong-Taik Kwon

Department of Neurosurgery, Chung-Ang University Hospital, Chung-Ang University College of Medicine, Seoul, Korea



Received: Feb 24, 2020

Revised: Apr 12, 2020

Accepted: Apr 17, 2020

Address for correspondence:

Kyoung Min Jang

Department of Neurosurgery, Chung-Ang University Hospital, Chung-Ang University College of Medicine, 102 Heukseok-ro, Dongjak-gu, Seoul 06973, Korea.
E-mail: eos2110@gmail.com

Copyright © 2020 Korean Neurotraumatology Society

This is an Open Access article distributed under the terms of the Creative Commons Attribution Non-Commercial License (<https://creativecommons.org/licenses/by-nc/4.0/>) which permits unrestricted non-commercial use, distribution, and reproduction in any medium, provided the original work is properly cited.

ORCID iDs

Hoonkyo Jung
<https://orcid.org/0000-0002-8678-7689>
Kyoung Min Jang
<https://orcid.org/0000-0002-0452-4595>
Taek Kyun Nam
<https://orcid.org/0000-0003-3151-631X>
Yong-Sook Park
<https://orcid.org/0000-0003-1152-6844>

Conflict of Interest

The authors have no financial conflicts of interest.

<https://kjnt.org>

ABSTRACT

Objective: Consensus about the sequence of cranioplasty and ventriculoperitoneal shunt placement to reduce postoperative complications has not been established. This meta-analysis investigated and collated further evidence to determine whether staged cranioplasty with ventriculoperitoneal shunt placement would significantly reduce the risk of postoperative surgical-site infection (SSI) and symptomatic intracranial hemorrhage.

Methods: Two independent reviewers identified articles and extracted the data of patients who underwent cranioplasty and ventriculoperitoneal shunt placement from PubMed, Embase, and Cochrane Central Register of Controlled Trials. A random effects model was used to compare the complication rates using odd ratios (ORs) and 95% confidence intervals (CIs). A meta-regression analysis for traumatic brain injury (TBI) was additionally performed.

Results: Data from 7 studies with 391 patients were consecutively included. The meta-analysis revealed that staged surgery was significantly associated with lower rates of SSI after decompressive craniectomy (staged group vs. simultaneous group: 6.2% vs. 23.7%, OR: 2.72, 95% CI: 1.46–5.06, $I^2=2.4%$, $p=0.407$). Pooled analysis did not indicate a statistically significant difference between the 2 groups for symptomatic intracranial hemorrhage (staged group vs. simultaneous group: 10.4% vs. 23.0%, OR: 1.66, 95% CI: 0.74–3.73, $I^2=0.0%$, $p=0.407$). The meta-regression analysis did not indicate any modifying effect of TBI on postoperative SSI development ($p=0.987$).

Conclusion: This meta-analysis indicated that staged surgery is significantly associated with a lower rate of postoperative SSI as compared with simultaneous surgery, but there is no difference in symptomatic intracranial hemorrhage. Additionally, there is no modifying effect of TBI on SSI.

Keywords: Cranioplasty; Ventriculoperitoneal shunt; Craniectomy; Infection; Intracranial hemorrhage

INTRODUCTION

Decompressive craniectomy is a life-saving surgical procedure to control intracranial pressure in refractory intracranial hypertension patients with various pathologies (e.g., traumatic brain injury [TBI], malignant infarction, subdural hemorrhage, intracerebral hemorrhage, and subarachnoid hemorrhage).^{2,6,7,18)} Cranioplasty and ventriculoperitoneal shunt placement are frequently performed in patients after decompressive craniectomy. Cranioplasty is performed for both protective and cosmetic purposes. Furthermore, neurologic amelioration after cranioplasty has been reported.⁴⁾ Some of these patients also have post-hemorrhagic hydrocephalus. Approximately 5%–15% of patients with decompressive craniectomy undergo ventriculoperitoneal shunt placement for hydrocephalus.^{5,7,14,15,19,22,26)}

Unexpected postoperative complications, such as surgical-site infection (SSI) and symptomatic intracranial hemorrhage, have been often reported after cranioplasty and ventriculoperitoneal shunt placement. Several studies have suggested that the staged or simultaneous approach of cranioplasty and ventriculoperitoneal shunt placement is associated with these postoperative complications.^{3,11,23)}

However, there is no established consensus about the sequence of these procedures to reduce complications. The purpose of this study was to compare the rates of complications, including SSI and symptomatic intracranial hemorrhage, between patients who underwent staged surgery and those who underwent simultaneous surgery.

MATERIALS AND METHODS

This systematic review was conducted according to the Preferred Reporting Items for Systematic Reviews and Meta-Analysis guidelines. The methods are presented in detail in **SUPPLEMENTARY TABLE 1**.

Data sources and search strategy

An electronic literature search of 3 online databases (PubMed, Embase, and Cochrane Central Register of Controlled Trials (CENTRAL), the United States National Institutes of Health registry of clinical trials) was performed. There was no limitation with regard to language or study date. Two different authors independently searched and screened full articles and reference lists. The search strategy according to the Population, Intervention, Comparison, and Outcome format is shown in **SUPPLEMENTARY TABLE 2**.

Study selection

The following inclusion criteria were considered to search appropriate articles for our study: 1) studies with prospective and retrospective designs; 2) studies enrolling participants who had undergone decompressive craniectomy with refractory intracranial hypertension; 3) studies including TBI and non-TBI (e.g., intracerebral hemorrhage or aneurysmal subarachnoid hemorrhage) as the diagnoses; 4) studies that involved simultaneous cranioplasty and ventriculoperitoneal shunt placement; 5) studies that involved staged cranioplasty and ventriculoperitoneal shunt placement; and 6) studies presenting postoperative SSI and symptomatic intracranial hemorrhage as the primary outcomes. The exclusion criteria were as follows: 1) studies that were reported in the format of editorial letters, conference abstracts, case series, and reports; 2) studies that included participants

who underwent 2 procedures of cranioplasty and ventriculoperitoneal shunt placement subsequently, with an interval of more than 6 months in case of staged surgery; 3) studies that included participants who underwent shunting operations, except ventriculoperitoneal shunt placement (e.g., lumbar-peritoneal shunt placement).

Data extraction and quality assessment

Data from selected studies identified independently by 2 investigators were included. A standardized form was utilized to extract study characteristics, study design, sample size, indications for decompressive craniectomy and ventriculoperitoneal shunt placement, timing for cranioplasty and ventriculoperitoneal shunt placement (whether staged or simultaneous), and postoperative complications. Complications were categorized into the following 2 groups: 1) postoperative SSI and 2) symptomatic intracranial hemorrhage. We excluded patients with pulmonary thromboembolism, deep-vein thrombosis, pneumonia, urinary tract infection, and sepsis in the complication group. Participants with infection requiring additional treatment after the surgery, such as antibiotic therapy, wound revision, and reoperation, were also considered to have SSI. The pathology of refractory intracranial hypertension was categorized and noted into the following 2 groups: 1) TBI and 2) non-TBI.

Quality assessment for eligible studies was performed by using the Newcastle–Ottawa Scale (NOS). The NOS assessed risk of bias in the following 3 aspects: 1) selection of study groups; 2) comparability of study groups; and 3) ascertainment of exposure and outcome. There were 4 numbered items in the selection domain and 3 numbered items in the exposure domain. Each item could be counted with one star when the study satisfied the condition. A maximum of 2 stars could be awarded in the comparability domain. A higher total score of the NOS indicates a higher study quality. A score higher than 7 was considered to indicate a low risk of bias. On the other hand, a score between 4 and 6 was considered to indicate a moderate risk of bias and a score lower than 4 was considered to indicate a high risk of bias. NOS scores were assessed by 2 independent authors.

Data synthesis and analysis

Data were statistically analyzed using Review Manager (RevMan version 5.3; The Cochrane Collaboration, Oxford, UK) and STATA/SE 15.0 (Stata Corp LP, College Station, TX, USA). The incidence rates of the postoperative complications, including SSI and symptomatic intracranial hemorrhage, were compared using the random effects model with the generic inverse variance method, and the findings were presented with odds ratios (ORs) and 95% confidence intervals (CIs). In order to homologate the results and validate the confounding effect, a meta-regression analysis for the proportion of TBI, which is known as the major pathology of patients who have undergone decompressive craniectomy, was additionally conducted.

Statistical heterogeneity was estimated with the I^2 statistic, which measures the degree of inconsistency across studies. We considered $I^2 < 25\%$, $< 50\%$, and $> 75\%$ to indicate low, moderate, and severe heterogeneity, respectively. The authors investigated publication bias through the visual asymmetry of a funnel plot and Egger's and Begg's tests. When visual asymmetry of the funnel plot was suspected, the trim-and-fill method was used to estimate an adjusted OR. A 2-sided p -value < 0.05 was considered to indicate statistical significance.

RESULTS

Search results

We conducted a systematic search and extracted citations from 3 online databases (1,032 from PubMed, 1,631 from Embase, and 0 from Cochrane Library). We excluded 658 duplicate articles. Among the remaining 2,005 articles, 28 were selected to undergo full text review on title and abstract review. Finally, 7 studies met all our eligibility criteria and were consecutively included in our study (**FIGURE 1**).

All 7 included studies had a low risk of bias according to the NOS. The NOS data assessing the risk of bias are documented in **SUPPLEMENTARY TABLE 3**.

Study characteristics

There were a total of 7 studies with 391 patients who underwent both cranioplasty and ventriculoperitoneal shunt placement after refractory intracranial hypertension. Among the total patients, 135 (34.5%) and 256 (65.5%) underwent simultaneous and staged surgeries, respectively. Of the 7 studies, 6 categorized the subgroups of TBI and non-TBI, whereas only 1 study omitted patient data regarding sex. There were 224 (5.2%) male and 130 (34.8%) female patients. The median age of the included patients ranged from 42.8 to 56.3 years in 6 studies. All these studies were designed as retrospective observational study and were conducted in a single center. Five of these studies reported the interval between cranioplasty and ventriculoperitoneal shunt placement in case of staged surgery, and it ranged from 24 hours to 6 months. The rates of autobody graft in cranioplasty were 82.3% (107/130) in 1 study,

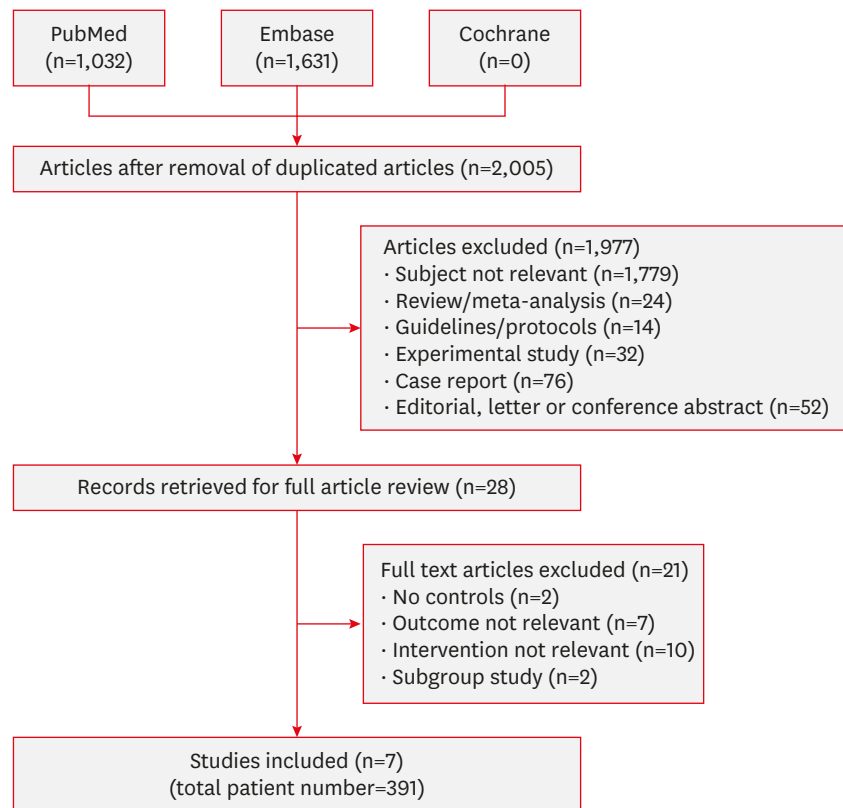


FIGURE 1. Flow diagram for the selection of relevant studies.

TABLE 1. Baseline characteristics of included studies

Study	Design	Study setting	Total	Age	Sex, male (%)	Trauma	Surgical strategy		Interval between CP & VPS	CP with autobone	Reported complications
							Simultaneous	Staged			
Yang et al. ²⁴⁾	RO	Single	130	54.0	91	62 (47.7)	21	109	NR	107 (82.3)	SSI
Heo et al. ⁸⁾	RO	Single	51	56.3	31	23 (45.1)	32	19	Within 6 months	51 (100)	SSI, post-operative hemorrhage, overall complications
Schuss et al. ¹⁷⁾	RO	Single	41	52.5	17	15 (36.6)	17	24	NR	NR	SSI, post-operative hemorrhage, overall complications
Jung et al. ⁹⁾	RO	Single	19	53.0	10	12 (63.2)	9	15	Within 3 days	19 (100)	SSI, post-operative hemorrhage, overall complications
von der Brelie et al. ²¹⁾	RO	Single	37	NR	NR	NR	10	27	Within 24 hours	NR	SSI, overall complications
Yang et al. ²⁵⁾	RO	Single	58	42.8	46	46 (79.3)	20	38	Within 72 hours	58 (100)	SSI, post-operative hemorrhage, overall complications
Meyer et al. ¹³⁾	RO	Single	50	43.0	29	19 (38)	26	24	Within 48 hours	50 (100)	SSI, overall complications

Values are presented as number (%).

CP: cranioplasty, NR: not reported, RO: retrospective observational, SSI: surgical site infection, VPS: ventriculoperitoneal shunt.

100% (178/178) in 4 studies, and not reported in 2 studies. SSI was reported in all included studies. Postoperative symptomatic intracranial hemorrhage and overall complications were investigated in 4 and 6 studies, respectively. The baseline characteristics of the 7 individual studies are summarized in **TABLE 1**.

SSI after cranioplasty and ventriculoperitoneal shunt placement

A total of 48 patients with SSI were reported in the included studies. The observed rates of SSI in the pooled analysis were 23.7% (32/135) in the simultaneous group and 6.2% (16/256) in the staged group. For integrating the 7 included studies, the pooled analysis using a random effects model revealed that the simultaneous group was significantly associated with a higher incidence of SSI as compared with the staged group (pooled OR: 2.72, 95% CI: 1.446–5.06, $p=0.407$) with low heterogeneity ($I^2=2.4%$; **FIGURE 2**). Although visual asymmetry was observed in the funnel plot for SSI, the adjusted OR showed no significant differences as compared with the pooled OR owing to the trim-and-fill correction (adjusted OR: 2.93, 95% CI: 1.21–7.09, $p=0.112$) (**SUPPLEMENTARY FIGURE 1A**).

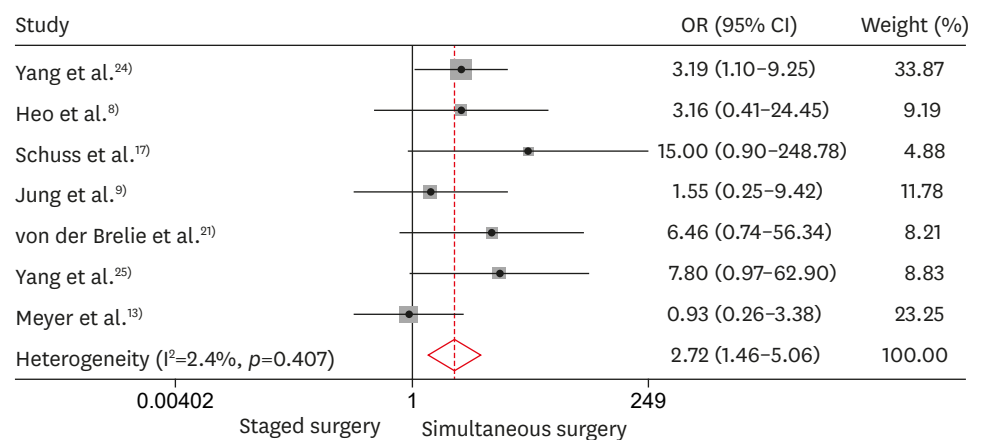


FIGURE 2. Comparison of postoperative surgical-site infection between staged and simultaneous surgeries involving cranioplasty and ventriculoperitoneal shunt placement. OR: odds ratio, CI: confidence interval.

Symptomatic intracranial hemorrhage after cranioplasty and ventriculoperitoneal shunt placement

In 4 studies, 28 patients had symptomatic intracranial hemorrhage postoperatively. The rates of symptomatic intracranial hemorrhage were 23.0% (18/78) in the simultaneous group and 10.4% (10/98) in the staged group. Pooled analysis did not indicate any statistically significant differences between the 2 different surgical methods for symptomatic intracranial hemorrhage (pooled OR: 1.66, 95% CI: 0.74–3.73, $p=0.407$) with low heterogeneity ($I^2=0.0\%$; **FIGURE 3**), although there was a trend toward favoring staged surgery to lower the symptomatic intracranial hemorrhage between the 2 groups. Funnel plots revealed that there was no publication bias for symptomatic intracranial hemorrhage, which was supported by the Egger's and Begg's tests ($p=0.497$ and $p=0.333$, respectively) (**SUPPLEMENTARY FIGURE 1B**).

Meta-regression analysis with TBI proportions for SSI

The subcategorized TBI group was compared with the non-TBI group to reveal the confounding effect of TBI on postoperative SSI. A meta-regression analysis was conducted to confirm this effect. However, there was no significant difference in the modifying effect of TBI on SSI ($p=0.987$) (**FIGURE 4**).

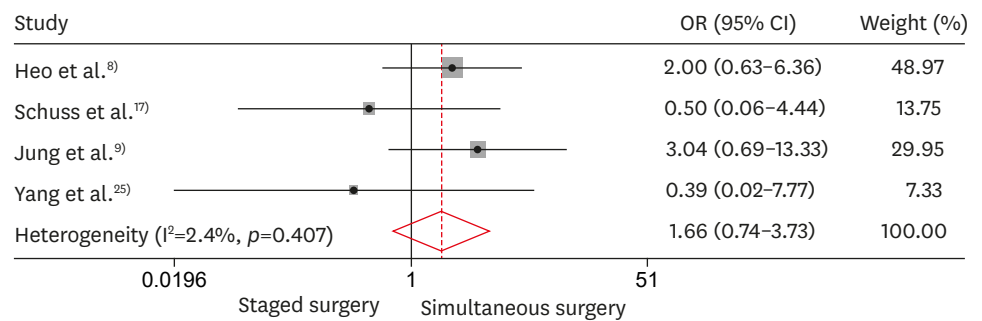


FIGURE 3. Comparison of postoperative symptomatic intracranial hemorrhage between staged and simultaneous surgeries involving cranioplasty and ventriculoperitoneal shunt placement. OR: odds ratio, CI: confidence interval.

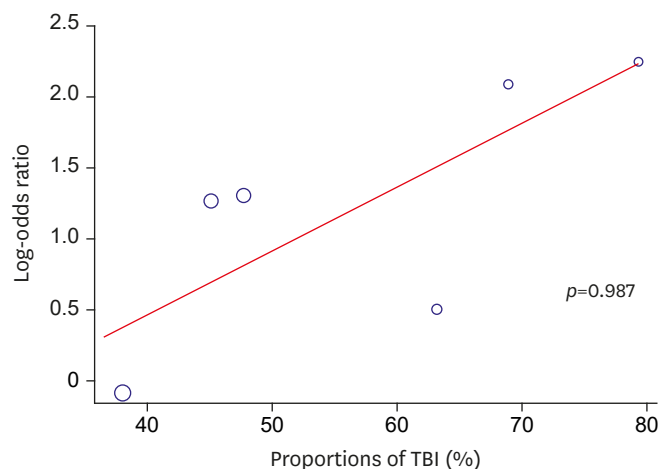


FIGURE 4. Meta-regression analysis for the proportions of TBI regarding postoperative surgical-site infection. TBI: traumatic brain injury.

DISCUSSION

In the process of treating patients with refractory intracranial hypertension who have undergone decompressive craniectomy, usually cranioplasty and ventriculoperitoneal shunt placement are performed in the last stage of treatment after all acute phases of management. For neurosurgeons, there is always a worrisome concern about the sequence of these 2 procedures, because unexpected complications can lengthen hospitalization and aggravate the patient's neurological status.⁹⁾ However, practice relies on the surgeon's individual preference and policy owing to the lack of evidence regarding this concern. To the best of our knowledge, no systematic review has been conducted to reveal the relationship between the sequence of cranioplasty and ventriculoperitoneal shunt placement and the incidences of postoperative SSI and symptomatic intracranial hemorrhage. In the present study, we carefully assumed that simultaneous cranioplasty and ventriculoperitoneal shunt placement is associated with an increased risk of SSI as compared with staged surgery. There was a trend indicating that the simultaneous group had a higher rate of symptomatic intracranial hemorrhage as compared with the staged group, but no statistically significant difference was confirmed. Considering these results, it may be suggested that staged surgery is recommended over simultaneous surgery for preventing postoperative SSI.

In the present study, the pooled incidence rate of SSI was 12.2% (48/391). This rate is comparable to the rates in other articles, which ranged from 4.5% to 18.4%, with cranioplasty and ventriculoperitoneal shunt placement.^{1,10)} From pathophysiologic perspectives, the mechanism of postoperative SSI is likely related with obliteration of the dead space at the surgical site. Rodriguez et al.¹⁶⁾ presented 7 patients with frontal sinus infection after frontal sinus injury. The authors proposed several surgical methods to control infection. Of note, they mentioned the importance of obliteration of dead space in the frontal sinus for the prevention of SSI. Additionally, Masuda et al.¹²⁾ reported in a case series that elimination of dead space with bone cement in postoperative SSI patients after spinal surgery had better therapeutic outcomes as compared with conventional treatment. In accordance with the above mechanisms, we could assume that simultaneous surgery of cranioplasty and ventriculoperitoneal shunt placement induces cerebrospinal fluid overdrainage and a more depressed brain as compared with the staged surgery, which leads to a persistent postoperative dead space at the surgical site.

In addition, Meyer et al.¹³⁾ compared the 2 groups of concomitant and staged surgeries involving cranioplasty and ventriculoperitoneal shunt placement by retrospectively reviewing 50 patients and reported that the incidence rate of SSI was higher in the concomitant group. The authors highlighted the difficulty in performing sterile draping techniques in simultaneous surgery with separate operation sites. Additionally, Schuss et al.¹⁷⁾ reported that candidates for simultaneous surgery tend to have a poorer systemic condition and neurologic status as compared with candidates for staged surgery, which can be factors for a higher SSI incidence.¹⁷⁾ These reports are in line with our results indicating that simultaneous surgery is associated with a higher incidence rate of SSI as compared with staged surgery.

Simultaneous surgery involving cranioplasty and ventriculoperitoneal shunt placement has been reported to be related to a higher incidence rate of symptomatic intracranial hemorrhage than the staged surgery group.⁸⁾ Heo et al.⁸⁾ retrospectively reviewed 50 patients who had undergone cranioplasty and ventriculoperitoneal shunt placement. Data for the surgical method, cranial defect size, and hydrocephalus were analyzed. The study revealed

that patients who underwent surgery with the simultaneous approach had higher rates of symptomatic intracranial hemorrhage than the staged group. The authors suggested the mechanism for this result through the difficulty of adjusting shunt pressure postoperatively, which would have caused subdural fluid collection and subdural hematoma. Moreover, Jung et al.⁹⁾ reported similar results and showed that patients who underwent simultaneous surgery had higher complication rates as compared with patients who underwent staged surgery. Of note, the authors suggested that temporarily blocking the shunt catheter after surgery could reduce the complication rate. For this result, the authors interpreted that the sunken down effect of the brain caused intracranial hemorrhage and subdural hemorrhage. From our meta-analysis, although there was no statistically significant difference between the simultaneous and staged groups regarding the occurrence rate of symptomatic intracranial hemorrhage, a trend of a higher incidence of symptomatic intracranial hemorrhage could be observed in the simultaneous group, and it could be explained by these previous reported mechanisms.

TBI has been investigated as a significant risk factor for postoperative complications in patients who have undergone intracranial surgery.²³⁾ Thus, we estimated that TBI could be a confounding factor to investigate the association between surgical methods and postoperative SSI. However, our analysis revealed that there was no significant confounding effect between these 2 variables. Walcott et al.²²⁾ conducted a study and analyzed the complication rate of cranioplasty between a trauma group and stroke group, which revealed that TBI was not a confounding factor for SSI, and this is in line with the present report.

There are some limitations in this meta-analysis. First, our results are not based on a relatively high level of evidence with the included studies. All of the 7 included studies were retrospective observational studies and were conducted in a single center. We performed a precise search strategy to include studies with a high level of evidence (e.g., prospective, randomized, controlled trials and multicenter studies), and we did not find adequate articles satisfying these conditions. We conducted quality assessments for all our included studies using the NOS. All 7 retrospective studies were considered to have low-to-moderate risk of bias. Thus, the results based on our analysis should be interpreted with caution. Furthermore, there is some heterogeneity regarding the study protocol among the included studies. The interval between cranioplasty and ventriculoperitoneal shunt placement in case of staged surgery ranged from 24 hours to 6 months.^{8,9,13,21,25)} The rate of autobody graft in cranioplasty was reported in 5 studies^{8,9,13,24,25)} and not reported in 2 studies. These 2 heterogeneities between the included studies could be confounding factors for complications.^{3,20)} Thus, a further study or analysis with a consistent protocol is necessary to clarify the effects of these possible confounding factors on SSI and symptomatic intracranial hemorrhage. A prospective study design and double-blinded, randomized, controlled trial with firm inclusion criteria would help reduce the confounding effect.

CONCLUSION

Staged surgery involving cranioplasty and ventriculoperitoneal shunt placement is greatly associated with a lower rate of postoperative SSI as compared with simultaneous surgery, but there is no difference in symptomatic intracranial hemorrhage. In addition, there is no modifying effect of TBI on SSI.

SUPPLEMENTARY MATERIALS

SUPPLEMENTARY TABLE 1

Checklist of items to include when reporting a systematic review or meta-analysis (PRISMA guideline)

[Click here to view](#)

SUPPLEMENTARY TABLE 2

Search strategy in accordance with the PICO format

[Click here to view](#)

SUPPLEMENTARY TABLE 3

Risk of bias assessment using Newcastle–Ottawa Scale

[Click here to view](#)

SUPPLEMENTARY FIGURE 1

Funnel plots for evaluating publication bias. Funnel plot revealed that there was no evidence for publication bias of across the direct comparisons between staged and simultaneous surgery in patients underwent cranioplasty and ventriculoperitoneal shunt for (A) surgical-site infection and (B) symptomatic intracranial hemorrhage.

[Click here to view](#)

SUPPLEMENTARY REFERENCES

[Click here to view](#)

REFERENCES

1. Archavlis E, Carvi Y, Nievas M. The impact of timing of cranioplasty in patients with large cranial defects after decompressive hemicraniectomy. *Acta Neurochir (Wien)* **154**:1055-1062, 2012
[PUBMED](#) | [CROSSREF](#)
2. Bullock MR, Chesnut R, Ghajar J, Gordon D, Hartl R, Newell DW, et al. Surgical management of acute subdural hematomas. *Neurosurgery* **58**:S16-24, 2006
[PUBMED](#)
3. Chang V, Hartzfeld P, Langlois M, Mahmood A, Seyfried D. Outcomes of cranial repair after craniectomy. *J Neurosurg* **112**:1120-1124, 2010
[PUBMED](#) | [CROSSREF](#)
4. Dujovny M, Aviles A, Agner C, Fernandez P, Charbel FT. Cranioplasty: cosmetic or therapeutic? *Surg Neurol* **47**:238-241, 1997
[PUBMED](#) | [CROSSREF](#)
5. Gooch MR, Gin GE, Kenning TJ, German JW. Complications of cranioplasty following decompressive craniectomy: analysis of 62 cases. *Neurosurg Focus* **26**:E9, 2009
[PUBMED](#) | [CROSSREF](#)
6. Güresir E, Raabe A, Setzer M, Vatter H, Gerlach R, Seifert V, et al. Decompressive hemicraniectomy in subarachnoid haemorrhage: the influence of infarction, haemorrhage and brain swelling. *J Neurol Neurosurg Psychiatry* **80**:799-801, 2009
[PUBMED](#) | [CROSSREF](#)

7. Güresir E, Schuss P, Vatter H, Raabe A, Seifert V, Beck J. Decompressive craniectomy in subarachnoid hemorrhage. *Neurosurg Focus* 26:E4, 2009
[PUBMED](#) | [CROSSREF](#)
8. Heo J, Park SQ, Cho SJ, Chang JC, Park HK. Evaluation of simultaneous cranioplasty and ventriculoperitoneal shunt procedures. *J Neurosurg* 121:313-318, 2014
[PUBMED](#) | [CROSSREF](#)
9. Jung YT, Lee SP, Cho JI. An improved one-stage operation of cranioplasty and ventriculoperitoneal shunt in patient with hydrocephalus and large cranial defect. *Korean J Neurotrauma* 11:93-99, 2015
[PUBMED](#) | [CROSSREF](#)
10. Klinger DR, Madden C, Beshay J, White J, Gambrell K, Rickert K. Autologous and acrylic cranioplasty: a review of 10 years and 258 cases. *World Neurosurg* 82:e525-e530, 2014
[PUBMED](#) | [CROSSREF](#)
11. Malcolm JG, Rindler RS, Chu JK, Grossberg JA, Pradilla G, Ahmad FU. Complications following cranioplasty and relationship to timing: a systematic review and meta-analysis. *J Clin Neurosci* 33:39-51, 2016
[PUBMED](#) | [CROSSREF](#)
12. Masuda S, Fujibayashi S, Otsuki B, Kimura H, Matsuda S. Efficacy of target drug delivery and dead space reduction using antibiotic-loaded bone cement for the treatment of complex spinal infection. *Clin Spine Surg* 30:E1246-E1250, 2017
[PUBMED](#) | [CROSSREF](#)
13. Meyer RM 4th, Morton RP, Abecassis JJ, Barber JK, Emerson SN, Nerva JD, et al. Risk of complications with simultaneous cranioplasty and placement of ventriculoperitoneal shunt. *World Neurosurg* 107:830-833, 2017
[PUBMED](#) | [CROSSREF](#)
14. Morton RP, Abecassis JJ, Hanson JF, Barber J, Nerva JD, Emerson SN, et al. Predictors of infection after 754 cranioplasty operations and the value of intraoperative cultures for cryopreserved bone flaps. *J Neurosurg* 125:766-770, 2016
[PUBMED](#) | [CROSSREF](#)
15. Quigley M. Risk of shunt-dependent hydrocephalus after occlusion of ruptured intracranial aneurysms by surgical clipping or endovascular coiling: a single-institution series and meta-analysis. *Neurosurgery* 63:E1209, 2008
[PUBMED](#) | [CROSSREF](#)
16. Rodriguez ED, Stanwix MG, Nam AJ, St Hilaire H, Simmons OP, Manson PN. Definitive treatment of persistent frontal sinus infections: elimination of dead space and sinonasal communication. *Plast Reconstr Surg* 123:957-967, 2009
[PUBMED](#) | [CROSSREF](#)
17. Schuss P, Borger V, Güresir Á, Vatter H, Güresir E. Cranioplasty and ventriculoperitoneal shunt placement after decompressive craniectomy: staged surgery is associated with fewer postoperative complications. *World Neurosurg* 84:1051-1054, 2015
[PUBMED](#) | [CROSSREF](#)
18. Schwab S, Steiner T, Aschoff A, Schwarz S, Steiner HH, Jansen O, et al. Early hemicraniectomy in patients with complete middle cerebral artery infarction. *Stroke* 29:1888-1893, 1998
[PUBMED](#) | [CROSSREF](#)
19. Sobani ZA, Shamim MS, Zafar SN, Qadeer M, Bilal N, Murtaza SG, et al. Cranioplasty after decompressive craniectomy: an institutional audit and analysis of factors related to complications. *Surg Neurol Int* 2:123, 2011
[PUBMED](#) | [CROSSREF](#)
20. Sundseth J, Sundseth A, Berg-Johnsen J, Sorteberg W, Lindegaard KF. Cranioplasty with autologous cryopreserved bone after decompressive craniectomy: complications and risk factors for developing surgical site infection. *Acta Neurochir (Wien)* 156:805-811, 2014
[PUBMED](#) | [CROSSREF](#)
21. von der Brélie C, Stojanovski I, Meier U, Lemcke J. Open traumatic brain injury is a strong predictor for aseptic bone necrosis after cranioplasty surgery: a retrospective analysis of 219 patients. *J Neurol Surg A Cent Eur Neurosurg* 77:19-24, 2016
[PUBMED](#)
22. Walcott BP, Kwon CS, Sheth SA, Fehnel CR, Koffie RM, Asaad WF, et al. Predictors of cranioplasty complications in stroke and trauma patients. *J Neurosurg* 118:757-762, 2013
[PUBMED](#) | [CROSSREF](#)
23. Yadla S, Campbell PG, Chitale R, Maltenfort MG, Jabbour P, Sharan AD. Effect of early surgery, material, and method of flap preservation on cranioplasty infections: a systematic review. *Neurosurgery* 68:1124-1129, 2011
[PUBMED](#) | [CROSSREF](#)

24. Yang SM, Park HK, Cho SJ, Chang JC, Park SQ, Kim RS. The current analysis of the risk factors for bone graft infection after cranioplasty. *Korean J Neurotrauma* 9:57, 2013
[CROSSREF](#)
25. Yang XF, Wang H, Wen L, Huang X, Li G, Gong JB. The safety of simultaneous cranioplasty and shunt implantation. *Brain Inj* 31:1651-1655, 2017
[PUBMED](#) | [CROSSREF](#)
26. Zanaty M, Chalouhi N, Starke RM, Clark SW, Bovenzi CD, Saigh M, et al. Complications following cranioplasty: incidence and predictors in 348 cases. *J Neurosurg* 123:182-188, 2015
[PUBMED](#) | [CROSSREF](#)