

# Truncal acne following JAK inhibitor use in vitiligo with rare opportunistic fungal infections: Two case reports



Jee Yun Doh, MD,<sup>a</sup> Piyapat Rintarhat, BS,<sup>b</sup> Won Hee Jung, PhD,<sup>b</sup> and Hei Sung Kim, MD, PhD<sup>c</sup>

**Key words:** acne; JAK inhibitor; Janus kinase; microbiome; *Rhodotorula*; skin; *Tintelnotia*.

## INTRODUCTION

Janus kinase (JAK) is a tyrosine kinase comprised of Janus kinase 1 (JAK1), Janus kinase 2, Janus kinase 3, and tyrosine kinase 2. JAK and signal transducer and activator of transcription signaling pathways play a pivotal role in regulating intracellular gene expression through various inflammatory cytokines. Inflammatory cytokines include interferons, interleukins, and multiple other growth factors. Dysregulation of JAK-signal transducer and activator of transcription signaling contributes to various inflammatory disorders, and JAK inhibitors (JAKi) are now considered a promising new treatment modality for multiple skin disorders, including atopic dermatitis (AD), psoriasis, psoriatic arthritis, alopecia areata, and vitiligo.<sup>1,2</sup> However, there are potential safety concerns regarding the use of JAKi. JAKi are most commonly associated with nausea, diarrhea, nasopharyngitis, acne, and elevated serum creatinine phosphokinase level. Acne is the most frequently reported cutaneous adverse events (AEs) associated with JAKi.<sup>1,3-5</sup> The exact etiology and pathophysiology of JAKi-induced acne remain unclear. Herein, we report 2 cases of JAKi-induced truncal acne in vitiligo patients with superimposed rare fungal infections.

### Abbreviations used:

AD: atopic dermatitis  
 AE: adverse event  
 JAK: Janus kinase  
 JAK1: Janus kinase 1  
 JAKi: JAK inhibitor

## CASE REPORT

### Case 1

A 63-year-old man with no prior medical history presented with a 1-year history of vitiligo (Table I, Fig 1). He denied any other prior history of acne, pityrosporum folliculitis, or pityriasis versicolor. The patient had been treated with topical tacrolimus 0.1% ointment and narrow band UV-B photochemotherapy without marked improvement. Given the recent evidence supporting the efficacy of JAKi in vitiligo, the patient was started with oral baricitinib (JAK-1/2 selective inhibitor; Olumiant, Eli Lilly) at a dose of 4 mg/day. After 6 weeks of treatment, the patient developed acneiform eruption on the neck and upper chest. There were no significant laboratory findings. Microbiological culture with skin swabbing showed colonies with a salmon-pink to coral-red color. Subsequently,

From the Department of Dermatology, Seoul St. Mary's Hospital, The Catholic University of Korea, Seoul, Republic of Korea<sup>a</sup>; Department of Systems Biotechnology, Chung-Ang University, Anseong, Republic of Korea<sup>b</sup>; and Department of Dermatology, Incheon St. Mary's Hospital, The Catholic University of Korea, Seoul, Republic of Korea.<sup>c</sup>

Funding sources: This work was supported by the Ministry of Education of the Republic of Korea and the National Research Foundation of Korea (NRF-2023R1A2C1007759) and a grant from the National Research Foundation of Korea (NRF-2021M3A9I4021431) funded by the Ministry of Science, ICT, and Future Planning.

IRB approval status: Reviewed and approved by the IRB of the Catholic University of Korea.

Patient consent: Consent for the publication of all patient photographs and medical information was provided by the authors at the time of article submission to the journal, stating that all patients gave consent for their photographs and

medical information to be published in print and online and with the understanding that this information may be publicly available.

Data sharing statement: The data supporting this study's findings are available upon reasonable request from the corresponding author.

Correspondence to: Hei Sung Kim, MD, PhD, Department of Dermatology, Incheon St. Mary's Hospital, The Catholic University of Korea, 222 Banpo-aero, Seocho-gu, Seoul, 06591, Republic of Korea. E-mail: [hazelkimhoho@gmail.com](mailto:hazelkimhoho@gmail.com).

JAAD Case Reports 2023;37:123-7.

2352-5126

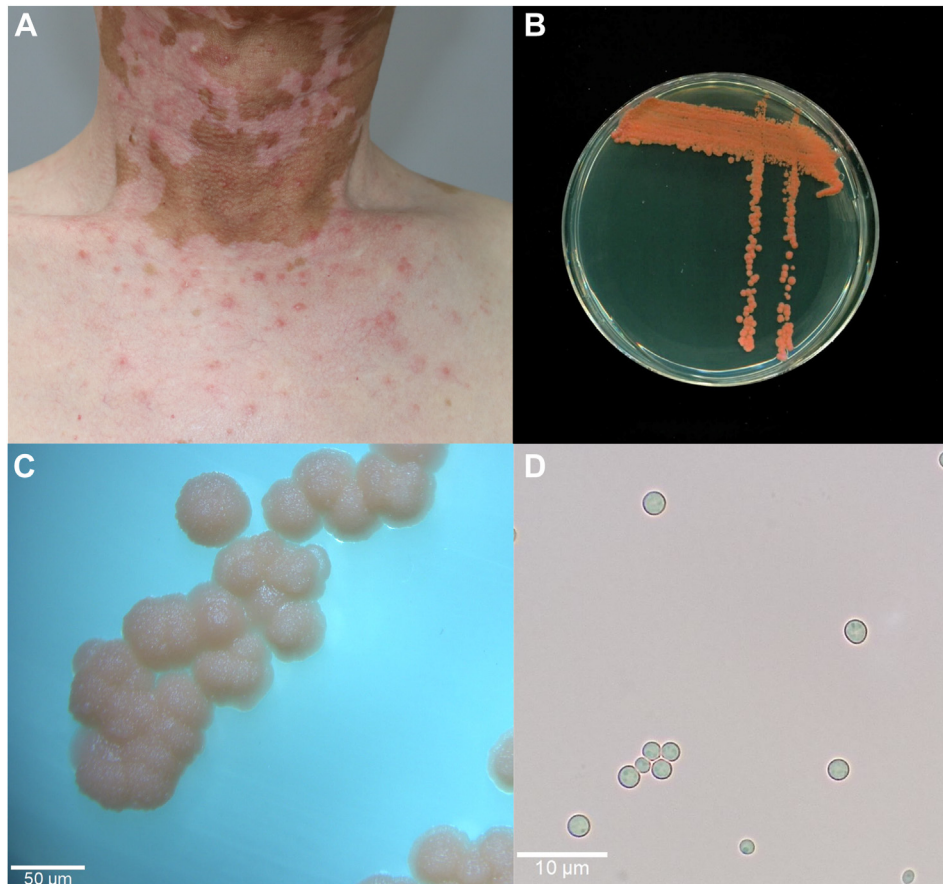
© 2023 by the American Academy of Dermatology, Inc. Published by Elsevier, Inc. This is an open access article under the CC BY-NC-ND license (<http://creativecommons.org/licenses/by-nc-nd/4.0/>).

<https://doi.org/10.1016/j.jidcr.2023.05.018>

**Table I.** Demographic information of patients

No.	JAK inhibitor (dose)	Sex/age (years)	Underlying disease	Disease duration	Distribution	VASI score	Time to onset of acne (weeks)	Site	History of previous treatment
Case 1	Baricitnib (4 mg)	M/63	Vitiligo	2 y	Face, neck, trunk, both hands, and feet	21.5	6	Neck, upper chest	NB-UVB, TCI
Case 2	Baricitnib (4 mg)	M/65	Vitiligo	2 y	Forehead, neck, upper trunk, both arms, and hands	8.02	18	Upper chest	NB-UVB, TCI

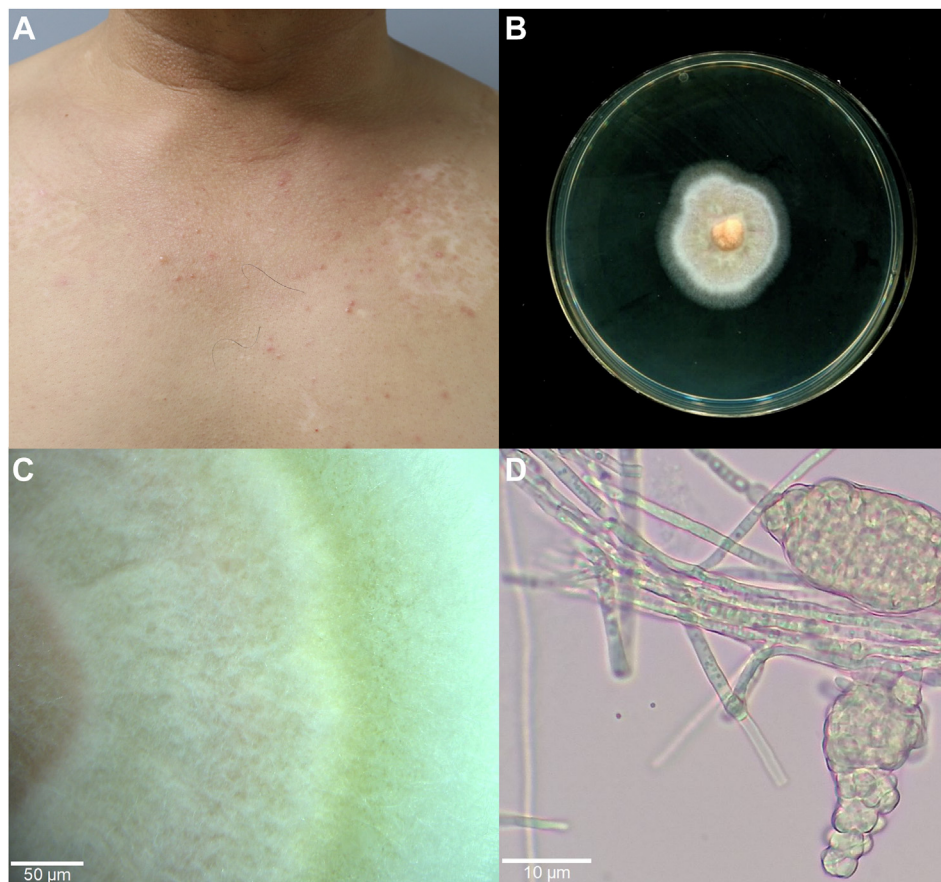
JAK, Janus kinase; M, male; NB-UVB, narrow band UV-B; TCI, topical calcineurin inhibitor; VASI, vitiligo area scoring index.



**Fig 1.** Case 1: (A) erythematous papules and pustules centered on follicles involving the *upper chest* and neck. (B) Growth of salmon *Rhodotorula mucilaginosa* (*R. mucilaginosa*) on Sabouraud agar after 7 days at 30 °C. Sabouraud dextrose agar was prepared by adding 30 g of Sabouraud dextrose broth (MB cell) and 15 g of agar (Biopure) in 1 L of distilled water and adjusted pH to 7.0 using HCl (Sigma). The medium was sterilized by autoclaving for 20 minutes at 121 °C. Gentamicin (0.1 g/L) (Santa Cruz Biotechnology) and chloramphenicol (0.05 g/L) (GOLD Biotechnology) were added. (C) The colonies of *R. mucilaginosa* (×50). (D) Microscopic image of yeast cells of *R. mucilaginosa* (×400).

polymerase chain reaction and DNA sequencing of the fungal colony confirmed the diagnosis of *Rhodotorula mucilaginosa* (*R. mucilaginosa*) (Supplementary Table I, available via Mendeley at

<https://doi.org/10.17632/9bp2dzvbp1>). The patient was treated with topical ketoconazole solution without additional systemic antifungal agents, and skin lesions improved significantly after



**Fig 2.** Case 2: **(A)** erythematous papules and pustules on the *upper chest* and neck. **B,** Growth of *Tintelnotia destructans* (*T. destructans*) on Sabouraud agar after 7 days at 30 °C. **C,** The colonies of *T. destructans* (×50). **D,** Microscopic image of pycnidia of *T. destructans* (×400).

1 month. The patient tolerated baricitinib without further AEs.

### Case 2

A 65-year-old male presented with vitiligo affecting the face and both hands for 2 years (Fig 2). The patient also had hypertension and dyslipidemia. Previous treatments included topical tacrolimus 0.1% ointment and narrow band UV-B therapy without significant improvement. Baricitinib at a 4 mg/d dose was commenced to improve repigmentation. After 18 weeks of treatment, the patient developed pruritic, erythematous papules and pustules on the upper chest. Laboratory findings were unremarkable. *Tintelnotia destructans* (*T. destructans*) were isolated in microbiological culture, which were confirmed by polymerase chain reaction and DNA sequencing (Supplementary Table I, available via Mendeley at xxx). The lesions resolved with topical ketoconazole solution.

Baricitinib was well tolerated with no further AEs since then.

### DISCUSSION

Both patients developed truncal acne after treatment with baricitinib for vitiligo. *R. mucilaginosa* and *T. destructans* were cultured in each patient. After treatment with topical ketoconazole, lesions of both patients were successfully treated without discontinuing baricitinib treatment. Although acne is the most common cutaneous AEs associated with JAKi, its exact etiology and pathophysiology is yet to be widely studied. JAKi-induced acne was first noticed in clinical trials of patients with AD and has been studied almost exclusively in patients with AD. JAKi-induced acne showed a dose-dependent relationship. Also, upadacitinib (JAK1-selective inhibitor; ABT-494, Rinvoq, Abbvie) was more commonly associated with acne than abrocitinib (JAK1-selective inhibitor; PF-04965842, Pfizer) and baricitinib.<sup>1</sup> In Measure Up 1/2 trials, acne occurred in

up to 13% of the cases being treated with upadacitinib 15 mg, up to 17% of the cases treated with upadacitinib 30 mg.<sup>3</sup> Daily dosage of 100 mg and 200 mg of abrocitinib in patients with AD resulted 2.9% and 6.6% incidence rates of acne respectively.<sup>4</sup> In whole BREEZE-AD, 2.9% of patients on baricitinib 4 mg developed acne.<sup>5</sup> The severity of acne was relatively mild and mainly stayed well controlled with topical treatment. The face was the most commonly affected site, while approximately one-third of the cases also reported truncal acne.<sup>1,2,4</sup>

Acne is usually developed from abnormal follicular epidermal hyperproliferation, increased sebum production, proliferation of *Cutibacterium acnes* (*C. acnes*), inflammation, and immune responses. JAKi may lead to hyperkeratinization of follicles by modulating the epidermal growth factor receptors.<sup>2</sup> Also, inhibition of JAK1 receptors induces Th1 deviation of the immune response, which leads to the change of microbial colonization of the skin.<sup>2</sup>

Recent studies suggest that the composition and activity of the skin microbiome might be related to acne development. *C. acnes* and *Staphylococcus epidermidis*, and *Malassezia* were more prevalent in acne patients. Also, not only the overgrowth itself but specific strains and balance among the metagenomics elements seem to play a crucial role.<sup>6,7</sup> The microbiome of vitiligo patients is still sparsely studied. However, several studies demonstrate the presence of dysbiosis along with local immune dysregulation in vitiligo patients. In the lesional skin of vitiligo, opportunistic pathogens, including *Mycoplasma*, *Streptococcus*, and *Proteobacteria*, were enriched, while the abundance and distribution of the microbiome were reduced.<sup>8,9</sup>

Although there are no data investigating the exact role of microbiota in those diseases, dysbiosis triggered by JAKi could contribute to the development of acne as skin microbes stabilize the host's barrier by fighting off pathogenesis, interacting with immune cells in the skin, and modifying host immunity.<sup>6</sup>

*Malassezia* is the most dominant fungal microbiome in the skin, accounting for up to 80% of the total skin fungal population. However, fungi other than *Malassezia*, including *Candida* and *Rhodotorula*, are also common commensal fungal species, accounting for more than 1% of the population.<sup>10</sup> The clinical significance of *Rhodotorula* ranges from superficial infections in immunocompetent hosts to invasive infections in immunocompromised individuals. Fungemia, central nervous system infections, ocular infections, and peritoneal dialysis-associated peritonitis were

the most common infections in immunocompromised patients.<sup>11</sup> Skin infections, including skin ulcers, tinea capitis, onychomycosis, and diabetic foot infections also have been reported.<sup>12-17</sup> Folliculitis caused by *R. mucilaginosa*, which was considered to have been facilitated by immunosuppression related to chemotherapy, also has been reported.<sup>18</sup> *Tintelnotia* is a newly classified genus in the *Phaeosphaeriaceae* family of fungi, belonging to *Coelomycete*. *Coelomycetes* fungi are known to cause systemic and localized infections, including cutaneous and subcutaneous mycosis, deep tissue infections, onychomycosis, and endophthalmitis.<sup>19</sup> Several cases of keratitis and onychomycosis caused by *Tintelnotia* have been reported, with keratitis being the most common.<sup>20</sup> Acne caused by *Tintelnotia* has not yet been reported in English literature, although skin infections have been confirmed in 1 case.<sup>19</sup> The immunosuppressive properties of JAKi can lead to dysbiosis of the microbiome and atypical infections. Although the relationship between microbial dysbiosis and JAKi-induced acne remains inconclusive, there may be a potential association between the development of acne and treatments using JAKi.

We present the first case of JAKi-induced acne promoted by an overgrowth of rare opportunistic fungal infection. Only a few studies have identified the role of the skin microbiota in JAKi-induced acne and our understanding of the pathogenesis still needs to be improved. Our case draws attention to further investigative need in the relationship between JAKi-induced acne and microbiome.

#### Conflicts of interest

None disclosed.

#### REFERENCES

- Correia C, Antunes J, Filipe P. Management of acne induced by JAK inhibitors. *Dermatol Ther*. 2022;35:e15688.
- Lee S-D, Ahn H-J, Shin MK. A case series of acne following Janus kinase inhibitors in patients with atopic dermatitis. *JAAD Case Rep*. 2022;30:11-16.
- Guttman-Yassky E, Teixeira HD, Simpson EL, et al. Once-daily upadacitinib versus placebo in adolescents and adults with moderate-to-severe atopic dermatitis (measure up 1 and measure up 2): results from two replicate double-blind, randomised controlled phase 3 trials. *Lancet*. 2021;397:2151-2168.
- Bieber T, Simpson EL, Silverberg JI, et al. Abrocitinib versus placebo or dupilumab for atopic dermatitis. *New Engl J Med*. 2021;384:1101-1112.
- Reich K, Kabashima K, Peris K, et al. Efficacy and safety of baricitinib combined with topical corticosteroids for treatment of moderate to severe atopic dermatitis: a randomized clinical trial. *JAMA Dermatol*. 2020;156:1333-1343.
- Lee YB, Byun EJ, Kim HS. Potential role of the microbiome in acne: a comprehensive review. *J Clin Med*. 2019;8:987.

7. Kim J, Park T, Kim H-J, An S, Sul WJ. Inferences in microbial structural signatures of acne microbiome and mycobiome. *J Microbiol.* 2021;59:369-375.
8. Ganju P, Nagpal S, Mohammed M, et al. Microbial community profiling shows dysbiosis in the lesional skin of Vitiligo subjects. *Sci Rep.* 2016;6:18761.
9. Bziouche H, Sjödin KS, West CE, et al. Analysis of matched skin and gut microbiome of patients with vitiligo reveals deep skin dysbiosis: link with mitochondrial and immune changes. *J Invest Dermatol.* 2021;141:2280-2290.
10. Leong C, Schmid B, Toi MJ, et al. Geographical and ethnic differences influence culturable commensal yeast diversity on healthy skin. *Front Microbiol.* 2019;10:1891.
11. Ioannou P, Vamvoukaki R, Samonis G. *Rhodotorula* species infections in humans: a systematic review. *Mycoses.* 2019;62:90-100.
12. Peretz A, Nitzan O, Freidus V, Kassem R. Tinea capitis-like infection caused by *Rhodotorula mucilaginosa* in a shelter for African Refugee Children in Northern Israel. *Acta Trop.* 2018;179:44-46.
13. Bhattacharyya S, Shivaprakash M, Chakrabarti A, Sharma N. Foot bleb infection due to *Rhodotorula mucilaginosa* in a diabetic patient: case report and review of the literature. *Biomed Res.* 2012;23:577-579.
14. Ghasemi R, Ansari S, Lotfali E, Shahnazian Z, Madinehzad SA, Aliabadi N, et al. Coinfection of toenail onychomycosis caused by *Rhodotorula mucilaginosa* and *Candida glabrata* in an immunocompromised adult: a case report and literature review. *Nov Biomed.* 2022;10:199-205.
15. Tligui H, Oudaina W, El Ftouh S, Madda F, Hesseissen L. A skin ulcer infection due to *Rhodotorula mucilaginosa* in an immunocompromised child. *J Mycol Med.* 2018;28:215-217.
16. Martini K, Müller H, Huemer H, Höpfl R. Nail psoriasis masqueraded by secondary infection with *Rhodotorula mucilaginosa*. *Mycoses.* 2013;56:690-692.
17. Idris NFB, Huang G, Jia Q, Yuan L, Li Y, Tu Z. Mixed infection of toe nail caused by *Trichosporon asahii* and *Rhodotorula mucilaginosa*. *Mycopathologia.* 2020;185:373-376.
18. Jaeger T, Andres C, Ring J, Anliker MD. *Rhodotorula mucilaginosa* infection in Li–Fraumeni-like syndrome: a new pathogen in folliculitis. *Br J Dermatol.* 2011;164:1120-1122.
19. Garcia-Hermoso D, Valenzuela-Lopez N, Rivero-Menendez O, et al. Diversity of coelomycetous fungi in human infections: a 10-y experience of two European reference centres. *Fungal Biol.* 2019;123:341-349.
20. Roels D, Coorevits L, Lagrou K. *Tintelnotia destructans* as an emerging opportunistic pathogen: first case of *T. destructans* superinfection in herpetic keratitis. *Am J Ophthalmol Case Rep.* 2020;19:100791.