

Surgical Treatment of Infected Aortoiliac Aneurysm

Joong Kee Youn^{1*}, Suh Min Kim^{2*}, Ahram Han¹, Chanjoong Choi¹, Sang-Il Min¹,
Jongwon Ha¹, Sang Joon Kim³, and Seung-Keel Min¹

¹Department of Surgery, Seoul National University College of Medicine, Seoul,

²Department of Surgery, Hallym University Kangdong Sacred Heart Hospital, Seoul,

³Department of Surgery, Myongji Hospital, Goyang, Korea

Purpose: Infected aneurysms of the abdominal aorta or iliac artery (IAAA) are rare but fatal and difficult to treat. The purpose of this study was to review the clinical presentations and outcomes of IAAA and to establish a treatment strategy for optimal treatment of IAAA.

Materials and Methods: Electronic medical records of 13 patients treated for IAAA at Seoul National University Hospital between March 2004 and December 2012 were retrospectively reviewed.

Results: Mean age was 64.2 (median 70, range 20-79) years. Aneurysms were located in the infrarenal aorta (n=7), iliac arteries (n=5), and suprarenal aorta (n=1). Seven patients underwent excision and in situ interposition graft, 3 underwent extra-anatomical bypass, and 1 underwent endovascular repair. One patient with endovascular repair in an outside hospital refused resection, and only debridement was done, which revealed tuberculosis infection. One staphylococcal infection was caused by iliac stenting. *Mycobacterium* was the most common pathogen, followed by *Klebsiella*, *Salmonella*, and *Staphylococcus*. There were 3 in-hospital mortalities and the causes were sepsis in 2 and aneurysm rupture in 1. The 3 extra-anatomic bypasses were all patent after 5-year follow-up.

Conclusion: IAAA develops from various causes and various organisms. IAAA cases with gross pus were treated with extra-anatomic bypass, which was durable. In situ reconstruction is favorable for long term-safety and efficacy, but extensive debridement is essential.

Key Words: Infected aneurysm, Operation, Endovascular procedure, Bypass, *Mycobacterium*

Received April 2, 2015

Revised May 22, 2015

Accepted May 26, 2015

Corresponding author: Seung-Keel Min
Department of Surgery, Seoul National University Hospital, 101 Daehak-ro, Jongno-gu, Seoul 110-744, Korea
Tel: 82-2-2072-0297
Fax: 82-2-766-3975
E-mail: skminmd@snuh.org
Conflict of interest: None.

*These authors contributed equally to this work.

Copyright © 2015, The Korean Society for Vascular Surgery

This is an Open Access article distributed under the terms of the Creative Commons Attribution Non-Commercial License (<http://creativecommons.org/licenses/by-nc/4.0>) which permits unrestricted non-commercial use, distribution, and reproduction in any medium, provided the original work is properly cited.

Vasc Spec Int 2015;31(2):41-46 • <http://dx.doi.org/10.5758/vsi.2015.31.2.41>

INTRODUCTION

Infected aneurysms of the abdominal aorta and its branch arteries are rare (0.5%-2.0%), but can be fatal and difficult to treat [1,2]. The aneurysm with signs of infection, such as fever, leukocytosis, C-reactive protein (CRP) elevation and positive blood culture, should be considered an infected aneurysm, and immediate and proper treat-

ment should be started. The definitive treatment of an infected aneurysm includes surgical resection, extensive debridement, revascularization, and perioperative long-term antibiotic therapy [2-4].

The purpose of this study was to review the clinical presentations and outcomes of infected abdominal aortoiliac aneurysm (IAAA) and to establish a treatment strategy for optimal treatment of IAAA.

MATERIALS AND METHODS

All consecutive patients treated for infected aneurysms at Seoul National University Hospital between March 2004 and December 2012 were included. This study was approved by the institutional review board of Seoul National University Hospital (IRB No. H-1504-039-663). The diagnosis of infected aneurysm was made with a combination of the following criteria: 1) a positive culture from the aneurysmal wall, its contents, or the surrounding tissue; 2) clinical presentation of infection (fever, abdominal or back pain, leukocytosis, and CRP elevation); and 3) radiologic findings on computed tomography (CT). All medical records were reviewed retrospectively. Patients were assessed for age, sex, size and location of aneurysm, fever (temperature $>38^{\circ}\text{C}$), leukocytosis (white blood cell count more than $10,000/\mu\text{L}$), CRP elevation (>0.5 mg/dL), and blood/tissue cultures. The risk factors and comorbidities for infection including prior or concurrent systemic infection, diabetes mellitus (DM), hypertension (HTN), hematologic malignancy, peripheral vascular disease, solid-organ malignancy, complications, early in-hospital mortality, late patient survival, and graft patency were also recorded.

Continuous data are summarized as the median with the range, and categorical data are summarized as proportions and percentages. Dichotomous variables were analyzed by univariate analysis with chi-square or Fisher exact test as appropriate. In case of continuous variables, independent sample T-test was used if normally distributed, and in-

dependent samples Mann-Whitney U test was used if the variable showed non-normal distribution. The Kaplan-Meier method was used to calculate graft and patient survival rates. All statistical analyses were performed with the PASW Statistics ver. 18.0 software (IBM Co., Armonk, NY, USA).

RESULTS

1) Patient characteristics

Thirteen patients including 12 men (92%) and 1 woman were identified, and patient characteristics are summarized in Table 1. The mean age of the patients was 64.2 (median 70, range 20-79) years. Six patients had underlying HTN (46%); 2 patients had DM and coronary heart disease, respectively; 2 patients had hematologic abnormalities, idiopathic thrombocytopenic purpura, and acute myelogenous leukemia; 1 patient had pulmonary tuberculosis infection; and 3 patients had concurrent systemic infections.

Six patients presented with fever as their chief complaint, and only 1 had abdominal pain. Two patients had low back pain, and 2 patients were diagnosed after a routine CT check for other comorbidities (liver abscess and renal cell carcinoma).

2) Surgical procedures

Among the 13 patients, 12 had a primary infected aortoiliac aneurysm and 1 patient had an infected ane-

Table 1. Patient demographics

Patient no.	Sex	Age (y)	Location	Size (cm)	Chief complaints	Comorbidity
1	Male	49	Infrarenal AAA	6.5	Fever	HBV-LC, DM
2	Male	76	Right CIAA	8	Pulsating mass	Asthma
3	Male	72	Infrarenal AAA	4.9	Fever	CAD, HTN, ASO
4	Male	61	Infrarenal AAA	7	Abdominal pain	None
5	Male	64	both CIAA	2.6	Follow-up CT	Liver abscess, DM, HTN
6	Male	70	Infrarenal AAA	3	Leg pain	HTN, TCC
7	Male	50	Infrarenal AAA	5.2	Fever	CAD, HTN, HIV, HCV
8	Female	75	Suprarenal AAA	5.1	Fever	ITP, Alcoholic LC
9	Male	74	Infrarenal AAA	3.5	Low back pain	HTN
10	Male	79	Infrarenal AAA	3.5	Low back pain	HTN
11	Male	67	Left CIAA	2	Fever	Colon cancer
12	Male	78	Right CIAA	2.3	Follow-up CT	ASO, TCC
13	Male	20	Right EIAA	1.4	Fever	Acute myelogenous leukemia

AAA, abdominal aortic aneurysm; HBV-LC, hepatitis B virus-related liver cirrhosis; DM, diabetes mellitus; CIAA, common iliac artery aneurysm; CAD, coronary artery disease; HTN, hypertension; ASO, atherosclerosis obliterans; CT, computed tomography; TCC, transitional cell carcinoma; HIV, human immunodeficiency virus; HCV, hepatitis C virus; ITP, idiopathic thrombocytopenia purpura; EIAA, external iliac artery aneurysm.

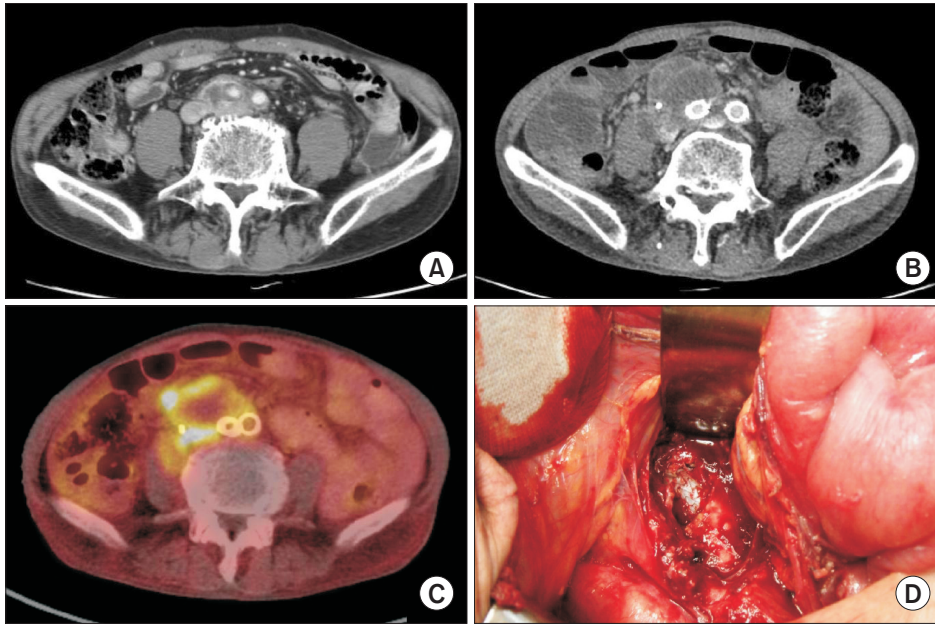


Fig. 1. Serial images of an infected stent-graft. (A) Computed tomography (CT) image before endovascular aneurysm repair (EVAR); (B) CT image after EVAR; (C) positron emission tomography-CT image after EVAR showing hot uptake around the stent-graft compatible with infection; (D) operative finding of the infected stent-graft with gross pus discharge.

Table 2. Clinical presentation of patients who underwent in situ repair and extra-anatomical bypass

	In situ repair	Bypass	P-value
No. of patients	7	3	
Age (y)	63.14±10.56	73.33±6.02	0.138
Aneurysm size (cm)	4.27±2.81	3.00±0.87	0.909
Preop antibiotics use (d)	5.14±11.19	14.00±12.00	0.114
Postop antibiotics use (d)	118.57±139.45	33.67±7.23	0.732
Preop WBC (/ μ L)	7,947±3,465	7,630±4,123	0.909
Postop WBC (/ μ L)	7,958±6,705	3,720±208	0.030
Preop CRP (mg/dL)	5.67±6.38	6.12±8.15	0.909
Postop CRP (mg/dL)	0.71±0.39	0.71±0.55	0.732
Postop hospital days	30.4±21.6	36.3±6.4	0.305

Preop, preoperative; Postop, postoperative; WBC, white blood cell; CRP, C-reactive protein.

urysm after stent insertion for iliac stenosis. Ten patients underwent curative surgery including in situ revascularization in 7 patients and extra-anatomical bypass in 3 patients. One patient had stent graft insertion with endovascular aneurysm repair (EVAR) due to poor general condition resulting from leukemia. One patient underwent EVAR at another hospital due to suspected contained rupture of a common iliac artery aneurysm was transferred due to aggravation of a periarterial low-density lesion with mild fever, which was confirmed as a tuberculosis infection after debridement and tissue culture. We suspect this was a primary infected aneurysm caused by tuberculosis (Fig. 1). Table 2 shows the clinical presentation of the patients who underwent in situ repair and extra-anatomical bypass.

3) Bacteriology

The microbiologic data are summarized in Table 3. All patients had preoperative blood cultures, and 6 presented with pathogens, including three *Staphylococcus aureus*, two *Klebsiella pneumoniae* and 2 *Salmonella* species. Tissue cultures were done in 7 patients who underwent surgery with resection of the infected tissue, and 3 patients had *Mycobacterium tuberculosis*, 2 had *Salmonella* species, and one was diagnosed with brucellosis. All patients were treated with broad-spectrum antibiotics perioperatively.

4) Early outcomes

The mean length of the hospital stay for all patients was 38.5±27.7 days. The patients who underwent in situ surgical repair and extra-anatomical repair stayed in the hospital for 30.4±21.6 and 36.3±6.4 days, respectively with no significant difference. There were 3 in-hospital mortalities. One patient who underwent in situ repair died of severe sepsis on postoperative day 19. One patient who underwent EVAR for external iliac artery aneurysm due to leukemia and systemic infection died of sepsis on postoperative day 34. One patient died of aneurysm rupture during stent graft preparation.

5) Late outcomes

Ten patients survived with a mean follow-up of 31.5 (1-63) months. Two patients were lost after a mean follow-up of 3 (1-5) months. Eight patients are currently

Table 3. Pathogens revealed by blood/tissue culture and the causes of mortality

Patient no.	Procedure name	Pathogen	Site of positive culture	Mortality
1	Aorto-biiliac bypass	<i>Klebsiella pneumoniae</i>	Blood	POD 19, sepsis
2	RIA interposition	<i>Escherichia coli, Escherichia faecalis</i>	Tissue	5 months, unknown
3	Aorto-biiliac bypass	<i>Staphylococcus aureus</i>	Blood	Alive
4	Aorto-biiliac bypass	<i>Mycobacterium tuberculosis</i>	Tissue	Alive
5	Aorto-biiliac bypass	<i>K. pneumonia</i>	Blood	Alive
6	Aorto-biiliac bypass (RFP-soaked graft)	<i>M. tuberculosis</i>	Tissue	Alive
7	Aorta interposition	<i>Salmonella B</i>	Blood and tissue	Alive
8	-	MRSA	Blood	Died during stent graft manufacture
9	Right axillo-femoral bypass, fem-fem bypass	<i>M. tuberculosis</i>	Tissue	40 months, pneumonia
10	Right axillo-femoral bypass, fem-fem bypass	<i>Brucella</i>	Blood	Alive
11	Fem-fem bypass	<i>Salmonella D</i>	Tissue	Alive
12	Debridement and drainage (prior EVAR)	<i>M. tuberculosis</i>	Tissue	5 months, unknown
13	EVAR	<i>Pseudomonas, MRSA, Candida albicans</i>	Blood	4 months, sepsis

POD, postoperative day; RIA, right iliac artery; RFP, rifampin; MRSA, methicillin-resistant *Staphylococcus aureus*; fem-fem, femoro-femoral; EVAR, endovascular aneurysm repair.

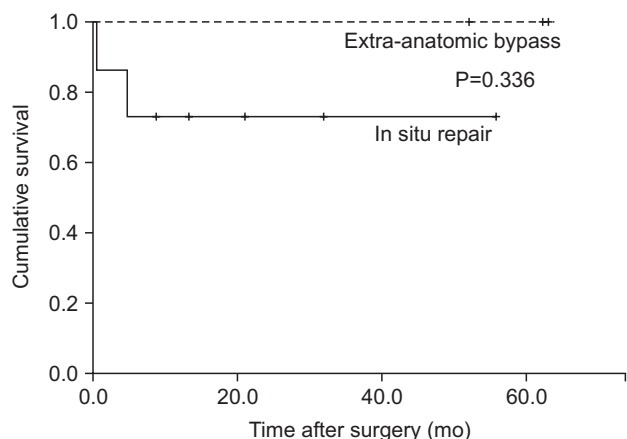


Fig. 2. Kaplan-Meier survival curve for each type of operation.

being followed and have not reported any graft-related complications. Fig. 2 shows the survival according to each type of surgery.

DISCUSSION

Infected aortoiliac aneurysms are rare and difficult to treat. Several studies suggested early diagnosis and surgical excision of the aneurysm with long-term antibiotic therapy as the most appropriate treatment option. The aim of our study was to review the clinical presentation and outcome of IAAA and to potentially establish an optimal

treatment strategy for IAAA. Controversial issues include revascularization options, the role and risk of endovascular repair, and the optimal duration of antibiotic therapy.

Various causes and pathogens of infected aneurysms have been identified. Some infections in our study were iatrogenic, which developed after a procedure of iliac stenting or Bacillus Calmette-Guérin inoculation into the bladder for the treatment of bladder cancer. One tuberculosis infection was misdiagnosed as transmural hematoma with impending rupture and unintended EVAR was performed in an infected AAA.

Salmonella species are reported to be the most common pathogens in the literature [5-7]. In the current study, various pathogens from more than 5 different species were identified, and the most common pathogen was *M. tuberculosis*.

The optimal duration of antibiotic therapy is still controversial, with various recommendations ranging from 6 weeks to lifelong use [8-10]. Usually antibiotic administration is recommended until there is no evidence of infection clinically and hematologically [2]. For tuberculosis infection, 6- to 9-month regimens with combinations of drugs are recommended [11].

Some authors suggested that vessel excision with extensive debridement of the infected tissue and extra-anatomical bypass should be the first option of revascularization [5,12-14]. Others reported that in situ repair could be performed safely after thorough de-

bridement of the infected field [2,4,6,15]. This study included 7 cases of in situ replacement and 3 cases of extra-anatomical bypass that showed similar early and late outcomes without any report of graft complications. Some authors suggested a selective approach in conducting in situ repair to avoid purulent infections in the operative field [2,6,16]. We performed in situ graft replacement in patients after thorough debridement of the infected tissue. If there was gross pus discharge in the vessels or when complete debridement was doubtful, extra-anatomic revascularization was performed. Regarding graft material, we used polytetrafluoroethylene (n=6) or Dacron (n=3) grafts. In 1 case of in-situ repair, a rifampicin-soaked Dacron graft was used to reduce the risk of infection. Injectable liquid-form rifampicin is available only in the Korea Orphan Drug Center, so emergency use of the drug was difficult. With increasing incidence of vascular infections, we have decided to use rifampicin-soaked grafts for any suspected infection and prepared predeposit vials of rifampicin in the operating room for a liberal use.

Recently, EVAR has been accepted widely as a treatment option for AAA [17]. Several authors have reported the results of EVAR for the treatment of IAAA [18,19]. Kan et al. [20] mentioned that when patients present with aneurysm rupture or fever, the EVAR method could be considered as a temporary measure, and a definitive surgical treatment should be considered afterwards. We had 1 case of EVAR (patient 13), and the patient was severely immunocompromised due to acute myelogenous leukemia. Because of the very high surgical risks, EVAR was performed for an external iliac artery aneurysm. Fever and septic conditions continued after the procedure, and the patient died 4 months after EVAR due to uncontrolled severe sepsis. Because infection control is very important in the management of infected aneurysms, the role of EVAR would be a bridge to delayed definitive open surgery.

When infected aneurysm is suspected, we usually recommend immediate broad-spectrum antibiotics therapy and emergent or urgent operation. Some may argue that surgery can be delayed because the use of appropriate antibiotics decreases the severity of infection. However, the causative organism can frequently be isolated only by tissue culture, and empirical broad spectrum antibiotics are not effective for atypical infections such as *Mycobacterium* or *Brucellosis*. Furthermore, there are substantial risks of complication during the delay, including aneurysm rupture, fistula into adjacent organs, circulatory bacteremia, and metastatic infection. Deciding the appropriate method and timing of the surgery must be based on the patient's general condition, considering age, hemodynamic instability, and life expectancy.

The limitations of this study include retrospective data collection and a limited number of patients. Another limitation could be the shorter follow-up period of in situ repair patients compared with bypass patients, due to the relatively recent introduction of the in situ replacement method. Further follow-up of these cases is needed to compare the longer-term results of both surgical methods. However, no prosthetic graft infection in either surgical option was noted.

CONCLUSION

IAAA can develop from various causes and organisms. The management of infected aneurysms consists of thorough surgical debridement of the infected field, revascularization, and prolonged antibiotic therapy. Revascularization can be performed safely either by in situ repair or extra-anatomical bypass, followed by aggressive prolonged antibiotic therapy. EVAR could be performed in cases of high surgical risks, but secondary open surgical repair may be needed for definitive management.

REFERENCES

- 1) Reddy DJ, Shepard AD, Evans JR, Wright DJ, Smith RF, Ernst CB. Management of infected aortoiliac aneurysms. *Arch Surg* 1991;126:873-878.
- 2) Müller BT, Wegener OR, Grabitz K, Pillny M, Thomas L, Sandmann W. Mycotic aneurysms of the thoracic and abdominal aorta and iliac arteries: experience with anatomic and extra-anatomic repair in 33 cases. *J Vasc Surg* 2001;33:106-113.
- 3) Gomes MN, Choyke PL, Wallace RB. Infected aortic aneurysms. A changing entity. *Ann Surg* 1992;215:435-442.
- 4) Lee CH, Hsieh HC, Ko PJ, Li HJ, Kao TC, Yu SY. In situ versus extra-anatomic reconstruction for primary infected infrarenal abdominal aortic aneurysms. *J Vasc Surg* 2011;54:64-70.
- 5) Woon CY, Sebastian MG, Tay KH, Tan SG. Extra-anatomic revascularization and aortic exclusion for mycotic aneurysms of the infrarenal aorta and iliac arteries in an Asian population. *Am J Surg* 2008;195:66-72.
- 6) Hsu RB, Chen RJ, Wang SS, Chu SH.

- Infected aortic aneurysms: clinical outcome and risk factor analysis. *J Vasc Surg* 2004;40:30-35.
- 7) Hsu RB, Tsay YG, Wang SS, Chu SH. Surgical treatment for primary infected aneurysm of the descending thoracic aorta, abdominal aorta, and iliac arteries. *J Vasc Surg* 2002;36:746-750.
 - 8) Hollier LH, Money SR, Creely B, Bower TC, Kazmier FJ. Direct replacement of mycotic thoracoabdominal aneurysms. *J Vasc Surg* 1993;18:477-484.
 - 9) Chan FY, Crawford ES, Coselli JS, Safi HJ, Williams TW Jr. In situ prosthetic graft replacement for mycotic aneurysm of the aorta. *Ann Thorac Surg* 1989;47:193-203.
 - 10) Brown SL, Busuttil RW, Baker JD, Machleder HI, Moore WS, Barker WF. Bacteriologic and surgical determinants of survival in patients with mycotic aneurysms. *J Vasc Surg* 1984; 1:541-547.
 - 11) American Thoracic Society. Medical Section of the American Lung Association: Treatment of tuberculosis and tuberculosis infection in adults and children. *Am Rev Respir Dis* 1986; 134:355-363.
 - 12) Belz J, Gattermann M, Schröder HJ. Extra-anatomic bypass as therapy of infected bacterial (mycotic) infrarenal aortic aneurysm. A comparative, literature supported analysis. *Chirurg* 1989;60:479-478.
 - 13) Pasic M, Carrel T, Vogt M, von Segesser L, Turina M. Treatment of mycotic aneurysm of the aorta and its branches: the location determines the operative technique. *Eur J Vasc Surg* 1992;6:419-423.
 - 14) Tanaka K, Kawauchi M, Murota Y, Furuse A. 'No-Touch' isolation procedure for ruptured mycotic abdominal aortic aneurysm. *Jpn Circ J* 2001;65:1085-1086.
 - 15) Vogt PR, von Segesser LK, Goffin Y, Pasic M, Turina MI. Cryopreserved arterial homografts for in situ reconstruction of mycotic aneurysms and prosthetic graft infection. *Eur J Cardiothorac Surg* 1995;9:502-506.
 - 16) Kyriakides C, Kan Y, Kerle M, Cheshire NJ, Mansfield AO, Wolfe JH. 11-year experience with anatomical and extra-anatomical repair of mycotic aortic aneurysms. *Eur J Vasc Endovasc Surg* 2004;27:585-589.
 - 17) Greenhalgh RM, Brown LC, Kwong GP, Powell JT, Thompson SG; EVAR trial participants. Comparison of endovascular aneurysm repair with open repair in patients with abdominal aortic aneurysm (EVAR trial 1), 30-day operative mortality results: randomised controlled trial. *Lancet* 2004; 364:843-848.
 - 18) Semba CP, Sakai T, Slonim SM, Razavi MK, Kee ST, Jorgensen MJ, et al. Mycotic aneurysms of the thoracic aorta: repair with use of endovascular stent-grafts. *J Vasc Interv Radiol* 1998; 9:33-40.
 - 19) Sörelius K, Mani K, Björck M, Nyman R, Wanhainen A. Endovascular repair of mycotic aortic aneurysms. *J Vasc Surg* 2009;50:269-274.
 - 20) Kan CD, Lee HL, Yang YJ. Outcome after endovascular stent graft treatment for mycotic aortic aneurysm: a systematic review. *J Vasc Surg* 2007; 46:906-912.