

Pulmonary Root Translocation with the Lecompte Maneuver: For Transposition of the Great Arteries with Ventricular Septal Defect and Pulmonary Stenosis

Dong Woog Yoon, M.D., Tae Ho Kim, M.D., Man-shik Shim, M.D.,
Tae-Gook Jun, M.D., Ph.D., Jae Seok Jang, M.D.

A five-month-old boy who had undergone previously transcatheter balloon atrioseptostomy at 3 days of age for complete transposition of the great arteries with ventricular septal defect and pulmonary stenosis underwent pulmonary root translocation with the Lecompte maneuver. This operation has the advantages of maintaining pulmonary valve function, preserving the capacity for growth, and avoiding problems inherent to the right ventricular to pulmonary artery conduit. This patient progressed well for 9 months postoperatively and we report this case of pulmonary root translocation with the Lecompte maneuver.

Key words: 1. Congenital heart defects
2. Transposition of great vessels

CASE REPORT

A two-day-old male with whole body cyanosis and tachypnea born at 38+2 weeks of gestation with a birth weight of 4,000 g was referred to Samsung Medical Center. His percutaneous oxygen saturation was 60% to 70%, and there was no response to oxygen supply. A grade 3/6 systolic murmur was heard at the left sternal border, and the vital signs were a blood pressure of 70/40, heart rate of 165 beats per minutes, respiratory rate of 42 breaths per minute, and temperature of 37.2°C. Echocardiographic findings demonstrated a complete transposition of the great arteries (TGA), large peri-membranous ventricular septal defect (VSD), mild pulmonary stenosis (PS) with a peak pressure gradient of 23 to 32 mmHg, and a small patent ductus arteriosus (PDA). Additionally, there was subpulmonic deviation of the outlet

septum with a small asymmetric pulmonary valve (PV) with fusion. The PV size was 5.8×6.1 mm (z -score < -2.5) (Fig. 1A, B). The patient underwent urgent cardiac catheterization and balloon atrioseptostomy at 3 days of age. After the procedure, the respiration rate stabilized and the percutaneous oxygen saturation was 80% under ambient conditions. The patient was discharged at 10 days of age.

The patient was relatively well until five months of age when he started to become increasingly short of breath. Eventually, he was admitted for operation, with a body weight of 7.4 kg, and underwent pulmonary root translocation with the Lecompte maneuver. The operation details are described below.

After median sternotomy, an inverted Y-shaped pericardiostomy was performed. Because in situ material was used for the right ventricular outflow tract (RVOT) recon-

Department of Thoracic and Cardiovascular Surgery, Samsung Medical Center, Sungkyunkwan University School of Medicine

Received: March 20, 2015, Revised: June 17, 2015, Accepted: June 23, 2015, Published online: October 5, 2015

Corresponding author: Tae-Gook Jun, Department of Thoracic and Cardiovascular Surgery, Samsung Medical Center, Sungkyunkwan University School of Medicine, 50 Irwon-dong, Gangnam-gu, Seoul 06351, Korea
(Tel) 82-2-3410-3484 (Fax) 82-2-3410-1680 (E-mail) tgjuncmc@gmail.com

© The Korean Society for Thoracic and Cardiovascular Surgery. 2015. All right reserved.

© This is an open access article distributed under the terms of the Creative Commons Attribution Non-Commercial License (<http://creativecommons.org/licenses/by-nc/4.0>) which permits unrestricted non-commercial use, distribution, and reproduction in any medium, provided the original work is properly cited.

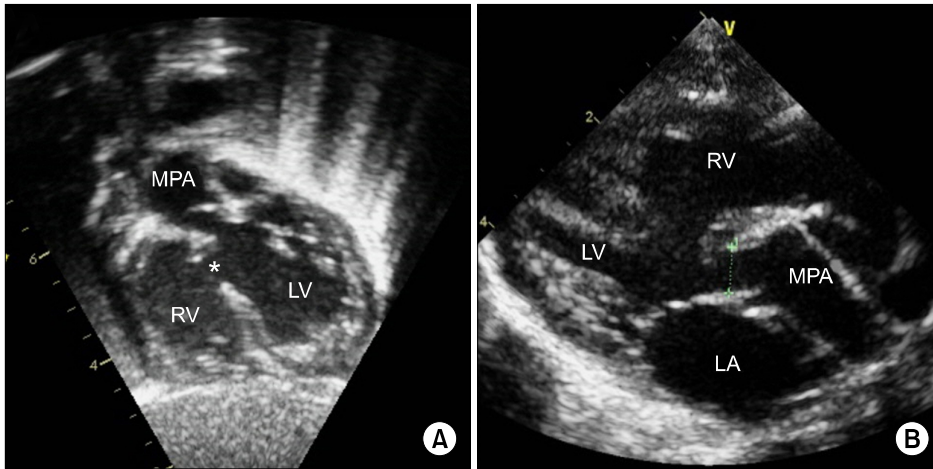


Fig. 1. Preoperative echocardiography showed transposition of the great arteries, large peri-membranous VSD, subpulmonic deviation of the outlet septum, and valvar pulmonary stenosis with asymmetric pulmonary valve with fusion (pulmonary valve size=5.8×6.1 mm, z-score<-2.5). (A) Subcostal view (* indicates VSD). (B) Parasternal long axis view. MPA, main pulmonary artery; RV, right ventricle; LV, left ventricle; LA, left atrium; VSD, ventricular septal defect.

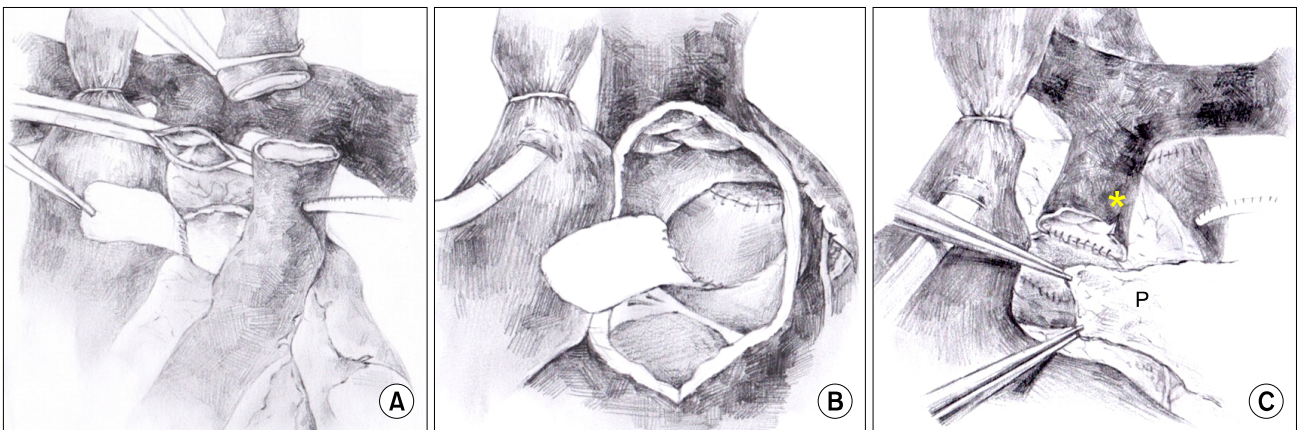


Fig. 2. Illustration of pulmonary root translocation with the Lecompte maneuver. (A) Dissected pulmonary artery, defect of the pulmonary root, bovine pericardial patch, and transected aorta. (B) After resection of the conal septum, the ventricular septal defect was closed with a bovine pericardial patch to create the left ventricle-to-aorta tunnel. (C) After the Lecompte maneuver, the right ventricular outflow tract was reconstructed with excised pulmonary root and an *in-situ* autologous pericardial patch on the anterior side (* indicates pulmonary valve commissurotomy and P indicates *in situ* autologous pericardium). Modified from Da Silva JP, da Fonseca L. Oper Tech Thorac Cardiovasc Surg 2009;14:23-34 [1].

struction, the pericardium was not harvested. Cardiopulmonary bypass began with aortic and bicaval cannulation during moderate hypothermia. After PDA division, antegrade cold blood cardioplegia was infused through the aortic root cannulation. Then, the pulmonary artery and its branches were extensively dissected, from the distal attachments into both pulmonary hila, to be mobilized anterior to right ventriculotomy. The coronary artery pattern was [1 AD; 2 R, Cx]. Because of the prominent left anterior descending (LAD) coronary artery, we planned a Lecompte maneuver. Without this maneuver, the LAD would have been compressed. After transection of the proximal ascending aorta, the pulmonary

artery root was excised below the PV annulus from the left ventricle (LV) (Figs. 2A, 3A) [1]. The main pulmonary artery was moved anteriorly with the Lecompte maneuver. After right ventriculotomy on the anterolateral side of the right ventricle (Fig. 3B), the VSD position was confirmed via the right atrium and right ventriculotomy. A portion of the right ventricular muscle was resected at the conal septum to relieve the LV exit to the aorta. Then, the defect in the pulmonary root was closed with a bovine pericardial patch and 6.0 polypropylene running suture. After an end-to-end anastomosis of the transected aorta, the VSD was closed with a bovine pericardial patch and 6.0 polypropylene running suture to create

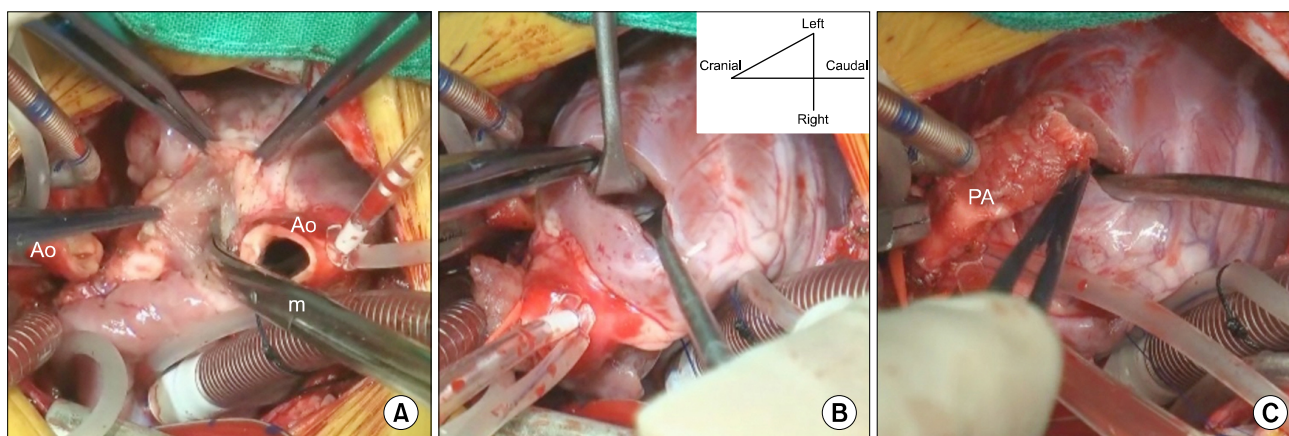


Fig. 3. (A) Pulmonary root dissection with careful attention. (B) Right ventriculotomy in the antero-lateral side of the right ventricle. (C) Position of the PA after the Lecompte maneuver. Ao, transected aorta; m, Metzzenbaum scissors; PA, pulmonary artery.

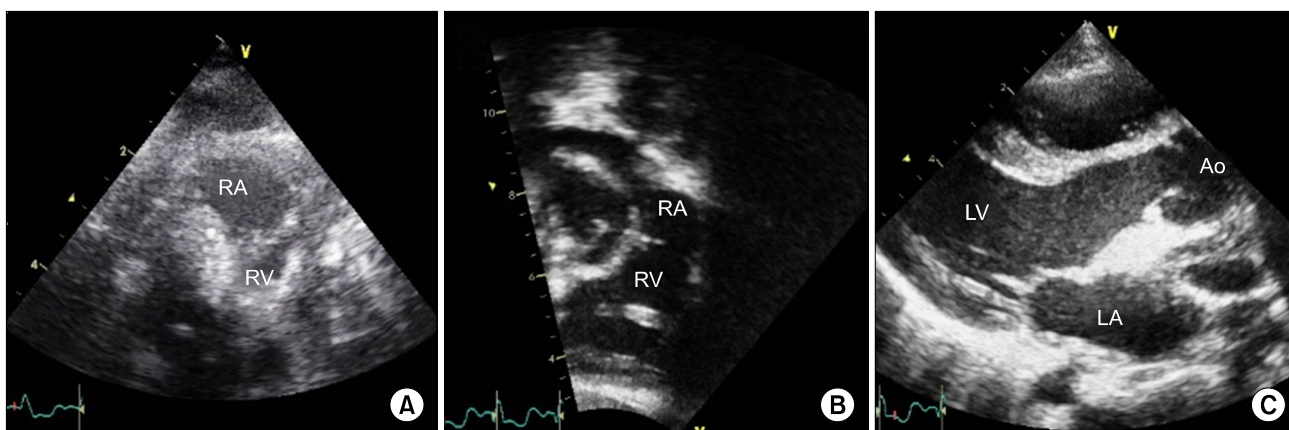


Fig. 4. (A) Echocardiography 7 days after the operation (subcostal view) showed minimal PS and a PV size of 6.8 mm (z-score < -2.5). (B and C) Echocardiography 6 months after the operation B. Subcostal view showed mild PS and a mature PV size of 15.8 mm (z-score = +1.70) without insufficiency of the right ventricular outflow tract. (C) A parasternal long axis view showed the absence of left ventricular outflow tract obstruction. PA, pulmonary artery; RV, right ventricle; LV, left ventricle; LA, left atrium; Ao, aorta; PS, pulmonary stenosis; PV, pulmonary valve.

the LV-to-aorta tunnel (Fig. 2B) [1]. Formation of LV tunneling with this patch During the LV tunneling, we tried to make the patch straightened for the preservation of RV volume. The PV was a functional bicuspid valve with fusion, and the PV annulus size which was measured intraoperatively using Hegar dilator was 9 mm. Appropriate PV annulus size according to the patient's body surface area (Z-score) was 10.5 mm, so we performed commissurotomy [2]. Next, a 10-mm hegar dilator was passed through the PV. The RVOT was reconstructed with an excised pulmonary artery root and an in situ autologous pericardial patch that had growth poten-

tial on the anterior side (Figs. 2C, 3C) [1]. Intraoperative transesophageal echocardiography showed no significant obstruction of the LVOT or RVOT.

After the operation, the patient was extubated on the 3rd post-operative day and discharged with no early post-operative complications on the 8th postoperative day. Echocardiographic findings 7 days after the operation showed minimal PS (mean PG=13 mmHg) with a PV size of 6.8 mm (z-score < -2.5), and those 6 months after the operation showed mild PS (mean PG=22 mmHg) with a mature PV size of 15.8 mm (z-score = +1.70) (Fig. 4). Additionally, residual arterial septal

defect, VSD, or insufficiency of the left ventricular outflow tract were not exhibited. At this time the patient is doing well 9 months postoperatively and has a New York Heart Association grade of class I.

DISCUSSION

The Rastelli procedure was first performed in 1968 [3] and soon became a standard surgical technique for patients with TGA associated with a VSD and PS. In addition to excellent relief of PS, the Rastelli procedure allows for anatomic correction and achieves good anatomic and physiologic results in the short term [4]. However, late results of this procedure have critical limitations: low long-term survival and an inevitable reoperation on the obstructed conduit. These problems come from the inability of the conduit to grow and from LVOT stenosis [5-7]. To overcome the limitations of this procedure, pulmonary root translocation (PRT) was introduced by da Silva et al. [8]. With the PRT technique, the dissected pulmonary root is implanted in the right ventricle outflow tract to allow for growth of the pulmonary artery. Therefore, the risk of late conduit obstruction may be decreased. Additionally, a more natural LVOT is constructed by avoiding making an incision or mobilizing the aorta. Coronary artery manipulation is also not required. Long-term follow-up data demonstrated high long-term survival and adequate pulmonary root growth [9].

Inspired by da Silva, we performed a PRT on a five-month-old patient with TGA, VSD, and PS. During the operation, great care was taken to avoid injury to the PV and the mitral valve when removing the pulmonary root. Unlike da Silva et al. [8], we employed the Lecompte maneuver. Because of a prominent LAD coronary artery, use of this technique was unavoidable. The translocated pulmonary trunk was close to the sternum, which resulted in an increased risk of bleeding during re-intervention. Additionally, we used an in situ autologous pericardium patch during the RVOT reconstruction because of the expected growth potential. However, a major drawback is the possible formation of aneurysmal dilatation of the pericardial hood [9].

In this case, an arterial switch operation was excluded be-

cause of the LVOT obstruction. Questions regarding adequate PV size for pulmonary root translocation have arisen. However, larger numbers of patients and longer follow-up data will be needed to address this point.

Management of TGA, VSD, and PS continues to be a challenge. Pulmonary root translocation with the Lecompte maneuver can be a candidate procedure with the aim of preserving the growth potential of the native PV.

CONFLICT OF INTEREST

No potential conflict of interest relevant to this article was reported.

REFERENCES

1. Da Silva JP, da Fonseca L. *Pulmonary root translocation*. Oper Tech Thorac Cardiovasc Surg 2009;14:23-34.
2. Zilberman MV, Khoury PR, Kimball RT. *Two-dimensional echocardiographic valve measurements in healthy children: gender-specific differences*. Pediatr Cardiol 2005;26:356-60.
3. Rastelli GC, Wallace RB, Ongley PA. *Complete repair of transposition of the great arteries with pulmonary stenosis: a review and report of a case corrected by using a new surgical technique*. Circulation 1969;39:83-95.
4. Rastelli GC, McGoon DC, Wallace RB. *Anatomic correction of transposition of the great arteries with ventricular septal defect and subpulmonary stenosis*. J Thorac Cardiovasc Surg 1969;58:545-52.
5. Kreutzer C, De Vive J, Oppido G, et al. *Twenty-five-year experience with rastelli repair for transposition of the great arteries*. J Thorac Cardiovasc Surg 2000;120:211-23.
6. Dearani JA, Danielson GK, Puga FJ, Mair DD, Schleck CD. *Late results of the Rastelli operation for transposition of the great arteries*. Semin Thorac Cardiovasc Surg Pediatr Card Surg Annu 2001;4:3-15.
7. Marcelletti C, Mair DD, McGoon DC, Wallace RB, Danielson GK. *The Rastelli operation for transposition of the great arteries: early and late results*. J Thorac Cardiovasc Surg 1976;72:427-34.
8. Da Silva JP, Baumgratz JF, da Fonseca L. *Pulmonary root translocation in transposition of great arteries repair*. Ann Thorac Surg 2000;69:643-5.
9. Da Silva JP, da Silva Lda F, Lopes LM, et al. *Pulmonary root translocation in malposition of great arteries repair allows right ventricular outflow tract growth*. J Thorac Cardiovasc Surg 2012;143:1292-8.