

Aripiprazole Improved Post-Streptococcal Dyskinesia by Modulating Dopaminergic Activity: A Case Report

Jae Hyun Ryou¹, Doug Hyun Han¹, Reeree Lee², Sun Mi Kim¹

¹Department of Psychiatry, Chung-Ang University College of Medicine, ²Department of Nuclear Medicine, Chung-Ang University Hospital, Seoul, Korea

This case report aimed to discuss the efficacy of aripiprazole for dyskinesia in patients with functional movement disorder after streptococcal infection, with its biological action of modulating dopamine hyperactivity in the basal ganglia as a dopamine partial agonist. This report has shown that the [¹⁸F] *N*-(3-Fluoropropyl)-2 β -carbon ethoxy-3 β -(4-iodophenyl) nortropane positron emission tomography findings of the patient revealed that the dopamine hyperactivity in the basal ganglia at baseline was normalized after aripiprazole treatment due to its balancing effect as a dopamine partial agonist.

KEY WORDS: Aripiprazole; Streptococcal infection; Dyskinesia; Basal ganglia; Dopamine.

INTRODUCTION

Functional movement disorder is a condition defined by the manifestation of abnormal involuntary movements, which are not typically observed in other neurological illnesses [1]. Neuroimaging studies on functional movement disorders have suggested motor, emotional, or sensory processing dysfunctions within the sensorimotor cortex, amygdala, supplementary motor area, prefrontal cortex, thalamus, cerebellum, and basal ganglia [2]. We present a case in which aripiprazole was effective for dyskinesia in a patient with functional movement disorder after streptococcal infection. The Institutional Review Board of Chung-Ang University Hospital approved the study protocol (approval number: 2012-010-441). Written informed consent was obtained from the patient for publication of any potentially identifiable data included in this article.

CASE

A 32-year-old male was admitted to the emergency room due to severe dysarthria, dyskinesia (involuntary twisting and shaking of the head and both upper and lower limbs), and weakness in the lower limbs that developed suddenly a day ago. The pattern of dyskinesia was not typical of dystonia, chorea, or tic. He had been under severe stress for months because of legal problems related to his business. Mental status examination revealed no psychiatric symptoms, including hallucinations, delusions, or clinically significant mood symptoms. The patient did not have any family history of psychiatric illness or dyskinesia after streptococcal infection. He had fever, chills, fatigue, and sore throat for a month preceding dyskinesia. An anti-streptolysin O titer, a blood test for recent streptococcal infection, was positive (400 IU/ml). The antibiotic ceftriaxone was administered for acute pharyngotonsillitis. There were no symptomatic or laboratory findings, including autoimmune antibody testing, brain magnetic resonance imaging, electroencephalography, and cerebrospinal fluid study, suggesting specific autoimmune or neurological diseases. To evaluate dopamine activity in the basal ganglia, [¹⁸F] *N*-(3-Fluoropropyl)-2 β -carbon ethoxy-3 β -(4-iodophenyl) nortropane (FP-CIT) positron

Received: June 24, 2021 / **Revised:** September 7, 2021

Accepted: October 6, 2021

Address for correspondence: Sun Mi Kim

Department of Psychiatry, Chung-Ang University College of Medicine, 102 Heukseok-ro, Dongjak-gu, Seoul 06973, Korea

E-mail: sunmikim706@gmail.com

ORCID: <https://orcid.org/0000-0003-4131-0542>

© This is an Open-Access article distributed under the terms of the Creative Commons Attribution Non-Commercial License (<http://creativecommons.org/licenses/by-nc/4.0>) which permits unrestricted non-commercial use, distribution, and reproduction in any medium, provided the original work is properly cited.

emission tomography (PET) was conducted. For the first four weeks, he was administered 10 mg aripiprazole, 3 mg clonazepam, 40 mg propranolol for dyskinesia, and 150 mg pregabalin for both leg pain, probably neuropathic, and physical therapy. The patient denied any mood symptoms, but mild depressive mood and mild to moderate anxiety were suggested in clinician-rated scales (Hamilton Depression Rating Scale [HDRS] [3] = 10 and Hamilton Anxiety Rating Scale [HAM-A] [4] = 19). In addition, he had insomnia. Considering the patient's mood, anxiety, and insomnia, we prescribed 15 mg mirtazapine. We conducted consultation with various departments such as departments of rheumatology, neurology, infectious diseases, and rehabilitation medicine, but other departments replied that it was difficult to find a specific cause and treatment for his difficulties. Therefore, he did not receive any particular medical treatment except psychiatric medication and antibiotic ceftriaxone for acute pharyngotonsillitis. Since extrapyramidal symptoms, such as worsening dysarthria and rigidity, appeared when ≥ 15 mg aripiprazole was administered around the fourth week, 10 mg aripiprazole was maintained and 5 mg procyclidine hydrochloride was added. Around the fifth week, procyclidine and pregabalin were discontinued because of voiding difficulties. Dyskinesia of the head and limbs was significantly improved in a dose-dependent manner by increasing the dose of aripiprazole, and was almost absent at rest following eight-weeks of aripiprazole treatment. Lower limb weakness improved enough for him to walk using a walker after being completely bedridden initially. Dysarthria also improved, making most forms of communication possible. At eight-week follow-up [18 F]FP-CIT PET, the mean standardized uptake values (SUV_{mean}) in the basal ganglia increased compared to baseline (Fig. 1). At follow-up, the SUV_{mean} of the right putamen, left putamen, right caudate, and left caudate increased by 17.2% (7.50 to 8.79), 20.7% (7.48 to 9.03), 21.1% (6.72 to 8.14), and 8.68% (6.84 to 8.68), respectively. The anti-streptolysin O antibody titer decreased, but was still positive (200 IU/ml) at follow-up. The follow-up score of HDRS for depression [3] was 5, and the score of HAM-A [4] for anxiety was 5, which is generally accepted to be within the normal range.

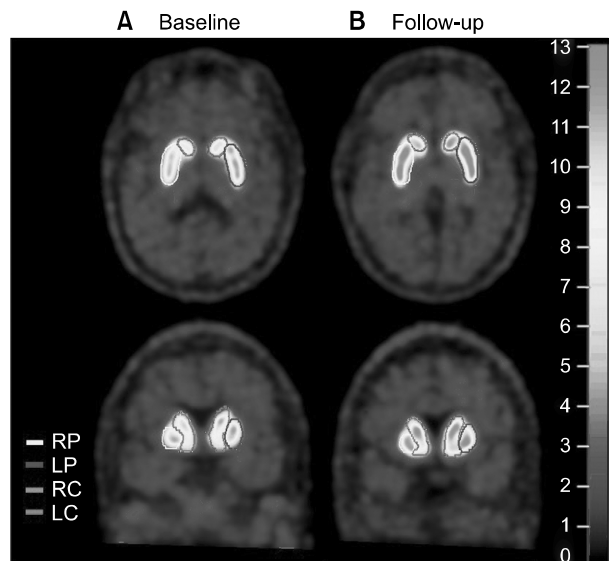


Fig. 1. Representative [18 F]FP-CIT PET images of the patient. (A) The baseline RP, LP, RC, and LC SUV_{mean} were 7.50, 7.48, 6.72, and 6.84. (B) At eight-week follow-up, RP, LP, RC, and LC SUV_{mean} were 8.79, 9.03, 8.14, and 8.68.

FP-CIT, *N*-(3-Fluoropropyl)-2 β -carbon ethoxy-3 β -(4-iodophenyl) nortropane; PET, positron emission tomography; SUV_{mean}, mean standardized uptake value; RP, right putamen; LP, left putamen; RC, right caudate; LC, left caudate.

DISCUSSION

To our knowledge, this is the first study on the therapeutic effect of antipsychotic drugs, including aripiprazole, on post-streptococcal dyskinesia. Antibodies against group A streptococci can cross-react with neuronal cells due to molecular similarity, especially in the basal ganglia, leading to movement and neuropsychiatric symptoms [5]. In this case, the patient developed symptoms after acute pharyngotonsillitis with an elevated titer of anti-streptolysin O. [18 F]FP-CIT binds to the dopamine transporter (DAT) of presynaptic nerve terminals and reflects the activity of dopaminergic neurons. In the patient's PET, the SUV_{mean} in the basal ganglia at baseline was within the normal range but relatively low. A relatively lower SUV_{mean} in the basal ganglia indicates dopaminergic denervation, presumably due to autoimmune damage. Dopaminergic denervation in the basal ganglia may induce abnormal turnover-related dopamine release, leading to dyskinesia. Therefore, we hypothesized that an autoimmune mechanism could be the cause of basal ganglia damage.

Aripiprazole is a dopamine D₂ receptor and serotonin

5-HT_{1A} receptor partial agonist [6]. Since dyskinesia is caused by a tonic dopamine neurotransmission imbalance, aripiprazole is therapeutic because it has both dopamine antagonistic and agonistic neuropharmacological properties depending on the tone of the local dopamine system [7]. Aripiprazole is an established treatment option for Huntington's disease [8], tics, and Tourette's disorder [9]. In the patient's follow-up PET, lower striatal DAT binding was normalized after eight-weeks of aripiprazole treatment because of its balancing effect as a partial dopamine agonist. Dyskinesia was improved by increasing the dosage of aripiprazole, strongly suggesting that aripiprazole played a major role in the therapeutic effect. The dosage of mirtazapine and clonazepam was fixed throughout the patient's treatment, and procyclidine was prescribed for only 10 days. Therefore, it is unlikely that medications other than aripiprazole had an effect on the relief of dyskinesia. Numerous preclinical and clinical studies have shown that prolonged (≥ 4 weeks) aripiprazole administration has long-term modification effects on the expression of genes involved in protective and neurotrophic proteins such as brain-derived neurotrophic factor and genes implicated in the pathogenesis of psychosis [10].

In conclusion, aripiprazole may be effective for treating dyskinesia in patients with functional movement disorder after streptococcal infection, and it can biologically modulate dopaminergic activity in the basal ganglia as a partial dopamine agonist.

■ Funding

None.

■ Acknowledgments

We thank the patient and his parents for their participation.

■ Conflicts of Interest

No potential conflict of interest relevant to this article was reported.

■ Author Contributions

Conceptualization: Sun Mi Kim, Doug Hyun Han. Data acquisition: Jae Hyun Ryou. Formal analysis: Sun Mi Kim, Reeree Lee. Supervision: Doug Hyun Han. Writing—original draft: Jae Hyun Ryou, Sun Mi Kim. Writing—review and editing: Doug Hyun Han. Approval of the final manuscript: All authors.

■ ORCID

Jae Hyun Ryou <https://orcid.org/0000-0003-4637-4350>
 Doug Hyun Han <https://orcid.org/0000-0001-5888-0686>
 Reeree Lee <https://orcid.org/0000-0001-8811-3699>
 Sun Mi Kim <https://orcid.org/0000-0003-4131-0542>

REFERENCES

1. Edwards MJ, Fotopoulou A, Pareés I. *Neurobiology of functional (psychogenic) movement disorders. Curr Opin Neurol* 2013;26:442-447.
2. Fobian AD, Elliott L. *A review of functional neurological symptom disorder etiology and the integrated etiological summary model. J Psychiatry Neurosci* 2019;44:8-18.
3. Hamilton M. *A rating scale for depression. J Neurol Neurosurg Psychiatry* 1960;23:56-62.
4. Hamilton M. *The assessment of anxiety states by rating. Br J Med Psychol* 1959;32:50-55.
5. Cunningham MW, Cox CJ. *Autoimmunity against dopamine receptors in neuropsychiatric and movement disorders: a review of Sydenham chorea and beyond. Acta Physiol (Oxf)* 2016;216:90-100.
6. Tuplin EW, Holahan MR. *Aripiprazole, a drug that displays partial agonism and functional selectivity. Curr Neuropharmacol* 2017;15:1192-1207.
7. Yoo HK, Joung YS, Lee JS, Song DH, Lee YS, Kim JW, et al. *A multicenter, randomized, double-blind, placebo-controlled study of aripiprazole in children and adolescents with Tourette's disorder. J Clin Psychiatry* 2013;74:e772-e780.
8. Frank S. *Treatment of Huntington's disease. Neurotherapeutics* 2014;11:153-160.
9. Billnitzer A, Jankovic J. *Current management of tics and tourette syndrome: behavioral, pharmacologic, and surgical treatments. Neurotherapeutics* 2020;17:1681-1693.
10. Di Sciascio G, Riva MA. *Aripiprazole: from pharmacological profile to clinical use. Neuropsychiatr Dis Treat* 2015;11:2635-2647.