

Original Article
Neuroscience



Long-Term Outcome of Unilateral Acoustic Neuromas With or Without Hearing Loss: Over 10 Years and Beyond After Gamma Knife Radiosurgery

Hye Ran Park ¹, Sang Soon Jeong ², Jung Hoon Kim ², Ho Sung Myeong ², Hyun Joo Park ^{3*}, Kwang Hyon Park ⁴, Kawngwoo Park ⁵, Byung Woo Yoon ⁶, Suyeon Park ⁷, Jin Wook Kim ⁸, Hyun-Tai Chung ², Dong Gyu Kim ² and Sun Ha Paek ^{2,8,9,10}

OPEN ACCESS

Received: Jan 31, 2023

Accepted: Jun 9, 2023

Published online: Oct 12, 2023

Address for Correspondence:

Sun Ha Paek, MD, PhD

Department of Neurosurgery, Seoul National University College of Medicine, 101 Daehak-ro, Jongno-gu, Seoul 03080, Korea.

Email: paeksh@snu.ac.kr

*Current affiliation: Department of Neurosurgery, Icahn School of Medicine at Mount Sinai, New York, USA

© 2023 The Korean Academy of Medical Sciences.

This is an Open Access article distributed under the terms of the Creative Commons Attribution Non-Commercial License (<https://creativecommons.org/licenses/by-nc/4.0/>) which permits unrestricted non-commercial use, distribution, and reproduction in any medium, provided the original work is properly cited.

ORCID iDs

Hye Ran Park
<https://orcid.org/0000-0003-0506-4882>
Sang Soon Jeong
<https://orcid.org/0000-0002-8566-0117>
Jung Hoon Kim
<https://orcid.org/0000-0002-8090-7758>
Ho Sung Myeong
<https://orcid.org/0000-0002-5970-1704>
Hyun Joo Park
<https://orcid.org/0000-0003-4481-6637>
Kwang Hyon Park
<https://orcid.org/0000-0003-2386-4680>
Kawngwoo Park
<https://orcid.org/0000-0002-6568-1009>

<https://jkms.org>

¹Department of Neurosurgery, Soonchunhyang University Seoul Hospital, Seoul, Korea

²Department of Neurosurgery, Seoul National University Hospital, Seoul, Korea

³Department of Neurosurgery, Seoul National University Bundang Hospital, Seongnam, Korea

⁴Department of Neurosurgery, Chungnam National University Hospital, Daejeon, Korea

⁵Department of Neurosurgery, Gachon University Gil Medical Center, Incheon, Korea

⁶Department of Internal Medicine, School of Medicine, Chung-Ang University, Seoul, Korea

⁷Department of Biostatistics, Soonchunhyang University Seoul Hospital, Seoul, Korea

⁸Clinical Research Institute, Seoul National University Hospital, Seoul, Korea

⁹Hypoxia/Ischemia Disease Institute, Cancer Research Institute, Seoul National University College of Medicine, Seoul, Korea

¹⁰Advanced Institutes of Convergence Technology, Suwon, Korea

ABSTRACT

Background: Since the long-term outcomes of 162 patients who underwent gamma knife radiosurgery (GKS) as an initial or adjuvant treatment for acoustic neuromas (ANs) with unilateral hearing loss were first reported in 1998, there has been no report of a comprehensive analysis of what has changed in GKS practice.

Methods: We performed a retrospective study of the long-term outcomes of 106 patients with unilateral sporadic ANs who underwent GKS as an initial treatment. The mean patient age was 50 years, and the mean initial tumor volume was 3.68 cm³ (range, 0.10–23.30 cm³). The median marginal tumor dose was 12.5 Gy (range, 8.0–15.0 Gy) and the median follow-up duration was 153 months (range, 120–216 months).

Results: The tumor volume increased in 11 patients (10.4%), remained stationary in 27 (25.5%), and decreased in 68 patients (64.2%). The actuarial 3, 5, 10, and 15-year tumor control rates were 95.3 ± 2.1%, 94.3 ± 2.2%, 87.7 ± 3.2%, and 86.6 ± 3.3%, respectively. The 10-year actuarial tumor control rate was significantly lower in the patients with tumor volumes of ≥ 8 cm³ ($P = 0.010$). The rate of maintaining the same Gardner-Robertson scale grade was 28.6%, and that of serviceable hearing was 46.4%. The rates of newly developed facial and trigeminal neuropathy were 2.8% and 4.7%, respectively. The patients who received marginal doses of less than 12 Gy revealed higher tumor control failure rates ($P = 0.129$) and newly occurred facial or trigeminal neuropathy rates ($P = 0.040$ and 0.313, respectively).

Conclusion: GKS as an initial treatment for ANs could be helpful in terms of tumor control, the preservation of serviceable hearing, and the prevention of cranial neuropathy. It is recommended to perform GKS as soon as possible not only for tumor control in unilateral ANs with hearing loss but also for hearing preservation in those without hearing loss.


Keywords: Acoustic Neuroma; Radiosurgery; Outcome; Hearing

Byung Woo Yoon 

<https://orcid.org/0000-0002-8597-807X>

Suyeon Park 

<https://orcid.org/0000-0002-6391-557X>

Jin Wook Kim 

<https://orcid.org/0000-0003-0934-3344>

Hyun-Tai Chung 

<https://orcid.org/0000-0001-8243-2568>

Dong Gyu Kim 

<https://orcid.org/0000-0002-5740-6189>

Sun Ha Paek 

<https://orcid.org/0000-0003-3007-8653>

Funding

This research was partly supported by the Bio & Medical Technology Development Program of the National Research Foundation (grant No. 2015M3C7A1028926 & 2020M3A9G8022029) and the National Research Foundation of Korea Grant (grant No. NRF2017M3C7A1047392) of the Ministry of Science and ICT, Republic of Korea; and the Korea Research Institute of Bioscience and Biotechnology (KRIBB) Research Initiative Program (KGM456212109816); and Electronics and Telecommunications Research Institute (ETRI) grant funded by the Korean government [21YB1500] to Sun Ha Paek and Soonchunhyang University Research Fund.

Disclosure

The authors have no potential conflicts of interest to disclose.

Author Contributions

Conceptualization: Park HR, Kim DG, Paek SH. Data curation: Park HR, Jeong SS, Myeong HS. Formal analysis: Kim JH. Funding acquisition: Paek SH. Investigation: Park HR, Jeong SS, Kim JH. Methodology: Park HJ, Park K. Project administration: Park KH. Software: Park HR, Park HJ, Park KH, Park K, Yoon BW, Park S, Chung HT. Supervision: Yoon BW, Kim JW, Chung HT, Kim DG, Paek SH. Validation: Park S, Kim JW, Chung HT. Visualization: Kim DG. Writing - original draft: Park HR. Writing - review & editing: Park HR, Myeong HS, Paek SH.

INTRODUCTION

The most frequent causes of unilateral sensorineural hearing loss are sudden deafness, Menière's disease and cerebellopontine angle tumors. Early diagnosis of acoustic neuroma (AN) or other lesions of the internal auditory meatus or cerebello-pontine angle requires special attention.¹ In general, acoustic neuromas have a benign course and slow growth rate of 0 to 1.8 mm per year or growth arrest.²⁻⁷ Even though an AN is not a life-threatening tumor, it could compromise the quality of life by compressing or irritating the fifth, sixth, or seventh cranial nerves as well as eighth cranial nerves. Long-lasting ANs could also cause brain stem compression or hydrocephalus requiring a ventriculoperitoneal (VP) shunt.

Since an AN was first treated by radiosurgery in 1969,⁸ stereotactic radiosurgery (SRS) has shown good tumor control and low morbidity rates and has been regarded as an acceptable alternative to surgical resection for ANs. Despite the debate over the optimal treatment for ANs, SRS has become more popular due to its effectiveness and less invasiveness.^{9,10}

Since Kondziolka et al.¹¹ first reported the long-term outcome of 162 patients who underwent gamma knife radiosurgery (GKS) as an initial or adjuvant treatment for acoustic neuromas in 1998, there has been no report of a comprehensive analysis of what has changed in GKS practice and the long-term outcomes of patients with ANs. The aim of this study was to retrospectively evaluate the very long-term outcomes of patients who underwent GKS for ANs in single institution, including the tumor control rates, hearing preservation, and associated complications, and provide a literature review.

METHODS

Patients

Between December 1997 and December 2004, 272 patients with ANs underwent 285 GKS sessions at the Gamma Knife Center. To investigate the outcome of GKS as an initial treatment option for AN, 98 patients who had previously undergone surgical resection or radiation were excluded. Twenty-six patients diagnosed with neurofibromatosis type II and 47 patients with clinical follow-up periods of less than 10 years were excluded. The remaining 106 patients who had unilateral sporadic ANs and no previous history of surgical resection or radiation were enrolled in this retrospective study.

The mean patient age was 50 years (range, 21–76 years). There were 48 men (45.3%) and 58 women (54.7%). The mean clinical follow-up duration was 153 ± 23 months (median, 148 months; range, 120–216 months). The most common initial presentation was hearing difficulty (69 patients, 65.1%), followed by tinnitus (53 patients, 50.0%), dizziness (23 patients, 21.7%), headache (22 patients, 20.8%), facial paresthesia (10 patients, 9.4%), facial hypesthesia (9 patients, 9.3%), facial palsy (2 patients, 1.9%), and hemifacial spasm (2 patients, 1.9%). Two patients with facial palsy had complete hearing loss and there was no image finding suggestive a facial nerve schwannoma. ANs were incidentally found without clinical symptoms in 3 patients (2.8%). Twenty-five patients (23.6%) had tumors confined to the internal auditory canal (IAC), 12 patients (11.3%) harbored cerebellopontine angle (CPA) cisternal tumors, and 69 patients (65.1%) had tumors occupying both the IAC and CPA cistern. The authors classified all tumors by the tumor component; 89 patients (84.0%) had solid-only tumors, and 17 patients (16.0%) had cystic mixed components. The mean initial tumor volume was 3.68 ± 4.42 cm³ (range, 0.10–23.30 cm³).

Of the 106 patients enrolled in this study, 56 (52.8%) had serviceable hearing based on Gardner Robertson (G-R) scale grades; 32 patients had G-R grade I, and 24 patients had G-R grade II.¹² Seventeen patients with G-R grade III, 3 patients with G-R grade IV, and 30 patients with G-R grade V were classified into the non-serviceable hearing group.

Stereotactic radiosurgery

Radiosurgery was performed on the patients under local anesthesia, supplemented with intravenous sedation. Patients were treated using the Leksell Gamma Knife (model B or C, Elekta Instrument AB) with the Leksell Gamma Plan (Elekta, Stockholm, Sweden). The median marginal tumor dose was 12.5 Gy (range, 8.0–15.0 Gy), the median covered ratio was 94% (range, 90–99%), and the isodose line for the tumor margin varied from 45% to 50% (median isodose line 50%). The mean dose and maximal dose to cochlea was 3.60 ± 2.60 Gy and 7.95 ± 2.60 Gy, respectively. And, the mean dose and maximal dose to cochlear nucleus was 4.64 ± 2.46 Gy and 9.17 ± 2.90 Gy, respectively.

Follow-up and outcome analysis

Patients underwent follow-up clinical evaluations 1, 3, 6, and 12 months after SRS and annually thereafter. Magnetic resonance imaging (MRI) was performed 6, 12, 18, and 24 months after GKS, then biannually thereafter. The radiologic volume status of the tumors was determined by the percentage ratio of the last follow-up tumor volume to the initial volume, and classified as increased ($\geq 120\%$), stationary (80–120%), or decreased ($< 80\%$).

Statistical analysis

The tumor control rate was established using the Kaplan-Meier product-limit method. Differences were assessed using the log-rank test, and statistical significance was accepted at $P < 0.050$. Stepwise backward multivariate analysis was performed using the Cox proportional hazard function, and $P < 0.050$ was considered statistically significant. All statistical analyses were performed with the SPSS statistical software package (version 22.0; IBM Corp., Armonk, NY, USA).

Ethics statement

This retrospective study was approved by the Institutional Review Board of Seoul National University Hospital (IRB No. 1704-111-847) and conformed to the principles of the Declaration of Helsinki. Informed consent was waived because of the retrospective design of the study and anonymous clinical data.

RESULTS

Tumor control

All 106 patients enrolled in this study were alive at the point of this study. The MRI volumetric assessment results at the time of the last follow-up were as follows: volume increased in 11 patients (10.4%), remained stationary in 27 (25.5%), and decreased in 68 patients (64.2%). The actuarial 3-, 5-, 10-, 15-year tumor control rates were $95.3 \pm 2.1\%$, $94.3 \pm 2.2\%$, $87.7 \pm 3.2\%$, and $86.6 \pm 3.3\%$, respectively (Fig. 1).

There was no statistically significant prognostic factor correlated with tumor control failure in either the uni- or multivariate analyses (Supplementary Table 1).

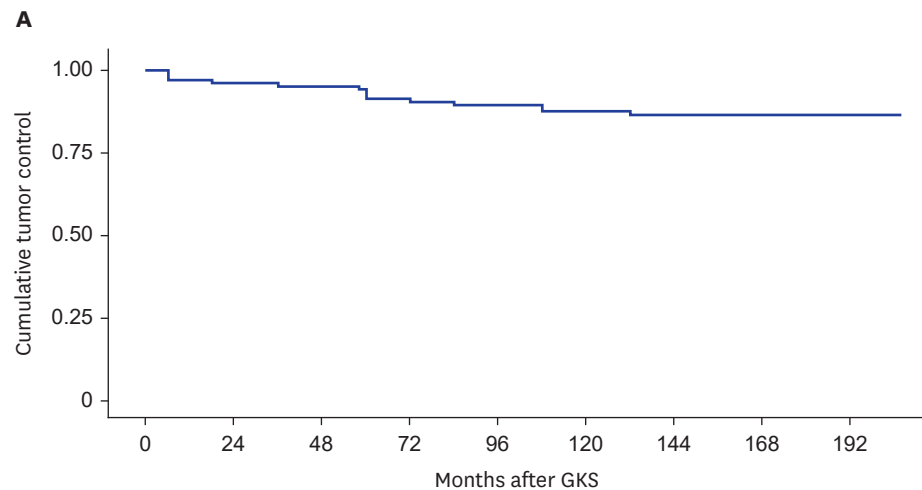
Within 24 months after GKS, an immediate tumor volume expansion of more than 120% compared to the initial volume was observed in 35 patients (33.3%). The median interval between GKS and the occurrence of tumor volume expansion occurrence was 6 months (range, 6–24 months), and the mean rate of volume expansion was 148.9% (range, 120.51–559.5%). About 60% of the patients showed a central loss of contrast enhancement in the MRI at 3- or 6-month follow-ups (**Supplementary Table 2**). We could not find significant correlation between changes in contrast enhancement and tumor control ($P = 0.913$).

Hearing preservation

Fifty-six patients (52.8%) had serviceable hearing before GKS; 32 patients had G-R scale I and 24 patients had G-R scale II. The hearing outcome was determined by G-R scale grades at the final follow-up visit. Of the 56 patients who had serviceable hearing at the time of GKS, 16 patients (28.6%) maintained the same G-R scale grade, 26 patients (46.4%) maintained serviceable hearing, and 40 patients (71.4%) experienced hearing deterioration defined as a PTA increase of ≥ 20 dB. The G-R scale grade at baseline and the last follow-up visit are described in **Table 1** and **Supplementary Fig. 1**. There was no statistically significant difference in cochlear dose at the time of GKS between the serviceable hearing preservation group (mean \pm SD, 4.50 ± 2.21 Gy) and the loss group (4.87 ± 2.95 Gy, $P = 0.569$).

Facial neuropathy

Both of the two patients who experienced facial neuropathy expressed as facial palsy before GKS experienced an improvement in facial palsy with a decline in the House-Brackmann (H-B) facial nerve grade. Over the follow-up periods after GKS, the facial nerve preservation rate was 97.2%. Three patients (2.8%) experienced newly developed facial neuropathy. The tumor



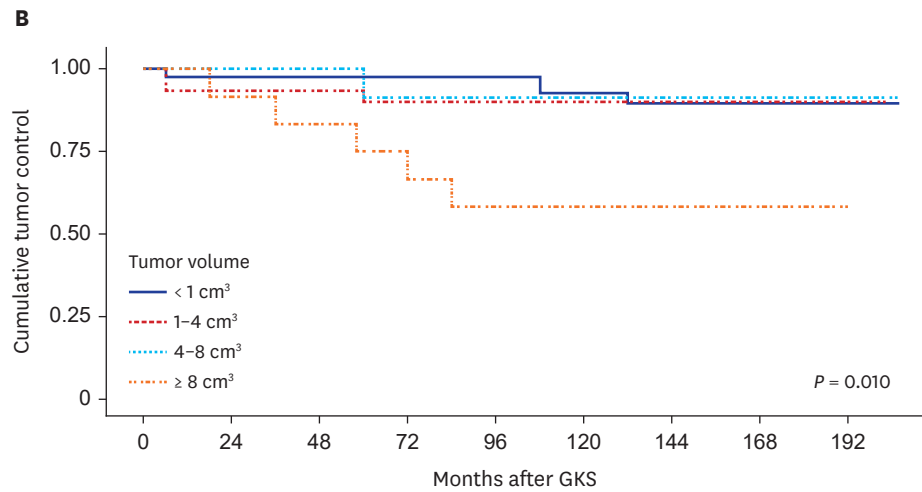
No. at risk

All 106 102 101 97 95 91 56 20 7

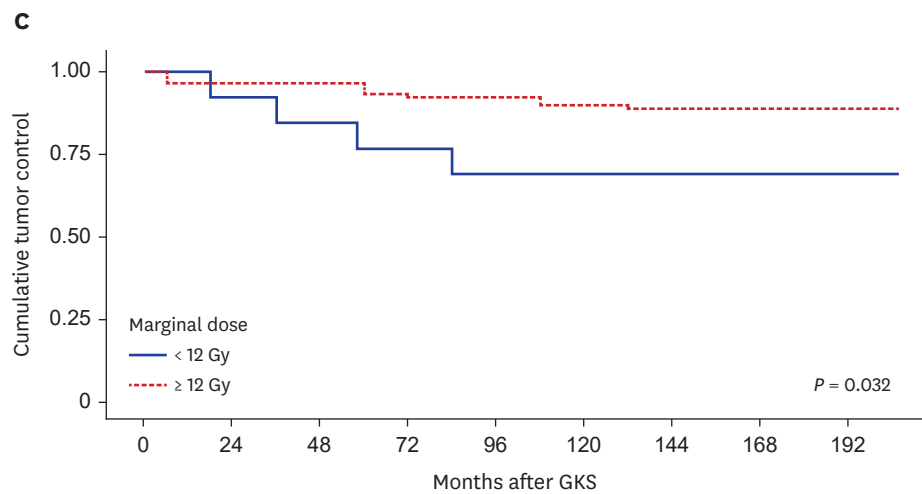
Fig. 1. Cumulative tumor control rates after GKS. **(A)** Cumulative tumor control rates of all 106 patients. The actuarial 3, 5, 10, and 15-year tumor control rates were $95.3 \pm 2.1\%$, $94.3 \pm 2.2\%$, $87.7 \pm 3.2\%$, and $86.6 \pm 3.3\%$, respectively. **(B)** Cumulative tumor control rates stratified into 4 groups according to the initial tumor volume. The 10-year actuarial tumor control rates were $92.7 \pm 4.1\%$, $90.0 \pm 5.5\%$, $91.3 \pm 5.9\%$, and $58.3 \pm 14.2\%$ in the patient group with initial tumor volumes of $< 1 \text{ cm}^3$, $1\text{--}4 \text{ cm}^3$, $4\text{--}8 \text{ cm}^3$ and $\geq 8 \text{ cm}^3$, respectively ($P = 0.010$). **(C)** Cumulative tumor control rates stratified into 2 groups according to marginal dose. The 10-year actuarial tumor control rates were $69.2 \pm 12.8\%$ and $90.3 \pm 3.1\%$ in the patient group with initial marginal doses of < 12 Gy and ≥ 12 Gy, respectively ($P = 0.032$).

GKS = gamma knife radiosurgery.

(continued to the next page)



No. at risk									
< 1 cm ³	41	40	40	40	40	37	19	6	2
1-4 cm ³	30	28	28	27	27	26	19	9	2
4-8 cm ³	23	23	23	21	21	21	13	4	2
≥ 8 cm ³	12	11	10	9	7	7	5	1	1



No. at risk									
< 12 Gy	13	12	11	10	9	9	8	4	3
≥ 12 Gy	93	90	90	87	86	82	48	16	4

Fig. 1. (Continued) Cumulative tumor control rates after GKS. **(A)** Cumulative tumor control rates of all 106 patients. The actuarial 3, 5, 10, and 15-year tumor control rates were $95.3 \pm 2.1\%$, $94.3 \pm 2.2\%$, $87.7 \pm 3.2\%$, and $86.6 \pm 3.3\%$, respectively. **(B)** Cumulative tumor control rates stratified into 4 groups according to the initial tumor volume. The 10-year actuarial tumor control rates were $92.7 \pm 4.1\%$, $90.0 \pm 5.5\%$, $91.3 \pm 5.9\%$, and $58.3 \pm 14.2\%$ in the patient group with initial tumor volumes of $< 1 \text{ cm}^3$, $1-4 \text{ cm}^3$, $4-8 \text{ cm}^3$ and $\geq 8 \text{ cm}^3$, respectively ($P = 0.010$). **(C)** Cumulative tumor control rates stratified into 2 groups according to marginal dose. The 10-year actuarial tumor control rates were $69.2 \pm 12.8\%$ and $90.3 \pm 3.1\%$ in the patient group with initial marginal doses of $< 12 \text{ Gy}$ and $\geq 12 \text{ Gy}$, respectively ($P = 0.032$). GKS = gamma knife radiosurgery.

volume of the patients who experienced newly developed facial neuropathy was significantly larger than that of the patients without further facial neuropathy ($9.44 \pm 9.34 \text{ cm}^3$ vs. $3.57 \pm 4.19 \text{ cm}^3$, $P = 0.023$). The marginal doses of each patient were 9, 12, and 12 Gy, and the doses were not higher than those of other patients. Only 1 of 3 patients had transient volume enlargement, but the tumor eventually shrank and was controlled.

Table 1. G-R scale before and after GKS

Hearing status before GKS	Before GKS		After GKS		Hearing outcome
	G-R scale	No.	G-R scale	No.	
Serviceable (n = 56)	I	32	I	10	Same G-R
			II	10	
			III	11	
	II	24	IV	1	Serviceable hearing loss
			II	6	Same G-R
			III	17	Serviceable hearing loss
Non-serviceable (n = 52)	III	17	IV	1	Serviceable hearing loss
			IV	2	Serviceable hearing loss
			V	4	Serviceable hearing loss
	IV	3	III	11	Same G-R
			IV	1	Same G-R
			V	2	Same G-R
V	30	V	30	Same G-R	

The hearing outcome was determined by G-R scale at the final follow-up visit. Of the 56 patients who had serviceable hearing at the time of GKS, 16 patients (28.6%) maintained the same G-R scale, 26 patients (46.4%) maintained serviceable hearing, and 40 patients (71.4%) suffered hearing deterioration defined as PTA increase \geq 20 dB. This table describes the G-R scale at baseline and the last follow-up visit. We subdivided 56 patients who had pre-GKS serviceable hearing into four groups according to the pure tone average: \leq 10 dB (n = 3), 10–20 dB (n = 12), 20–30 dB (n = 17), and 30–50 dB (n = 24). There was a significant difference in the G-R scale of the patients in each group after GKS ($P = 0.004$). As described in Fig. 2, among the patients who had serviceable hearing with pure tone average of 20 dB or less before GKS, 10 out of 15 (66.7%) maintained serviceable hearing of G-R scale I or II. However, 10 out of 17 patients (58.8%) in the patients with pure tone average 20–30 dB and 6 out of 24 (25.0%) in the patients with 30–50 dB maintained serviceable hearing. Even within the group of patients who had the same serviceable hearing before GKS, the higher the remaining hearing, the higher the serviceable hearing preservation rate.

G-R = Gardner Robertson, GKS = gamma knife radiosurgery.

Trigeminal neuropathy

Nineteen patients (17.9%) had trigeminal neuropathy such as paresthesia (10 patients) and hypesthesia (9 patients) before GKS. Of the 10 patients presenting with paresthesia, 5 patients (50.0%) obtained symptom relief, and 5 patients (50.0%) remained stationary after GKS. The trigeminal nerve preservation rate after GKS was 94.3%. Trigeminal neuropathy was newly developed in 5 patients (5.7%), with hypesthesia in 3 patients, and paresthesia in 2 patients. Transient volume enlargement occurred in 2 of 5 patients, but tumors were controlled in all 5 patients. The mean initial tumor volume of the patients who experienced newly developed trigeminal neuropathy was significantly larger than that of the patients without further trigeminal neuropathy ($9.71 \pm 10.73 \text{ cm}^3$ vs $2.46 \pm 2.71 \text{ cm}^3$, $P < 0.001$).

Hydrocephalus associated with acoustic neuroma

At the time of the GKS, 5 patients (4.7%) presented with hydrocephalus defined as an Evans ratio of > 0.3 . Four of them displayed hydrocephalus-related symptoms, and 2 of them received a VP shunt for cerebrospinal fluid (CSF) diversion before radiosurgery. Newly developed hydrocephalus over the follow-up periods was discovered in 5 patients (4.9%). Two patients required a VP shunt for symptom-related hydrocephalus. The interval time between GKS and placement of the VP shunts was 3 and 12 years, respectively.

Delayed cyst formation

Of the 89 patients who had solid tumors, 7 patients (7.9%) experienced delayed cyst formation over the follow-up periods; intratumoral cysts developed in 6 patients and an extratumoral cyst in 1 patient (Supplementary Fig. 2). The median interval time between GKS and cyst formation was 6 months (range, 6–60 months). Five patients received close observation for cysts, and 2 patients underwent surgical resection 58 and 84 months after GKS, respectively.

Salvage treatment

After GKS, 8 patients required additional treatments. There were 6 cases of surgical resection due to uncontrollable tumor growth, and 2 cases of VP shunt for hydrocephalus causing associated symptoms. The median interval between GKS and further surgical resection of the 6 patients who underwent surgical resections was 66 months (range, 18–132 months). The histological diagnosis was compatible with schwannoma in all 6 patients.

DISCUSSION

The actuarial tumor control rates in this study were 94.3% at 5 years and 87.7% at 10 years, which was consistent with previous reports.

In the tumor control group, all tumors were decreased, which is plotted in Fig. 2A. Based on this plot, we proposed a formula that could predict the change in tumor volume after the first 2 years after SRS using linear regression analysis. Using this formula, the approximate percent change in tumor volume (y) at t months after SRS can be predicted: $y(t) = 100 - 0.471t$.

We also plotted the tumor volume of all 126 patients including tumor control failure group and patients with imaging follow-up of at least 2 years, who were excluded from this study because of the follow-up period of less than 10 years (Fig. 2B). Of the 14 patients with tumor

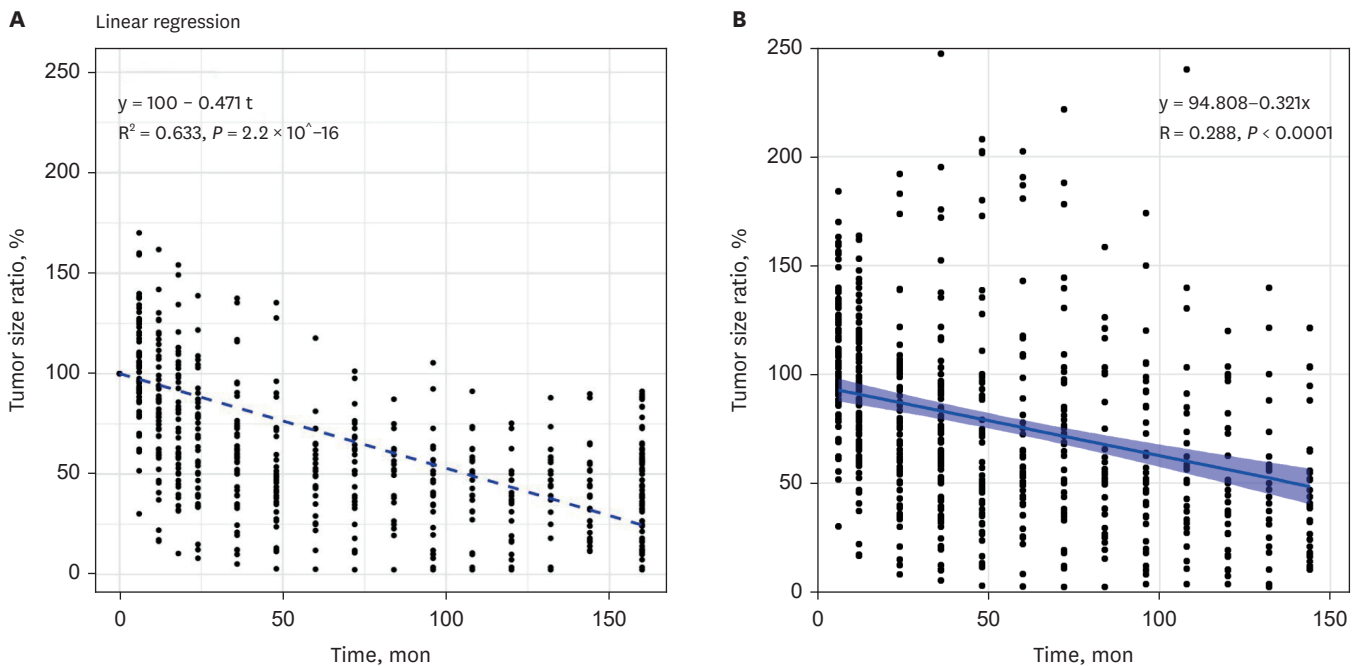


Fig. 2. Chronological tumor volume plotting. **(A)** Tumor volume plotting of the tumor control group. GKS treatment not only prevented tumor growth but also gradually induced tumor volume shrinkage over time after GKS, resulting in an average of about 60% after 150 months compared to 100% of the tumor volume at the time of GKS. In the first 2 years, the tumor was temporarily swollen due to the vascular insult caused by radiation, making it difficult to predict, but after 2 years it was generally consistent with the change in tumor volume. We proposed a formula that could predict the change in tumor volume after the first 2 years after SRS using linear regression analysis. Using this formula, the approximate percent change in tumor volume (y) at t months after SRS could be predicted as shown in this figure: $y(t) = 100 - 0.471t$. **(B)** Tumor volume plotting of all 126 patients with imaging follow-up of at least 2 years. As the subjects of this study included patients who had been followed for more than 10 years, bias may occur due to study design. To overcome this, this figure represents tumor volume plotting of all 126 patients who were clinically followed for less than 10 years, if they underwent follow-up image for at least 2 years. GKS = gamma knife radiosurgery, SRS = stereotactic radiosurgery.

control failure in this study, 6 patients experienced sudden tumor volume enlargement in the late periods between 5 and 11 years after GKS. We recommend more than 5 years of imaging follow-up to assess the tumor control outcomes in patients with AN after GKS.

We found that tumor volume expansion occurred within 24 months after GKS in 33.3% of the patients. The incidence rates of transient volume expansion vary from 5% to 39% in the literature review, and expansion is known to persist until 24–30 months after GKS.¹³⁻²⁰ Of the 35 patients with volume expansion after GKS in this study, 28 patients (80%) eventually obtained tumor control, and 7 patients (20%) experienced sustained tumor growth (**Supplementary Fig. 3**). Of the 7 patients with continuous tumor growth, one patient underwent surgical resection due to increased tumor volume associated with relevant symptoms. Another one patient has been under close observation without surgery due to old age and comorbidities despite the deterioration of dizziness, and the remaining 5 patients have been under close observation without any associated symptoms.

Although the risks of other cranial nerve neuropathies after GKS were dramatically decreased, the risk of serviceable hearing preservation still ranged between 40% and 70%.^{21,22} Because of the earlier use of higher-quality MRI followed by an increasing number of patients with useful or normal hearing, hearing preservation has become a more important issue.

In this study, the rates of maintaining the same G-R scale grade and preserving serviceable hearing were 28.6% and 46.4%, respectively, after GKS with a median tumor marginal dose of 12.5 Gy. And the lower the pure tone average before GKS, the higher the rate of maintaining serviceable hearing after GKS. In a follow-up study without treatment, the average annual hearing loss speed was 2.3 dB/year.²³ Other studies comparing observation and surgical intervention recommend active therapy rather than observation in terms of hearing preservation.^{24,25}

Since the Pittsburgh group investigated the superiority of low dose of 12–13 Gy compared to high doses of 16 Gy or more, GKS for AN with 12–13 Gy has provided high rates of tumor control and low rates of serviceable hearing loss and cranial nerve neuropathy occurrence.^{26,27} The factors we considered for GKs planning were mainly tumor volume and serviceable hearing preservation. In most cases where the tumors were not very large, a marginal dose of 12 Gy was prescribed. If there is no serviceable hearing on the tumor side, 13 Gy was prescribed to obtain satisfactory tumor control. In cases with large tumor size and serviceable hearing, a marginal dose of 12 Gy or less was prescribed for serviceable hearing preservation. To investigate the optimal dose for ANs, we stratified the tumor marginal dose into 5 classes (< 12 Gy, 12 Gy, 12.5 Gy, 13 Gy, and > 13 Gy) and compared the tumor control rates, serviceable hearing preservation rates, and cranial neuropathy occurrence rates. As shown in **Supplementary Table 3**, patients who received marginal doses of less than 12 Gy revealed higher tumor control failure rates ($P = 0.129$) and newly occurred facial or trigeminal neuropathy rates ($P = 0.040$ and $P = 0.313$, respectively).

Recently published studies have shown that biologically effective dose (BED), rather than absolute dose, has a significant correlation with clinical outcomes including hearing preservation and tumor control rates.^{49,50} By accounting for various factors, including the total radiation dose, the fractionation scheme, and the tumor's radiobiological parameters, the BED aims to provide a more accurate estimation of the biological effectiveness of a radiation treatment. When determining the optimal dose, it is necessary to refer to recent research results on BED.

After Kondziolka et al.¹¹ demonstrated long-term outcomes after radiosurgery for acoustic tumors in 1998, radiosurgery has emerged as an alternative treatment for microsurgery, especially for intracanalicular or small- or medium-sized tumors. Since then, the number of radiosurgical cases for ANs has increased steadily every year. According to data suggested by Elekta, ANs accounted for about 8.8% of all GKS cases in 2019, and the number of cumulative patients who received GKS with AN increased by 11.7 times from 10,730 in 1998 to 125,710 in 2019.

Table 2 summarizes the literature reporting the long-term outcomes of radiosurgery for AN. Compared to the first report by the Kondziolka group,¹¹ there has been a change in the trend of radiosurgery for ANs. Although the marginal dose has gradually decreased from 16–17 Gy at the beginning to 12–13 Gy now, the tumor control rate was maintained at above 95% in most studies. Because the marginal dose was reduced, facial and trigeminal nerve preservation was better than before, but the hearing preservation rate did not change significantly.

To reiterate the role of radiosurgery in ANs, a meta-analysis comparing radiosurgery and microsurgery as a primary treatment for small- to medium-sized sporadic ANs was conducted, which showed that although the tumor control rate was better in the microsurgery group, the facial nerve and hearing preservation outcomes and quality of life were superior in the radiosurgery group.⁵¹

Table 2. Prior studies reporting long-term outcomes of GKS for ANs

Author	Year	n	Median follow-up, yr	Median marginal dose, Gy	Median volume, mL	Local control rates	Serviceable hearing preservation rate	Trigeminal nerve preservation	Facial nerve preservation
Flickinger et al. ²⁸	1993	134	2	17	2.75	89.2% (4 yr)	35.1% (5 yr)	32.9%	71%
Kondziolka et al. ¹¹	1998	162	5–10	16	Mean diameter 22 mm	98%	47%	73%	79%
Flickinger et al. ²⁹	2001	190	2.5	13	2.7	97.1% (5 yr)	71% (5 yr)	97.4%	98.9%
Flickinger et al. ³⁰	2004	313	2	13	1.1	98.6% (5 yr)	70.3% (5 yr)	95.6%	
Lunsford et al. ³¹	2005	252	> 10	13	2.5	98% (5 yr) 98% (10 yr)	79% (5 yr)	96.9%	99%
Chung et al. ³²	2005	195	2.6		4.1 (mean)	96.8% (5 yr)	60% (5 yr)	99%	100%
Myrseth et al. ³³	2005	103	3	12.2	NA	93%	32%	94.8%	
Chopra et al. ³⁴	2007	216	5.7	13	1.3	98.3% (10 yr)	44%	100%	94.9%
Regis et al. ³⁵	2008	184	3	(Lower than 13)			60% (3 yr)		
Yang et al. ³⁶	2009	65	3			87% (5 yr)	82% (2 yr)	94%	98%
Tamura et al. ³⁷	2009	74	4	12		93%	78%	NR	
Regis et al. ³⁸	2010	34	2.9			97%	77% (64% at 5 years)	NR	
Murphy et al. ³⁹	2011	103	3.6	13	1.95	91.5% (5 yr) (91.1)	NA (84.6% 5 yr)	95%	99%
Breivik et al. ⁴⁰	2013	113	4.6			NR	36%	NR	
Kim et al. ⁴¹	2013	60	5.2	12.2	0.34 (mean)	100%	57%	NR	
Carlson et al. ⁴²	2013	44	9.3			97% (5 yr)	55% (5 yr)	96.4%	95.6%
Hasegawa et al. ⁴³	2013	427	12.5	12.8	2.8	92% (5 yr) 91% (10 yr)	43% (5 yr)	99%	99%
Boari et al. ⁴⁴	2014	379	5.8	13	1.94 (mean)	97.1%	49%	96%	98.7%
Jacob et al. ⁴⁵	2014	59	2.1			95%	96%	100%	100%
Bir et al. ⁴⁶	2014	82	5			95% (5 yr) 95% (10 yr)	83% (5 yr)	96%	
Watanabe et al. ⁴⁷	2016	183	9.5	12	2.0	96% (5 yr) 93% (10 yr)	49% (5 yr)	97%	98.9%
Bowden et al. ⁴⁸	2017	219	4.1	12.5	2.6	96.4%	61.5%		91.8%
This study	-	106	12.7	12.5	3.68	95.3% (5 yr) 94.3% (10 yr)	46.4%	95.3%	97.2%

Table 2 summarizes the literature reporting the long-term outcome of radiosurgery for AN. Compared to the first report of the Kondziolka group,¹¹ there has been a change in the trend of radiosurgery for ANs. Although the marginal dose was gradually decreased from 16–17 Gy at the beginning to 12–13 Gy now, the tumor control rate has been maintained above 95% in most studies. Because the marginal dose was reduced, the facial and trigeminal nerve preservation was better than before, but the hearing preservation rate did not change significantly.

GKS = gamma knife radiosurgery, AN = acoustic neuroma, NA = not applicable, NR = not reported.

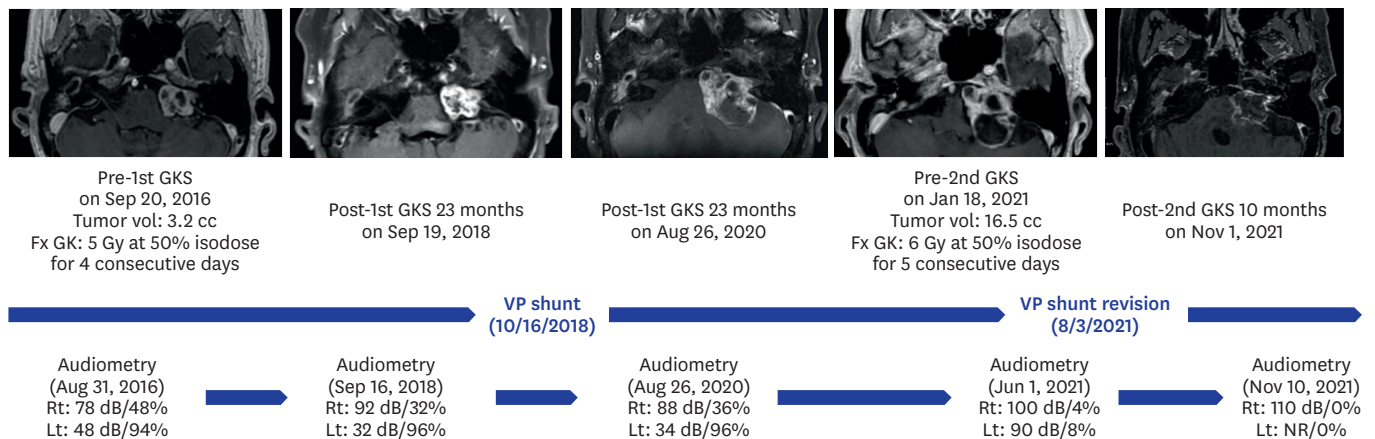


Fig. 3. Case of one patient who underwent FGKS using a frame for AN. We implemented FGKS using a frame before the introduction of ICON™. This case represents one of the patients who underwent FGKS for an AN. An adult patient with a left AN of 3.2 mL underwent FGKS at a marginal dose of 5 Gy per fraction for 4 consecutive days. Afterward, an additional ventriculoperitoneal shunt was required for progressive hydrocephalus. After 52 months, the second stage of FGKS was performed with a marginal dose of 6 Gy per fraction for 5 consecutive days. The ten-month follow-up MRI confirmed that shrinkage occurred along with necrosis inside the tumor.
 FGKS = fractionated gamma knife radiosurgery, AN = acoustic neuroma, MRI = magnetic resonance imaging, VP = ventriculoperitoneal.

The remaining controversy in presenting GKS as a primary treatment for AN is as an alternative for the management of large-sized ANs and better hearing preservation. We can consider the inclusion of brain MRI with audiometry in the health screenings of people over 40 for early diagnosis before the onset of hearing loss. Subtotal resection with functional preservation followed by GKS or fractionated GKS (FGKS) can be suggested as an alternative for the treatment of large-sized ANs (Fig. 3). With the recent introduction of ICON™, clinical experience with frameless FGKS is gradually accumulating, and dose optimization may be done using the accumulated results in the near future.

This study included patients who underwent very long-term follow-up compared to previous studies. However, this study had some drawbacks. One of them is the retrospective study design; the information that could be obtained from medical records was limited. In addition, selection bias could have occurred since only patients with more than 10 years of follow-up were included. More systematic studies under prospective control are required.

In conclusion, GKS as an initial treatment for small ANs that are detected early could be helpful in terms of tumor control, the preservation of serviceable hearing, and the prevention of cranial neuropathy, which can be the rationale for early GKS for ANs. Better treatment outcome of GK SRS can be expected, when the size of the AN is small and the hearing is preserved. It is recommended to perform GKS as soon as possible not only for tumor control in unilateral ANs with hearing loss but also for hearing preservation in those without hearing loss.

SUPPLEMENTARY MATERIALS

Supplemental Table 1

Analysis of factors related with tumor control failure and serviceable hearing loss

[Click here to view](#)

Supplementary Table 2

Comparison of tumor control and serviceable hearing preservation according to central loss of contrast enhancement of the tumor

[Click here to view](#)

Supplementary Table 3

Tumor control failure, serviceable hearing loss, and newly developed cranial neuropathy according to marginal dose

[Click here to view](#)

Supplementary Fig. 1

Gardner-Robertson scale grade after gamma knife radiosurgery according to the pre-radiosurgical pure tone average. The dB on the vertical axis represents the hearing level before GKS, and the numbers (%) in the horizontal axis indicate the hearing level after GKS in each group. Among the patients who had serviceable hearing with a pure tone average of 20 dB or less before GKS, 10 out of 15 (66.7%) maintained serviceable hearing of G-R scale grade I or II. However, 10 out of 17 patients (58.8%) with pure tone averages of 20–30 dB and 6 out of 24 (25.0%) patients with 30–50 dB maintained serviceable hearing. Within the group of patients who had the same serviceable hearing before GKS, the higher the remaining hearing, the higher the serviceable hearing preservation rate.

[Click here to view](#)

Supplementary Fig. 2

Delayed cyst formation. Of the 89 patients who had solid tumors, 7 patients (7.9%) experienced delayed cyst formation over the follow-up periods. Intratumoral cysts developed in 6 patients and an extratumoral cyst developed in 1 patient. The median interval time between GKS and cyst formation was 6 months (range, 6–60 months). Five patients received close observation for cysts, and 2 patients underwent surgical resections 58 and 84 months after GKS, respectively. The mean initial tumor volume of the patients who experienced delayed cyst formation was statistically significantly higher than that of the patients without delayed cyst formation ($10.82 \pm 7.48 \text{ cm}^3$ vs. $2.81 \pm 3.62 \text{ cm}^3$, $P = 0.000$). However, there was no significant correlation between delayed cyst formation and serviceable hearing preservation ($P = 1.000$).

[Click here to view](#)

Supplementary Fig. 3

Mean volume of the tumors of the 35 patients who experienced transient volume expansion separated into tumor control ($n = 28$) and tumor control failure ($n = 7$). Of the 35 patients with volume expansion after GKS in this study, 28 patients (80.0%) obtained tumor control eventually, and 7 patients (20.0%) experienced sustained tumor growth. It would be helpful if transient volume expansion or sustained tumor growth could be predictable when the tumor volume is increased in the early follow-up period after GKS. The serial tumor volumes were compared between the tumor control and tumor control failure groups. There was a significant difference at 12 months after GKS (143.9% vs. 106.8%, $P = 0.032$). The volume expansion between 6 and 12 months after GKS should not be regarded as a tumor control

failure. However, further treatment should be considered if the tumor volume is not stabilized until 24 months after GKS.

[Click here to view](#)

REFERENCES

1. Oyler RF, Oyler AL, Matkin ND. Unilateral hearing loss: demographics and educational impact. *Lang Speech Hear Serv Sch* 1988;19(2):201-10.
[CROSSREF](#)
2. Charabi S, Tos M, Thomsen J, Charabi B, Mantoni M. Vestibular schwannoma growth--long-term results. *Acta Otolaryngol Suppl* 2000;543(543):7-10.
[PUBMED](#) | [CROSSREF](#)
3. Deen HG, Ebersold MJ, Harner SG, Beatty CW, Marion MS, Wharen RE, et al. Conservative management of acoustic neuroma: an outcome study. *Neurosurgery* 1996;39(2):260-4.
[PUBMED](#) | [CROSSREF](#)
4. Hoistad DL, Melnik G, Mamikoglu B, Battista R, O'Connor CA, Wiet RJ. Update on conservative management of acoustic neuroma. *Otol Neurotol* 2001;22(5):682-5.
[PUBMED](#) | [CROSSREF](#)
5. Tschudi DC, Linder TE, Fisch U. Conservative management of unilateral acoustic neuromas. *Am J Otol* 2000;21(5):722-8.
[PUBMED](#)
6. Walsh RM, Bath AP, Bance ML, Keller A, Tator CH, Rutka JA. The natural history of untreated vestibular schwannomas. Is there a role for conservative management? *Rev Laryngol Otol Rhinol (Bord)* 2000;121(1):21-6.
[PUBMED](#)
7. Son EI, Kim IM, Kim SP. Vestibular schwannoma with malignant transformation: a case report. *J Korean Med Sci* 2001;16(6):817-21.
[PUBMED](#) | [CROSSREF](#)
8. Hirsch A, Norén G. Audiological findings after stereotactic radiosurgery in acoustic neurinomas. *Acta Otolaryngol* 1988;106(3-4):244-51.
[PUBMED](#) | [CROSSREF](#)
9. Lee WJ, Lee JI, Choi JW, Kong DS, Nam DH, Cho YS, et al. Optimal volume of the residual tumor to predict long-term tumor control using stereotactic radiosurgery after facial nerve-preserving surgery for vestibular schwannomas. *J Korean Med Sci* 2021;36(16):e102.
[PUBMED](#) | [CROSSREF](#)
10. Kim KM, Park CK, Chung HT, Paek SH, Jung HW, Kim DG. Long-term outcomes of gamma knife stereotactic radiosurgery of vestibular schwannomas. *J Korean Neurosurg Soc* 2007;42(4):286-92.
[PUBMED](#) | [CROSSREF](#)
11. Kondziolka D, Lunsford LD, McLaughlin MR, Flickinger JC. Long-term outcomes after radiosurgery for acoustic neuromas. *N Engl J Med* 1998;339(20):1426-33.
[PUBMED](#) | [CROSSREF](#)
12. Gardner G, Robertson JH. Hearing preservation in unilateral acoustic neuroma surgery. *Ann Otol Rhinol Laryngol* 1988;97(1):55-66.
[PUBMED](#) | [CROSSREF](#)
13. Norén G. Long-term complications following gamma knife radiosurgery of vestibular schwannomas. *Stereotact Funct Neurosurg* 1998;70 Suppl 1:65-73.
[PUBMED](#) | [CROSSREF](#)
14. Yang I, Sughrue ME, Han SJ, Fang S, Aranda D, Cheung SW, et al. Facial nerve preservation after vestibular schwannoma Gamma Knife radiosurgery. *J Neurooncol* 2009;93(1):41-8.
[PUBMED](#) | [CROSSREF](#)
15. Delsanti C, Tamura M, Galanaud D, Régis J. Changing radiological results, pitfalls and criteria of failure. *Neurochirurgie* 2004;50(2-3 Pt 2):312-9.
[PUBMED](#)
16. Pollock BE. Management of vestibular schwannomas that enlarge after stereotactic radiosurgery: treatment recommendations based on a 15 year experience. *Neurosurgery* 2006;58(2):241-8.
[PUBMED](#) | [CROSSREF](#)

17. Kwon Y, Khang SK, Kim CJ, Lee DJ, Lee JK, Kwun BD. Radiologic and histopathologic changes after Gamma Knife radiosurgery for acoustic schwannoma. *Stereotact Funct Neurosurg* 1999;72 Suppl 1:2-10.
[PUBMED](#) | [CROSSREF](#)
18. Nakamura H, Jokura H, Takahashi K, Boku N, Akabane A, Yoshimoto T. Serial follow-up MR imaging after gamma knife radiosurgery for vestibular schwannoma. *AJNR Am J Neuroradiol* 2000;21(8):1540-6.
[PUBMED](#)
19. Norén G, Greitz D, Hirsch A, Lax I. Gamma knife surgery in acoustic tumours. *Acta Neurochir Suppl (Wien)* 1993;58:104-7.
[PUBMED](#) | [CROSSREF](#)
20. Yu CP, Cheung JY, Leung S, Ho R. Sequential volume mapping for confirmation of negative growth in vestibular schwannomas treated by gamma knife radiosurgery. *J Neurosurg* 2000;93 Suppl 3:82-9.
[PUBMED](#) | [CROSSREF](#)
21. Iwai Y, Yamanaka K, Shiotani M, Uyama T. Radiosurgery for acoustic neuromas: results of low-dose treatment. *Neurosurgery* 2003;53(2):282-7.
[PUBMED](#) | [CROSSREF](#)
22. Flickinger JC, Kondziolka D, Niranjan A, Maitz A, Voynov G, Lunsford LD. Acoustic neuroma radiosurgery with marginal tumor doses of 12 to 13 Gy. *Int J Radiat Oncol Biol Phys* 2004;60(1):225-30.
[PUBMED](#) | [CROSSREF](#)
23. Sakamoto T, Fukuda S, Inuyama Y. Hearing loss and growth rate of acoustic neuromas in follow-up observation policy. *Auris Nasus Larynx* 2001;28 Suppl:S23-7.
[PUBMED](#) | [CROSSREF](#)
24. Zanoletti E, Mazzoni A, d'Avella D. Hearing preservation in small acoustic neuroma: observation or active therapy? Literature review and institutional experience. *Acta Neurochir (Wien)* 2019;161(1):79-83.
[PUBMED](#) | [CROSSREF](#)
25. Zanoletti E, Cazzador D, Faccioli C, Gallo S, Denaro L, D'Avella D, et al. Multi-option therapy vs observation for small acoustic neuroma: hearing-focused management. *Acta Otorhinolaryngol Ital* 2018;38(4):384-92.
[PUBMED](#) | [CROSSREF](#)
26. Flickinger JC, Kondziolka D, Niranjan A, Lunsford LD. Results of acoustic neuroma radiosurgery: an analysis of 5 years' experience using current methods. *J Neurosurg* 2001;94(1):1-6.
[PUBMED](#) | [CROSSREF](#)
27. Chopra R, Kondziolka D, Niranjan A, Lunsford LD, Flickinger JC. Long-term follow-up of acoustic schwannoma radiosurgery with marginal tumor doses of 12 to 13 Gy. *Int J Radiat Oncol Biol Phys* 2007;68(3):845-51.
[PUBMED](#) | [CROSSREF](#)
28. Flickinger JC, Lunsford LD, Linskey ME, Duma CM, Kondziolka D. Gamma knife radiosurgery for acoustic tumors: multivariate analysis of four year results. *Radiother Oncol* 1993;27(2):91-8.
[PUBMED](#) | [CROSSREF](#)
29. Flickinger JC, Kondziolka D, Niranjan A, Lunsford LD. Results of acoustic neuroma radiosurgery: an analysis of 5 years' experience using current methods. *J Neurosurg* 2001;94(1):1-6.
[PUBMED](#) | [CROSSREF](#)
30. Flickinger JC, Kondziolka D, Niranjan A, Maitz A, Voynov G, Lunsford LD. Acoustic neuroma radiosurgery with marginal tumor doses of 12 to 13 Gy. *Int J Radiat Oncol Biol Phys* 2004;60(1):225-30.
[PUBMED](#) | [CROSSREF](#)
31. Lunsford LD, Niranjan A, Flickinger JC, Maitz A, Kondziolka D. Radiosurgery of vestibular schwannomas: summary of experience in 829 cases. *J Neurosurg* 2005;102 Suppl:195-9.
[PUBMED](#) | [CROSSREF](#)
32. Chung WY, Liu KD, Shiao CY, Wu HM, Wang LW, Guo WY, et al. Gamma knife surgery for vestibular schwannoma: 10-year experience of 195 cases. *J Neurosurg* 2005;102 Suppl:87-96.
[PUBMED](#) | [CROSSREF](#)
33. Myrseth E, Møller P, Pedersen PH, Vassbotn FS, Wentzel-Larsen T, Lund-Johansen M. Vestibular schwannomas: clinical results and quality of life after microsurgery or gamma knife radiosurgery. *Neurosurgery* 2005;56(5):927-35.
[PUBMED](#)
34. Chopra R, Kondziolka D, Niranjan A, Lunsford LD, Flickinger JC. Long-term follow-up of acoustic schwannoma radiosurgery with marginal tumor doses of 12 to 13 Gy. *Int J Radiat Oncol Biol Phys* 2007;68(3):845-51.
[PUBMED](#) | [CROSSREF](#)
35. Régis J, Tamura M, Delsanti C, Roche PH, Pellet W, Thomassin JM. Hearing preservation in patients with unilateral vestibular schwannoma after gamma knife surgery. *Prog Neurol Surg* 2008;21:142-51.
[PUBMED](#) | [CROSSREF](#)

36. Yang I, Sughrue ME, Han SJ, Fang S, Aranda D, Cheung SW, et al. Facial nerve preservation after vestibular schwannoma Gamma Knife radiosurgery. *J Neurooncol* 2009;93(1):41-8.
[PUBMED](#) | [CROSSREF](#)
37. Tamura M, Carron R, Yomo S, Arkha Y, Muraciolle X, Porcheron D, et al. Hearing preservation after gamma knife radiosurgery for vestibular schwannomas presenting with high-level hearing. *Neurosurgery* 2009;64(2):289-96.
[PUBMED](#) | [CROSSREF](#)
38. Régis J, Carron R, Park MC, Soumare O, Delsanti C, Thomassin JM, et al. Wait-and-see strategy compared with proactive Gamma Knife surgery in patients with intracanalicular vestibular schwannomas. *J Neurosurg* 2010;113 Suppl:105-11.
[PUBMED](#) | [CROSSREF](#)
39. Murphy ES, Barnett GH, Vogelbaum MA, Neyman G, Stevens GH, Cohen BH, et al. Long-term outcomes of Gamma Knife radiosurgery in patients with vestibular schwannomas. *J Neurosurg* 2011;114(2):432-40.
[PUBMED](#) | [CROSSREF](#)
40. Brevik CN, Nilsen RM, Myrseth E, Pedersen PH, Varughese JK, Chaudhry AA, et al. Conservative management or gamma knife radiosurgery for vestibular schwannoma: tumor growth, symptoms, and quality of life. *Neurosurgery* 2013;73(1):48-56.
[PUBMED](#) | [CROSSREF](#)
41. Kim YH, Kim DG, Han JH, Chung HT, Kim IK, Song SW, et al. Hearing outcomes after stereotactic radiosurgery for unilateral intracanalicular vestibular schwannomas: implication of transient volume expansion. *Int J Radiat Oncol Biol Phys* 2013;85(1):61-7.
[PUBMED](#) | [CROSSREF](#)
42. Carlson ML, Jacob JT, Pollock BE, Neff BA, Tombers NM, Driscoll CL, et al. Long-term hearing outcomes following stereotactic radiosurgery for vestibular schwannoma: patterns of hearing loss and variables influencing audiometric decline. *J Neurosurg* 2013;118(3):579-87.
[PUBMED](#) | [CROSSREF](#)
43. Hasegawa T, Kida Y, Kato T, Iizuka H, Kuramitsu S, Yamamoto T. Long-term safety and efficacy of stereotactic radiosurgery for vestibular schwannomas: evaluation of 440 patients more than 10 years after treatment with Gamma Knife surgery. *J Neurosurg* 2013;118(3):557-65.
[PUBMED](#) | [CROSSREF](#)
44. Boari N, Bailo M, Gagliardi F, Franzin A, Gemma M, del Vecchio A, et al. Gamma Knife radiosurgery for vestibular schwannoma: clinical results at long-term follow-up in a series of 379 patients. *J Neurosurg* 2014;121 Suppl:123-42.
[PUBMED](#) | [CROSSREF](#)
45. Jacob JT, Carlson ML, Schiefer TK, Pollock BE, Driscoll CL, Link MJ. Significance of cochlear dose in the radiosurgical treatment of vestibular schwannoma: controversies and unanswered questions. *Neurosurgery* 2014;74(5):466-74.
[PUBMED](#) | [CROSSREF](#)
46. Bir SC, Ambekar S, Bollam P, Nanda A. Long-term outcome of gamma knife radiosurgery for vestibular schwannoma. *J Neurol Surg B Skull Base* 2014;75(4):273-8.
[PUBMED](#) | [CROSSREF](#)
47. Watanabe S, Yamamoto M, Kawabe T, Koiso T, Yamamoto T, Matsumura A, et al. Stereotactic radiosurgery for vestibular schwannomas: average 10-year follow-up results focusing on long-term hearing preservation. *J Neurosurg* 2016;125 Suppl 1:64-72.
[PUBMED](#) | [CROSSREF](#)
48. Bowden G, Cavaleri J, Monaco E 3rd, Niranjana A, Flickinger J, Lunsford LD. Cystic vestibular schwannomas respond best to radiosurgery. *Neurosurgery* 2017;81(3):490-7.
[PUBMED](#) | [CROSSREF](#)
49. Tuleasca C, Faouzi M, Maeder P, Maire R, Knisely J, Levivier M. Biologically effective dose correlates with linear tumor volume changes after upfront single-fraction stereotactic radiosurgery for vestibular schwannomas. *Neurosurg Rev* 2021;44(6):3527-37.
[PUBMED](#) | [CROSSREF](#)
50. Jones B, Hopewell JW, Paddick I. Biologically effective dose correlates with linear tumour volume changes after upfront single-fraction stereotactic radiosurgery for vestibular schwannomas. *Neurosurg Rev* 2022;45(3):2493-5.
[PUBMED](#) | [CROSSREF](#)
51. Savardekar AR, Terrell D, Lele SJ, Diaz R, Keesari PR, Trosclair K, et al. Primary treatment of small to medium (<3 cm) sporadic vestibular schwannomas: a systematic review and meta-analysis on hearing preservation and tumor control rates for microsurgery versus radiosurgery. *World Neurosurg* 2022;160:102-113.e12.
[PUBMED](#) | [CROSSREF](#)