

Previsional space during direct laryngoscopy

Implication in the difficult laryngoscopy

Seongjoo Park, MD, PhD^a, Ji-Won Han, MD^a, Sukwon Cha, PhD^b, Sung-Hee Han, MD, PhD^a, Jin-Hee Kim, MD, PhD^{a,*}

Abstract

The laryngoscope should displace oral soft tissues forward out of the operator's vision. Therefore, the space in front of the view may be critical for determining the laryngoscopic view. The aim was to investigate the difference in the previsional space during difficult versus easy laryngoscopy (EL).

Under general anesthesia, digital photographs of the lateral view of the head and neck were taken in the horizontal sniffing position, after head extension, and during laryngoscopy with a defined force (50N). Three points (thyroid notch (T), maxillary incisor (I), and mandibular mentum (M)) were marked on the photograph. The previsional space was defined as the TIM triangle. We compared these areas and other variables of the TIM triangle between male patients with difficult laryngoscopy (DL: Cormack–Lehane III–IV, n = 12) versus those of age- and body mass index-matched male patients with EL (Cormack–Lehane I–II, n = 12).

When the head was extended, the areas TIM triangle in DL were significantly smaller than in EL. During laryngoscopy, all values of the TIM triangle in DL, including the TIM area (16.4 ± 3.7 vs 22.6 ± 2.8 cm², $P < .01$), were significantly smaller than the values in EL.

The previsional space was smaller in patients with DL than in those with EL. The TIM triangle could suggest new way to explain the mechanism underlying DL.

Abbreviations: ASA = American Society of Anesthesiologists, DL = difficult laryngoscopy, EL = easy laryngoscopy, Ext-50N = difference between extended sniffing position and laryngoscopy, height = vertical line from M to IT line, Hor-Ext = difference between horizontal sniffing and extended sniffing position, IT line = line that connects the tip of the upper incisor (I) and thyroid notch (T), LV = line of vision, MI line = line that connects mandibular mentum (M) and the tip of the upper incisor (I), TIM triangle = the triangle composed of 3 points T, I, and M, TM line = line that connects thyroid notch (T) and mandibular mentum (M).

Keywords: airway management, difficult laryngoscopy, previsional space

1. Introduction

Difficult tracheal intubation may lead to a detrimental complication and death.^[1–3] According to the closed claims analysis of the American Society of Anesthesiologists,^[3] 67% of difficult airway claims were due to complications associated with induction. Persistent failure of tracheal intubation is highly associated with brain damage and death in an emergency situation. Although diverse tools and methods have been developed to get around difficult intubation, most of them are associated with poor outcomes.^[3] Direct laryngoscopy is still the standard method of tracheal intubation in clinical practice.

Considering the poor predictability of difficult laryngoscopy (DL) and the risk posed by unpredicted DL,^[3,4] it is imperative to elucidate the mechanism underlying DL to avoid life-threatening complications.

Successful laryngoscopy depends on achieving a clear line of vision (LV) from the maxillary incisors to the larynx. The LV is obscured by oropharyngeal soft tissues, including the tongue, hyoid bone and epiglottis, before laryngoscopy. Although some part of the tongue can be displaced to the left side by the flange of the laryngoscopic blade, the laryngoscope should displace the residual soft tissues into a limited space (previsional space), which is in front of the LV but is confined to the mandibular mentum

Editor: Somchai Amornyotin.

Funding: This work was supported by the grant no. 02-2014-051 from Seoul National University Bundang Hospital Research Fund.

This study was approved by the Institutional Review Board of Seoul National University Bundang Hospital (Ref No: B-1307-211-008) and registered at the Clinical Research Information Service (CRiS; <http://cris.nih.go.kr>; registration number: KCT0001009).

This report describes human research. IRB contact information: Seoul National University Bundang Hospital, IRB Phone: 82-31-787-1376; Email: kj.seo@snuh.org.

This manuscript was screened for plagiarism using Article Checker.

The authors have no conflicts of interest to disclose.

^a Department of Anesthesiology and Pain Medicine, Seoul National University Bundang Hospital, Seongnam-si, Gyeonggi-do, ^b Department of Mechanical and Aerospace Engineering, Advanced Automotive Research Center, Seoul National University, Gwanak-gu, Seoul, Korea.

* Correspondence: Jin-Hee Kim, Department of Anesthesiology and Pain Medicine, Seoul National University Bundang Hospital, 82, Gumi-ro 173 Beon-gil, Bundang-gu, Seongnam-si, Gyeonggi-do, 13620, Korea (e-mail: anesing1@snu.ac.kr).

Copyright © 2017 the Author(s). Published by Wolters Kluwer Health, Inc.

This is an open access article distributed under the terms of the Creative Commons Attribution-Non Commercial License 4.0 (CCBY-NC), where it is permissible to download, share, remix, transform, and buildup the work provided it is properly cited. The work cannot be used commercially without permission from the journal.

Medicine (2017) 96:27(e7408)

Received: 18 November 2016 / Received in final form: 5 June 2017 / Accepted: 12 June 2017

<http://dx.doi.org/10.1097/MD.0000000000007408>

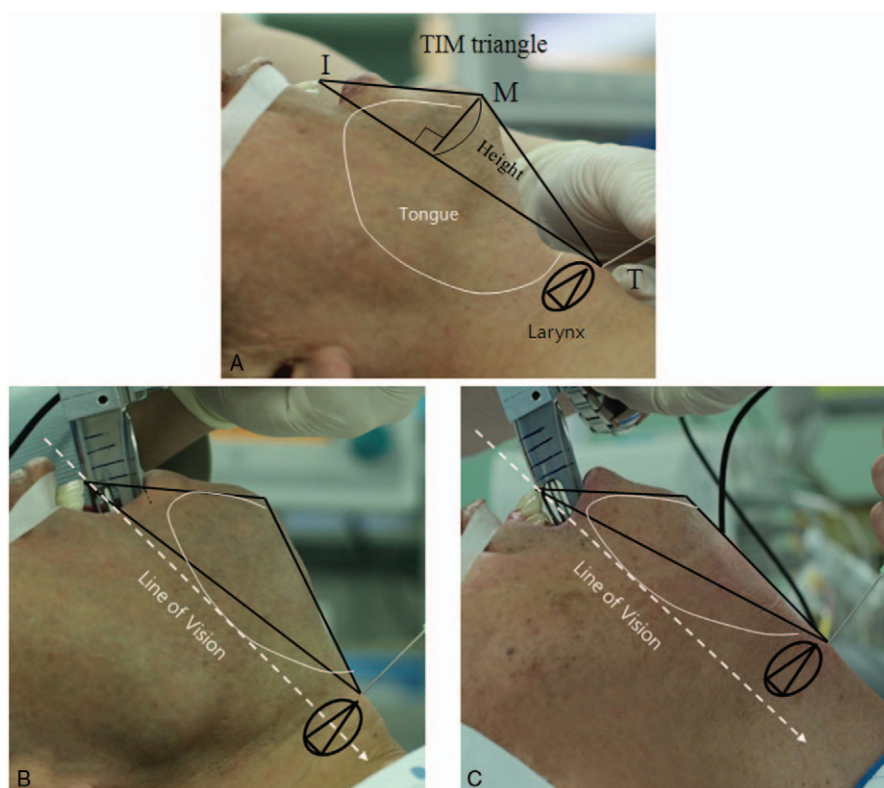


Figure 1. TIM triangle (previsional space) on the lateral photographs during laryngoscopy. Definitions of the 3 points: T = thyroid notch, I = tip of the maxillary incisor, M = mandibular mentum. Definition of the lines: TM line = line that connects thyroid notch (T) and mandibular mentum (M), MI line = line that connects mandibular mentum (M) and the tip of the upper incisor (I), IT line = line that connects the tip of the upper incisor (I) and thyroid notch (T), height = vertical line from M to IT line. TIM triangle = the triangle composed of 3 points T, I, and M (A). During laryngoscopy, the TIM triangle (previsional space) is expanded enough to contain the tongue volume, which make the line of vision reach the larynx in patient with easy laryngoscopy (B). On the other hand, the TIM triangle is too small to contain the tongue in patient with difficult laryngoscopy, making the larynx out of reach of the line of vision (C).

(Fig. 1). Accordingly, the size of the space could influence the displacement of the soft tissues and the establishment of the LV, which affects the performance of tracheal intubation.

We defined the previsional space as the TIM triangle, which is composed of 3 anatomical points (thyroid notch, maxillary incisor, and mentum of mandible) in the lateral head and neck view. Our hypothesis was that the patients with DL would have a smaller previsional space than the patients with easy laryngoscopy (EL) during direct laryngoscopy. To test this hypothesis, the area and components of the TIM triangle were assessed in the sniffing position, the sniffing position combined with neck extension, and during direct laryngoscopy using lateral photography. The results were compared between patients who had EL and those who had DL.

2. Materials and methods

The study protocol was approved by the Institutional Review Board of Seoul National University Bundang Hospital and registered at the Clinical Research information Service (CRiS; <http://cris.nih.go.kr>; registration number: KCT0001009). Written informed consent was obtained from each patient. The study was conducted between January 2014 and August 2014. Among about 1200 patients screened, total of 24 male patients (ASA classes I–II) requiring general anesthesia were enrolled in this controlled, nonrandomized, observational study. Patients with ASA class \geq III, dentures, absence of upper incisor, a history of

cervical spine surgery or cervical herniated intervertebral disc, craniofacial anomalies, or a history of psychological disease with or without psychoactive drug use, were excluded. We first recruited 13 patients to the DL group due to the presence of multiple positive predictors, such as Mallampati class \geq 3, a thyromental distance \leq 65 mm, or a receding mandible.^[5] Direct laryngoscopy was easy in 1 of these 13 patients, who was reassigned to the EL (Cormack–Lehane I–II) group after age and body mass index matching to the DL (Cormack–Lehane III–IV) group. Additional 11 patients without positive predictors, who were matched based on age and body mass index to DL group patients, were assigned to the EL group. Laryngoscopy was easy in all of these patients.

2.1. Anesthesia induction

All patients were premedicated with intravenous midazolam at 0.03 mg/kg. Electrocardiogram, noninvasive blood pressure, and peripheral oxygen saturation were continuously monitored. For the induction of general anesthesia, 1.2 to 1.5 mg/kg propofol was infused intravenously; remifentanyl was administered intravenously using a target-controlled infusion system with target concentrations of 2 to 4 ng/mL. Muscle paralysis was induced by injecting a muscle relaxant (0.6 mg/kg rocuronium). Anesthesia was maintained with continuous infusion of remifentanyl and supplemental inhalation of 3% to 6% sevoflurane with positive-pressure mask ventilation. Direct laryngoscopy was performed using #4

curved blade laryngoscope (Welch Allyn, Skaneateles Falls, NY) after the loss of all 4 twitches on the train-of-four stimulation.

2.2. Measurement of force

A metallic sheath designed to cover the laryngoscopic handle was developed. A transducer (247ST; K-TOYO, Euijeongbu, Korea) was placed between the sheath and the handle to measure the axial force loaded onto the handle^[6,7] (Fig. 2). A NI cDAQ-9172 data acquisition system (National Instrument, Austin, TX) converted signals into measured laryngoscopic forces, with values displayed on the monitor of a laptop computer. Data collection programs were generated using the LabVIEW software package (ver. 8.5; National Instruments), and the data acquisition rate was 10 Hz. The MATLAB program (MathWorks, Natick, MA) was used for data analysis, and the laryngoscope was calibrated before each experiment.

2.3. Experimental procedures and measurements

Laryngoscopic forces were measured by the similar methods which were described in our previous research.^[7] All measurements were performed with patients under general anesthesia in the supine position; sniffing position was achieved with a 7-cm-high hard pillow under the patient's head. During the procedure, the patient's head was fully extended, the maxillary incisors were exposed by lifting the upper lip with adhesive tape, and the thyroid notch was identified by an assistant with an indicator. A goniometer was attached tightly to the patient's forehead to measure neck extension. The lateral photograph of the head and neck was taken with a digital camera (EOS 5D Mark II, Canon, Tokyo, Japan) during each of the 3 steps listed below. The lens of the camera was placed 1 m from the patient, at the level of the mandible while in the sniffing position.

1. Horizontal sniffing position: simple sniffing position without head extension.
2. Extended sniffing position: head was extended maximally.

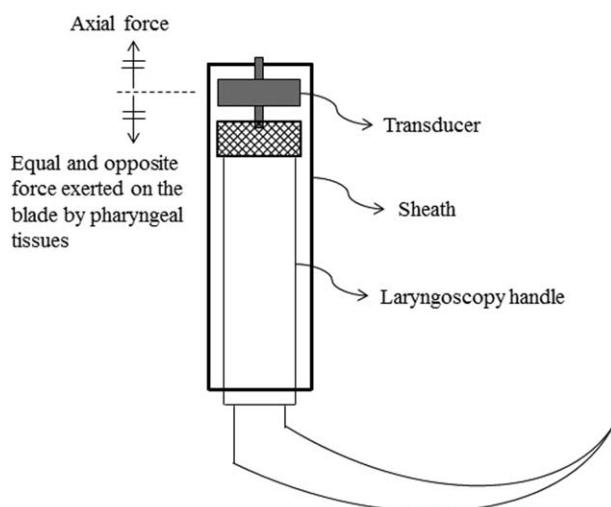


Figure 2. Diagram of the laryngoscope designed for this experiment. A metal sheath was designed to cover the entire laryngoscope handle. A transducer detecting the stretch force was placed between the upper end of the laryngoscopic handle and the sheath. During laryngoscopy, the axial forces loaded on the handle were checked and converted to electrical signals through the transducer.

3. 50N: the axial force reached 50 N at extended sniffing position.

Laryngoscopic force was recorded on a laptop computer in seconds. As the laryngoscopic force started to increase, axial force was monitored by an assistant. When the force reached its maximum (50 N), the operator maintained that force and the laryngoscopic view, for 2 to 3 seconds to obtain an image. The operator attempted to keep the patient's neck fully extended with his right hand throughout the experiment, and the assistant checked the angle of the goniometer continuously. The laryngoscopic view at 50 N was recorded using the Cormack–Lehane grade, defined as follows: I, the majority of the glottis is visible; II, only the posterior portion of the glottis is visible; III, no part of the glottis is visible and only the epiglottis can be observed; and IV, not even the epiglottis is visible.^[8]

In previous reports, the maximum laryngoscopic force required for the optimal laryngoscopic view ranged between 27.1 and 57 N.^[6,9,10] Although laryngoscopic forces >50 N can be generated, such forces would increase the risk of tissue trauma. Therefore, the laryngoscopic force was limited to 50 N.^[7]

After step 3, tracheal intubation was performed and mechanical ventilation was started. All measurements were completed within 40 seconds and were terminated before oxygen saturation decreased to 98%. Two anesthesiologists, who were experts in tracheal intubation with direct laryngoscope, performed the experiment. One anesthesiologist, who was blinded to the study design, printed the photographs, identified the anatomical landmarks, and measured the parameters associated with the TIM triangle.

2.4. Measurements of variables related to the TIM triangle

Figure 1 depicts the lateral photographs from an easy (B) and DL (C) during direct laryngoscopy. Anatomical landmarks (maxillary incisor, I; thyroid notch, T; and mandibular mentum, M) were identified. The TIM triangle was defined as a triangle comprising the 3 points T, I, and M. The length of the 3 sides of the triangle (TI, IM, and TM) were measured and converted to real values using the reduction ratio of the size of the laryngoscopic handle on the photographs. The area of the TIM triangle and its height (the perpendicular line from M to the IT line) was calculated using Heron formula. The lengths of the 3 sides were denoted by a , b , and c , and the area of the triangle was expressed as follows:

$$\text{Area of } \Delta = \sqrt{s(s-a)(s-b)(s-c)}, \quad s = \frac{a+b+c}{2}$$

The height of the TIM triangle was expressed as follows:

$$\text{Height} = (2 \times \text{Area of } \Delta) / \text{IT length}$$

The primary outcomes were the differences in the area and components of the TIM triangle between the EL and DL groups. Secondary outcomes included the differences in the changes in the area and components of the TIM triangle from extended sniffing position to maximal laryngoscopic force between the EL and DL groups.

2.5. Statistical analyses

Primary outcome was the area of the TIM triangle. In a pilot study, the mean area of the TIM triangle, with a laryngoscopic force of 50 N, was $25.5 \pm 3.9 \text{ cm}^2$. We considered a 20% change

in the TIM area to be clinically significant. With $\alpha = 0.05$ and $\beta = 0.1$, 11 patients were required to detect this change. Considering a 10% dropout rate, we estimated that 12 patients would be required in each group. A normality test was performed for all measured values in each group, and all of the variables of the TIM triangle were normally distributed. To compare values among groups, a *t* test was performed for continuous variables, while χ^2 tests were performed for categorical variables. Spearman correlation analysis was used to assess the correlation between clinical predictors of difficult intubation and prelaryngoscopically measured values in the TIM triangle, and between values obtained in the extended sniffing position and under maximal laryngoscopic force. A value of $P < .05$ was taken to indicate statistical significance. All data are presented as means \pm SD. All analyses were performed using the SPSS for Windows software package (ver. 18.0; SPSS, Inc., Chicago, IL).

3. Results

The demographic data and perioperative airway assessments for both groups are described in Table 1. Age and body mass index were not different between the 2 groups. However, there were significant differences in the thyromental distance, neck extension and Mallampati class ($P < .05$).

3.1. The area of the TIM triangle (TIM area) is smaller in DL than in EL

In the horizontal sniffing position, there was no difference in the TIM area, although the height of the TIM triangle was shorter in

Table 1

Demographic data and results of perioperative airway assessment for the patients with difficult laryngoscopy (DL) and without difficult laryngoscopy (EL).

	EL	DL	P
Age, y	63.5 (9.6)	63.8 (11.1)	.954
Weight, kg	67.0 (5.9)	69.7 (6.6)	.292
Height, cm	164.9 (5.6)	167.5 (4.8)	.231
Body mass index, kg/m ²	24.6 (1.7)	24.8 (1.8)	.783
Thyromental distance, mm	83.3 (5.8)	75.0 (5.2)	.001
Neck extension, °	21.0 (4.2)	15.9 (5.6)	.021
Mallampati class, I/II/III/IV	5/6/1/0	1/1/7/3	<.001

Values are mean (SD) or number of patients.

the DL group than in the EL group (Fig. 3). After neck extension in the sniffing position, however, the TIM area, the length of the TM, and the height of the TIM triangle in the DL group were significantly smaller than in the EL group. During laryngoscopy with maximum force (50N), all values of the TIM triangle, including the TIM area, were significantly smaller in the DL group compared to the EL group (Figs. 1B and C and 2).

3.2. Patients with small TIM triangles during laryngoscopy also had small TIM triangles in the extended sniffing position

Most of the values of the TIM triangle in the extended sniffing position were correlated with the values during laryngoscopy (Table 2). Among them, the TM length showed the highest

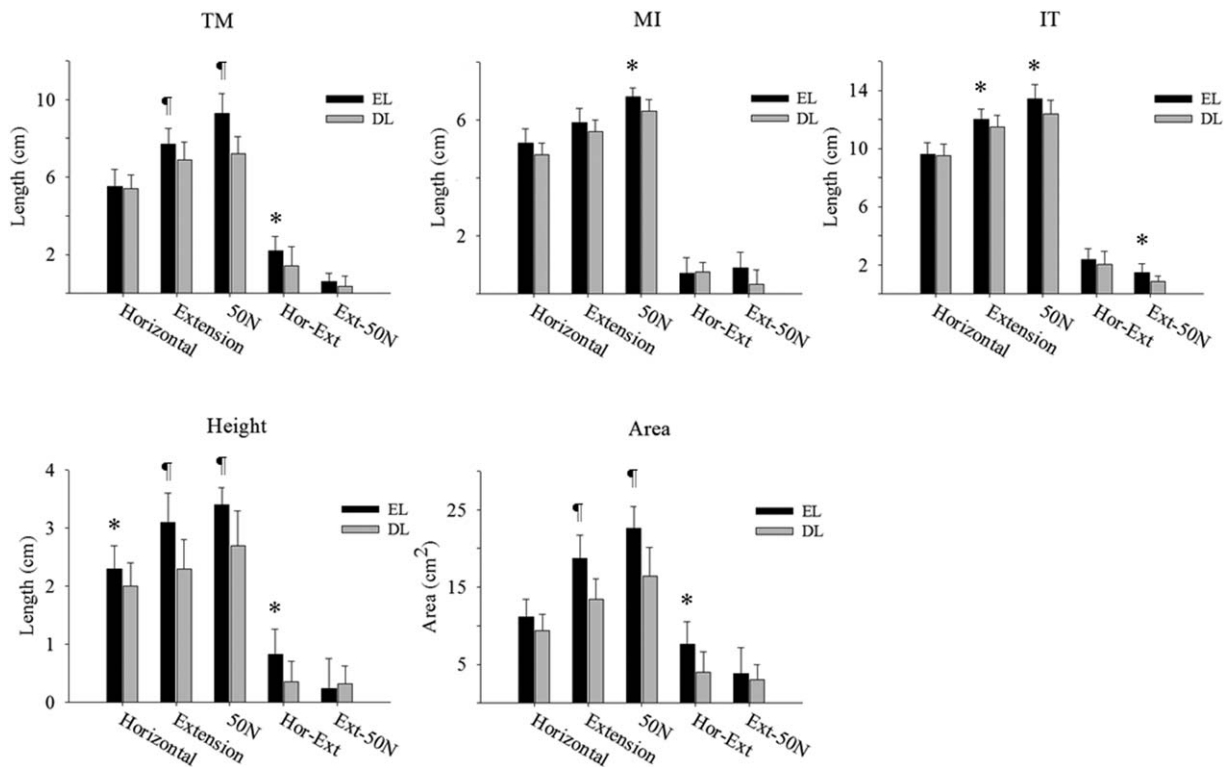


Figure 3. Area and other variables of TIM triangle in patients with difficult laryngoscopy and easy laryngoscopy. * $P < .05$ vs DL group; † $P < .01$ vs DL group. DL = difficult laryngoscopy, EL = easy laryngoscopy, Ext-50N = difference between extended sniffing position and laryngoscopy, height = straight distance from M to IT line, Hor-Ext = difference between horizontal sniffing and extended sniffing position, IT = line that connect I and T, MI line = line that connect M and I, TIM = triangle composed of 3 points T, I, and M, TM = line that connect T and M.

Table 2

Correlation of values between in the extended position and under maximal laryngoscopic force and correlation between clinical predictors and prelaryngoscopically measured values in TIM triangle.

	Correlation of values between in the extended position and under maximal laryngoscopic force	Clinical predictors		
		Mallampati	Neck extension	Thyromental distance
Height (horizontal)	NA	-0.271 (0.211)	0.156 (0.476)	0.301 (0.162)
TIM area (horizontal)	NA	-0.332 (0.121)	0.038 (0.865)	0.367 (0.085)
TM (extension)	0.901 (<0.001)	-0.508 (0.013)	0.370 (0.082)	0.631 (0.001)
MI (extension)	0.311 (0.139)	0.003 (0.991)	0.193 (0.379)	0.206 (0.346)
IT (extension)	0.789 (<0.001)	-0.449 (0.032)	0.317 (0.140)	0.546 (0.007)
Height (extension)	0.763 (<0.001)	-0.324 (0.131)	0.409 (0.053)	0.594 (0.003)
TIM area (extension)	0.828 (<0.001)	-0.418 (0.047)	0.450 (0.031)	0.685 (<0.001)

Values are Spearman rho (*P*-value).

Height (extension) = height at extended sniffing position, height (horizontal) = height at horizontal sniffing position, height = straight distance from M to IT line, IT (extension) = IT length at extended sniffing position, IT = line that connects I and T, MI (extension) = MI length at extended sniffing position, MI line = line that connects M and I, NA = not applicable, TIM area (extension) = the area of TIM triangle at extended sniffing position, TIM area (horizontal) = area of TIM triangle at horizontal sniffing position, TIM = triangle composed of 3 points T, I, and M, TM (extension) = TM length at extended sniffing position, TM = line that connects T and M.

correlation. In addition, the change in the TIM area, the height, and the TM length from the horizontal sniffing position to the extended sniffing position was greater in the EL group than in the DL group, but there was no significant difference in the change from the extended sniffing position to laryngoscopy between the 2 groups (Fig. 3). These results suggest that the small previsual space during DL might originate from the small space in the extended sniffing position.

4. Discussion

In this study, we demonstrated that the previsual space (the area of the TIM triangle) was significantly smaller during DL compared to EL in the extended sniffing position, as well as during direct laryngoscopy. The area of the TIM triangle in the extended sniffing position was associated with clinical predictors for DL.

According to the obstacle theory suggested by Isono,^[5,11] the sniffing position increases the submandibular space, which is defined as the space between the mandibular mentum and the thyroid notch (thyromental distance). A further increase in the submandibular space during direct laryngoscopy allows for the displacement of the anterior obstacles (tongue, epiglottis, and mandible). However, failure to increase the submandibular space impedes the displacement of the anterior obstacles and limits the operator's view. Consistent with this theory, our results also showed that patients in the DL group had a significantly shorter TM length in the TIM triangle, which corresponded to the submandibular space. Unfortunately, however, we hardly noticed the displacement of the anterior obstacles through the submandibular space in patients without DL. Instead, a protruded submandibular space was frequently observed in patients with DL. These results suggest that the submandibular space, which is defined in one dimension, cannot act as a "gate or space" to allow the displacement of the anterior obstacles rather than a sign of space shortage or sufficiency for the anterior obstacles to be displaced during laryngoscopy. Therefore, a new concept is needed to explain the mechanism underlying DL in terms of the capacity of higher dimensional space in which the anterior obstacles can be confined in front of the LV during laryngoscopy.

The TIM triangle (the previsual space) was defined as the space between the mandibular mentum and the LV (maxillary incisors–thyroid notch), which is obscured by the tongue when

the direct laryngoscope is not used. Therefore, a large previsual space will make it easier for the operator to push the tongue aside in front of the LV and clear the view to the larynx. Furthermore, a small space will not provide sufficient space to contain the tongue during laryngoscopy. Therefore, the residual part of the tongue that is posterior to the LV will obscure the operator's vision. Our study demonstrated that the TIM area in DL was significantly smaller than that in EL in the extended sniffing position and during laryngoscopy. This is in line with our previous study which showed that limited movement of LV causes DL.^[7] Additionally, the significant correlation of the TIM area in the extended sniffing position and that during laryngoscopy might also support our suggestion.

The previsual space is not fixed but changeable. The mentum of the mandible, which is the anterior border of the space, is anchored to the mandibular joint and is covered by skin over the thyromental area. Therefore, the space can be expanded during position change or direct laryngoscopy, but the extent of expansion will be limited under the defined laryngoscopic force. Our results showed that the TIM area was significantly increased after neck extension during both EL and DL, which suggests that neck extension not only shifts the posterior obstacles downward but also expands the space into which the anterior obstacles can be pushed before laryngoscopy. However, the extent of the increase in the previsual space was different between the 2 groups. The EL group showed a significantly greater increase in the TIM area from the horizontal to the extended sniffing position than the DL group (Fig. 3). The greater increase in the previsual space might result in easier laryngoscopy.

The previsual space (TIM triangle) consists of several components of the TIM triangle, and some of these components are associated with clinical predictors for DL. First, the TM corresponds to the thyromental distance, which is considered to be a mandibular space.^[12] The distance also reflects whether tongue displacement during laryngoscopy will be easy or difficult.^[4] Consistent with this notion, our results demonstrated that patients with DL had a short TM in the sniffing position and then presented a small TIM area (previsual space) during laryngoscopy. Second, a short interincisors distance can lead to a short MI. Significantly limited mouth opening may disrupt the LV to the larynx.^[13,14] However, the contribution of this factor to DL is not fully known.^[4] Although the MI during laryngoscopy in the DL group was shorter than in the EL group in our study, whether the short MI was due to the short interincisors distance

or to other factors was not determined. Third, the height of the TIM triangle (depth of previsual space) may be associated with the growth of the mandible. The patients in the DL group in our study had small mandibles and had shorter TIM triangle heights compared to those in the EL group in the horizontal sniffing position, extended sniffing position and even during laryngoscopy. The previsual space is directly influenced by the height of the TIM triangle (TIM area = IT × height of TIM). Therefore, a receding mandible might cause a small previsual space because of the small height of the TIM. Similar to the increased submandibular angle in the lateral view,^[15] the small height of the TIM triangle can represent the receding mandible. In addition, movement of the temporomandibular joint can also influence direct laryngoscopy.^[16,17] Stiffness of the joint limits not only mouth opening but also forward movement of the mandible during laryngoscopy. This limitation results in the failure to increase the height and area of the TIM triangle.

Prediction of DL is necessary to prevent the life-threatening risk caused by unpredicted DL. Compared to the value of each predictor alone, a combination of the multiple clinical predictors may increase the diagnostic value.^[4,13] The TIM area is a product of 3 side lines and the height of the TIM triangle, which are associated with multiple clinical predictors for DL, such as thyromental distance, receding mandible, mobility of the temporomandibular joint, and the interincisor distance. Additionally, the TIM area in the EL group showed a greater expansion from the horizontal to the extended sniffing position compared to the DL group, but not from the extended sniffing position to laryngoscopy. Nevertheless, conducted for the anesthetized patients, these features might allow the TIM area in the extended sniffing position to contribute to the prediction of DL. Future studies are warranted to investigate the predictive values during wakefulness for DL or intubation in a large patient population.

Our study has some limitations. First, the previsual space was defined by 2-dimensions, but the real tongue can be contained only in 3-dimensional space during laryngoscopy. The laryngoscopic blade, however, is placed in the midline of the oral space, and the tongue is compressed into the space along the midline plane. Therefore, a 2-dimensional previsual space incorporating the maxillary incisor, larynx and mandibular mentum would function no less than a 3-dimensional space containing the whole tongue. Second, the conditions of intraoral structures such as the volume of tongue or incisor teeth size were not considered. If a successful laryngoscopy depends on the balance between the tongue volume and the previsual space, the volume of the tongue must also be evaluated. However, the tongue volume is proportional to body mass index (BMI)^[18,19] and the present study was designed with BMI-matched patients. Therefore, our results would be still valid, regardless of the tongue volume measurement. In addition, the experiment was conducted in the Korean male patients, so we believe that individual differences of upper incisor sizes would not be significant. Finally, the values of the TIM triangle were obtained via lateral view photographs. Taking the photograph, measuring the values, and calculating the TIM area can be time-demanding and cumbersome work. A method to directly measure the values (e.g., with a compass or dividers) might limit the necessary labor.

In conclusion, the previsual space (TIM triangle) during direct laryngoscopy was smaller in patients with DL than in those with EL. These results suggest that the TIM triangle could suggest the advanced mechanism underlying DL.

Acknowledgments

The English in this document has been checked by at least 2 professional editors, both native speakers of English. For a certificate, please see: <http://www.textcheck.com/certificate/4legqA>.

References

- [1] Cook TM, Woodall N, Frerk C. Major complications of airway management in the UK: results of the Fourth National Audit Project of the Royal College of Anaesthetists and the Difficult Airway Society. Part 1: anaesthesia. *Br J Anaesth* 2011;106:617–31.
- [2] Hove LD, Steinmetz J, Christoffersen JK, et al. Analysis of deaths related to anesthesia in the period 1996–2004 from closed claims registered by the Danish Patient Insurance Association. *Anesthesiology* 2007;106:675–80.
- [3] Peterson GN, Domino KB, Caplan RA, et al. Management of the difficult airway: a closed claims analysis. *Anesthesiology* 2005;103:33–9.
- [4] Shiga T, Wajima Z, Inoue T, et al. Predicting difficult intubation in apparently normal patients: a meta-analysis of bedside screening test performance. *Anesthesiology* 2005;103:429–37.
- [5] Kitamura Y, Isono S, Suzuki N, et al. Dynamic interaction of craniofacial structures during head positioning and direct laryngoscopy in anesthetized patients with and without difficult laryngoscopy. *Anesthesiology* 2007;107:875–83.
- [6] Hastings RH, Hon ED, Nghiem C, et al. Force, torque, and stress relaxation with direct laryngoscopy. *Anesth Analg* 1996;82:456–61.
- [7] Park S, Jeong J, Cha S, et al. Angular change in the line of vision to the larynx: implications for determining the laryngoscopic view. *Can J Anesth* 2014;61:433–40.
- [8] Cormack RS, Lehane J. Difficult tracheal intubation in obstetrics. *Anaesthesia* 1984;39:1105–11.
- [9] Sudhir G, Wilkes A, Clyburn P, et al. User satisfaction and forces generated during laryngoscopy using disposable Miller blades: a manikin study. *Anaesthesia* 2007;62:1056–60.
- [10] Bucx MJL, Scheck PAE, Van Geel RTM, et al. Measurement of forces during laryngoscopy. *Anaesthesia* 1992;47:348–51.
- [11] Isono S. Common practice and concepts in anesthesia: time for reassessment: is the sniffing position a “gold standard” for laryngoscopy? *Anesthesiology* 2001;95:825–7.
- [12] Randell T. Prediction of difficult intubation. *Acta Anaesthesiol Scand* 1996;40:1016–23.
- [13] Wilson ME, Spiegelhalter D, Robertson JA, et al. Predicting difficult intubation. *Br J Anaesth* 1988;61:211–6.
- [14] Karkouti K, Rose DK, Wigglesworth D, et al. Predicting difficult intubation: a multivariable analysis. *Can J Anaesth* 2000;47:730–9.
- [15] Suzuki N, Isono S, Ishikawa T, et al. Submandible angle in nonobese patients with difficult tracheal intubation. *Anesthesiology* 2007;106:916–23.
- [16] Sahin SH, Yilmaz A, Gunday I, et al. Using temporomandibular joint mobility to predict difficult tracheal intubation. *J Anesth* 2011;25:457–61.
- [17] Kayashima K, Matsushita H, Murashima K. Difficult tracheal intubation using the Airway Scope in a patient with unexpected mouth-opening difficulty. *J Anesth* 2012;26:308–9.
- [18] Do KL, Ferreyra H, Healy JF, et al. Does tongue size differ between patients with and without sleep-disordered breathing? *Laryngoscope* 2000;110:1552–5.
- [19] Shigeta Y, Ogawa T, Ando E, et al. Influence of tongue/mandible volume ratio on oropharyngeal airway in Japanese male patients with obstructive sleep apnea. *Oral Surg Oral Med Oral Pathol Oral Radiol Endod* 2011;111:239–43.