









Successful Interventional Treatment of a Huge Pseudoaneurysm of the Popliteal Artery Caused by a Percutaneous Balloon Angioplasty Complication: A Case Report

경피적 풍선성형술의 합병증으로 발생한 슬와동맥 거대 가성동맥류의 성공적인 인터벤션 치료: 증례 보고

Hyunmin Kim, MD¹ , Seung Yeon Noh, MD¹ , Se Hwan Kwon, MD^{1*} ,
Hyun-Min Ko, MD² , Hyung Joon Ahn, MD² , Joo Hyeong Oh, MD¹ 

Departments of ¹Radiology and ²Surgery, College of Medicine, Kyung Hee University, Kyung Hee University Hospital, Seoul, Korea

ORCID iDs

Hyunmin Kim  <https://orcid.org/0000-0002-5969-0902>
Seung Yeon Noh  <https://orcid.org/0000-0001-7532-5211>
Se Hwan Kwon  <https://orcid.org/0000-0002-7777-8422>
Hyun-Min Ko  <https://orcid.org/0000-0002-5078-6860>
Hyung-Joon Ahn  <https://orcid.org/0000-0002-7427-0746>
Joo Hyeong Oh  <https://orcid.org/0000-0002-8558-2112>

Pseudoaneurysms are among the most serious complications of percutaneous balloon angioplasty. Although pseudoaneurysm rupture rarely happens, when it does, the result can be fatal; thus, early detection and management are crucial. In this report, we disclose the case of a 34-year-old male with end-stage renal disease who presented with a huge symptomatic pseudoaneurysm of the left popliteal artery, following percutaneous balloon angioplasty three months prior. The pseudoaneurysm was successfully excluded using interventional treatment. The patient recovered well, and the follow-up was uneventful, with excellent patency of the covered stent.

Index terms Popliteal Artery; Pseudoaneurysm; Balloon Angioplasty; Peripheral Arterial Disease; Vascular System Injuries

Received September 7, 2022
Revised October 22, 2022
Accepted December 5, 2022

*Corresponding author

Se Hwan Kwon, MD
Department of Radiology,
College of Medicine,
Kyung Hee University,
Kyung Hee University Hospital,
23 Kyungheedaero-ro,
Dongdaemun-gu, Seoul 02447,
Korea.

Tel 82-2-958-8622
Fax 82-2-960-0787
E-mail kwon98@khu.ac.kr

This is an Open Access article distributed under the terms of the Creative Commons Attribution Non-Commercial License (<https://creativecommons.org/licenses/by-nc/4.0>) which permits unrestricted non-commercial use, distribution, and reproduction in any medium, provided the original work is properly cited.

INTRODUCTION

Percutaneous transluminal angioplasty (PTA) is a widely accepted first-line treatment for peripheral arterial steno-occlusive disease. PTA seems to be the treatment of choice for short segmental stenosis in patients with critical limb ischemia presenting with ischemic rest pain, non-healing ulcers, or gangrene and having a high risk of or with contraindications for surgical treatment (1). PTA is often preferred over surgical treatment and has become an attractive alternative because of the low incidence of serious complications and relatively low cost and level of discomfort for the patient (2). However, the procedure is still associated with many technical difficulties, which may result in various complications. Local complications occurring at the site of dilatation include vessel occlusion (due to dissection or a thrombotic event), vessel spasm, puncture site hematomas/bleeding, and less frequently, vessel rupture (1). Huge pseudoaneurysm formation at the site of previous PTA is an uncommon complication. In this study, we present the case of a 34-year-old male who was successfully treated with interventional management after developing a huge symptomatic left popliteal artery pseudoaneurysm following percutaneous balloon angioplasty for critical limb ischemia.

CASE REPORT

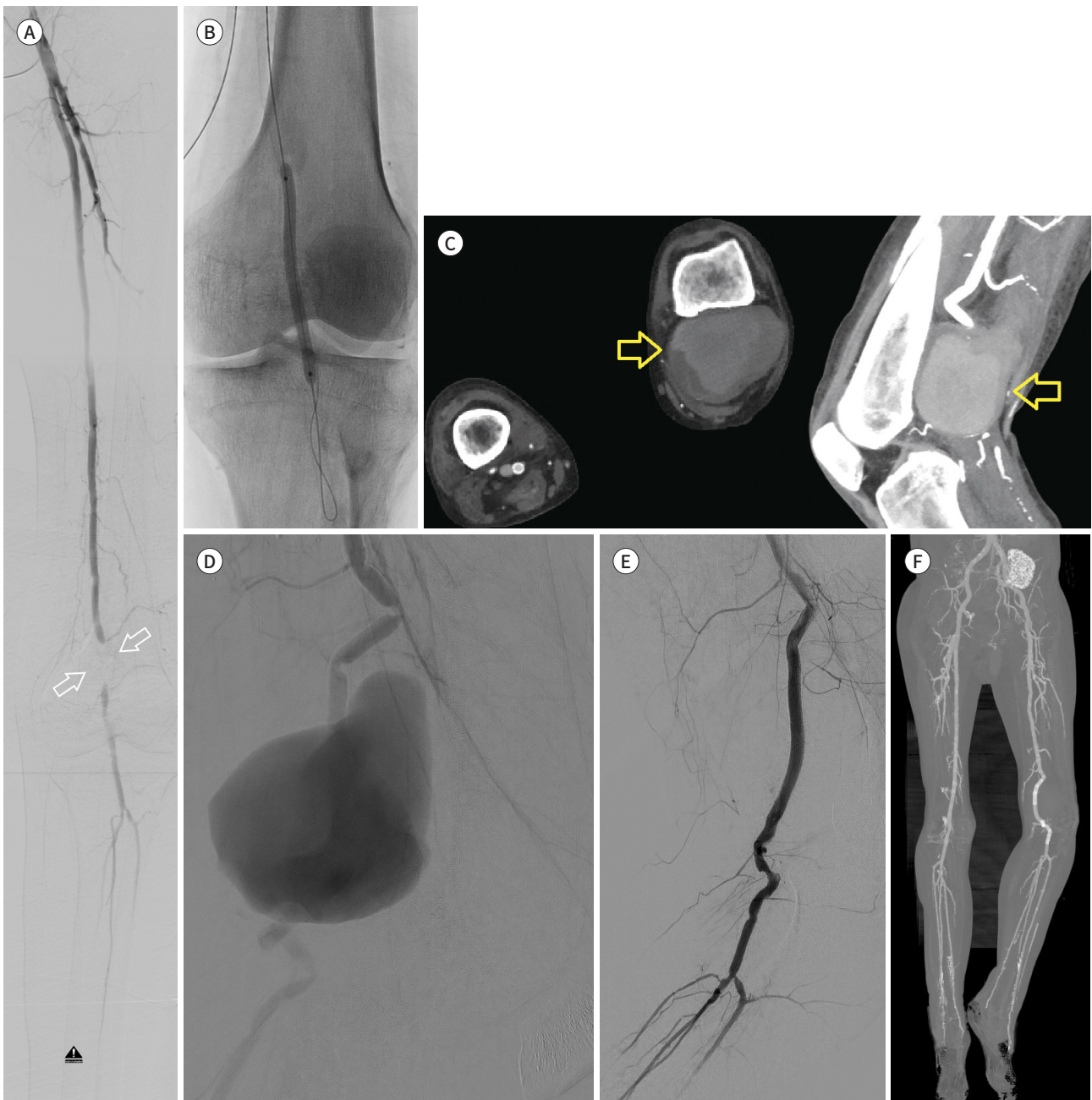A 34-year-old male was admitted to our institution with severe pain and swelling in the left popliteal area. The patient had underlying necrotic changes in both feet and flexion deformities of both knee joints. He was diagnosed with immunoglobulin A nephropathy at age 14. The patient eventually developed end-stage renal disease and underwent three kidney transplantations in the years 2005, 2010, and 2014. Unfortunately, the transplanted kidneys were nonfunctional because of graft rejection, and he was placed on hemodialysis three times a week. Three months prior, he presented ischemic pain and delayed wound healing in the left foot due to segmental occlusion of left popliteal artery (Fig. 1A), and undergone percutaneous balloon angioplasty (Fig. 1B) at another hospital.

After admission to our hospital, the patient underwent full evaluation. MRI and vascular doppler ultrasonography (US) showed a 7.2 cm × 8.9 cm × 8.9 cm-sized pseudoaneurysm formation at the popliteal artery with the intramuscular extension of the hemorrhage into the posterior compartment of the distal thigh (not shown here). Concurrent lower extremity 3D CT angiography also correlated with the MRI and US findings (Fig. 1C). Considering the location of the lesion, the pseudoaneurysm was diagnosed as a complication of previous percutaneous balloon angioplasty. Deemed at high risk of rupture of the left popliteal artery pseudoaneurysm, the patient was consulted for several possible therapeutic options including surgical resection or bypass and endovascular treatment. The patient's general condition was unfit for surgery, and bilateral below-the-knee amputations were planned in the near future. Thus, preoperative endovascular intervention to reduce the amputation extent was preferred over surgical treatment, and stent-graft deployment was selected as the therapeutic method, despite the joint location.

An antegrade left femoral approach was used with local anesthesia in the angiography room. After placement of an 8-Fr introducer sheath, a 0.035-inch guidewire (Radiofocus M;

Fig. 1. Successful interventional treatment of a huge pseudoaneurysm of the popliteal artery caused by a percutaneous balloon angioplasty in a 34-year-old male.

- A.** Initial arteriography of the left leg shows a segmental occlusion of the left popliteal artery (arrows).
- B.** Drug-eluting ballooning angioplasty was performed at the occluded site of the left popliteal artery.
- C.** Three months after the ballooning angioplasty, the patient developed a huge left popliteal artery pseudoaneurysm formation (arrows) shown on contrast-enhanced lower extremity CT.
- D.** The left popliteal arteriography image taken during covered stent insertion shows a huge, irregular-shaped pseudoaneurysm formation.
- E.** The post-stenting angiography image reveals the successful exclusion of the pseudoaneurysm and preserved distal flows of left lower extremity via the covered stent.
- F.** A maximum-intensity projection image of contrast-enhanced CT, taken one month after the covered stent placement, shows a properly located covered stent with excellent patency.



Terumo, Tokyo, Japan) and 5-Fr angiography catheter (Cook Medical, Bloomington, IN, USA) were inserted through the introducer sheath. Conventional angiography confirmed a huge pseudoaneurysm of the left popliteal artery (Fig. 1D). Diffuse dense wall calcification, angulated contours, and > 50% stenosis were also noted in the popliteal and below-knee arteries.

The pseudoaneurysm and the distal popliteal artery were cannulated using the 5-Fr catheter, while the guidewire was advanced below the posterior tibial artery. Initially, balloon angioplasty was performed in the underlying stenotic lesions (Mustang 4 mm × 40 mm; Boston Scientific, Marlborough, MA, USA, and Admiral 5 mm × 40 mm, 6 mm × 40 mm; Medtronic, Dublin, Ireland). Next, two 7 mm-sized covered stents (7 mm × 100 mm and 7 mm × 60 mm; Covera SG, Becton Dickinson, Tempe, AZ, USA) were deployed to exclude the pseudoaneurysm. Post-procedural angiography (Fig. 1E) revealed successful exclusion of the huge pseudoaneurysm and preserved left distal lower extremity artery flow through the covered stent.

The clinical course of the patient after the covered stent placement was uneventful. Follow-up computed tomography at 1 month after the treatment showed a complete thrombosed state of the previous pseudoaneurysm and a properly located covered stent with excellent patency (Fig. 1F).

This case report was exempt from the ethical approval in our institution. This study was performed according to the latest ethical principles in the Declaration of Helsinki (2013).

DISCUSSION

Popliteal artery pseudoaneurysm is an uncommon clinical entity, accounting for less than 4% of all popliteal artery aneurysms. A popliteal pseudoaneurysm can result from changes in bone structure such as exostosis, osteochondroma, and fracture, or from iatrogenic causes including surgery and trauma (3-5). Pseudoaneurysm formation is a relatively slow process, requiring a long period to become symptomatically apparent after the initial trauma. Thus, the diagnosis of popliteal artery pseudoaneurysms is often delayed by several months. The two most common symptoms of pseudoaneurysms are painful swelling (44%) and a pulsatile mass (39%, positive predictive value of 100%) (6). Physical examination is usually highly suggestive, revealing a pulsatile mass with a palpable thrill, pain, attenuated pulses, and a compressive effect of the mass. However, the clinical picture is not always typical, and imaging modalities play an essential role in the diagnosis. Color Doppler US is recommended for all cases because it can confirm the diagnosis via the pathognomonic presence of the “to-and-fro” waveform, which reflects the entry and exit of blood inside and outside the sac. Additionally, arteriography and CT angiography allow direct visualization of the lesion and provide detailed anatomical information including the characteristics, size of the neck, sac length, and its relationship with the adjacent structures.

Surgical methods include resection of the pseudoaneurysm with interposition grafting, ligation and bypass, and primary arterial repair without grafting (7). Aneurysm resection with primary end-to-end anastomosis is considered for small aneurysms (5). Open surgical repair is recommended for specific clinical situations such as expanding hematomas, infected pseudoaneurysms, and compression of the nerve caused by the mass effect of the adjacent lesion. However, surgical repair usually requires large incisions and carries the risk of injury

to important structures including large veins and nerves. Destruction of muscle tissue, possibility of surgical wound infection, and necrosis are also major concerns (8).

Endovascular repairs including the use of covered stents and bare stents, and embolization with coils, are safe and efficient ways of treating popliteal artery pseudoaneurysms that can lead to lower morbidity and shorter hospital stays (5). Additionally, the popliteal vessels are particularly amenable to endovascular repair because of the ease of access owing to its relatively unhindered anatomy and the wide arsenal of available therapeutic devices (8). However, stent placement is generally avoided in the popliteal artery because it is an anatomical site of constant flexion, particularly in young patients. Furthermore, endovascular repair has a high rate of remodeling, low long-term patency, and risks of device migration, occlusion, and fracture (9).

Therefore, careful patient selection is warranted for endovascular repair, particularly since an increased risk of early occlusion has been reported, which may further render this approach less desirable (5). Unlike the patients in other cases where stenting in the usual flexion area is not a definite and final treatment, our patient was planned for an upcoming below-the-knee amputation due to critical limb ischemia. Thus, the anatomical location of the stenting was not a limiting factor. Moreover, the pre-amputation endovascular repair would potentially improve peripheral vascular flow, possibly resulting in a reduction in the amputation extent. Lastly, the patient's general condition was unfit for surgery; therefore, surgical repair was not an option. After careful consideration, we offered covered stent insertion to exclude the pseudoaneurysm, and follow-up studies proved that the endovascular covered stent exclusion of the lesion was effective and well-preserved.

In conclusion, popliteal artery pseudoaneurysm is an uncommon entity, with no standardized approach for managing the lesion. However, refinement of the device design and increased experience with endovascular interventions in this region may expand the indications for endovascular repair of popliteal artery lesions. This study demonstrates the efficiency of covered stent implantation in the acute management of popliteal artery pseudoaneurysms and encourages radiological interventions with promising clinical outcomes.

Author Contributions

Conceptualization, K.H., K.S.H.; data curation, K.H., N.S.Y.; formal analysis, K.H., N.S.Y.; investigation, K.H., N.S.Y., K.S.H.; project administration, K.S.H.; supervision, N.S.Y., K.S.H., O.J.H.; validation, all authors; visualization, K.H., A.H.J., K.H.M., O.J.H.; writing—original draft, K.H.; and writing—review & editing, K.H., K.S.H.

Conflicts of Interest

The authors have no potential conflicts of interest to disclose.

Funding

None

REFERENCES

1. Min J, Park SW, Hwang JH, Kwon YW, Shin DH. Management of complications during below-the-knee endovascular treatment: a technical note. *Korean J Radiol* 2020;21:935-945
2. Labropoulos N, Giannoukas AD, Kutoubi AA, Nicolaidis AN. Pseudoaneurysm of superficial femoral artery after balloon angioplasty: report of two cases. *Vasc Surg* 1996;30:255-259

3. Oliveira GDP, Guillaumon AT, Brito IBD, Lima JMT, Benvindo SC, Santos LGD. Idiopathic popliteal artery pseudoaneurysm: emergency diagnosis and treatment. *J Vasc Bras* 2014;13:244-248
4. Reynolds A, Sandstrom A, Jha PK. Totally endovascular management of popliteal artery occlusion and pseudoaneurysm formation after total knee replacement. *Ann Vasc Surg* 2017;38:316.e13-316.e16
5. Katsogridakis E, Patel H, Serracino-Inglott F, Chalmers N. Popliteal artery pseudoaneurysm treated with covered stent placement and thrombolysis: a case report. *J Surg Case Rep* 2015;2015:rjv082
6. Raheirnantenaina F, Rajaonahary TM, Rakoto Ratsimba HN. [Management of popliteal artery pseudoaneurysms as a result of limb trauma and orthopedic surgery or associated with osteochondromas]. *Ann Cardiol Angeiol (Paris)* 2016;65:265-274. French
7. dos Santos Nogueira AC, Salgado CG, dos Santos Nogueira FB, do Amaral SI, Rabischoffsky A. Pseudoaneurysms: when and how to treat them. *Arq Bras Cardiol: Imagem Cardiovasc* 2013;26:289-230
8. Marín J, Schwartz E, Villablanca M, Olguín R, Ceroni E, Marín C. Terapia endovascular en trauma vascular periférico: experiencia inicial. *Revista Chilena de Cirugía* 2016;68:310-315
9. Domingues RB, Araújo AC, van Bellen B. Endovascular treatment of popliteal artery aneurysm. Early and midterm results. *Rev Col Bras Cir* 2015;42:37-42

경피적 풍선성형술의 합병증으로 발생한 슬와동맥 거대 가성동맥류의 성공적인 인터벤션 치료: 증례 보고

김현민¹ · 노승연¹ · 권세환^{1*} · 고현민² · 안형준² · 오주형¹

가성동맥류는 경피적 풍선성형술의 가장 심각한 합병증 중의 하나이다. 가성동맥류의 파열은 드물게 발생하지만, 발생할 경우 환자의 죽음을 초래할 수 있기 때문에 조기 발견과 적절한 치료가 매우 중요하다. 저자들은 3개월 전 실시한 경피적 풍선성형술의 합병증으로 발생한 증상을 동반한 좌측 슬와동맥 거대 가성동맥류를 가진 34세 말기신부전 남자 환자의 증례를 보고한다. 가성동맥류는 인터벤션 치료를 통하여 성공적으로 치료되었고, 환자는 추적기간 동안 다른 합병증 없이 잘 회복되었다.

경희대학교 의과대학 경희대학교병원 ¹영상의학과, ²외과