

STATE-OF-THE-ART REVIEW

Distal Radial Access

Consensus Report of the First Korea-Europe Transradial Intervention Meeting



Gregory A. Sgueglia, MD, PhD,^a Bong-Ki Lee, MD, PhD,^b Byung-Ryul Cho, MD,^b Avtandil Babunashvili, MD, PhD,^c Jin Bae Lee, MD,^d Jun-Won Lee, MD,^e Karsten Schenke, MD,^f Sang Yeub Lee, MD, PhD,^g Stefan Harb, MD^h

ABSTRACT

Among patients undergoing percutaneous coronary procedures, transradial access, compared with transfemoral access, is associated with a reduced risk for complications including mortality, especially in higher risk patients. However, transradial access is limited by radial artery occlusion (RAO) that despite being mostly asymptomatic because of the extensive anastomoses between the forearm arteries restricts future use of the same radial artery. Distal radial access (DRA) in the anatomic snuffbox or on the dorsum of the hand has recently gained global popularity as an alternative access route for vascular procedures. A strong anatomic and physiological rationale yields potential for significantly reduced risk for RAO and positive impact on procedural outcome for better patient care. Indeed, currently published studies buttress very low rates of RAO after DRA, hence supporting its development. The authors provide an analysis of the foundation of DRA, provide historical background, and offer a critical review of its current status and future directions. Also, given the limited evidence currently available to properly perform DRA in the real world, consensus opinion on what is considered optimal practice is also presented to supplement this document and enhance the implementation of DRA while minimizing its complications. (J Am Coll Cardiol Intv 2021;14:892-906) © 2021 by the American College of Cardiology Foundation.

Distal radial access (DRA) in the anatomic snuffbox or on the dorsum of the hand has recently gained global popularity as an alternative access route for interventional coronary and interventional radiologic procedures (1-4). On December 13 and 14, 2019, the CHORUS congress, a large Korean conference in cardiology and cardiac surgery, held a European chapter in Berlin and hosted an international DRA meeting to discuss the current role of DRA in relation to conventional transradial

access (TRA). This gathering promoted a direct exchange of ideas and techniques among invited faculties of Korean and European interventional cardiologists with both operative experience and research interests focused on DRA. Although the coronavirus disease pandemic has prevented a subsequent planned scientific appointment in Seoul, the discussion has very fruitfully continued on the Internet. The high quality of the scientific debate and its potential positive impact on procedural

From the ^aDivision of Cardiology, Sant'Eugenio Hospital, Rome, Italy; ^bDivision of Cardiology, Department of Internal Medicine, Kangwon National University Hospital, Kangwon National University School of Medicine, Chuncheon, South Korea; ^cDepartment of Cardiovascular Surgery, Center for Endosurgery and Lithotripsy, Moscow, Russian Federation; ^dDepartment of Cardiology, Daegu Catholic University Medical Center, Daegu, South Korea; ^eDivision of Cardiology, Department of Internal Medicine, Wonju Severance Christian Hospital, Yonsei University Wonju College of Medicine, Wonju, South Korea; ^fCardiology Department, Asklepios Klinik Barmbek, Hamburg, Germany; ^gDepartment of Internal Medicine, Chungbuk National University College of Medicine, Cheongju, South Korea; and the ^hUniversity Heart Center, Medical University of Graz, Graz, Austria.

The authors attest they are in compliance with human studies committees and animal welfare regulations of the authors' institutions and Food and Drug Administration guidelines, including patient consent where appropriate. For more information, visit the [Author Center](#).

Manuscript received October 16, 2020; revised manuscript received January 28, 2021, accepted February 9, 2021.

HIGHLIGHTS

- TRA reduces complications in patients undergoing percutaneous coronary procedures.
- Conventional TRA is limited by RAO restricting future use of the same radial artery.
- DRA is emerging as an alternative to TRA yielding potential for highly reduced RAO.
- Available studies provide heterogeneous data for a safe and effective DRA practice.
- This report delivers in-depth analysis of DRA rationale and its future perspectives.

outcomes for better patient care have yielded the present Berlin Report, to be shared with the interventional community. Given the limited heterogeneous evidence currently available to properly perform DRA in the real world, consensus opinion on what is considered optimal practice is also presented to supplement this document and enhance the implementation of DRA while minimizing its complications.

ADVANTAGES AND LIMITATIONS OF CONVENTIONAL TRA

Among patients undergoing percutaneous coronary procedures, TRA, compared with transfemoral access, is associated with a reduced risk for access-site bleeding, vascular complications, and mortality, especially in higher risk patients, such as those presenting with acute coronary syndromes (5-7). Accordingly, TRA has been endorsed as the default access site for patients with acute coronary syndromes undergoing invasive management in Europe, the United States, and the Far East (8,9).

Moreover, TRA allows earlier ambulation, offers greater post-procedural comfort for the patient and is cost effective, which is of particular relevance for national health systems given that substantial cost savings can be achieved while improving clinical outcomes (10,11).

From an ergonomic point of view, left TRA is less comfortable than right TRA for both the operator and the patient, especially if overweight or obese, given the need to keep the left arm in a supine position that significantly limits its hyperadduction and obliges the operator to bend over (12). Because of this ergonomic shortcoming, many operators prefer femoral access to

left TRA, and thus their patients do not benefit from the aforementioned advantages of TRA when left-sided access is indicated (13).

A comprehensive outline of the advantages and limitations of TRA is provided in [Table 1](#).

Korean-European consensus opinion: Given its significant advantages, TRA should be constantly promoted, and the limitations of TRA should be understood so that they can be increasingly overcome.

THE ISSUE OF RADIAL ARTERY OCCLUSION

Limited post-procedural complications are reported after TRA, with radial artery occlusion (RAO) being the most frequent, with an estimated incidence of 7.7% in the first 24 h after radial catheterization (14). Because of the extensive carpal and metacarpal anastomoses between the forearm arteries, RAO is not associated with ischemic complications and thus is frequently overlooked (15,16). However, RAO was reported to be symptomatic in almost one-half of patients at 2 to 8 days in a study comparing 5-F with 6-F transradial coronary procedures (17). In contrast, investigations specifically assessing the consequences of RAO on hand function failed to support an adverse impact on handgrip strength, thumb and forefinger pinch, transcutaneous oxygen pressure, and thumb capillary lactate production (18,19). Still, despite correct experimental methods, the overall evidence is somewhat limited by the small number of patients assessed. When RAO occurs, it restricts the use of the same radial artery for further cardiovascular or surgical procedures, intra-arterial pressure monitoring, and arteriovenous fistula creation for hemodialysis (20). The first issue is especially unsettling in light of better outcomes associated with TRA (5,6), and given that the probability of such future needs cannot be established, the potential consequences of this limitation are currently unknown. Notably, the failure rate of TRA has been shown to increase with successive procedures, primarily because of RAO (21), which is particularly relevant in light of the increasing adoption of TRA for a growing number of different indications, potentially leading to multiple catheterization procedures in the same patient.

Several mechanisms, including vascular injury, blood flow reduction, and thrombosis, have been linked to the occurrence of RAO (22). Recently, different methods shown to minimize the risk for RAO were reviewed in an international consensus document that supports their systematic implementation in everyday interventional practice (20).

ABBREVIATIONS AND ACRONYMS

DRA = distal radial access

RAO = radial artery occlusion

TRA = transradial access

Notably, DRA has been proposed as a potential approach for RAO avoidance given its anatomic basis and physiological rationale (23).

Korean-European consensus opinion: Awareness of the importance of RAO should be broadly developed to implement known strategies to reduce this complication.

HISTORICAL LANDMARKS

The first report of TRA was published by Radner (26) in 1948, describing this new catheterization approach for thoracic aortography. Later, Campeau (27) described its use for coronary angiography in 1989, and in 1993, Kiemeneij and Laarman (28) showed that TRA is feasible for percutaneous coronary intervention. In the following years, devices and techniques evolved to extend the applicability of TRA, and more than 20,000 patients were enrolled in randomized clinical trials that demonstrated an overall significant reduction of adverse cardiovascular and access-related events compared with transfemoral access (Figure 1). With increased perception of the better outcomes associated with TRA for coronary procedures, RAO emerged as its main limitation.

Anesthesiologists were the first to use DRA as an alternative site for peri-operative blood pressure monitoring and sampling in cardiac pediatric and adult patients, as reported by Amato et al. (29) in 1977 and Pyles et al. (30) in 1982, respectively. In 2011, Babunashvili and Dundua (31) described the first experience of DRA to retrogradely open occluded

radial arteries. Then, Kaledin et al. (24) described DRA as the default technique for coronary procedures, and Roghani-Dehkordi et al. (25) highlighted the advantages of DRA among hand arterial access routes at a Middle Eastern transradial course in 2016. On the basis of those experiences, Kiemeneij (1) promoted left DRA in the anatomic snuffbox for improved procedure ergonomics and patient comfort in right-handed subjects. In the following year, DRA spread widely across the Internet, leading to questions regarding the casual use of social media as a surrogate for traditional scientific debates (32,33) but inspiring an exploratory phase in clinical research. These endeavors describing the initial DRA practice of interventional cardiologists and interventional radiologists worldwide showed that most current interventional procedures can be safely achieved through DRA (1,4,25,34-50). Following the intuition of DRA pioneers (1,24,25), Sgueglia et al. (23) highlighted a physiological rationale for DRA and demonstrated effective flow persistence in the forearm radial artery in the worst-case scenario of distal RAO (51). Acquired knowledge and improved skill in performing DRA have paved the way for ongoing randomized clinical trials comparing DRA with conventional TRA (Table 2).

The journey to the distal part of the radial artery was initiated and conceptualized by Campeau (52), who switched from cutdown arteriotomy of the proximal radial artery, as an alternative to the brachial artery approach described by Sones, to a percutaneous proximal arterial approach and then to a percutaneous “distal” approach at the lower forearm. In a way, true distal radial artery puncture represents the culmination of his vision.

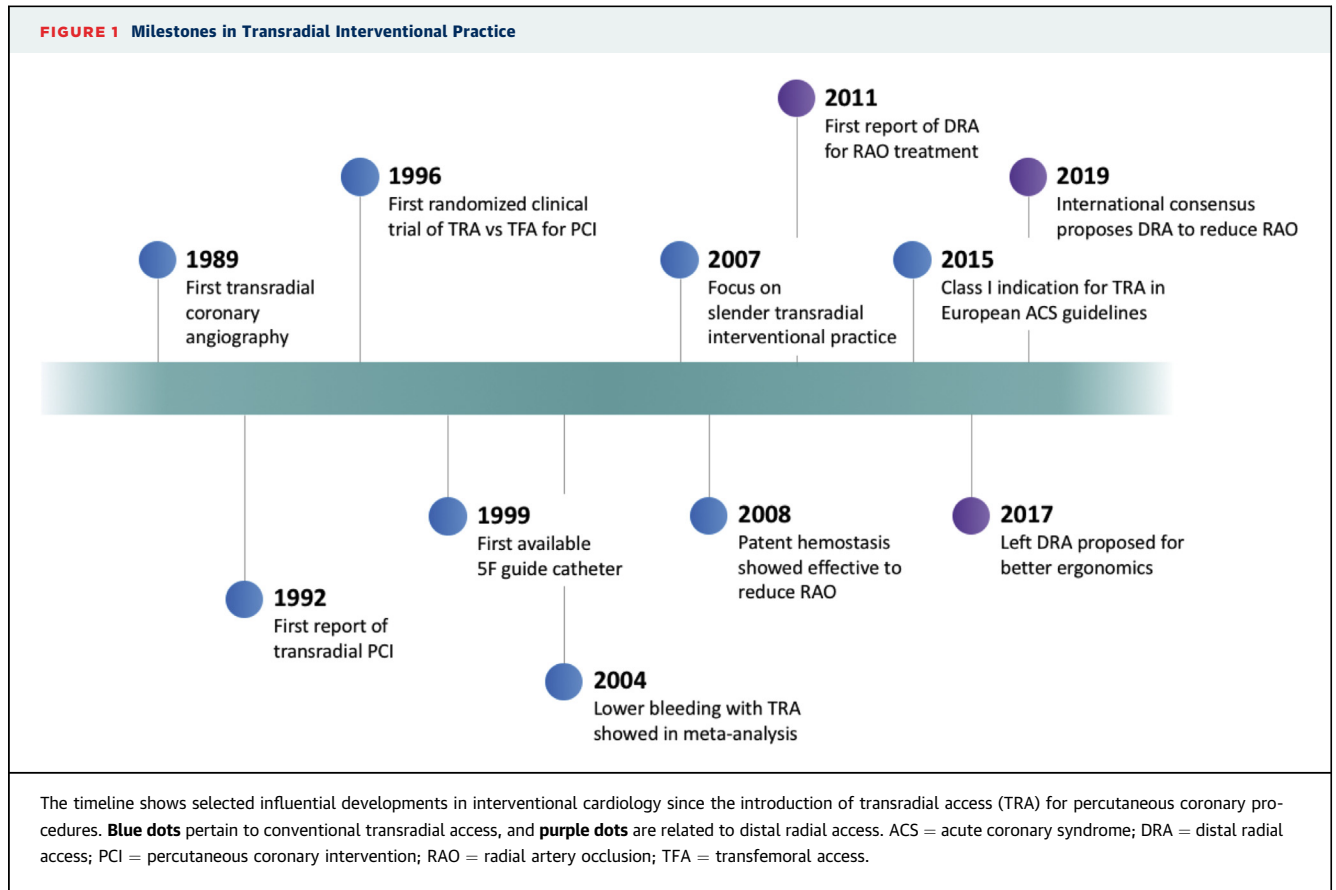
Korean-European consensus opinion: DRA is developing as an evolution and a refinement of conventional TRA.

APPLIED ANATOMY

The course of the distal radial artery with respect to relevant surrounding structures has been extensively reviewed (23). Briefly, the radial artery descends along the lateral side of the forearm above the radius toward the wrist. Just distally, the radial artery gives rise to the superficial palmar branch, which passes through the thenar muscles, sometimes anastomosing with the end of the ulnar artery to form the superficial palmar arch. The distal part of the radial artery then crosses the anatomic snuffbox beneath the tendons of the abductor pollicis longus and the extensor pollicis brevis, just above the scaphoid and trapezium bones (Figure 2). Its pulse can be felt in the

TABLE 1 Advantages of Transradial Access Over Transfemoral Access and Its Intrinsic Limitations

Advantages	Limitations
Improved patient comfort	Potential procedural challenges (e.g., radial artery spasm, subclavian tortuosity)
Lower rate of bleeding	Unknown structural or functional long-term consequences
Lower rate of vascular complications	Risk for radial artery occlusion, preventing future use of the radial artery
Lower rate of worsening kidney function in high-risk populations	Potential for compartment syndrome in case of severe bleeding complications
Lower rate of adverse outcomes including mortality in high-risk populations	Cumbersome left-sided access
Early ambulation and reduce length of stay (same-day discharge possible)	Restriction of guide catheter size
Reduced costs	Possible greater radiation exposure



anatomic snuffbox. The radial artery continues its course quite superficially in the first intermetacarpal space on the dorsum of the hand, where a pulsation may be felt at the vertex of the angle between the tendon of the extensor pollicis longus and the second metacarpal bone (Figure 2). Finally, it swerves medially between the heads of the first dorsal interosseous muscle into the palm, where it may anastomose with the deep branch of the ulnar artery, to form the deep palmar arch. Notably, completeness of the superficial palmar arch and deep palmar arch may differ extensively across population. Complete superficial palmar arch is more frequently found among Asians, while complete deep palmar arch is prevalent in Caucasians (53).

The 2 sites at which the radial pulse can be found, in the anatomic snuffbox and on the dorsum of the hand, represent alternative puncture points for DRA yielding the same benefits as conventional TRA.

Korean-European consensus opinion: It must be highlighted that the distal radial artery accessed in the anatomic snuffbox or on the dorsum of the hand is the very same radial artery continuing its course from the forearm into the hand.

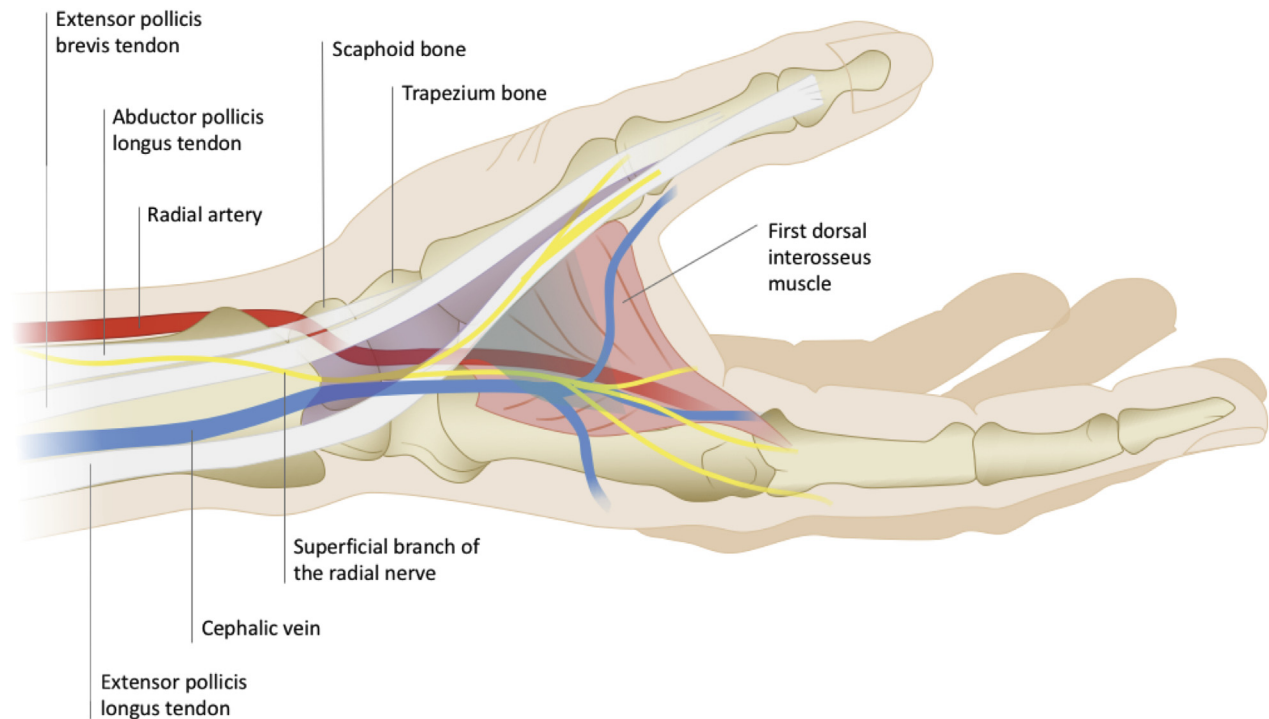
DISTINCTIVE FEATURES OF DRA

The puncture sites of the distal radial artery are beyond the rise of several anastomotic branches that, in case of vessel occlusion occurring at the distal radial artery puncture site, could avoid flow interruption in the forearm radial artery and possibly limit the reduction of blood supply to the hand (1,23-25). Of

TABLE 2 Main Ongoing Randomized Clinical Trials Comparing Distal Radial Access With Conventional Transradial Access

Trial	Registration	N	Primary Endpoint
ANGIE	NCT03986151	774	Forearm radial artery occlusion
CORRECT Radial	NCT04194606	500	Forearm radial artery occlusion
DAPRAO	NCT04238026	282	Forearm radial artery occlusion
DISCO Radial	NCT04171570	1,330	Early forearm radial artery occlusion
DIPRA	NCT04318990	300	Motor hand function
DRAMI	NCT03611725	352	Puncture success in STEMI
TENDERA	NCT04211584	1,500	Late radial artery occlusion

CORRECT Radial = Coronary Angiography and Interventions via Distal vs Proximal Access; DIPRA = Distal vs Proximal Radial Artery Access for Cath; DISCO Radial = Distal Versus Conventional Radial Access for Coronary Angiography and Intervention; DRAMI = Comparison of Success Rate Between Distal Radial Approach and Radial Approach in STEMI; STEMI = ST-segment elevation myocardial infarction.

FIGURE 2 Anatomic Landmarks for Distal Radial Access

The schematic illustration shows relevant anatomic structures on the dorsal side of the hand. The **purple shadow** outlines the triangular depression at the base of the thumb known as the anatomic snuffbox, which is bounded by the extensor pollicis brevis tendon and the abductor pollicis longus tendon laterally (radial side) and by the extensor pollicis longus tendon medially (ulnar side). Its floor is constituted by the scaphoid and trapezium carpal bones. This anatomic region is crossed by the distal radial artery, the superficial branch of the radial nerve, and variably by the cephalic vein. The extensor pollicis longus tendon separates the anatomic snuffbox from the first intermetacarpal space, where the distal radial artery can be accessed on the dorsum of the hand region, outlined by the **turquoise shadow**.

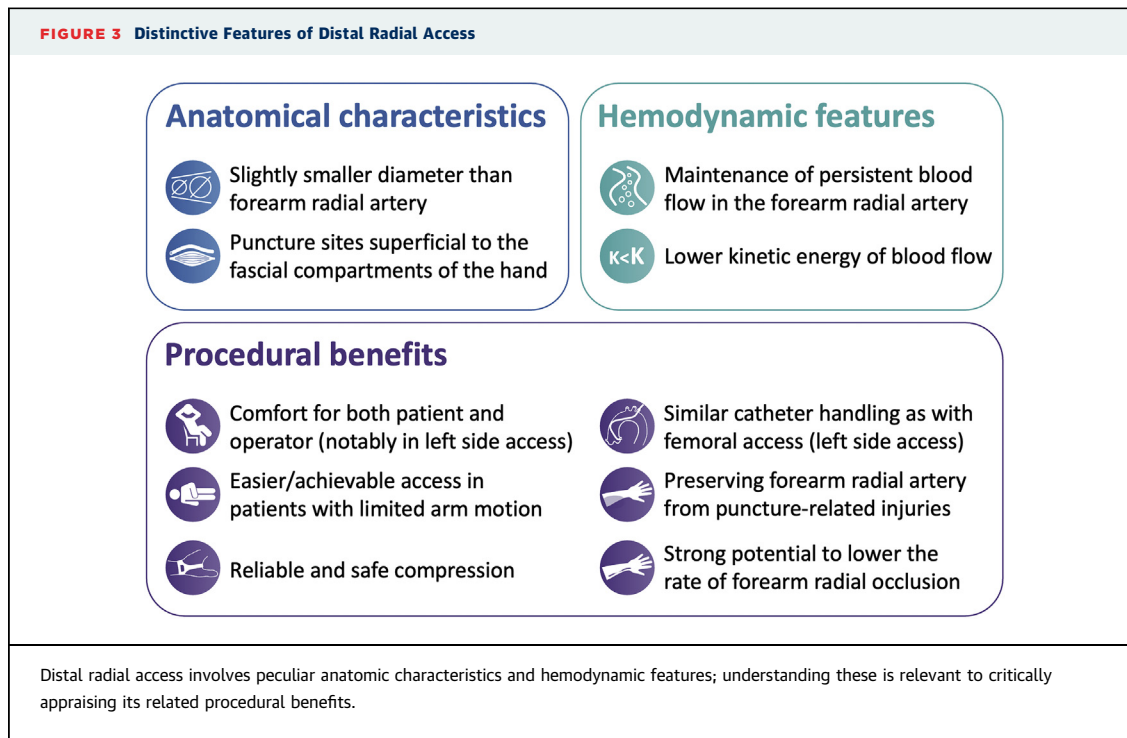
note, in an experimental study involving healthy subjects, simulated occlusion of the distal radial artery in the anatomic snuffbox did not cause significant flow reduction in the forearm radial artery compared with simulated occlusion of the radial artery at wrist (51).

Given the central role played by flow interruption in the complex interplay of factors leading to RAO (22), DRA is expected to significantly reduce the risk for proximally extending thrombosis and widespread forearm RAO. Interestingly, a recent optical coherence tomographic study showed a low incidence of forearm radial artery injury following coronary procedures performed through DRA (54), comparing favorably with conventional TRA (55).

Other important features of DRA are summarized in Figure 3 and include reliable compression hemostasis thanks to favorable surrounding anatomy (bone floor of the anatomic snuffbox and the muscle surrounding the first intermetacarpal space, lack of venous stasis because of the absence of major venous vessel compression). Hemostasis following DRA is

also favored by its superficial course (56). Moreover, the distal radial artery lies in the loose dorsal subcutaneous space that, being superficial to the fascial compartments of the hand, limits the functional consequences in case of puncture site bleeding. There is currently limited information on distal radial artery size, but it has consistently been reported to be slightly smaller than the wrist radial artery (4,34,56,57). Because of the distinct course and the anatomic relationships, DRA in the anatomic snuffbox or on the dorsum of the hand may differ as to the risk for side branch access, vessel damage, wire failure, and bleeding.

Additional advantages include the possibility to have the left hand close to the groin, with its dorsum facing up, in such a way that is comfortable for both the operator, who does not have to bend over the patient, and the patient, who, if right-handed, would no longer experience restriction of use of the dominant upper limb during the hemostatic compression following sheath removal (1). Such an opportunity could also be well appreciated by those operators who



have been trained in transfemoral access and may prefer the left approach to the coronary arteries (12).

Korean-European consensus opinion: DRA offers similar advantages to those of conventional TRA at the wrist level, along with additional advantages including strong potential for lower rates of RAO and vascular complications, rapid hemostasis, and favorable ergonomics.

DRA TECHNIQUE

One main focus of published papers on DRA has been providing technical insight. Indeed, among 20 English-language studies assessing the feasibility of DRA for coronary procedures that were indexed in PubMed between 2017 and 2020 (1,4,25,34-50), 17 (85%) provide photographs highlighting relevant procedural aspects according to each group, thus yielding complementary approaches to DRA. The overall practical skills identified so far are summed up in a step-by-step scheme presented in Figure 4. A good distal radial puncture starts with the selection of the most appropriate puncture site before bringing the patient to the catheterization table in order to optimize both patient and laboratory setup.

When ultrasound scanning is performed prior to the procedure, it should also be used to assess the distal radial artery diameter to confirm the suitability of DRA in relation to the intended procedure and

identify the best alternative access in case of failure. Optimal arm positioning represents another key step in effective distal radial puncture. Different setups have been previously outlined (1,2,23). In case of right-sided access, the upper limb is placed along the patient's body in a neutral position with its lateral side facing superiorly. In the case of left-sided access, the left hand is bent over toward the patient's groin, or the left arm is first abducted on a mobile supportive board to allow a puncture from the patient's left side and then moved toward the operator on the patient's right side. In both cases, the left arm is supported by towels to keep its lateral side facing upward. After disinfection and generous local anesthesia to prevent pain to the surrounding anatomic structures, subcutaneous injection of nitroglycerin at the puncture site may facilitate DRA by favoring vasodilation (58). An optimal knowledge of anatomic landmarks and the 3-dimensional course of the distal radial artery is of paramount importance for safe and effective DRA. Accordingly, different puncture techniques and styles may be equally effective. Importantly, because of the curvilinear route of the distal radial artery, a similar angulation to the skin of the needle at the different puncture sites on the hand yields different entry angles into the distal radial artery. Hence, to avoid the risk for vessel dissection, the needle should be slightly tilted down before advancing the mini-guidewire. Successively, as in

FIGURE 4 Distal Radial Access Technique**Patient assessment**

- Following distal radial artery palpation, the most appropriate puncture site is selected
- Ultrasound is useful to determine the diameter of the distal radial artery and to select the proper sheath introducer and catheter size

Patient setup

- The arm should be optimally positioned according to access side and operator's preference and/or experience
- Asking the patient to grasp his/her thumb under the other four fingers or holding a handle favors the distal radial artery shifting to the surface
- The puncture area is disinfected and covered with a sterile drape

Local anaesthesia

- Subcutaneous injection of a local anesthetic also helps the radial artery shifting toward the surface
- The depth of infiltration of the numbing agent varies according to the puncture technique (deeper in case of through-and-through technique, shallow in case of anterior wall puncture)

Puncture

- Operator preference and/or experience helps using an open needle or a catheter-covered needle
- The approach differs whether the radial artery is punctured in the anatomical snuffbox or in the dorsum of the hand
- The complex three-dimensional course of the distal radial artery turning around the base of the thumb allows different possible supero-inferior and latero-medial entry angles to achieve vascular access

Mini guidewire

- A mini guidewire is carefully advanced in the vessel lumen
- If resistance is felt, the guidewire should be retracted and rotated to avoid damaging small arterial branches rising between the puncture site and the forearm radial artery
- Thumb adduction straightens the radial artery and may reduce the risk of the guidewire misdirection
- Shaping the mini guidewire tip may alternatively help to overcome distal radial artery tortuosity
- Individual preference directs the choice of a 0.025 inch or a 0.018 inch mini guidewire

Sheath introducer

- A small skin incision may be helpful to favor sheath introducer insertion through the tougher skin of the dorsal side of the hand
- A thin-walled sheath introducer, with a minimal outer diameter in relation to the inner diameter, appears a wise choice
- Administration of a spasmolytic drug right after sheath introducer placement is beneficial to avoid spasm and radial artery occlusion

Angiographic wire

- A 210 cm wire is the best choice for catheter exchanges
- In case of left distal radial access, some resistance can be encountered when the tip of the wire approaches the brachial artery due to the flexed elbow, if it occurs the elbow should be stretched first and a hydrophilic wire could be used

Catheters

- Catheters 110 cm in length may be advantageous in tall subjects
- Universal radial curves should be preferred for diagnostic angiography

Overview of step-by-step distal radial access procedure summing up technical recommendations from patient assessment to catheter selection.

conventional TRA, operators should have a low threshold for using fluoroscopy or ultrasound to image the mini-guidewire course and for checking the pressure waveform from the introducer sheath when in doubt about their optimal positioning.

Korean-European consensus opinion: Comprehensive knowledge of the 3-dimensional course of the distal radial artery and of the surrounding anatomic structures is of paramount importance for safe and effective DRA. All techniques that reliably and safely grant DRA are equally valuable, and each operator should discover the one that suits him or her best.

ULTRASOUND GUIDANCE

Previous studies have shown that ultrasound guidance for conventional TRA improves first-pass puncture success and time to access and reduces vascular adverse events (59). Accordingly, ultrasound guidance can increase the success of DRA, either if implemented systematically or as a bailout after failure of tactile-guided approach. In the only study comparing both approaches, ultrasound guidance shifted DRA success from 87% to 97% (60). The main advantages of ultrasound guidance are accurate identification of the puncture site and careful assessment of the size and curvilinear course of the distal radial artery. Sliding imaging of the distal radial artery also offers a unique opportunity to build one's mental 3-dimensional anatomic model of the anatomic snuffbox and the dorsum of the hand. Yet ultrasound allows safer DRA by avoiding injury to surrounding anatomic structures and identifying early puncture-related complications.

An in-depth guide to ultrasound guidance in DRA has been recently published, providing valuable technical advice (61). A linear-array transducer ultrasound probe with a frequency range of 5 to 13 MHz is typically used to assess the vasculature. The gel is applied on the probe, which is then covered by a sterile sheath. Assessment begins by scanning over the anatomic snuffbox and/or the dorsum of the hand in transverse orientation to identify the distal radial artery. Soaking the skin with sterile saline solution may improve image quality. An assistant also helps in optimizing image parameters. If needed, applying light pressure to the probe may help differentiate a vein that will collapse from the radial artery, which will not. Once properly identified, the radial artery should be centered on the screen. The probe is then tilted to visualize the tip of the needle that punctures the skin. As the needle is advanced, the probe is progressively tilted back to follow the needle tip

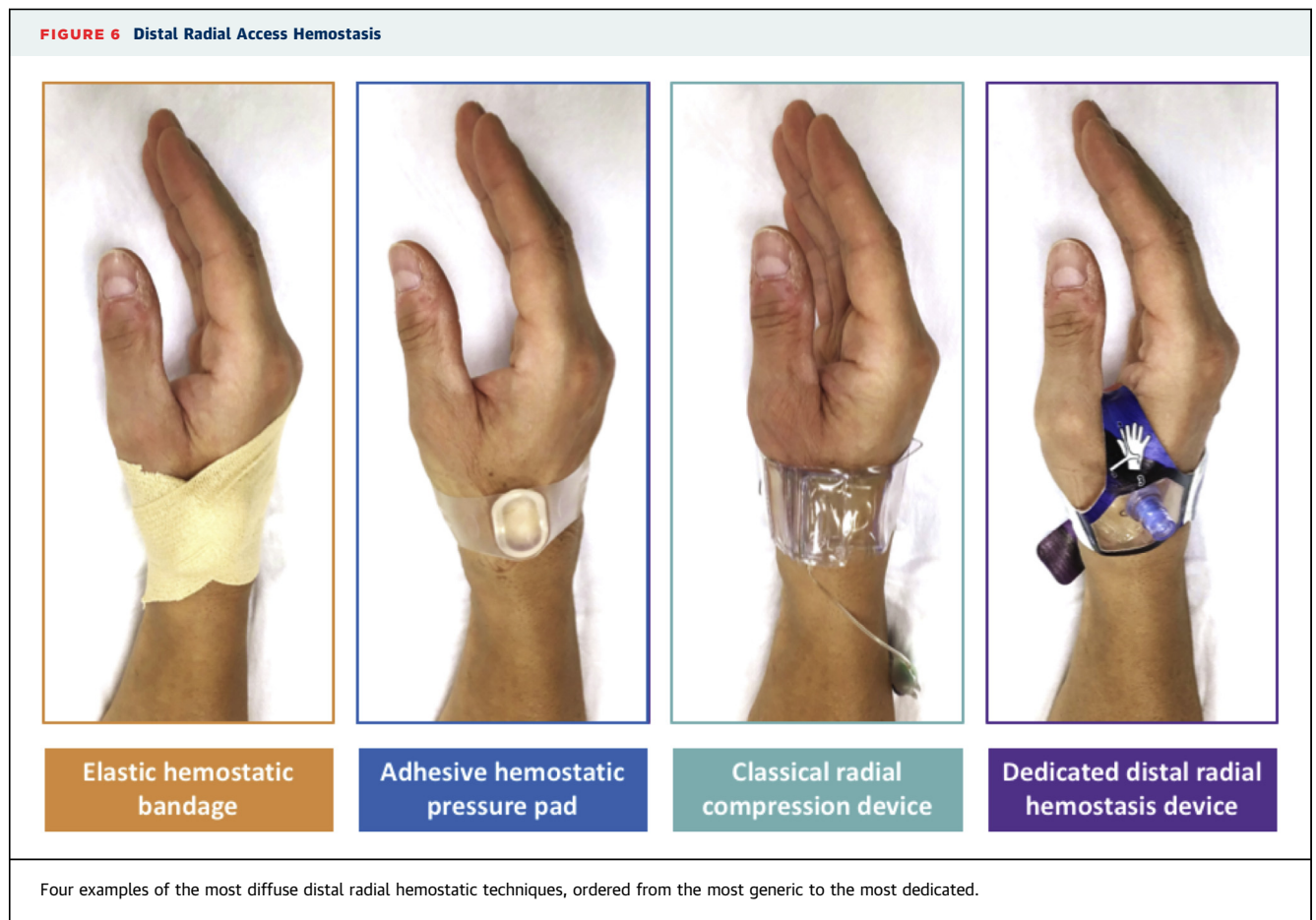
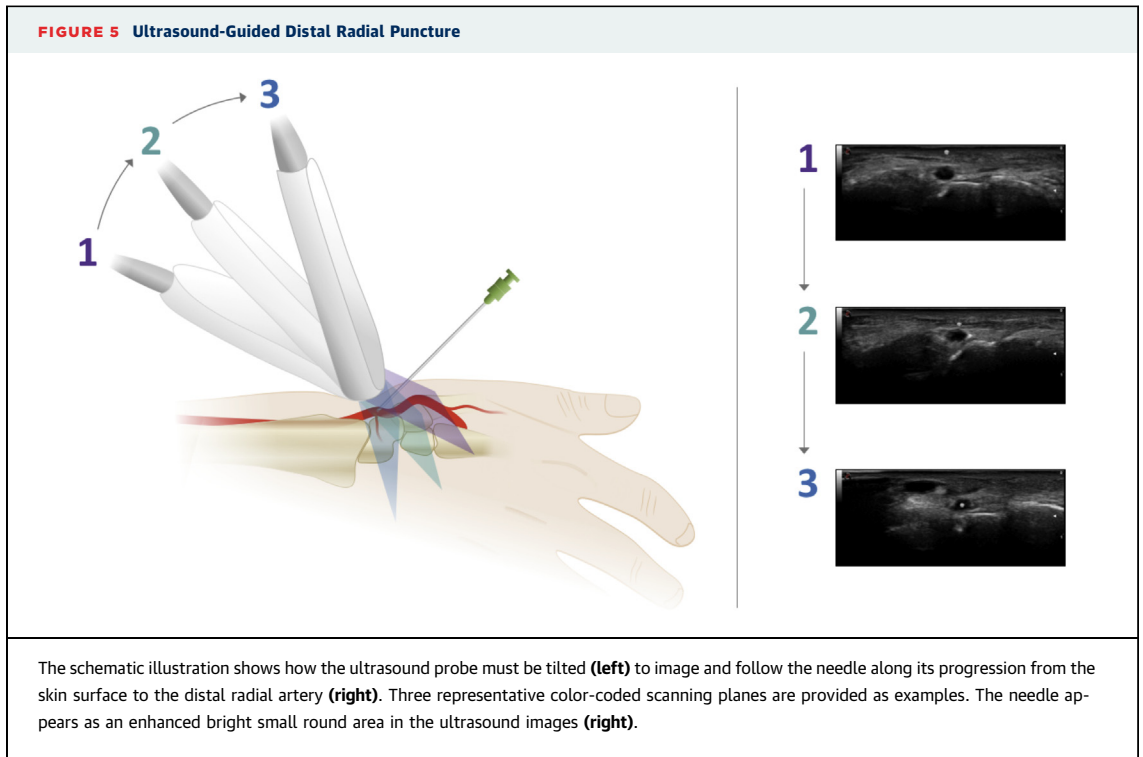
along its whole trajectory until its entry in the arterial lumen is seen on the screen and is confirmed by blood return from the needle hub (Figure 5). In this way, it is possible to safely and effectively reposition the needle tip that does not appear to be directed to the radial artery.

Korean-European consensus opinion: Developing proficiency in ultrasound-guided arterial puncture may enhance one's DRA practice. Upstream use of ultrasound makes it possible to measure the artery and to devise optimal sheath and catheter selection for the best procedure outcome.

HEMOSTASIS AND BLEEDING

After the procedure, hemostasis may be easily achieved with a system implementing either 2 or 3 anchor points, such as a hemostasis device or a gauze plug wrapped with a tight elastic bandage or a special hemostasis device (Figure 6). To date, only 1 dedicated anatomic snuffbox compression device has been developed in right and left versions (62). Otherwise, a conventional wristlet-type radial compression band performs well in stopping distal radial artery bleeding, providing removal of any hard plastic element, to allow optimal conformation to the hand anatomy and thus prevent slipping from the puncture site. Hemostatic patches have also reported to improve hemostasis after DRA (63). There are no randomized studies comparing the safety and efficacy of the different hemostatic methods. In the anatomic snuffbox, the carpal bones offer a parallel plane for lighter compression to be effective and safe in contrast to what occurs at the conventional TRA puncture site, where the radius bone is at an oblique angle to the anterior forearm surface. Whether absence of such a bony floor may potentially affect the efficacy and safety of hemostasis after DRA on the dorsum of the hand cannot be established from the limited published experience with puncture at this site.

Moreover, being distal to the carpal anastomotic branches, DRA allows persistent flow in the forearm radial artery without any particular effort in managing distal radial hemostasis. In contrast, there is substantial lack of knowledge on distal RAO, and given its position within an anastomotic network, assessing its patency during and after hemostasis is more difficult. However, the expected smaller diameter and lower blood flow velocity of the distal radial artery provide a relevant opportunity for systematically shorter and nonocclusive hemostasis in order to pursue the lowest probability of distal RAO (46,61). Also, in the anatomic snuffbox, the



distal radial artery takes place in a groove that prevents flow interruption even in case of hard compression and favors a kind of natural patent hemostasis. Still, the radial artery distal to the tendon of the extensor pollicis longus is more superficial and embedded in small muscles and compression may potentially lead to less predictable results.

Certainly, concerns about serious site complications have proved unfounded so far. To date, only a few vascular complications have been reported (64-66). Hematoma can be large given the loose hand subcutaneous tissue, but in the only reported case, the hematoma did not propagate to the lower forearm area (64). Pseudoaneurysm formation has also been described (65). Prevention of those complications depends on optimal puncture, effective hemostasis, and close monitoring of the hand, while treatment should be directed at contrasting pressure increase in the subcutaneous space by elevating the hand and carefully reducing the arterial inflow with appropriate compression, possibly involving the upstream radial artery at the wrist level. Finally, caution has been raised about DRA and the risk for ischemic damage to the wrist bones. However, such an event has never been reported and appears quite unlikely, because the radial dorsal and palmar branches to the scaphoid arise proximal to the anatomic snuffbox at the level of the styloid process of the radius and at the level of the radioscaphoid joint (16,67).

Korean-European consensus opinion: Current data and experience suggest that the standard compression method routinely used in the particular catheterization laboratory for conventional TRA or a dedicated anatomic snuffbox compression device appear equally effective for DRA hemostasis that should be as light and short as possible.

OPERATIONAL DEFINITIONS

To promote a homogenous diffusion of DRA and allow meaningful comparisons between published reports and clinical studies, a common nomenclature is essential. Because of the technical features of distal radial artery, an operational approach to terminology definition has been selected and presented in Table 3.

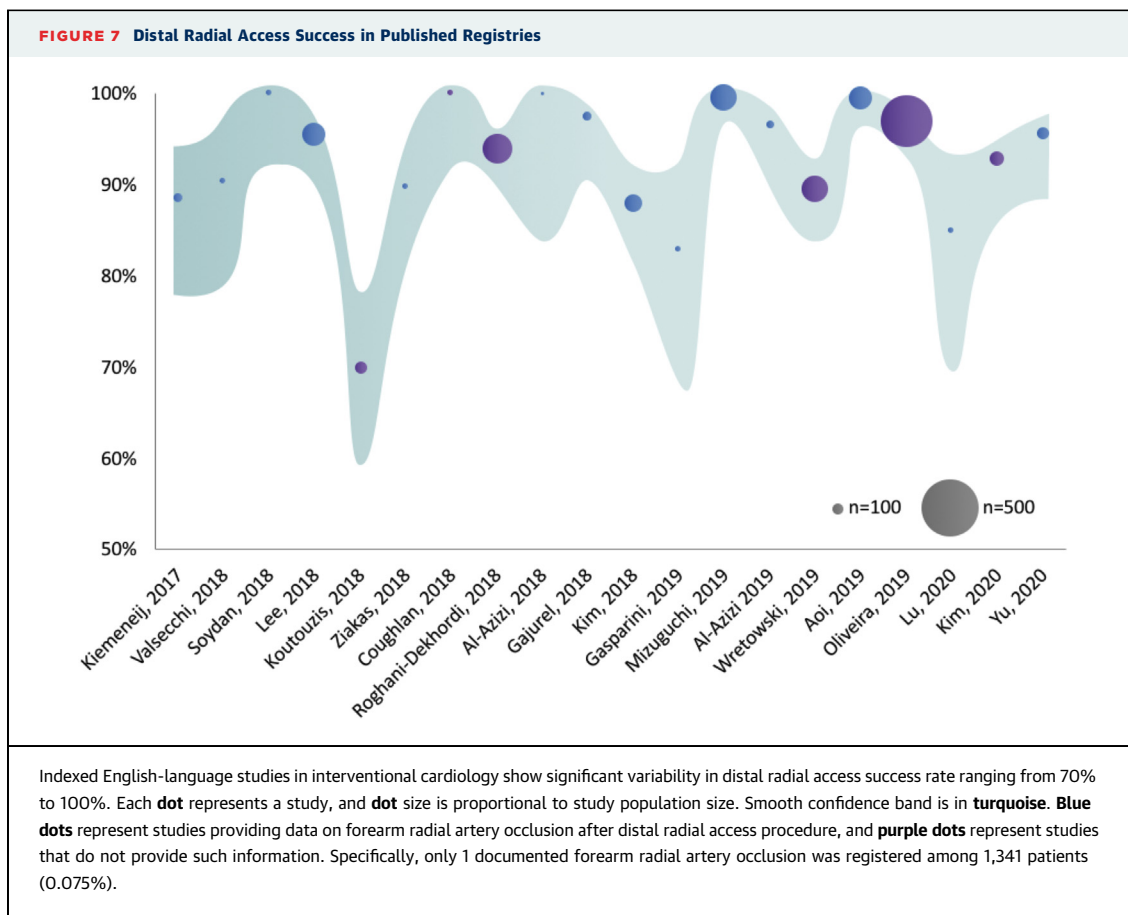
Korean-European consensus opinion: A common use of terms should be pursued to appropriately share and effectively compare different experiences with DRA and allow systematic comparisons with conventional TRA and femoral access.

TABLE 3 Operational Definitions

Distal radial artery	Radial artery in a palpable site distal to the styloid process of the radius bone. This term includes radial artery in the distinct anatomic area known as the anatomic snuffbox and radial distal to the tendons on the dorsum of the hand. This latter term is simpler and should be preferred to "first intermetacarpal space" (too complex) or "very distal radial artery" (redundant).
Conventional radial artery	Radial artery proximal to the styloid process of the radius bone. This term is preferred to "traditional radial artery" (less scientific) or "proximal radial artery" (proximal radial artery is indeed generally at the elbow level).
Distal radial access	Vascular access in the distal radial artery.
Transradial access	Vascular access in the conventional radial artery.
Puncture attempt	Each insertion of the needle in the skin. Slight redirection of the needle when still in the skin does not constitute a second puncture attempt
Puncture success	Occurs when a guidewire can be introduced through the punctured artery.
Puncture time	Starts when the puncture needle contacts the skin and stops when the guidewire passes through the puncture needle into the artery.
Access success	Occurs when an introducer sheath can be properly placed through the punctured artery.
Access time	Starts when the anesthesia needle contacts the skin and stops when the introducer sheath has been properly placed.
Access switch	Occurs when puncture is unsuccessful or when a successfully punctured artery site is abandoned in favor of another site in the same artery (e.g., from distal radial artery in the anatomic snuffbox to conventional radial artery at the wrist level or from a puncture site distal to the extensor pollicis longus tendon to a puncture site proximal to it or vice versa) or another site in another artery (e.g., from right distal radial artery to left distal radial artery).

CURRENT LANDSCAPE

Preliminary outcome data on DRA are limited mainly to observational studies showing rather promising results (1,34). Indeed, DRA feasibility is supported by an overall high rate of success despite considerable variability among studies (Figure 7). Notably, in most instances, investigators' very first DRA procedures were included, hence grounding the exploratory phase of this new approach. Procedural characteristics showed important variability too, reflecting comparable investigational earliness. More remarkably, no major safety issue has been reported so far among published registries, pointing out a very low incidence of radial artery spasm, shorter time to hemostasis, and a substantial absence of forearm RAO despite no mention of any dedicated strategy to favor vessel patency. Specifically, after DRA, only 1 forearm RAO was registered among 1,341 patients (0.075%) enrolled in 14 observational studies reporting this complication. Finally, available registries highlight that DRA may allow the very same procedures as conventional TRA, including intervention for left main coronary artery and complex bifurcation lesion; intravascular imaging; intravascular shockwave lithotripsy and



rotational atherectomy; primary angioplasty; chronic total occlusion intervention; peripheral intervention for the carotid, lower extremity, and radial artery itself; and even balloon aortic valvuloplasty (3,31,42,49,63,68-72). Also, DRA is increasingly used in interventional radiology and interventional neuroradiology practice (3,73-77).

Korean-European consensus opinion: Multinational observational studies assessing the feasibility of DRA have consistently shown its efficacy and safety in a large range of settings. DRA appears to combine the advantages of conventional TRA with additional benefits to patients. Randomized clinical trials comparing DRA with conventional TRA are expected to definitively establish its role in interventional cardiology.

TRANSITION TO DRA

A good understanding of transradial practice is an indispensable requirement to start a DRA experience. If available, operators should try to gain some

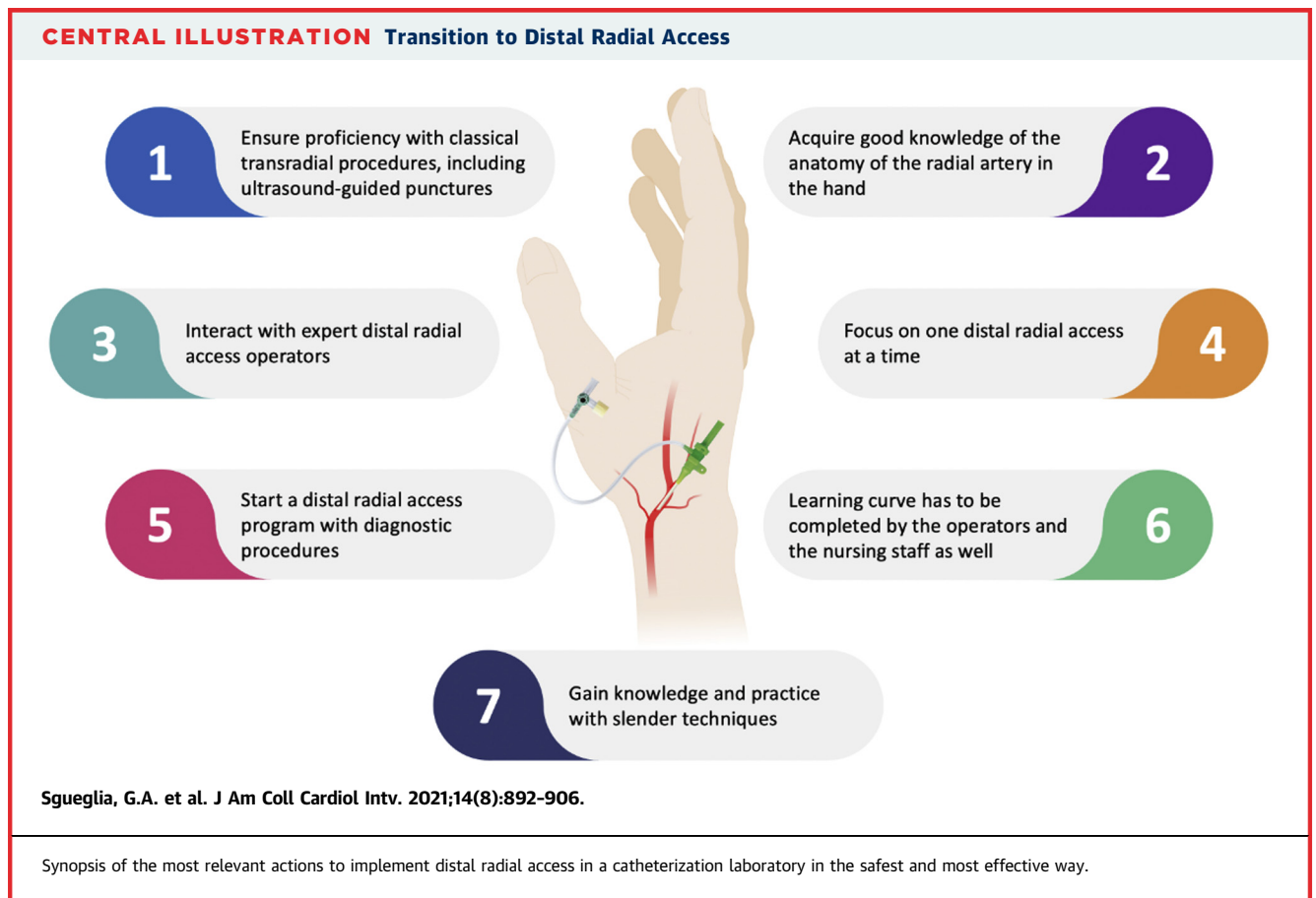
familiarity with ultrasound-guided conventional radial technique (78) prior to applying this technique to DRA (61). Good knowledge of the anatomy of the radial artery in the hand is absolutely essential to aspire to effective and reliable distal radial artery puncture (23). Familiarity with anatomic landmarks and surrounding structures will enhance puncture safety and also lower its intrinsic complexity. Attending a DRA educational event or interacting with an expert DRA operator can significantly boost one's confidence with a different, initially more demanding access route. Accessing the distal radial artery in the anatomic snuffbox may appear easier during the learning curve. Given the different course of the radial artery in the anatomic snuffbox and on the dorsum of the hand and the different puncture techniques required to successfully obtain DRA at these 2 sites, it is wise to focus and master 1 of the 2 DRA techniques at a time. Starting a DRA program with diagnostic procedures characterized by expectedly lower anti-coagulation is also advisable to limit potential

complications while mastering DRA hemostasis. Given the potentially different setup for distal radial artery puncture and the potentially different hemostasis technique compared with conventional TRA, the learning curve must be completed by both the operator and the nursing staff. In a TRA-proficient catheterization laboratory, the path to DRA may still be quite lengthy and hence a little bit frustrating. For conventional TRA, the threshold to overcome the learning curve appears to be approximately 30 to 50 cases (79). It is likely that the learning curve is not shorter for DRA (24). When the catheterization laboratory team is fully confident with DRA in diagnostic procedures in patients in stable condition, those in less stable condition and more complex procedures may then be progressively approached. Finally, given the slightly smaller diameter of the distal radial artery compared with the forearm radial artery (4,34,56,57), every procedure should be performed with the smallest possible introducer sheath and catheter combination to allow a safe and effective case according to the operator's confidence (20). Yet operators should gain knowledge and practice with

TABLE 4 Main Features of Devices Allowing Slender Distal Radial Access Coronary Procedures

Device	Advantages	Limitations
Thin-walled introducer	Lower outer diameter allowing for about 1 F savings due to reduced wall thickness	Risk of kinking with some technologies
Dedicated sheathless guide catheter	Larger inner diameter in relation to the overall outside diameter Safe guide catheter upsizing	Higher costs Limited curve options
Dedicated sheathless access system	Use of any guide catheter with a smaller access profile Safe guide catheter upsizing	Additional cost of the long vessel dilator Size specificity of the long vessel dilator
Sheathless balloon assisted tracking	Use of any guide catheter with a smaller access profile Safe guide catheter upsizing	Advanced technique Higher risk for entry point vessel damage

slender techniques and sheathless guide strategies to offer the advantages of DRA to an increasing proportion of patients (Table 4) (80). The most important steps for a safe and effective transition to DRA are summarized in the Central Illustration.



Korean-European consensus opinion: Mastering DRA is an investment in the best outcomes for patients and in a higher quality of one's interventional practice.

FUTURE PERSPECTIVES

Currently available information points toward DRA as a very promising alternative to conventional TRA (23,81). However, present knowledge is rather incomplete. A rigorous trial comparing DRA with conventional TRA assessing the rate of RAO according to a randomized design is certainly the most eagerly expected among interventional cardiologists. Yet further details are equally important. Tall and small patients may represent a potential limitation of DRA because of insufficient length of conventional catheters and very small artery diameter requiring sheathless techniques, respectively. Whether DRA is systematically effective in those population remains to be established. Anatomic and functional assessment of radial artery patency after DRA would also be needed. A better understanding of the optimal anticoagulation strategy, hemostasis duration, and type of compression as well as their interaction is necessary to ensure the highest safety standards. Very few vascular complications have been reported to date, suggesting an extremely low rate of access-related issues (81). Whether the current estimate is accurate must be determined, as well as any possible relation of vascular complications with anticoagulation and hemostasis. On this background the role of DRA in primary percutaneous coronary intervention needs to be thoughtfully ascertained. Accordingly, the potential of DRA as the default alternative access in case of

conventional TRA failure or dual DRA as the safest and most comfortable approach for chronic total occlusion percutaneous coronary intervention should be carefully evaluated. Also, whether there is a need and a way to test for patent hemostasis is worth clarification. Finally, hand function after DRA and both operator and patient radiation exposure during DRA deserve to be explored.

Korean-European consensus opinion: The great enthusiasm and interest surrounding DRA should promote scientific initiatives aimed at providing definite answers to the many existing queries.

ACKNOWLEDGMENTS The authors acknowledge Seung-Hwan Lee, MD, PhD, and Sung Yun Lee, MD, PhD, respectively past and present chairmen of the Korean Transradial Intervention working group, and In-Ho Chae, MD, PhD, president of the Korean Society of Interventional Cardiology, for their devotion to the authors' work. The authors also thank Jai-Wun Park, MD, Ulf Landmesser, MD, PhD, and Sang-Wook Kim, MD, PhD, for hosting the CHORUS Berlin 2019 meeting and Ferdinand Kiemeneij, MD, PhD, for his inspiration and for encouraging the European team to get in touch with the Korean team and make friends.

FUNDING SUPPORT AND AUTHOR DISCLOSURES

The authors have reported that they have no relationships relevant to the contents of this paper to disclose.

ADDRESS FOR CORRESPONDENCE: Dr. Gregory A. Sgueglia, UOC Cardiology, Ospedale Sant'Eugenio, 10 Piazzale dell'Umanesimo, 00144 Rome, Italy. E-mail: g.a.sgueglia@gmail.com.

REFERENCES

- Kiemeneij F. Left distal transradial access in the anatomical snuffbox for coronary angiography (ldTRA) and interventions (ldTRI). *EuroIntervention* 2017;13:851-7.
- Davies RE, Gilchrist IC. Back hand approach to radial access: the snuff box approach. *Cardiovasc Revasc Med* 2018;19:324-6.
- Nardai S, Vegh E, Orias V, et al. Feasibility of distal radial access for carotid interventions: the RADCAR-DISTAL pilot study. *EuroIntervention* 2020;15:1288-90.
- Lee JW, Park SW, Son JW, Ahn SG, Lee SH. Real-world experience of the left distal transradial approach for coronary angiography and percutaneous coronary intervention: a prospective observational study (LeDRA). *EuroIntervention* 2018;14:e995-1003.
- Valgimigli M, Gagnor A, Calabro P, et al. Radial versus femoral access in patients with acute coronary syndromes undergoing invasive management: a randomised multicentre trial. *Lancet* 2015;385:2465-76.
- Ferrante G, Rao SV, Juni P, et al. Radial versus femoral access for coronary interventions across the entire spectrum of patients with coronary artery disease: a meta-analysis of randomized trials. *J Am Coll Cardiol Intv* 2016;9:1419-34.
- Ratib K, Mamas MA, Anderson SG, et al. Access site practice and procedural outcomes in relation to clinical presentation in 439,947 patients undergoing percutaneous coronary intervention in the United Kingdom. *J Am Coll Cardiol Intv* 2015;8:20-9.
- Ibanez B, James S, Agewall S, et al. 2017 ESC guidelines for the management of acute myocardial infarction in patients presenting with ST-segment elevation: the Task Force for the Management of Acute Myocardial Infarction in Patients Presenting With ST-Segment Elevation of the European Society of Cardiology (ESC). *Eur Heart J* 2018;39:119-77.
- Mason PJ, Shah B, Tamis-Holland JE, et al. An update on radial artery access and best practices for transradial coronary angiography and intervention in acute coronary syndrome: a scientific statement from the American Heart Association. *Circ Cardiovasc Interv* 2018;11:e000035.
- Cooper CJ, El-Shiekh RA, Cohen DJ, et al. Effect of transradial access on quality of life and cost of cardiac catheterization: a randomized comparison. *Am Heart J* 1999;138:430-6.
- Amin AP, Pinto D, House JA, et al. Association of same-day discharge after elective percutaneous coronary intervention in the United States with costs and outcomes. *JAMA Cardiol* 2018;3:1041-9.
- Rao SV, Cohen MG, Kandzari DE, Bertrand OF, Gilchrist IC. The transradial approach to

percutaneous coronary intervention: historical perspective, current concepts, and future directions. *J Am Coll Cardiol* 2010;55:2187-95.

13. Shroff AR, Fernandez C, Vidovich MI, et al. Contemporary transradial access practices: Results of the second international survey. *Catheter Cardiovasc Interv* 2019;93:1276-87.
14. Rashid M, Kwok CS, Pancholy S, et al. Radial artery occlusion after transradial interventions: a systematic review and meta-analysis. *J Am Heart Assoc* 2016;5:e002686.
15. Hahalis G, Azaouridis K, Tsigkas G, et al. Radial artery and ulnar artery occlusions following coronary procedures and the impact of anticoagulation: ARTEMIS (Radial and Ulnar Artery Occlusion Meta-Analysis) systematic review and meta-analysis. *J Am Heart Assoc* 2017;6:e005430.
16. Freedman DM, Botte MJ, Gelberman RH. Vascularity of the carpus. *Clin Orthop Relat Res* 2001;383:47-59.
17. Uhlemann M, Mobius-Winkler S, Mende M, et al. The Leipzig prospective vascular ultrasound registry in radial artery catheterization: impact of sheath size on vascular complications. *J Am Coll Cardiol Interv* 2012;5:36-43.
18. Sciahbasi A, Rigattieri S, Sarandrea A, et al. Radial artery occlusion and hand strength after percutaneous coronary procedures: results of the HANGAR study. *Catheter Cardiovasc Interv* 2016; 87:868-74.
19. van der Heijden DJ, van Leeuwen MAH, Ritt M, van de Ven PM, van Royen N. Chronic radial artery occlusion does not cause exercise induced hand ischemia. *J Interv Cardiol* 2018;31:949-56.
20. Bernat I, Aminian A, Pancholy S, et al. Best practices for the prevention of radial artery occlusion after transradial diagnostic angiography and intervention: an international consensus paper. *J Am Coll Cardiol Interv* 2019;12:2235-46.
21. Abdelaal E, Molin P, Plourde G, et al. Successive transradial access for coronary procedures: experience of Quebec Heart-Lung Institute. *Am Heart J* 2013;165:325-31.
22. Mamas MA, Fraser DG, Ratib K, et al. Minimising radial injury: prevention is better than cure. *EuroIntervention* 2014;10:824-32.
23. Sgueglia GA, Di Giorgio A, Gaspardone A, Babunashvili A. Anatomic basis and physiological rationale of distal radial artery access for percutaneous coronary and endovascular procedures. *J Am Coll Cardiol Interv* 2018;11:2113-9.
24. Kaledin AL, Kochanov IN, Seletskii SS, Arkharov IV, Ia Burak T, Kozlov KL. Peculiarities of arterial access in endovascular surgery in elderly patients. *Adv Gerontol* 2014;27:115-9.
25. Roghani-Dehkordi F, Hashemifard O, Sadeghi M, et al. ARYA Atheroscler 2018;14: 95-100.
26. Radner S. Thoracic aortography by catheterization from the radial artery; preliminary report of a new technique. *Acta Radiol* 1948;29:178-80.
27. Campeau L. Percutaneous radial artery approach for coronary angiography. *Cathet Cardiovasc Diagn* 1989;16:3-7.
28. Kiemeneij F, Laarman GJ. Percutaneous transradial artery approach for coronary stent implantation. *Cathet Cardiovasc Diagn* 1993;30: 173-8.
29. Amato JJ, Solod E, Cleveland RJ. A "second" radial artery for monitoring the perioperative pediatric cardiac patient. *J Pediatr Surg* 1977;12: 715-7.
30. Pyles ST, Scher KS, Vega ET, Harrah JD, Rubis LJ. Cannulation of the dorsal radial artery: a new technique. *Anesth Analg* 1982;61:876-8.
31. Babunashvili A, Dundua D. Recanalization and reuse of early occluded radial artery within 6 days after previous transradial diagnostic procedure. *Catheter Cardiovasc Interv* 2011;77:530-6.
32. Serruys PW, Onuma Y. Twitterature: will social media have an impact on scientific journals? *EuroIntervention* 2018;14:e962-4.
33. Capodanno D. Twitterature. *EuroIntervention* 2018;14:e959-61.
34. Valsecchi O, Vassileva A, Cereda AF, et al. Early clinical experience with right and left distal transradial access in the anatomical snuffbox in 52 consecutive patients. *J Invasive Cardiol* 2018;30: 218-23.
35. Soydan E, Akin M. Coronary angiography using the left distal radial approach—an alternative site to conventional radial coronary angiography. *Anatol J Cardiol* 2018;19:243-8.
36. Koutouzis M, Kontopodis E, Tassopoulos A, et al. Distal versus traditional radial approach for coronary angiography. *Cardiovasc Revasc Med* 2019;20:678-80.
37. Ziakas A, Koutouzis M, Didagelos M, et al. Right arm distal transradial (snuffbox) access for coronary catheterization: initial experience. *Hellenic J Cardiol* 2020;61:106-9.
38. Coughlan JJ, Zebrauskaite A, Arnous S, Kiernan TJ. Left distal trans-radial access facilitates earlier discharge post-coronary angiography. *J Interv Cardiol* 2018;31:964-8.
39. Al-Azizi KM, Lotfi AS. The distal left radial artery access for coronary angiography and intervention: a new era. *Cardiovasc Revasc Med* 2018; 19:35-40.
40. Gajurel RM, Sahi R, Shrestha H, Thapa S, Khanal R. Initial experience on anatomical snuff box approach for coronary angiogram & percutaneous coronary intervention in a tertiary care center Nepal. *World J Cardiovasc Dis* 2018;8: 578-87.
41. Kim Y, Ahn Y, Kim I, et al. Feasibility of coronary angiography and percutaneous coronary intervention via left snuffbox approach. *Korean Circ J* 2018;48:1120-30.
42. Gasparini GL, Garbo R, Gagnor A, Oreglia J, Mazarrotto P. First prospective multicentre experience with left distal transradial approach for coronary chronic total occlusion interventions using a 7 Fr Glidesheath Slender. *EuroIntervention* 2019;15:126-8.
43. Mizuguchi Y, Izumikawa T, Hashimoto S, et al. Efficacy and safety of the distal transradial approach in coronary angiography and percutaneous coronary intervention: a Japanese multicenter experience. *Cardiovasc Interv Ther* 2020;35:162-7.
44. Al-Azizi KM, Grewal V, Gobeil K, et al. The left distal transradial artery access for coronary angiography and intervention: a US experience. *Cardiovasc Revasc Med* 2019;20:786-9.
45. Wretowski D, Krakowian M, Łabyk A, Pruszczyk P, Roik M. Very distal transradial approach (VITRO) for coronary interventions. *Postepy Kardiologii Interwencyjnej* 2019;15:42-5.
46. Aoi S, Htun WW, Freeo S, et al. Distal transradial artery access in the anatomical snuffbox for coronary angiography as an alternative access site for faster hemostasis. *Catheter Cardiovasc Interv* 2019;94:651-7.
47. Oliveira MDP, Navarro EC, Kiemeneij F. Distal transradial access as default approach for coronary angiography and interventions. *Cardiovasc Diagn Ther* 2019;9:513-9.
48. Lu H, Wu D, Chen X. Comparison of distal transradial access in anatomic snuffbox versus transradial access for coronary angiography. *Heart Surg Forum* 2020;23:E407-10.
49. Kim Y, Lee JW, Lee SY, et al. Feasibility of primary percutaneous coronary intervention via the distal radial approach in patients with ST-elevation myocardial infarction. *Korean J Intern Med* 2021;36 suppl 1:S53-61.
50. Yu W, Hu P, Wang S, et al. Distal radial artery access in the anatomical snuffbox for coronary angiography and intervention: a single center experience. *Medicine* 2020;99:e18330.
51. Sgueglia GA, Santoliquido A, Gaspardone A, Di Giorgio A. First results of the Distal Radial Access Doppler study. *J Am Coll Cardiol Img.* 2021 Jan 4 [E-pub ahead of print].
52. Campeau L. Entry sites for coronary angiography and therapeutic interventions: from the proximal to the distal radial artery. *Can J Cardiol* 2001;17:319-25.
53. Zarzecki MP, Popieluszko P, Zayachkowski A, Pekala PA, Henry BM, Tomaszewski KA. The surgical anatomy of the superficial and deep palmar arches: a meta-analysis. *J Plast Reconstr Aesthet Surg* 2018;71:1577-92.
54. Kim Y, Lee SY, Lee DI, et al. Assessment of the conventional radial artery with optical coherent tomography after the snuffbox approach. *Cardiol* 2020 Jul 25 [E-pub ahead of print].
55. Yonetsu T, Kakuta T, Lee T, et al. Assessment of acute injuries and chronic intimal thickening of the radial artery after transradial coronary intervention by optical coherence tomography. *Eur Heart J* 2010;31:1608-15.
56. Norimatsu K, Kusumoto T, Yoshimoto K, et al. Importance of measurement of the diameter of the distal radial artery in a distal radial approach from the anatomical snuffbox before coronary catheterization. *Heart Vessels* 2019;34:1615-20.
57. Hadjivassiliou A, Cardarelli-Leite L, Jalal S, et al. Left distal transradial Access (IdTRA): a comparative assessment of conventional and distal radial artery size. *Cardiovasc Intervent Radiol* 2020;43:850-7.
58. Chen Y, Ke Z, Xiao J, et al. Subcutaneous injection of nitroglycerin at the radial artery

- puncture site reduces the risk of early radial artery occlusion after transradial coronary catheterization: a randomized, placebo-controlled clinical trial. *Circ Cardiovasc Interv* 2018;11:e006571.
59. Moussa Pacha H, Alahdab F, Al-Khadra Y, et al. Ultrasound-guided versus palpation-guided radial artery catheterization in adult population: a systematic review and meta-analysis of randomized controlled trials. *Am Heart J* 2018;204:1-8.
60. Mori S, Hirano K, Yamawak M, et al. A comparative analysis between ultrasound-guided and conventional distal transradial access for coronary angiography and intervention. *J Interv Cardiol* 2020;2020:7342732.
61. Hadjivassiliou A, Kiemeneij F, Nathan S, Klass D. Ultrasound-guided access of the distal radial artery at the anatomical snuffbox: a technical guide. *EuroIntervention* 2021;16:1342-8.
62. Kawamura Y, Yoshimachi F, Nakamura N, Yamamoto Y, Kudo T, Ikari Y. Impact of dedicated hemostasis device for distal radial arterial access with an adequate hemostasis protocol on radial arterial observation by ultrasound. *Cardiovasc Interv Ther* 2021;36:104-10.
63. Hadjivassiliou A, Cardarelli-Leite L, Jalal S, et al. Safety and efficacy of a truncated deflation algorithm for distal transradial access. *J Vasc Interv Radiol* 2020;31:1328-33.
64. Koutouzis M, Kontopodis E, Tassopoulos A, Tsiafoutis I, Lazaris E. Hand hematoma after cardiac catheterization via distal radial artery. *J Invasive Cardiol* 2018;30:428.
65. Mizuguchi Y, Yamada T, Taniguchi N, Nakajima S, Hata T, Takahashi A. Pseudoaneurysm formation after cardiac catheterization using the distal transradial approach. *J Invasive Cardiol* 2019;31:E257.
66. Shah SR, Kiemeneij F, Khuddus MA. Distal arteriovenous fistula formation after percutaneous coronary intervention: an old complication of a new access site. *Catheter Cardiovasc Interv* 2021; 97:278-81.
67. Gelberman RH, Menon J. The vascularity of the scaphoid bone. *J Hand Surg Am* 1980;5: 508-13.
68. Sgueglia GA, Gioffre G, Piccioni F, Gaspardone A. Slender distal radial five French coronary shockwave lithotripsy. *Catheter Cardiovasc Interv* 2019;94:395-8.
69. Bae DH, Lee SY, Lee DI, Kim SM, Bae JW, Hwang KK. Percutaneous angioplasty at previous radial puncture site via distal radial access of anatomical snuffbox. *Cardiol J* 2019; 26:610-1.
70. Kim Y, Jeong MH, Kim MC, et al. Successful percutaneous coronary intervention with two-stent technique for unprotected true left main bifurcation lesion via left snuffbox approach. *J Invasive Cardiol* 2019;31:E55.
71. Kim Y, Jeong MH, Kim I, et al. Intravascular ultrasound-guided percutaneous coronary intervention with drug-eluting stent for unprotected left main disease via left snuffbox approach. *Korean Circ J* 2018;48:532-3.
72. Di Cesare A, Tonet E, Campo G, Tumscitz C. Snuffbox approach for balloon aortic valvuloplasty: a case series. *Catheter Cardiovasc Interv* 2020 Aug 13 [E-pub ahead of print].
73. Pua U, Sim JZT, Quek LHH, Kwan J, Lim GHT, Huang IKH. Feasibility study of "snuffbox" radial access for visceral interventions. *J Vasc Interv Radiol* 2018;29:1276-80.
74. van Dam L, Geeraedts T, Bijdevaate D, van Doormaal PJ, The A, Moelker A. Distal radial artery access for noncoronary endovascular treatment is a safe and feasible technique. *J Vasc Interv Radiol* 2019;30:1281-5.
75. Kühn AL, de Macedo Rodrigues K, Singh J, Massari F, Puri AS. Distal radial access in the anatomical snuffbox for neurointerventions: a feasibility, safety, and proof-of-concept study. *J Neurointerv Surg* 2020;12:798-801.
76. Park SE, Cho SB, Baek HJ, et al. Clinical experience with distal transradial access for endovascular treatment of various noncoronary interventions in a multicenter study. *PLoS ONE* 2020;15:e0237798.
77. Weinberg JH, Sweid A, Khanna O, et al. Access through the anatomical snuffbox for neuro-endovascular procedures: a single institution series. *Oper Neurosurg* 2020;19:495-501.
78. Ailon J, Mourad O, Chien V, Saun T, Dev SP. Videos in clinical medicine. Ultrasound-guided insertion of a radial arterial catheter. *N Engl J Med* 2014;371:e21.
79. Hess CN, Peterson ED, Neely ML, et al. The learning curve for transradial percutaneous coronary intervention among operators in the United States: a study from the National Cardiovascular Data Registry. *Circulation* 2014;129: 2277-86.
80. Kiemeneij F, Yoshimachi F, Matsukage T, et al. Focus on maximal miniaturisation of transradial coronary access materials and techniques by the Slender Club Japan and Europe: an overview and classification. *EuroIntervention* 2015; 10:1178-86.
81. Coomes EA, Haghbayan H, Cheema AN. Distal transradial access for cardiac catheterization: a systematic scoping review. *Catheter Cardiovasc Interv* 2020;96:1381-9.

KEY WORDS anatomic snuffbox, consensus, distal radial access, transradial access