

Horizontal Effects of 10-mm Inferior Oblique Recession versus 14-mm Inferior Oblique Recession

Jae Min Kim¹, Ungsoo Samuel Kim^{1,2}

¹Kim's Eye Hospital, Seoul, Korea

²Department of Ophthalmology, Konyang University College of Medicine, Daejeon, Korea

Purpose: The aim of this study was to investigate the quantitative effect of inferior oblique (IO) 10- and 14-mm recession on postoperative horizontal deviation.

Methods: Patients (22 men and 18 women) who underwent IO recession were divided into two groups for comparison studies: group 1 (10-mm IO recession, 15 patients) and group 2 (14-mm IO recession, 25 patients). Preoperative and postoperative horizontal deviations were measured, and the resulting horizontal deviations from the 10- and 14-mm IO recession surgeries were compared. The effects of superior oblique underaction, IO overaction, and combined exodeviation on postoperative horizontal deviation were analyzed.

Results: Although group 1 did not show a significant horizontal deviation change after surgery (1.9 ± 4.5 prism diopters [PD], $p = 0.452$), group 2 had a meaningful horizontal change after 14-mm recession (2.2 ± 3.8 PD, $p = 0.022$). Both groups showed a significant esodrift in horizontal deviation (group 1, $p = 0.017$; group 2, $p = 0.030$) in patients with exodeviation over 8 PD. The mean change in horizontal deviation was 6.0 ± 5.4 PD for group 1 and 9.0 ± 5.0 PD for group 2. Although the amount of superior oblique underaction did not affect the extent of change in horizontal deviation, patients with severe IO overaction showed a significant change in horizontal deviation after 14-mm IO recession.

Conclusions: Fourteen-millimeter IO recession could make a statistically significant change in horizontal deviation after surgery. In addition, esodrift should be considered after IO recession in patients with a preoperative exodeviation greater than 8 PD or severe IO overaction.

Key Words: Strabismus, Superior oblique palsy, Surgical treatment

Superior oblique (SO) palsy is the most common form of single ocular muscle palsy. Treatment of SO palsy involves strengthening of the SO muscle and weakening of the inferior oblique (IO) muscle. Surgeries involving IO weakening

include IO disinsertion, IO myectomy, IO anterior transposition, IO recession, and IO denervation and extirpation [1].

The function of the IO muscle is to provide ocular movement in the form of denervation and extirpation (primarily extorsion), elevation, and abduction [2]. A secondary function of the SO muscle is abduction. Therefore, a surgery that weakens either the IO or SO muscle could affect abduction and result in esodeviation [2-4]. The effects of IO weakening surgery on horizontal deviation of the eye have been a topic of debate in the past. Jampel [5] reported that

Received: April 10, 2018 Accepted: June 19, 2018

Corresponding Author: Ungsoo Samuel Kim, MD. Department of Ophthalmology, Kim's Eye Hospital, #136 Yeongsin-ro, Yeongdeungpo-gu, Seoul 07301, Korea. Tel: 82-2-2639-7517, Fax: 82-2-2677-9214, E-mail: ungsookim@kimeye.com

© 2018 The Korean Ophthalmological Society

This is an Open Access article distributed under the terms of the Creative Commons Attribution Non-Commercial License (<http://creativecommons.org/licenses/by-nc/3.0/>) which permits unrestricted non-commercial use, distribution, and reproduction in any medium, provided the original work is properly cited.

IO recession does not significantly affect horizontal deviation or surgery results. However, several studies have demonstrated an esoshift upon IO recession, from 5 to 10 prism diopters (PD) [6,7]. However, previous reports did not analyze the effects of IO recession and preoperative horizontal deviation. Therefore, we evaluated the quantitative effect of IO recession and preoperative horizontal deviation on postoperative horizontal deviation in SO palsy patients.

Materials and Methods

This study was a non-randomized, retrospective review of the medical records of 40 patients diagnosed with SO palsy at Kim's Eye Hospital between 2010 and 2015. SO palsy was defined as positive in the three-step test. Patients with a history of blow-out fracture and surgeries of the strabismus, simultaneous horizontal muscle, or vertical rectus muscle were not considered for the study. Definition of congenital SO palsy was as follows: manifested in childhood, larger than normal vertical fusion amplitude, and/or presence of facial asymmetry. Cyclotropia, head tilt toward the involved side, or absence of abnormal head posture limits the diagnostic criteria of acquired SO palsy. The research was approved by the institutional review board at Kim's Eye Hospital (2017-05-002-001), and according to the institutional review board standard operating procedures on retrospective study, informed consent was not required for this study. This study also conducted in accordance with the principles of the Declaration of Helsinki.

Demographic characteristics of patients included in the study are presented in Table 1. Patients who underwent IO recession were divided into two groups for comparison studies: group 1 (10-mm IO recession, 15 patients) and group 2 (14-mm IO recession, 25 patients). One surgeon performed all surgeries. Preoperative and postoperative horizontal deviations were measured from a distance by the alternating prism cover test with correction. Postoperative horizontal deviation was measured at 6 months after surgery, and the resulting horizontal deviation from the 10- and 14-mm IO recession surgeries were compared. To analyze the effect of combined exodeviation, we conducted subgroup analysis of the patients with preoperative exodeviation greater than 8 PD. In addition, the effects of superior oblique underaction and IO overaction on postoperative horizontal deviation were investigated.

Data were analyzed using PASW Statistics ver. 18.0 (SPSS Inc., Chicago, IL, USA). Statistical analyses of demographics and horizontal deviations between the two groups were performed by the chi-square and Mann-Whitney test, respectively. Wilcoxon's signed rank test was used to evaluate the change between preoperative and postoperative deviation.

Results

Forty patients (22 men and 18 women) with a mean age of 24.0 ± 18.7 years were enrolled in the present study. Preoperative horizontal exodeviation was recorded as 6.0 ± 8.7

Table 1. Clinical characteristics of patients

	Group 1 (n = 15)	Group 2 (n = 25)	p-value
Sex (male : female)	7 : 8	15 : 10	0.206*
Nature of disorder (congenital : acquired)	6 : 9	15 : 10	0.527*
Age (yr)	24.8 \pm 18.7 (5–55)	23.9 \pm 14.2 (4–54)	0.866†

*Chi-square test; †Mann-Whitney test.

Table 2. Change in horizontal deviation after inferior oblique recession

	Group 1 (n = 15)	Group 2 (n = 25)	p-value
Preoperative horizontal deviation (PD)	6.0 \pm 8.7 (0–20)	3.0 \pm 4.5 (0–14)	0.159*
Postoperative horizontal deviation (PD)	4.1 \pm 5.8 (0–14)	0.8 \pm 2.1 (0–8)	0.012*
Change in horizontal deviation (PD)	1.9 \pm 5.4 (0–12)	2.2 \pm 3.8 (0–14)	0.820*

PD = prism diopters.

*Mann-Whitney test.

and 3.0 ± 4.5 PD in group 1 and group 2 ($p = 0.159$) patients, respectively. Postoperative horizontal exodeviation was found to be 4.1 ± 5.8 and 0.8 ± 2.1 PD in group 1 and group 2 ($p = 0.012$) patients, respectively (Table 2). The total change of horizontal exodeviation after surgery was noted as 1.9 ± 4.5 PD ($p = 0.452$) in group 1 patients and 2.2 ± 3.8 PD ($p = 0.022$) in group 2 patients (Fig. 1A). As a result, 14-mm IO recession demonstrated a significant esodrift after surgery.

Among the 40 patients that participated in the study, 10 had a preoperative exodeviation over 8 PD. The preoperative horizontal deviation in these patients was determined to be 15.0 ± 4.5 and 12.0 ± 2.3 PD in group 1 and group 2 ($p = 0.205$), respectively. The postoperative horizontal deviation in these 10 patients was calculated to be 9.0 ± 5.2 and 3.0 ± 3.8 PD for group 1 and group 2 ($p = 0.06$), respectively (Table 3). Both groups showed a significant change in horizontal deviation (group 1, $p = 0.004$; group 2, $p = 0.015$). The mean change in horizontal deviation was 6.0 ± 5.4 PD for group 1 patients and 9.0 ± 5.0 PD for group 2 patients (Fig. 1B). Although the amount of SO underaction did not affect the extent of change in horizontal

deviation, patients with severe IO overaction showed a significant change in horizontal deviation after 14-mm IO recession (Fig. 2A-2D).

Discussion

The study demonstrated that a 14-mm IO recession could initiate a significant esodrift, especially in patients with exotropia. In contrast to 10-mm IO recession, the 14-mm IO recession resulted in a statistically significant change in horizontal deviation after surgery. In addition, patients with a preoperative exodeviation greater than 8 PD showed a significant postoperative esodrift.

Esoshift resulting from IO weakening surgery can be caused by different surgical procedures. Chang and Yang [8] presented a 4.4-PD esoshift after IO myectomy or Z-myotomy. Stager and Parks [6] reported that only 16% of patients with straight eyes undergoing weakening procedures for IO overaction showed a postoperative horizontal alignment change of 4 PD or higher, and no patient reported a change greater than 8 PD. Based on the findings of

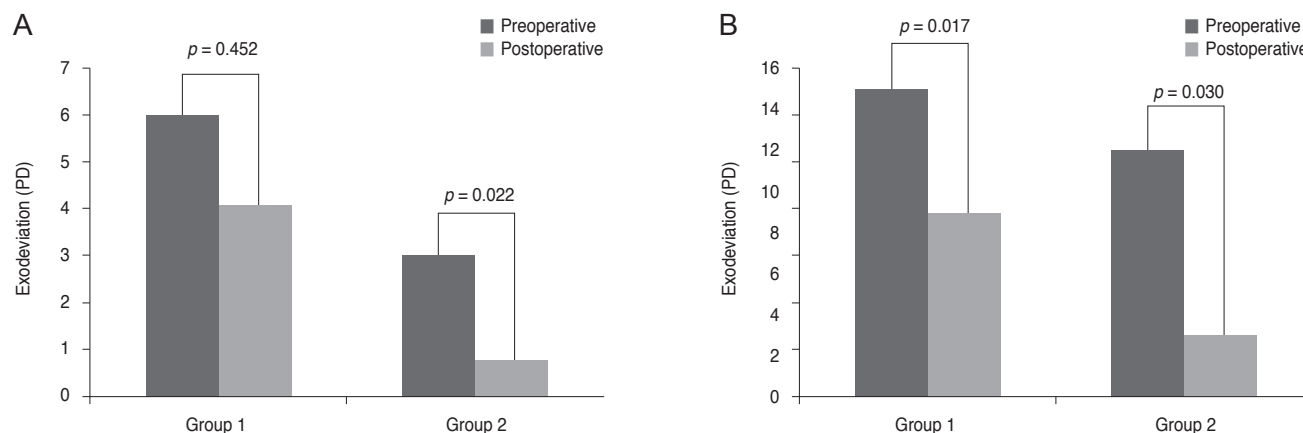


Fig. 1. (A) Change in horizontal deviation after inferior oblique recession. (B) Change in horizontal deviation after inferior oblique recession in patients with preoperative horizontal deviation greater than 8 prism diopters (PD).

Table 3. Change in horizontal deviation after inferior oblique recession in patients with preoperative horizontal deviation greater than 8 prism diopters

	Group 1 (n = 6)	Group 2 (n = 4)	p-value
Preoperative horizontal deviation	15.0 ± 4.5	12.0 ± 2.3	0.205*
Postoperative horizontal deviation	9.0 ± 5.2	3.0 ± 3.8	0.060*
Change in horizontal deviation	6.0 ± 5.4	9.0 ± 5.0	0.068*

*Mann-Whitney test.

these two reports, the mean esoshift value might be estimated to be around 4 PD, slightly lower than those recorded in the current study (i.e., 1.9 and 2.2 PD). The studies by Stager and Parks [6] and Chang and Yang [8] included IO myectomy and Z-myotomy and IO myectomy and 8-mm IO recession, respectively. However, they did not compare each effect according to surgical procedure. As a result, we could not conduct a direct comparison between the results of these studies and those obtained here.

However, a relationship could be established between the state of oblique function and surgical outcomes. SO underaction might affect the results of horizontal deviation after IO weakening surgery [6]. However, no significant difference was found based on SO action. A notable observation in the current study was that the patients with severe IO overaction demonstrated a significant esoshift after surgery. Therefore, the state of IO might affect the esoshift after IO weakening surgery.

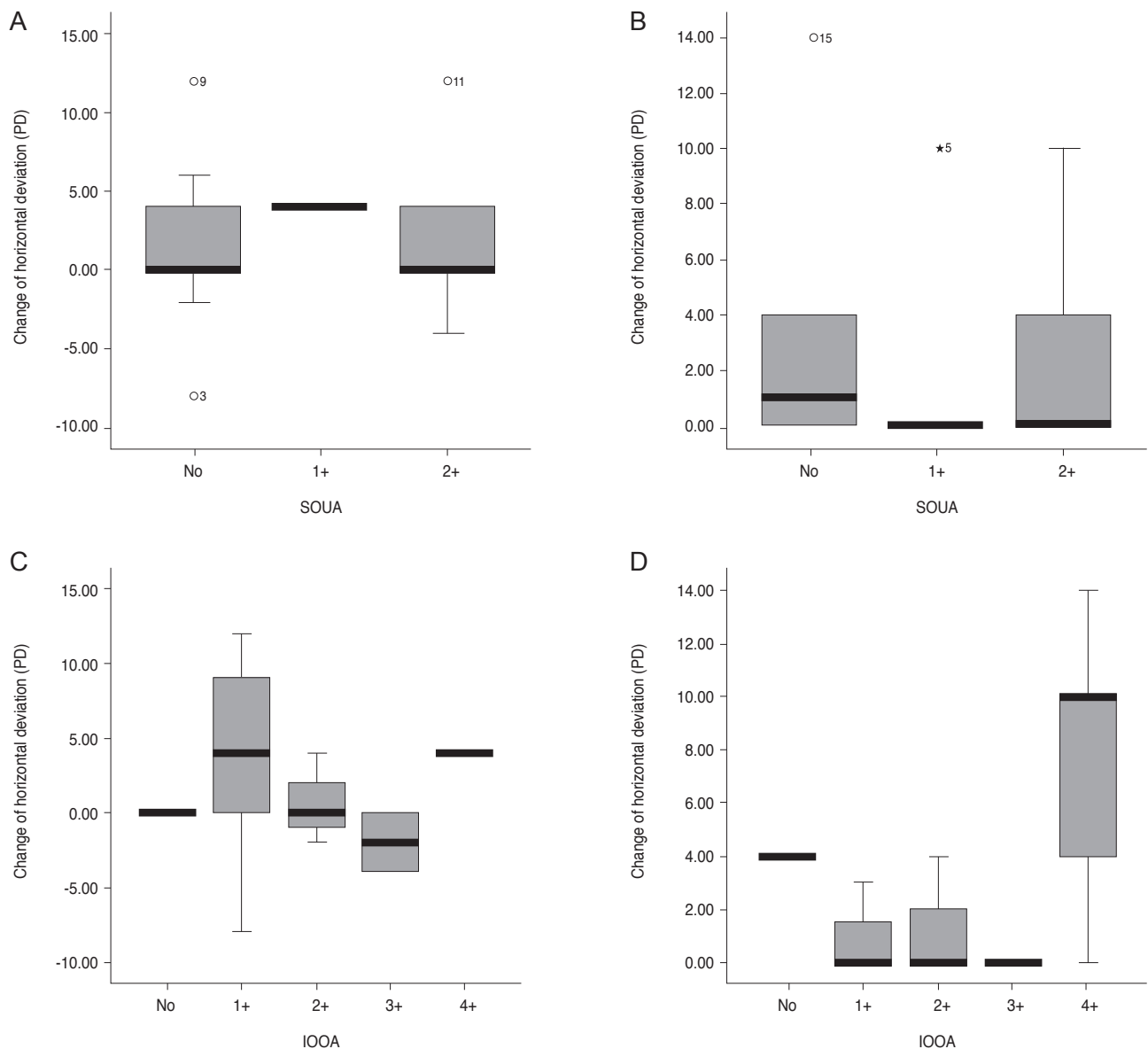


Fig. 2. Change in horizontal deviation due to superior oblique underaction (SOUA). (A) Group 1 and (B) group 2 showed no significant change in horizontal deviation after surgery (chi-square test, $p = 0.880$ and $p = 0.794$, respectively). Change in horizontal deviation due to inferior oblique overaction (IOOA). (C) Group 1 patients showed no significant change after 10-mm recession (chi-square test, $p = 0.725$). However, a significant horizontal change was noted in (D) group 2 patients with 4+ IOOA (chi-square test, $p = 0.002$). PD = prism diopters.

We showed a significant esodrift in patients with exodeviation greater than 8 PD. Tommila and Valle [9] reported a significant esodrift after IO recession in approximately 50% of patients in their study. However, several reports have suggested that horizontal deviation is not affected when IO weakening and exotropia surgeries are performed in combination [10,11]. This discrepancy might result from different inclusion criteria and surgical techniques.

We acknowledge that this study has certain limitations. First, it was a retrospective review and not a randomized controlled analysis, which could have resulted in a bias in patient selection. Congenital SO palsy and acquired SO palsy have different characteristics, and this could affect the postoperative horizontal deviation. In addition, the 10- and 14-mm recession were not randomly assigned but were applied according to the status of patients. Thus, a randomized, controlled study is needed. Second, the small number of patients enrolled in the study could impact the precision of subgroup analysis. Finally, as in Fig. 1, although the 14-mm IO recession group had significant postoperative horizontal changes, a change of 2 PD may not have much clinical impact. Thus, when preoperative exodeviation is small, the postoperative effect on horizontal deviation might be meaningless. However, the results of this study highlight a consistent decrease in exodeviation after IO weakening surgery in both study groups.

In conclusion, surgeons should consider changes in horizontal deviation when opting for 14-mm IO recession in the treatment of superior oblique palsy, especially in patients with preoperative horizontal deviation greater than 8 PD or severe IO overaction.

Conflict of Interest

No potential conflict of interest relevant to this article was reported.

References

1. Engel JM. Treatment and diagnosis of congenital fourth nerve palsies: an update. *Curr Opin Ophthalmol* 2015;26:353-6.
2. Taylan Sekeroglu H, Dikmetas O, Sanac AS, et al. Inferior oblique muscle weakening: is it possible to quantify its effects on horizontal deviations? *J Ophthalmol* 2012;2012:813085.
3. Souza-Dias C. Horizontal effect of the surgical weakening of the oblique muscles. *Arq Bras Oftalmol* 2011;74:382.
4. Diamond GR, Parks MM. The effect of superior oblique weakening procedures on primary position horizontal alignment. *J Pediatr Ophthalmol Strabismus* 1981;18:35-8.
5. Jampel RS. The fundamental principle of the action of the oblique ocular muscles. *Am J Ophthalmol* 1970;69:623-38.
6. Stager DR, Parks MM. Inferior oblique weakening procedures. Effect on primary position horizontal alignment. *Arch Ophthalmol* 1973;90:15-6.
7. Khawam E, Scott AB, Jampolsky A. Acquired superior oblique palsy. Diagnosis and management. *Arch Ophthalmol* 1967;77:761-8.
8. Chang BL, Yang SW. Inferior oblique overaction. *Korean J Ophthalmol* 1988;2:77-81.
9. Tommila V, Valle O. Effect of inferior oblique muscle recession on horizontal deviation. *Acta Ophthalmol (Copenh)* 1968;46:779-84.
10. Shin JH, Paik HJ. Effect of inferior oblique weakening procedures combined with surgery for intermittent exotropia. *J Korean Ophthalmol Soc* 2015;56:249-53.
11. Guzzinati GC. Effect of surgery of the inferior oblique muscle on horizontal heterotropia. *Ann Ottalmol Clin Ocul* 1955;81:447-54.