



# Decreased Brain Surface Complexity in Children With Attention Deficit Hyperactivity Disorder

Jin Joo Choi<sup>a</sup>  
Dong Woo Park<sup>b</sup>  
Dong Hyun Ahn<sup>c</sup>  
Woo-Suk Tae<sup>d</sup>  
Jin-Hwa Moon<sup>e</sup>

<sup>a</sup>Department of Pediatrics, Hanyang University Medical Center, Seoul, Korea  
<sup>b</sup>Departments of <sup>b</sup>Radiology and <sup>c</sup>Psychiatry, Hanyang University College of Medicine, Seoul, Korea  
<sup>d</sup>Brain Convergence Research Center, Korea University College of Medicine, Seoul, Korea  
<sup>e</sup>Department of Pediatrics, Hanyang University College of Medicine, Seoul, Korea

**Received** May 31, 2021  
**Revised** July 13, 2021  
**Accepted** July 13, 2021

## Correspondence

Jin-Hwa Moon, MD, PhD  
Division of Pediatric Neurology,  
Department of Pediatrics,  
Hanyang University Guri Hospital,  
153 Gyeongchun-ro, Guri 11923 Korea  
**Tel** +82-31-560-2258  
**Fax** +82-31-552-9493  
**E-mail** jinhwamoon@hanyang.ac.kr

Woo-Suk Tae, PhD  
Brain Convergence Research Center,  
Korea University College of Medicine,  
73 Goryeodae-ro, Seongbuk-gu,  
Seoul 02841 Korea  
**Tel** +82-2-2286-1055  
**Fax** +82-0504-202-4629  
**E-mail** wstae@korea.ac.kr

Dear Editor,

Various neuroimaging studies of attention deficit hyperactivity disorder (ADHD) have revealed abnormalities in the frontal cortex, left basal ganglia, and left inferior frontal gyrus.<sup>1</sup> However, the results of these studies have been inconsistent and usually not replicable.<sup>1,2</sup> To date, there is not a single neuroimaging marker for ADHD diagnosis.

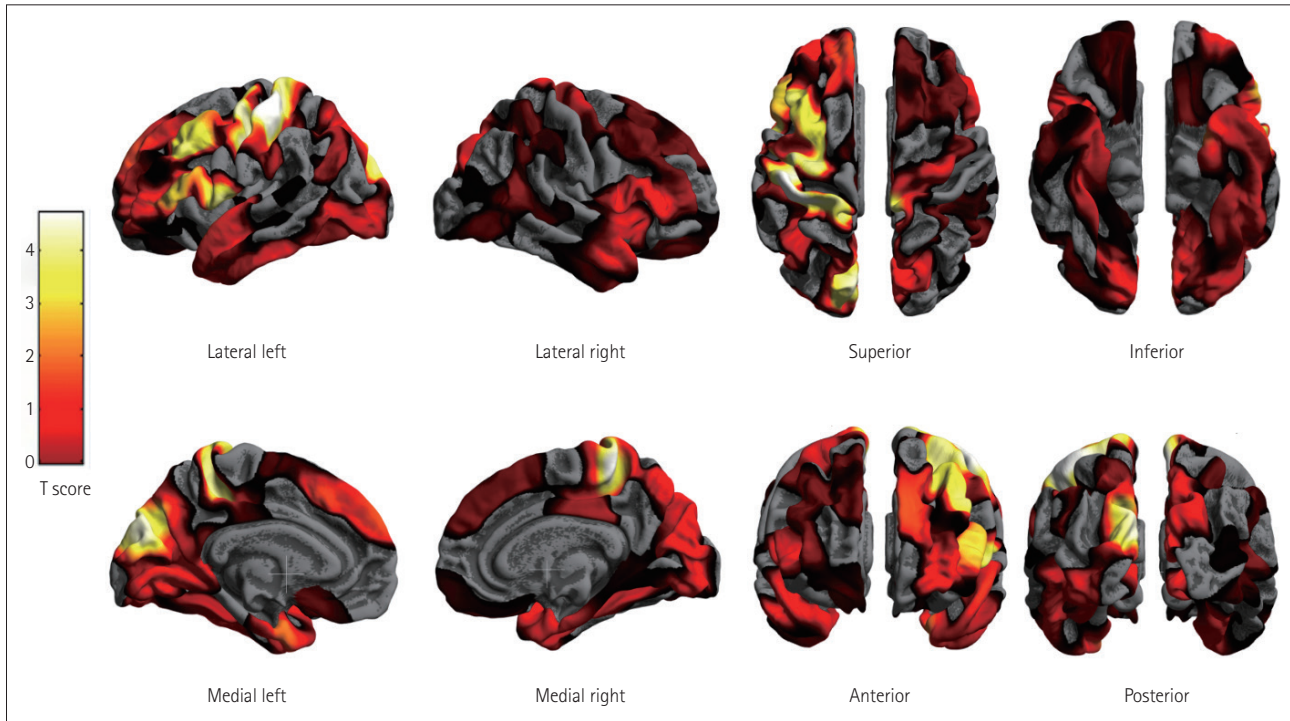
Surface-based morphometry (SBM) can be used to analyze various characteristics of the brain surface and estimate the cortical thickness (CT), local gyrification index (LGI), surface area, and fractal dimension (FD). Previous large-scale studies of CT revealed subtle differences between ADHD children and controls,<sup>1</sup> whereas the few studies of LGI have found no difference between ADHD and control groups. FD characterizes the fractal patterns of geometric objects, and is currently used to estimate the cortical complexity. However, very few studies have applied FD analysis to ADHD.<sup>3</sup> This study aimed to compare various SBM characteristics between ADHD children and controls.

Children aged 8–15 years who were diagnosed with ADHD and age-matched controls who voluntarily participated were included. Patients with structural brain lesions, severe medical problems, full-scale intelligence quotient (FSIQ) <80, or impairments in hearing, vision, or movement were excluded. Neurological and neuropsychological examinations and neurocognitive function tests (NCFTs) were performed. ADHD was diagnosed based on ADHD Rating Scale-IV. Magnetic resonance imaging (MRI) was performed using a 3-T MRI scanner. The detailed acquisition methods are presented in Supplementary Table 1 (in the online-only Data Supplement). For SBM, coronal three-dimensional T1-weighted structural images were processed using the Computational Anatomy Toolbox (version 12, <http://www.neuro.uni-jena.de/cat/>). Group differences in CT, LGI, and FD were tested separately using analysis of covariance with age and sex as with 5,000 permutations. The multiple-comparison problem was corrected at the cluster level using threshold-free cluster enhancement to a family-wise error (TFCE-FWE), with a rate of  $p < 0.05$ .

The study included 11 patients and 19 controls, whose detailed demographics and NCFT data are presented in Supplementary Table 2 (in the online-only Data Supplement). Age, right-handedness, male-to-female ratio, and FSIQ did not differ significantly between the groups. The SBM analysis did not reveal any significant differences in CT and LGI between the groups. However, FD analysis showed significant group differences in multiple regions, with FD being lower in ADHD patients than in controls. Although group differences were observed in both the right and left cortexes, FD of the ADHD group was decreased most significantly (TFCE-FWE-corrected  $p < 0.05$ ) in the left frontal, parietal, cingulate, and occipital cortexes (Fig. 1). No region in the ADHD group showed an increased FD.

This study found that the cortical FD is significantly decreased in ADHD children, especially in the left cortex. A decreased FD in ADHD indicates an altered geometric complexity of the brain surface, which implicates low efficiency of the corresponding brain regions in per-

© This is an Open Access article distributed under the terms of the Creative Commons Attribution Non-Commercial License (<https://creativecommons.org/licenses/by-nc/4.0>) which permits unrestricted non-commercial use, distribution, and reproduction in any medium, provided the original work is properly cited.



**Fig. 1.** FD was decreased in children with ADHD compared with controls. FD for the ADHD group was found to be significantly decreased (TFCE-FEW-corrected  $p < 0.05$ ) in the left frontal, parietal, cingulate, and occipital cortices. No region showing increased FD was detected in the ADHD group, unlike in the control group. ADHD, attention deficit hyperactivity disorder; FD, fractal dimension; TFCE-FEW, threshold-free cluster enhancement to a family-wise error.

forming sophisticated information processing, such as that involved in executive function.<sup>1</sup> Although we found bilateral decreases, the involvement was greater on the left side, similar to previous reports.<sup>1,3</sup> A greater decrease in complexity on the left side may be related with maturation lag or altered development of goal-directed attention in children with ADHD.<sup>1,4</sup>

The limitations of this study were the smallness of the sample and differences not being elucidated according to ADHD subtypes. Notwithstanding these limitations, a significantly decreased FD in the frontal, parietal, cingulate, and occipital cortices (primarily on the left side) might affect the development of executive function in ADHD children. Further longitudinal studies should be designed to establish whether FD is a useful neurobiological index for ADHD.

### Supplementary Materials

The online-only Data Supplement is available with this article at <https://doi.org/10.3988/jcn.2022.18.1.123>.

### Ethics Statement

All research protocols were approved by the Institutional Review Board of Hanyang University Guri Hospital (IRB File No. 2015-11-005-012). The participants underwent brain magnetic resonance imaging (MRI) and electroencephalography according to the original study protocol (NRF-2015R1D1A1A02062396), but we focused on MRI analysis in this report.

### Availability of Data and Material

The datasets generated or analyzed during the study are not publicly available due to its privacy and ethical concerns.

### ORCID iDs

Jin Joo Choi	<a href="https://orcid.org/0000-0003-2179-5802">https://orcid.org/0000-0003-2179-5802</a>
Dong Woo Park	<a href="https://orcid.org/0000-0002-7507-1175">https://orcid.org/0000-0002-7507-1175</a>
Dong Hyun Ahn	<a href="https://orcid.org/0000-0001-7024-2732">https://orcid.org/0000-0001-7024-2732</a>
Woo-Suk Tae	<a href="https://orcid.org/0000-0003-0451-0713">https://orcid.org/0000-0003-0451-0713</a>
Jin-Hwa Moon	<a href="https://orcid.org/0000-0003-0235-5318">https://orcid.org/0000-0003-0235-5318</a>

### Author Contributions

Conceptualization: Jin-Hwa Moon. Data curation: Jin-Hwa Moon, Dong Woo Park, Dong Hyun Ahn. Formal analysis: Jin-Hwa Moon, Woo-Suk Tae. Funding acquisition: Jin-Hwa Moon. Supervision: Dong Woo Park, Dong Hyun Ahn. Writing—original draft: Jin Joo Choi. Writing—review & editing: Jin-Hwa Moon, Woo-Suk Tae.

### Conflicts of Interest

The authors have no potential conflicts of interest to disclose.

### Funding Statement

This work was supported by the National Research Foundation of Korea (NRF-2015R1D1A1A02062396) and the National Research Foundation of Korea funded by the Korea government (MSIP) (NRF-No. 2017M3C7A1079696)

### REFERENCES

1. Hoogman M, Muetzel R, Guimaraes JP, Shumskaya E, Mennes M, Zwiers MP, et al. Brain imaging of the cortex in ADHD: a coordinat-

- ed analysis of large-scale clinical and population-based samples. *Am J Psychiatry* 2019;176:531-542.
2. Ghahreghazlou A, Freitas C, Ameis SH, Taylor MJ, Lerch JP, Radua J, et al. Cortical gyrification morphology in individuals with ASD and ADHD across the lifespan: a systematic review and meta-analysis. *Cereb Cortex* 2021;31:2653-2669.
  3. Li X, Jiang J, Zhu W, Yu C, Sui M, Wang Y, et al. Asymmetry of prefrontal cortical convolution complexity in males with attention-deficit/hyperactivity disorder using fractal information dimension. *Brain Dev* 2007;29:649-655.
  4. Corbetta M, Shulman GL. Control of goal-directed and stimulus-driven attention in the brain. *Nat Rev Neurosci* 2002;3:201-215.