



How to Perform Concomitant Medial Meniscus Pull-Out Repair With Medial Open-Wedge High Tibial Osteotomy Without Technical Failure

Jin Woo Jin, M.D., Ph.D., Jin Goo Kim, M.D., Ph.D., Joon Ho Wang, M.D., Ph.D.,
Jungyeun Tae, Jun Ho Kim, M.D., Ph.D., Byung Hoon Lee, M.D., Ph.D.,
Jun Yong Park, M.D., and Do Kyung Lee, M.D., Ph.D.

Abstract: Varus alignment of the knee joint (varus $>5^\circ$) is known as a poor prognostic factor for medial meniscus root repair, and alignment correction is recommended in patients with varus deformity and medial meniscus root tears. However, simultaneous medial meniscus pull-out repair and high tibial osteotomy are technically demanding procedures due to the long surgical time, poor visualization, and breaking of the pull-out sutures during high tibial osteotomy procedures. In the present Technical Note, we will introduce a surgical method to perform 2 procedures simultaneously without technical difficulty. The main surgical techniques are as follows. (1) Release the superficial medial collateral ligament before arthroscopic medial meniscus pull-out repair, which secures sufficient working space and visualization. Therefore, the operation time could also be reduced by performing the arthroscopic procedure with the anterior portal. (2) Protect the pull-out sutures with an ENDOBUTTON reamer, which prevents pull-out sutures from breaking during the high tibial osteotomy procedure.

Medial meniscus root tears (MMRTs) are commonly observed in medial compartment osteoarthritic knees.¹ A previous biomechanical study showed that the peak contact pressure after an MMRT

is similar to that after total meniscectomy,^{2,3} and it increases the medial joint contact pressure by approximately 50% to 100% due to disruption of hoop tension.^{4,5} MMRT causes meniscal extrusion, loss of articular cartilage, joint space narrowing, and eventually progresses to osteoarthritis.⁶⁻⁸ For these reasons, interest in MMRT repair has recently increased.

According to a recent study, varus alignment of the knee joint (varus $>5^\circ$) is known as a poor prognostic factor for medial meniscus root repair.^{9,10} Alignment correction is recommended in patients with varus deformity and MMRT. However, performing concomitant medial meniscus pull-out repair and high tibial osteotomy (HTO) is a technically demanding procedure for the following reasons: (1) there is a longer operation time due to performing 2 concomitant surgical procedures, which could increase the risk of postoperative complications; (2) poor visualization and insufficient working space for medial meniscus root repair due to narrow medial joint space^{11,12}; and (3) the possibility of breaking the pull-out sutures during HTO procedures. In the present Technical Note, we will introduce a surgical method to perform 2 procedures simultaneously without technical difficulty.

From the Department of Orthopedic Surgery, Samsung Changwon Hospital, Sungkyunkwan University School of Medicine, Changwon (J.W.J., J.Y.P., D.K.L.); Department of Orthopedic Surgery, Myong Ji Hospital, Hanyang University School of Medicine, Seoul (J.G.K.); Department of Orthopedic Surgery, Samsung Medical Center, Sungkyunkwan University School of Medicine, Seoul (J.H.W.); Konyang University School of Medicine, Daejeon (J.T.); Department of Orthopedic Surgery, Kyunghee University Hospital at Gangdong, Kyunghee University School of Medicine, Seoul (J.H.K.); Department of Orthopedic Surgery, Gachon University Gil Medical Center, Incheon (B.H.L.); and Konyang University Myunggok Medical Research Institute, Daejeon, (D.K.L.) Korea.

The authors report the following potential conflicts of interest or sources of funding: supported by Konyang University Myunggok Research Fund of 2019. Full ICMJE author disclosure forms are available for this article online, as [supplementary material](#).

Received November 10, 2021; accepted January 7, 2022.

Address correspondence to Do Kyung Lee, M.D., Ph.D., Department of Orthopedic Surgery, Changwon Samsung Hospital, Sungkyunkwan University School of Medicine, Changwon, Korea. E-mail: dr-lee331@hanmail.net

© 2022 THE AUTHORS. Published by Elsevier Inc. on behalf of the Arthroscopy Association of North America. This is an open access article under the CC BY-NC-ND license (<http://creativecommons.org/licenses/by-nc-nd/4.0/>).

2212-6287/211592

<https://doi.org/10.1016/j.eats.2022.01.006>

Surgical Technique (With Video 1 Illustration)

Patient Positioning and Diagnostic Arthroscopic Examination

The patient is positioned supine, and the lower extremity is prepped for routine knee arthroscopy. A routine arthroscopic portal (anteromedial [AM], anterolateral [AL], and superolateral portal) is made. The AM portal is used for the working portal, and the AL portal is used for the viewing portal. Diagnostic arthroscopic examination is performed through the AL portal. The AM portal is positioned just above the medial meniscus to facilitate the passage of the instrument during root repair.

Superficial Medial Collateral Ligament (sMCL) Release

The longitudinal incision site is determined after checking the position of the HTO plate with the C-arm. A standard longitudinal incision is performed, and the sartorial fascia is exposed. After palpating the pes anserinus, the osteotomy site is marked at the upper border of the pes anserinus. The pes anserinus is detached with one flap. Then, the sMCL can be exposed. The sMCL is completely released at the osteotomy level (Fig 1). The authors prefer to decide the osteotomy level at 3 to 5 mm below the upper margin of the pes anserinus. Because one of the proximal locking screws should be shortened due to crossing the tibial tunnel, a sufficient locking screw length of the D hole might be helpful to secure plate stability. The release of sMCL makes the medial joint space wide and secures the working space to perform arthroscopic root repair with the AM portal (Fig 2). Wet gauze is packed at the incision site to prevent contamination.

Medial Meniscus Root Repair

The margin of the root tear is refreshed with an arthroscopic shaver to induce bleeding and facilitate soft-tissue healing. The detached portion of the medial meniscus posterior horn penetrates the 45° angled suture hook at least 5 mm medial from the torn edge. A 1-0 polydioxanone suture (PDS; Ethicon, a Johnson &

Johnson Company, Somerville, NJ) is passed through the medial meniscus and it is taken out through the AM portal using a suture retriever. Two stitch sutures are performed using the same method as described previously, and the interval of each suture is approximately 10 mm (Fig 3A). Meniscus Scorpion suture passers (Arthrex, Naples, FL) might be an alternative option for those unfamiliar with using a suture hook (Fig 3B). The repair technique can be changed into a modified Mason–Allen technique depending on the surgeon's preference and arthroscopic proficiency. Four strands of PDS sutures that came out to the AM portal (Fig 3C) are tagged using mosquito forceps.

Bone Bed Preparation and Tibial Bone Tunnel Creation

Curettage of the articular cartilage and bone bed preparation for creating a tibial bone tunnel can be performed with the AM portal (Fig 4A). However, using the AL portal as a viewing portal and the AM portal as a working portal may make it difficult to create a bone tunnel in the accurate anatomical position due to poor visualization. Sometimes the position of the tibial bone tunnel might unexpectedly deviate into the anterior or medial direction from the anatomical footprint of the medial meniscus root. Therefore, the authors prefer to use the posteromedial (PM) portal as the viewing portal. The instrument passes through the AM portal and the bare space between the posterior cruciate ligament (PCL) and medial femoral condyle. The advantage of using the PM portal is that the anatomical footprint position of the medial meniscus root could be confirmed easily. Therefore, the bone tunnel can be created in a more anatomical position (Fig 4B). Soft-tissue debridement is performed just at the medial border of the PCL and lateral border of the MMPH root to secure good visualization. Bone bed preparation is performed at the MMPH root insertion site using a curved curette. The angle of the ACL guide is set to 30°, and the entry point of the guide is placed just above the osteotomy site. The ACL guide is aimed at the slightly posterior portion from the anatomical footprint of the

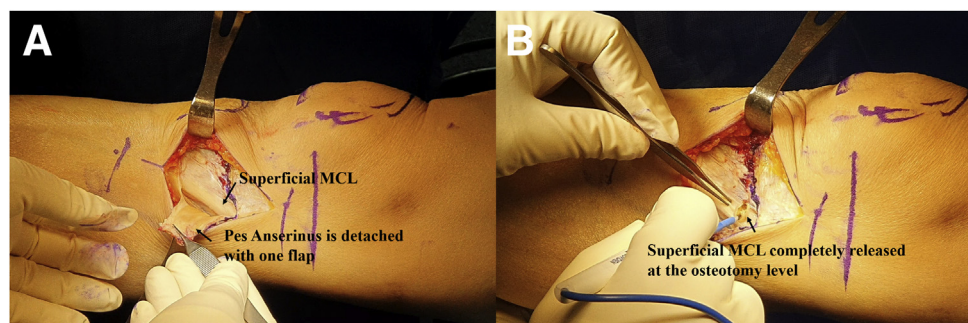
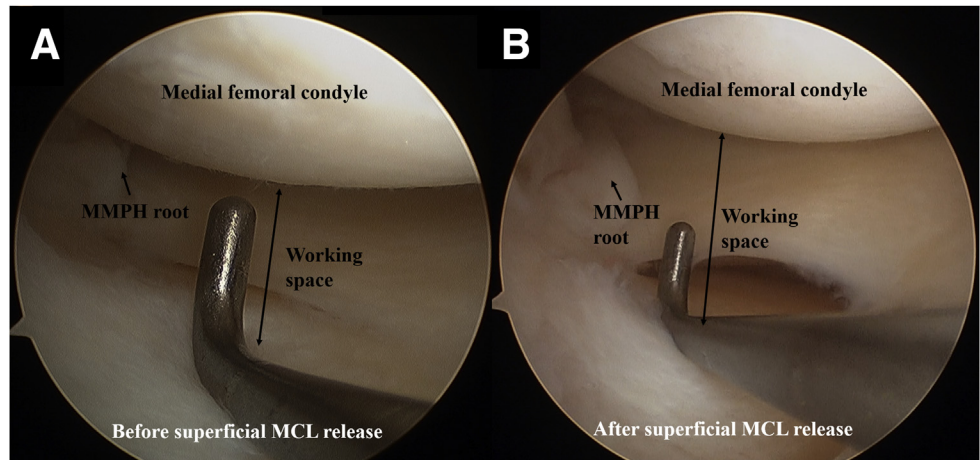


Fig 1. (A) The pes anserinus is detached with one flap. Then, the superficial medial collateral ligament (superficial MCL) can be exposed. (B) The superficial MCL release is cut at the osteotomy level before arthroscopic medial meniscus root repair.

Fig 2. The change in medial joint space (A) before sMCL release and (B) after sMCL release (arthroscopic images with 30° arthroscopy via anterolateral portal of right knee). The procedure makes the medial joint space wide and secures the working space to perform arthroscopic root repair with the anteromedial portal. (sMCL, superficial medial collateral ligament.)



MMPH root while simultaneously placing the ACL guide at the medial border of the posterior cruciate ligament.

A guide pin is inserted into the ACL guide, and a tibial bone tunnel is created using the ENDOBUTTON reamer. During ENDOBUTTON reaming, the guide pin is blocked with a curette to prevent iatrogenic neurovascular or cartilage injury (Fig 5A). After the formation of the tibial bone tunnel (Fig 5B), the ENDOBUTTON reamer is removed, and a Bis-pin tied with No. 2 ETHIBOND (Ethicon, a Johnson & Johnson Company) is inserted into the tibial bone tunnel (Fig 5C).

Passing PDS Sutures Into the Tibial Bone Tunnel With the Shuttle Relay Technique

The ETHIBOND No. 2 is pulled out into the AM portal using the suture retriever to shuttle relay the sutured 4 strands of sutured PDS. Roll-wire might be replaced with No. 2 ETHIBOND, depending on the surgeon's preference. However, the aperture of the tibial bone tunnel might be broken and deviate from the

anatomical footprint of the medial meniscus root insertion site, especially in the case of osteoporotic bone, if excessive traction force of the roll wire is applied. This is because the angle of the tibial bone tunnel becomes shallow to make the tibial bone tunnel above the osteotomy site, which weakens the aperture of the tibial bone tunnel. Therefore, the authors prefer to use No. 2 ETHIBOND. Four strands of sutured PDS and No. 2 ETHIBOND are pulled out into the AM portal using the suture retriever to prevent soft-tissue incarceration. Four strands of sutured PDS are tagging to No. 2 ETHIBOND and shuttle relay into the tibial bone tunnel (Fig 6 A and B).

High Tibial Osteotomy

After the arthroscopic procedure, the lower extremities are placed onto the Mayo stand. It easily changes positions from the arthroscopic position to supine position, and inferior bare space makes it easy to pass the C-arm. The author prefers the reverse distal biplane osteotomy to prevent changing the patellar height. Two parallel guide pins are inserted at

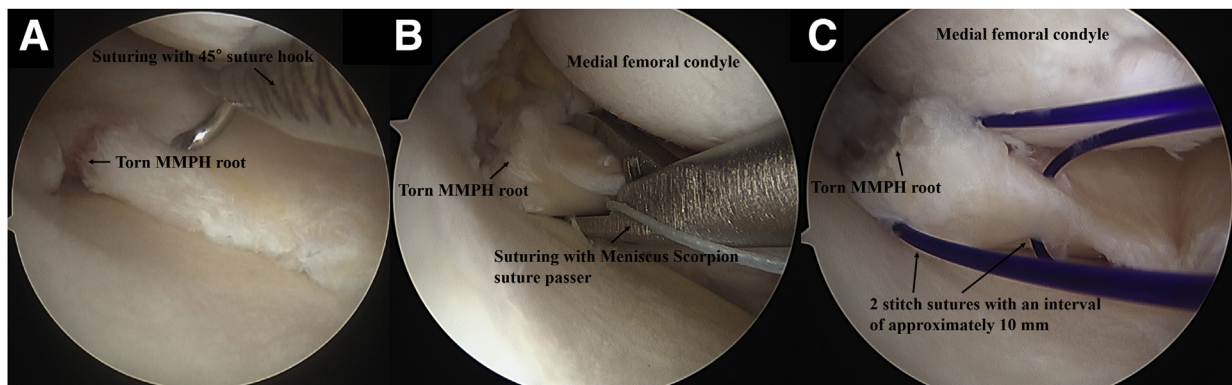


Fig 3. (A) MMPH root repair using a 45° suture hook. (B) MMPH root repair using Meniscus Scorpion suture passer. (C) Two stitch sutures with an interval of approximately 10 mm for each suture. (MMPH, medial meniscus posterior horn.)

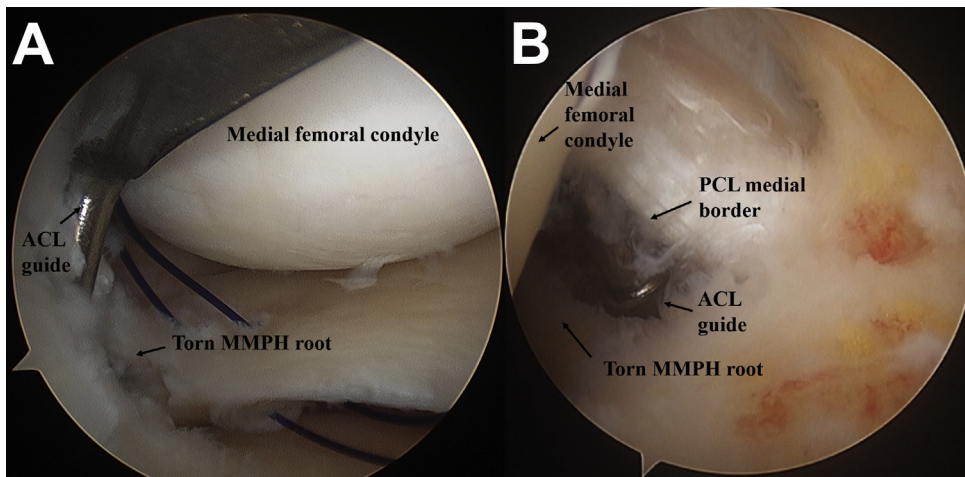


Fig 4. Bone tunnel formation viewing (A) antrolateral portal and (B) posteromedial portal with 30° arthroscopy via of right knee. Anatomical footprint of MMPH root can be easily confirmed using the PM portal as the viewing portal, this technique prevents deviating the bone tunnel into a non-anatomical position (medial or anterior direction). (ACL, anterior cruciate ligament; MMPH, medial meniscus posterior horn.)

the predetermined osteotomy level (upper margin of pes anserinus) and aim at the safety zone. One additional guide pin is also inserted along the anterior margin of the predetermined osteotomy site. Wet gauze is packed through the posterior bone margin of the tibia, and a radiolucent protector is placed along the osteotomy line to protect the neurovascular structure. Initial biplane osteotomy is performed with an oscillating saw along with the guide pins, and the coupled chisel technique is used. In our experience, there was no case in which the tibial tunnel was violated during the osteotomy procedure, and it does not need to be considered whether the pull-out sutures are damaged during the osteotomy procedure. The osteotomy site is widened with a laminar spreader as preoperative planning, and a metal block is inserted into the osteotomy site to temporarily maintain the osteotomy site. The correction angle is determined with the cable method, and the target of correction is

aimed at the weight-bearing line passing the lateral tibial spine. After achieving appropriate alignment, the ENDOBUTTON reamer is inserted reversely through the pull-out sutures and tibial tunnel, in which the sharp end is positioned distally. This technique protects pull-out sutures and prevents breaking the sutures during the drilling and insertion of the locking screws (Fig 7). If the drill bit crosses the tibial bone tunnel, it can be confirmed by contacting the ENDOBUTTON reamer. In this case, a 2-mm shorter locking screw is inserted in that hole to prevent crossing the tibial tunnel. In most cases, locking screws encounter the tibial tunnel at one of the A-D holes. After fixation procedures are performed, the ENDOBUTTON reamer and metal block are removed. Pull-out sutures are tied up to the HTO plate. Serial irrigation is performed, and a chip bone allograft is filled at the bone defect by osteotomy. Last, the detached pes anserinus is repaired.

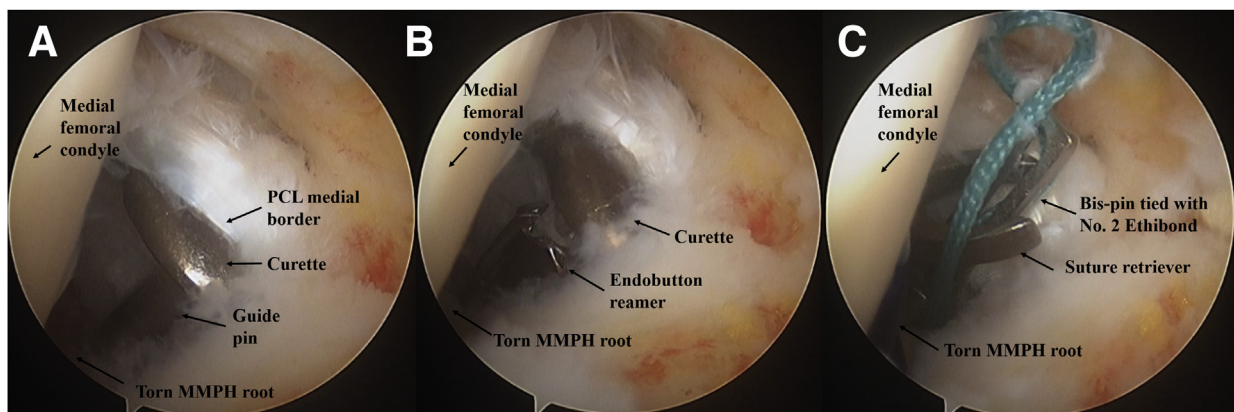


Fig 5. Arthroscopic images with 30° arthroscopy via posteromedial portal of right knee (A) The guide pin is blocked with a curette to prevent iatrogenic neurovascular or cartilage injury. (B) The tibial bone tunnel creates with an ENDOBUTTON reamer. (C) The ENDOBUTTON reamer is removed, and a Bis-pin tied with No. 2 ETHIBOND is inserted into the tibial bone tunnel. (MMPH, medial meniscus posterior horn; PCL, posterior cruciate ligament.)

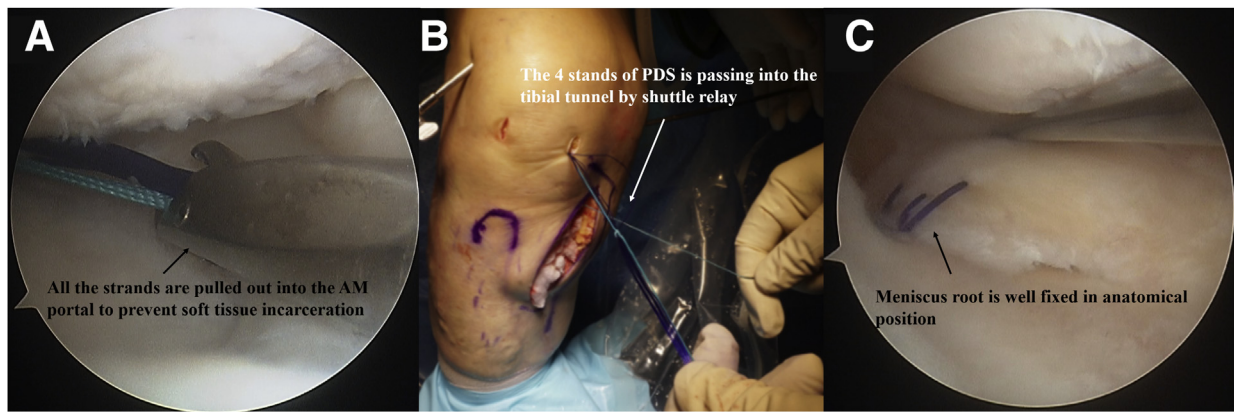


Fig 6. Arthroscopic images with 30° arthroscopy via anterolateral portal of right knee. (A) Four strands of sutured PDS and No.2 ETHIBOND is pulled out into the anteromedial portal using the suture retriever to prevent soft-tissue incarceration. (B) The 4 strands of sutured PDS are tagged to No. 2 ETHIBOND and shuttle relay into the tibial bone tunnel. (C) The sutures can be secured in the anatomical footprint of the medial meniscus root. (PDS, polydioxanone suture.)

Discussion

Historically, partial meniscectomy was the treatment of choice for MMRT. Some studies showed functional improvement with partial meniscectomy in MMRT.^{1,13} However, several authors reported that the Kellgren–Lawrence radiographic grade was aggravated after partial meniscectomy.^{1,14} Recently, there was a paradigm shift toward meniscal preservation to prevent osteoarthritic progression, and interest in MMRT repair also has increased.¹⁵ MMRT repair might be helpful on a theoretical basis by restoring hoop tension and preventing the progression of osteoarthritis.^{6,16,17} In biomechanical studies, there have been reports that meniscal root repair restores normal joint kinematics and contact pressures.^{3,5,18-20} In addition, meniscus root repairs demonstrated superior clinical outcomes and slowed the radiographic progression of knee osteoarthritis compared with patients treated with meniscectomy.^{21,22} Chung et al.^{22,23} also showed that patients who underwent root repair had a very low clinical failure rate and subsequently reduced the

conversion to total knee replacement. The presented studies show a recent trend of adopting meniscal repair as the preferred surgical option for MMRT. However, recent evidence has shown that varus alignment of the knee joint (varus $>5^\circ$) is a poor prognostic factor for medial meniscus root repair.^{9,10} Alignment correction with HTO is recommended in patients with varus deformity and MMPH root tears. Therefore, interest in concomitant medial meniscus root repair and HTO has recently increased.

Performing 2 procedures simultaneously might be technically demanding, and the present study showed how to perform both techniques simultaneously without technical failure (Table 1). In particular, the current surgical technique has 2 major advantages (Table 2). First, medial meniscus root repair could be easily performed with the anterior portal. Conventional medial meniscus pull-out repair approached the anterior or posterior portal. The reason for posterior access is the difficulty of securing surgical visualization caused by medial joint space narrowing and contracture. There is a

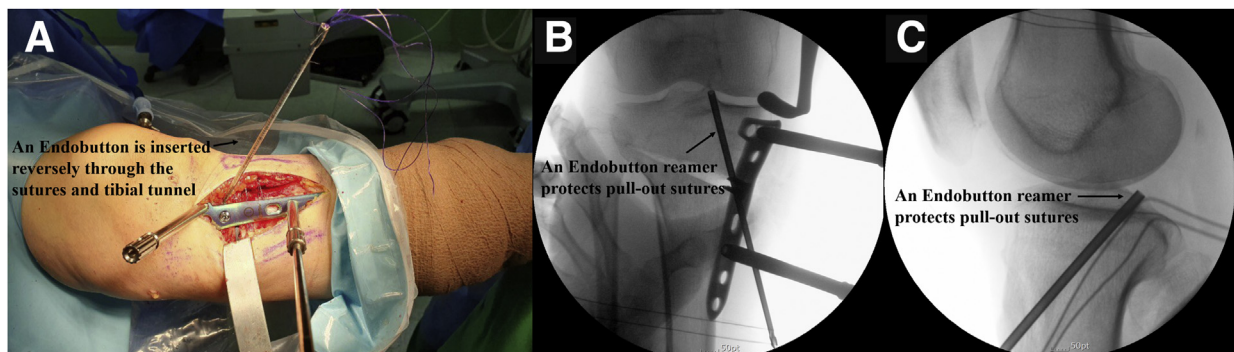


Fig 7. (A) An ENDOBUTTON reamer is inserted reversely through the pull-out sutures and tibial tunnel, in which the sharp end is positioned distally. This technique protects pull-out sutures and prevents breaking the sutures during the drilling and insertion of the locking screws. (B and C) Whether the pull-out sutures are well protected was confirmed by checking the C-arm.

Table 1. Pitfalls and Pearls

Pitfalls

The angle of the tibial tunnel is shallow and the tunnel aperture could be weak; therefore, the position of the tibial bone tunnel might unexpectedly deviate into the anterior or medial direction from the anatomical footprint of the medial meniscus root.
If the entrance of the tibial tunnel is located posteriorly, it may overlap with the HTO position, making it difficult to position the plate in the appropriate location.

Pearls

The ACL guide should be aimed at the slightly posterior portion from the anatomical footprint of the MMPH root while simultaneously placing the ACL guide at the medial border of the posterior cruciate ligament.
Using the PM portal as a viewing portal could be a useful method to prevent cartilage and neurovascular injury and to position the tibial tunnel into the anatomical footprint of the medial meniscus.
Using the ETHIBOND No. 2 is recommended for the shuttle relay into the tibial bone tunnel.
The entrance of the tibial tunnel should be positioned as anterior as possible to secure sufficient length of the locking screws and to properly position the HTO plate.

ACL, anterior cruciate ligament; HTO, high tibial osteotomy; MMPH, medial meniscus root repair; PM, posteromedial.

Table 2. Advantages, Risks, and Limitations

Advantages

Medial meniscus root repair could be easily performed with the anterior portal
Secure sufficient working space and prevent unexpected iatrogenic complications (chondral damage, MCL injury, or avulsion fracture due to excessive varus force)
Time-saving compared with the posterior portal approach
Pull-out sutures could be protected safely during the HTO procedure
The change of patella height is minimal

Risks and limitations

Longer operation time compared with the single procedure (root repair and HTO)
Further studies are needed whether concomitant medial meniscus root repair an HTO could be superior surgical outcomes compared with the single procedure

HTO, high tibial osteotomy; MCL, medial collateral ligament.

risk of iatrogenic chondral damage with the anterior portal approach in the case of narrow medial compartment joint space.²⁴ In addition, an unexpected complication, such as MCL injury or fracture of the femur, might occur in cases in which excessive varus force is applied with the anterior portal approach.²⁵ However, the posterior approach requires additional posterior side portal (PM, posterolateral, transseptal) formation, which is technically demanding and time-consuming.²⁶ To solve these problems, the authors prefer to proceed to release sMCL first before the arthroscopic procedure. In proceeding with HTO, the procedure of superficial MCL release is a necessary procedure before osteotomy. By shifting the order of surgical procedures, sufficient working space of the medial compartment can be achieved, as shown in the present study. Therefore, the anterior approach could be possible, as it could reduce operation time and prevent unexpected complications with the anterior portal approach. Furthermore, an additional decompression effect of the medial compartment might be achieved. A recent biomechanical study also showed that the release of the distal fiber of the MCL has a decompression effect on medial compartment pressure after HTO.²⁷ Other studies^{11,24} also adopted the method of releasing sMCL and approaching anteriorly when repairing MMRTs. Chung et al.²⁴ reported that the

release of the distal attachment of the sMCL showed similar clinical outcomes compared with the nonrelease group. The procedure did not show residual instability, and the operation time was also reduced by securing the operation fields. In our case, we also adopted their idea, and the average root repair procedure time was 30~40 minutes. Second, pull-out sutures could be protected safely during the HTO procedure. Pull-out sutures could be cut out in the process of drilling or inserting the locking screw. As suggested in the present study, pull-out sutures could be protected by the ENDOBUTTON reamer, and 2 procedures can be carried out without breaking pull-out sutures.

It remains controversial²⁸⁻³³ whether concomitant medial meniscus root repair and HTO could be superior surgical outcomes compared with the single procedure (root repair or HTO). Further research is needed to determine whether concomitant MMRT repair and HTO could lead to superior surgical outcomes.

Acknowledgments

Do Kyung Lee really appreciate my coauthors for the effort to proceed this study. Special thanks to Jin Goo Kim and Joon Ho Wang, who provided creative ideas for the study.

References

- Ozkoc G, Circi E, Gonc U, Irgit K, Pourbagher A, Tandogan RN. Radial tears in the root of the posterior horn of the medial meniscus. *Knee Surg Sports Traumatol Arthrosc* 2008;16:849-854.
- Allaire R, Muriuki M, Gilbertson L, Harner CD. Biomechanical consequences of a tear of the posterior root of the medial meniscus. Similar to total meniscectomy. *J Bone Joint Surg Am* 2008;90:1922-1931.
- Saltzman BM, Habet NA, Rao AJ, et al. Biomechanical evaluation of an all-inside posterior medial meniscal root repair technique via suture fixation to the posterior cruciate ligament. *Arthroscopy* 2020;36:2488-2497 e2486.
- Lee SJ, Aadalen KJ, Malaviya P, et al. Tibiofemoral contact mechanics after serial medial meniscectomies in the human cadaveric knee. *Am J Sports Med* 2006;34:1334-1344.
- Muriuki MG, Tuason DA, Tucker BG, Harner CD. Changes in tibiofemoral contact mechanics following radial split and vertical tears of the medial meniscus an in vitro investigation of the efficacy of arthroscopic repair. *J Bone Joint Surg Am* 2011;93:1089-1095.
- Lerer DB, Umans HR, Hu MX, Jones MH. The role of meniscal root pathology and radial meniscal tear in medial meniscal extrusion. *Skeletal Radiol* 2004;33:569-574.
- Lee YG, Shim JC, Choi YS, Kim JG, Lee GJ, Kim HK. Magnetic resonance imaging findings of surgically proven medial meniscus root tear: Tear configuration and associated knee abnormalities. *J Comput Assist Tomogr* 2008;32:452-457.
- Guermazi A, Hayashi D, Jarraya M, et al. Medial posterior meniscal root tears are associated with development or worsening of medial tibiofemoral cartilage damage: The multicenter osteoarthritis study. *Radiology* 2013;268:814-821.
- Moon HK, Koh YG, Kim YC, Park YS, Jo SB, Kwon SK. Prognostic factors of arthroscopic pull-out repair for a posterior root tear of the medial meniscus. *Am J Sports Med* 2012;40:1138-1143.
- Ahn JH, Jeong HJ, Lee YS, et al. Comparison between conservative treatment and arthroscopic pull-out repair of the medial meniscus root tear and analysis of prognostic factors for the determination of repair indication. *Arch Orthop Trauma Surg* 2015;135:1265-1276.
- Park YS, Moon HK, Koh YG, et al. Arthroscopic pullout repair of posterior root tear of the medial meniscus: The anterior approach using medial collateral ligament piecrusting release. *Knee Surg Sports Traumatol Arthrosc* 2011;19:1334-1336.
- Fakioglu O, Ozsoy MH, Ozdemir HM, Yigit H, Cavusoglu AT, Lobenhoffer P. Percutaneous medial collateral ligament release in arthroscopic medial meniscectomy in tight knees. *Knee Surg Sports Traumatol Arthrosc* 2013;21:1540-1545.
- Bin SI, Kim JM, Shin SJ. Radial tears of the posterior horn of the medial meniscus. *Arthroscopy* 2004;20:373-378.
- Kwon OJ, Bin SI, Kim JM, et al. There is no difference in radiographic outcomes after average 9 years after arthroscopic partial medial meniscectomy for both posterior horn tears and posterior horn root tears. *Arthroscopy* 2020;36:524-532.
- Bhatia S, LaPrade CM, Ellman MB, LaPrade RF. Meniscal root tears: Significance, diagnosis, and treatment. *Am J Sports Med* 2014;42:3016-3030.
- Chung KS, Ha JK, Ra HJ, Kim JG. A meta-analysis of clinical and radiographic outcomes of posterior horn medial meniscus root repairs. *Knee Surg Sports Traumatol Arthrosc* 2016;24:1455-1468.
- Feucht MJ, Kuhle J, Bode G, et al. Arthroscopic transtibial pullout repair for posterior medial meniscus root tears: A systematic review of clinical, radiographic, and second-look arthroscopic results. *Arthroscopy* 2015;31:1808-1816.
- Marzo JM, Gurske-DePerio J. Effects of medial meniscus posterior horn avulsion and repair on tibiofemoral contact area and peak contact pressure with clinical implications. *Am J Sports Med* 2009;37:124-129.
- Padalecki JR, Jansson KS, Smith SD, et al. Biomechanical consequences of a complete radial tear adjacent to the medial meniscus posterior root attachment site: In situ pull-out repair restores derangement of joint mechanics. *Am J Sports Med* 2014;42:699-707.
- Okazaki Y, Furumatsu T, Yamauchi T, et al. Medial meniscus posterior root repair restores the intra-articular volume of the medial meniscus by decreasing posteromedial extrusion at knee flexion. *Knee Surg Sports Traumatol Arthrosc* 2020;28:3435-3442.
- Lee JK, Jung M, Yang JH, et al. Repair versus nonrepair of medial meniscus posterior root tear: A systematic review of patients' selection criteria, including clinical and radiographic outcomes. *Medicine (Baltimore)* 2020;99, e19499.
- Chung KS, Ha JK, Yeom CH, et al. Comparison of clinical and radiologic results between partial meniscectomy and re-fixation of medial meniscus posterior root tears: A minimum 5-year follow-up. *Arthroscopy* 2015;31:1941-1950.
- Chung KS, Ha JK, Ra HJ, Yu WJ, Kim JG. Root repair versus partial meniscectomy for medial meniscus posterior root tears: Comparison of long-term survivorship and clinical outcomes at minimum 10-year follow-up. *Am J Sports Med* 2020;48:1937-1944.
- Chung KS, Ha JK, Ra HJ, Kim JG. Does release of the superficial medial collateral ligament result in clinically harmful effects after the fixation of medial meniscus posterior root tears? *Arthroscopy* 2017;33:199-208.
- Allum R. Complications of arthroscopy of the knee. *J Bone Joint Surg Br* 2002;84:937-945.
- Ahn JH, Wang JH, Yoo JC, Noh HK, Park JH. A pull out suture for transection of the posterior horn of the medial meniscus: Using a posterior trans-septal portal. *Knee Surg Sports Traumatol Arthrosc* 2007;15:1510-1513.
- Agneskirchner JD, Hurschler C, Wrann CD, Lobenhoffer P. The effects of valgus medial opening wedge high tibial osteotomy on articular cartilage pressure of the knee: A biomechanical study. *Arthroscopy* 2007;23:852-861.
- Ke X, Qiu J, Chen S, et al. Concurrent arthroscopic meniscal repair during open-wedge high tibial osteotomy is not clinically beneficial for medial meniscus posterior root tears. *Knee Surg Sports Traumatol Arthrosc* 2021;29:955-965.

29. Lee HI, Park D, Cho J. Clinical and radiological results with second-look arthroscopic findings after open wedge high tibial osteotomy without arthroscopic procedures for medial meniscal root tears. *Knee Surg Relat Res* 2018;30:34-41.
30. Jing L, Liu K, Wang X, et al. Second-look arthroscopic findings after medial open-wedge high tibial osteotomy combined with all-inside repair of medial meniscus posterior root tears. *J Orthop Surg (Hong Kong)* 2020;28:2309499019888836.
31. Kim YM, Joo YB, Lee WY, Kim YK. Remodified Mason-Allen suture technique concomitant with high tibial osteotomy for medial meniscus posterior root tears improved the healing of the repaired root and suppressed osteoarthritis progression. *Knee Surg Sports Traumatol Arthrosc* 2021;29:1258-1268.
32. Hohmann E. Editorial Commentary: Medial meniscal root repair may not be required during knee medial-compartment unloading high tibial osteotomy. *Arthroscopy* 2020;36:2476-2477.
33. Lee DW, Lee SH, Kim JG. Outcomes of medial meniscal posterior root repair during proximal tibial osteotomy: Is root repair beneficial? *Arthroscopy* 2020;36:2466-2475.