



Serial brain magnetic resonance imaging in a patient with invasive streptococcal infection with ventriculitis and choroid plexitis

Jaewoon Chung, MD¹; Ji Young Lee, MD, PhD²; Young Seo Kim, MD, PhD¹

¹Department of Neurology, Hanyang University College of Medicine, Seoul, Korea

²Department of Radiology, Hanyang University College of Medicine, Seoul, Korea

IMAGES IN NEUROCRITICAL CARE

Received: October 11, 2021

Revised: November 26, 2021

Accepted: November 26, 2021

Corresponding Author:

Young Seo Kim, MD, PhD

Department of Neurology, Hanyang University College of Medicine, 222-1 Wangsimni-ro, Seongdong-gu, Seoul 04763, Korea

Tel: +82-2-2290-8375

Fax: +82-2-2299-2391

E-mail: aescula@hanmail.net

A 39-year-old previously healthy man visited the hospital with fever, myalgia, and vomiting. His systolic blood pressure was below 60 mmHg, and he was admitted to the intensive care unit with the suspicion of septic shock. After admission, *Streptococcus pneumoniae* was found in his blood, and treatment with vancomycin 2 g/day and ceftriaxone 4 g/day was initiated. Following antibiotic treatment for 4 days, his mentation deteriorated to a stupor. Brain magnetic resonance imaging (MRI) indicated hydrocephalus, ventriculitis, and choroid plexitis (Fig. 1). Cerebrospinal fluid (CSF) examination showed normal opening pressure (180 mmHg), pleocytosis (white blood cell count, 280; neutrophils, 55%), high protein level (1,448 mg/dL), and low glucose levels (CSF, 54 mg/dL; serum, 135 mg/dL). Consequently, a high dose of steroids (dexamethasone, 40 mg/day) was prescribed together with antibiotics. After 14 days of antibiotic treatment, his general condition improved.

Brain MRI findings depicting pyogenic ventriculitis typically include ependymal thickening and enhancement with T2 prolongation surrounding the ventricle, hydrocephalus, and debris within the dependent aspect of the ventricles [1,2]. In addition, diffusion restriction and swelling of the choroid plexus are suggestive

of choroid plexitis [2,3]. Although the MRI findings of our patient seemed more critical than previous reports, the patient experienced a good outcome with antibiotics [4].

ARTICLE INFORMATION

Ethics statement

This case was approved by the Institutional Review Board of the Hanyang University Hospital (IRB No. HYUH 2021-10-010). Informed consent from a patient was waived by the IRB.

Conflict of interest

No potential conflict of interest relevant to this article.

ORCID

Jaewoon Chung <https://orcid.org/0000-0001-6936-9023>

Ji Young Lee <https://orcid.org/0000-0003-1181-8070>

Young Seo Kim <https://orcid.org/0000-0002-7050-3426>

Author contributions

Conceptualization: YSK. Data curation: JC, JYL. Formal analysis:

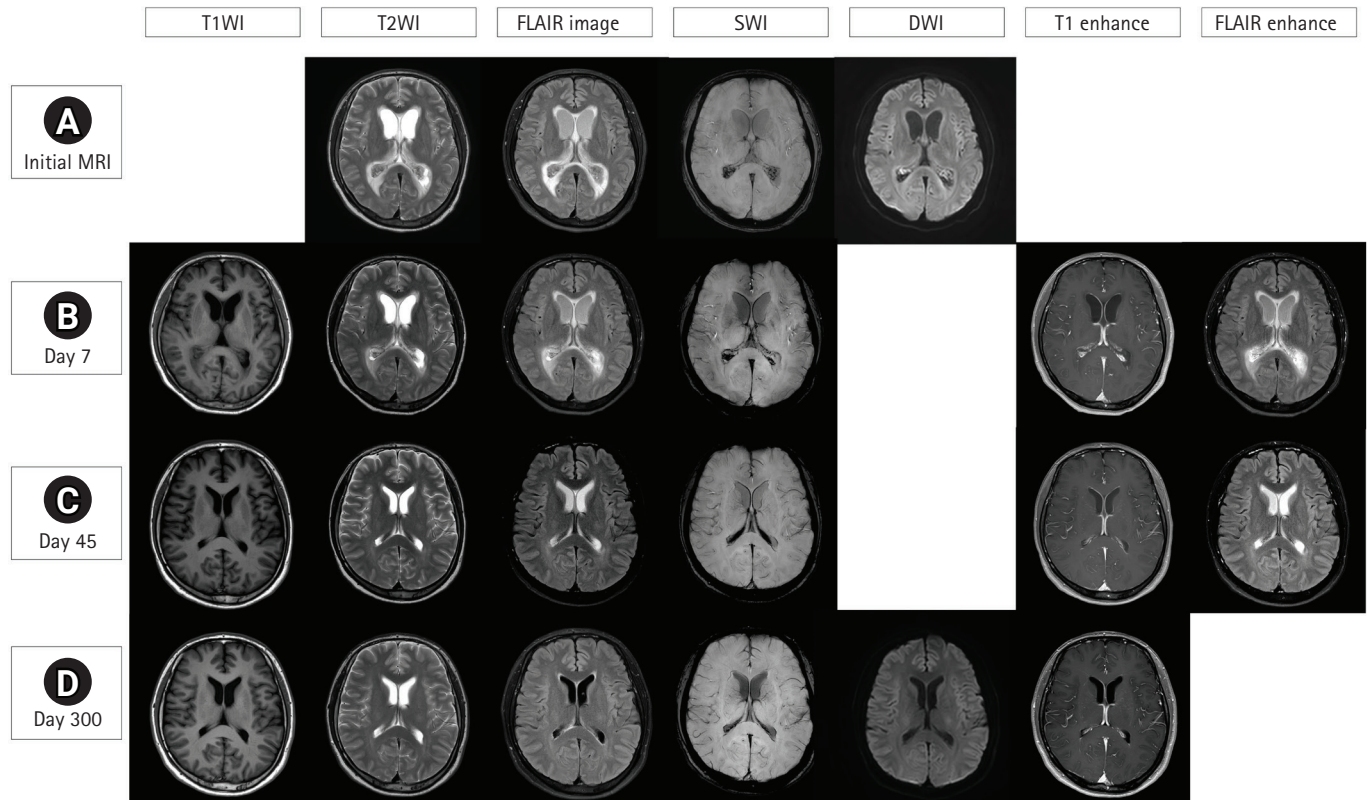


Fig. 1. Serial brain magnetic resonance imaging (MRI) findings of invasive streptococcal sepsis with ventriculitis and choroid plexitis. Initial brain images reveal hydrocephalus with severe interstitial edema and non-suppressed high-signal fluid in the lateral ventricle on fluid-attenuated inversion recovery (FLAIR) imaging, suggesting pyogenic ventriculitis. In addition, restricted diffusion on diffusion-weighted imaging (DWI) and low signal intensity on susceptibility-weighted imaging (SWI) in both choroid plexuses indicate choroid plexitis with hemorrhaging (A). Although the patient's mental status improved after administration of intravenous vancomycin and ceftriaxone, no significant change is observed in the brain MRI on day 7 after admission (B). The brain MRI of day 45 shows improved hydrocephalus, interstitial edema, ventriculitis, and choroid plexitis; however, a high signal of cerebrospinal fluid on FLAIR imaging is noted (C). Finally, on day 300, a normal brain MRI is observed (D).

YSK. Methodology: YSK. Project administration: YSK, JYL. Visualization: JYL. Writing—original draft: JC. Writing—review & editing: YSK.

REFERENCES

1. Mohan S, Jain KK, Arabi M, Shah GV. Imaging of meningitis and ventriculitis. *Neuroimaging Clin N Am* 2012;22:557-83.
2. Hazany S, Go JL, Law M. Magnetic resonance imaging of infectious meningitis and ventriculitis in adults. *Top Magn Reson Imaging* 2014;23:315-25.
3. Pezzullo JA, Tung GA, Mudigonda S, Rogg JM. Diffusion-weighted MR imaging of pyogenic ventriculitis. *AJR Am J Roentgenol* 2003;180:71-5.
4. Woehrl B, Linn J, Lummel N, Pfefferkorn T, Koedel U, Pfister HW, et al. Pneumococcal meningitis-associated pyogenic ventriculitis. *J Infect* 2015;70:311-4.