



Spectrum of nitrous oxide intoxication related neurological disorders in Korea: a case series and literature review

Jungsoo Lee^{1*}, Yangmi Park^{2*}, Hyunkee Kim¹, Nakhoon Kim¹, Wonjae Sung¹, Sanggon Lee¹, Jinseok Park¹

¹Department of Neurology, Hanyang University College of Medicine, Seoul, Korea

²Department of Neurology, Seoul Metropolitan Government Boramae Medical Center, Seoul National University College of Medicine, Seoul, Korea

Received: June 14, 2021

Revised: July 9, 2021

Accepted: July 29, 2021

Correspondence to

Jinseok Park

Department of Neurology, Hanyang University Hospital, 222-1 Wangsimni-ro, Seongdong-gu, Seoul 04763, Korea
Tel: +82-2-2290-8367
Fax: +82-2-2296-8370

E-mail: jinspark@hanyang.ac.kr

*These authors contributed equally.

ORCID

Jungsoo Lee

<https://orcid.org/0000-0001-8390-6059>

Yangmi Park

<https://orcid.org/0000-0002-8765-9988>

Hyunkee Kim

<https://orcid.org/0000-0003-3824-6930>

Nakhoon Kim

<https://orcid.org/0000-0001-9002-9904>

Wonjae Sung

<https://orcid.org/0000-0002-4637-5890>

Sanggon Lee

<https://orcid.org/0000-0003-0622-1210>

Jinseok Park

<https://orcid.org/0000-0001-6581-5831>

<http://www.e-acn.org>

pISSN 2508-691X

eISSN 2508-6960

Background: Nitrous oxide (N₂O) is used in surgery and dentistry for its anesthetic and analgesic effects. However, neurological and psychiatric manifestations of N₂O abuse have been increasingly reported among Korean adults. The aim of this study was to demonstrate laboratory findings of N₂O abuse in Korean patients.

Methods: Patients diagnosed with N₂O-induced neuropathy or myelopathy from August 2018 to December 2019 were enrolled. Their clinical presentations and laboratory and imaging findings were analyzed.

Results: Sensory changes and limb weakness were present in nine of the enrolled patients. The laboratory findings revealed that seven patients had high homocysteine levels and five had high methylmalonic acid levels in their blood. Nerve conduction studies indicated that axonal neuropathy was present in four cases and longer F-wave and Hoffman's-reflex latencies were present in two cases. Signal changes in cervical spine imaging occurred in five patients, while two had normal results.

Conclusions: Chronic N₂O abuse can cause neurological damage or psychiatric problems. Because N₂O is illegal for recreational use in Korea, patients tend to hide their history of use. Even though the spinal imaging results were normal, clinicians should consider the possibility of N₂O use, and further electrophysiological tests should be applied for precise evaluations.

Key words: Nitrous oxide; Neuropathy; Spinal cord; Subacute combined degeneration; Homocysteine

Copyright © 2021 The Korean Society of Clinical Neurophysiology

This is an Open Access article distributed under the terms of the Creative Commons Attribution Non-Commercial License (<http://creativecommons.org/licenses/by-nc/4.0>) which permits unrestricted non-commercial use, distribution, and reproduction in any medium, provided the original work is properly cited.

INTRODUCTION

Nitrous oxide (N₂O) is a colorless and nonflammable gas that is used in surgery and dentistry due to its anesthetic effects. N₂O has recently been misused for recreational purposes due to its euphoric effects when inhaled. The recreational use of N₂O is currently prohibited in Korea due to its negative clinical effects, such as inducing vitamin B₁₂ deficiency¹ or mechanisms that lead to thrombosis.² However, N₂O is still available in whipped-cream canisters or small bulbs that are predominantly used for recreation by young people.³ Reported cases of neurological and psychiatric manifestations of N₂O abuse have recently increased among adults in Korea.⁴

The neurological complications associated with N₂O abuse usually manifest as subacute combined degeneration (SCD) of the spinal cord. N₂O deactivates the enzyme methionine synthase by inactivating methylcobalamin and impairing the methylation of myelin sheath proteins, leading to spinal cord degeneration and myelopathy.⁴ These processes can also cause peripheral nervous polyneuropathies. Several clinicians in Korea have reported various clinical symptoms and abnormal findings in tests after N₂O inhalation, such as in electrophysiological examinations and magnetic resonance imaging (MRI).⁵ Additionally, vitamin B₁₂ deficiency tends to the induction of hyperhomocysteinemia, which in turn induces thrombosis.² There are numerous previously reported cases of hyperhomocysteinemia inducing deep vein thrombosis or pulmonary thromboembolism (PTE).^{2,6}

The use of illegal drugs such as cocaine, heroin, methamphetamine, and cannabis is reportedly lower in Korean than in other countries.⁷ Illegal drug usage is therefore considered by Korean clinicians less when they are determining symptom etiology. Since it is rare for patients to report their N₂O use, diagnosing patients with atypical clinical manifestations is also difficult. A good understanding of the clinical manifestations of N₂O usage is therefore important. Here we report nine patients with neurological manifestations and abnormal laboratory findings following N₂O abuse.

MATERIALS AND METHODS

Patient sample and clinical measurements

We retrospectively analyzed clinical data from nine patients

diagnosed with N₂O-induced neuropathy or myelopathy. This hospital-based case-series study investigated patients who presented at the Hanyang University Hospital (a tertiary referral medical center) in Seoul, Korea from August 2018 to December 2019. All patients underwent routine laboratory tests including a complete blood count, coagulation test, electrolyte test, and routine urine analysis. Considering the effects of N₂O on vitamin B₁₂ metabolism, serum methylmalonic acid (MMA), homocysteine, and vitamin B₁₂ levels were also examined. Electrophysiological tests such as a nerve conduction study (NCS) or electromyography were applied to eight patients. Spinal cord MRI, computed tomography (CT) scan with contrast enhancement, and chest CT angiography had been performed on seven, one, and one patient, respectively. Neurological examinations were performed, with the motor power of all four limbs measured according to the Medical Research Council grading system. Ethical approval was obtained for this study from the Institutional Review Board of the Hanyang University Hospital (IRB No. 2020-03-008).

Electrophysiological examinations

Standard motor and antidromic sensory NCSs were performed bilaterally on four motor nerves (median, ulnar, posterior tibial, and fibular) and three sensory nerves (median, ulnar, and sural) of eight patients. This analysis evaluated the terminal latency, compound muscle action potential amplitude (CMAP), and conduction velocity of each nerve. We defined abnormal results as changes of at least 20% from the lower conduction velocity and CMAP limits, and from the upper terminal latency limit. Demyelinating NCS patterns were defined according to the guidelines from the American Association of Neuromuscular and Electrodiagnostic Medicine.⁸ F-wave latency was measured after supramaximal motor nerve stimulation, which identified ten F-waves. Hoffmann's reflex (H-reflex) was recorded from the soleus when stimulating the tibial nerve.

Literature review

Literature searches were performed of the MEDLINE and PubMed databases using the search terms "neuropathy N₂O" and/or "myelopathy N₂O" and including case reports published between 2006 and 2019 in South Korea. The reference lists of these reports were considered secondary

Table 1. Clinical features and laboratory findings of nine patients with neurological effects from (N₂O) intoxication

Pt no.	Age (years)	Sex	Duration ^a	Initial symptoms	Neurological examination	Laboratory data		Spinal cord MRI	Other findings
1	28	M	3 weeks	Weakness in both limbs Paresthesia in both legs (proximal→distal)	Quadriparesis (grade IV) Hypesthesia below C5 Tandem gait (-), Romberg's sign (+)	Hb 12.2 ^b , MCV 100.3 ^b D-dimer 1.83 ^b aPTT 31	Vit B ₁₂ 382.2 HCY 56.7 ^b MMA 12.27 ^b	T2-weighted hyperintensity at the posterior column (C2-C5)	Pulmonary artery thromboembolism on chest CT
2	27	F	3 weeks	Gait disturbance Acroparesthesia Dyspepsia	Decreased dorsiflexion (grade IV) Stocking-glove hypesthesia Tandem gait (-), Romberg's sign (+) Dysmetria	Hb 13.2, MCV 103.2 ^b D-dimer 0.09 aPTT 38	Vit B ₁₂ 267.7 HCY 45.4 ^b MMA 9.44 ^b	T2-weighted hyperintensity at the posterior column (upper cervical cord)	
3	24	M	16 weeks	Weakness in both leg Numbness in both legs	Decreased dorsiflexion (grade IV) Hypesthesia in both legs Tandem gait (-), Romberg's sign (+)	Hb 14.7 MCV 97.5 D-dimer 0.20 aPTT 33	Vit B ₁₂ > 2,000 HCY 10.7 ^b MMA 1.00	Not checked	
4	23	F	4 weeks	Weakness in both limbs (distal→proximal) Acroparesthesia	Decreased dorsiflexion (grade III) Quadriparesis (grade IV) Stocking-glove hypesthesia Hypoactive DTR Decreased anal tone Tandem gait (-), Romberg's sign (+)	Hb 11.5 ^b , MCV 106.1 ^b D-dimer 0.52 ^b aPTT 27	Vit B ₁₂ > 2,000 HCY 25.0 MMA 2.63	T2-weighted hyperintensity at the posterior column (C2-C6)	
5	28	M	2 weeks	Weakness in both ankles Acroparesthesia	Decreased dorsiflexion (grade IV) Stocking-glove hypesthesia Hypoactive DTR Tandem gait (-)	Hb 16.9, MCV 100.6 ^b D-dimer not checked aPTT 36	Vit B ₁₂ 201.6 HCY 45.6 ^b MMA not checked	No signal change	
6	24	M	Unknown	Weakness in both legs (distal→proximal) Paresthesia in in both legs	Quadriparesis (proximal, grade IV; distal, grade II) Stocking-glove hypesthesia Areflexia Tandem gait (-), Romberg's sign (+)	Hb 16.9, MCV 100.6 ^b D-dimer not checked aPTT 37	Vit B ₁₂ 414.5 HCY 45.5 ^b MMA 5.86 ^b	Not checked	
7	26	F	2 weeks	Numbness in both legs (distal→proximal)	Vibration loss in both legs Hypoactive DTR Tandem gait (-), Romberg's sign (+)	Hb 11.3 ^b , MCV 102.5 ^b aPTT 27 D-dimer 0.14	Vit B ₁₂ 162.1 ^b HCY 49.1 ^b MMA 4.87 ^b	No signal change	

Table 1. Continued

Pt no.	Age (years)	Sex	Duration ^a	Initial symptoms	Neurological examination	Laboratory data		Spinal cord MRI	Other findings
8	22	F	12 weeks	Acroparesthesia	Stocking-glove hypesthesia Tandem gait (-), Romberg's sign (+)	Hb 13.5 MCV 101.6 ^b	Vit B ₁₂ 1,456 HCY 11.2 MMA 3.32	T2-weighted hyperintensity at the posterior column (C2 and C3)	
9	35	F	12 weeks	Weakness in both legs Paresthesia in both legs	Paraparesis Vibration loss in both legs Hyperactive DTR, Babinski sign (+)	Hb 11 MCV 107.1 D-dimer 1.1 aPTT 31	Vit B ₁₂ 222.1 HCY 76.4 MMA not checked	T2-weighted hyperintensity at posterior, anterior, and lateral column (C7 to conus medullaris)	Chest CT angiography showed no specific lesions

Pt, patient; MRI, magnetic resonance imaging; M, male; Hb, hemoglobin (normal range = 12-18 g/dL); MCV, mean corpuscular volume (normal range = 80-99 fL); D-dimer (normal range = 0-0.24 mg/L); aPTT, activated partial thromboplastin time (normal range = 25-39 seconds); Vit B₁₂, vitamin B₁₂ (normal range = 197-771 pg/mL); HCY, homocysteine (normal range = 0-15 μmol/L); MMA, methylmalonic acid (normal range = 0.01-3.76 mg/g); CT, computed tomography; F, female; DTR, deep tendon reflex.

^aInterval between time of last N₂O inhalation and symptom onset as reported by the patient; ^bAbnormal laboratory findings.

sources. Cases without postmortem analyses or NCS results were excluded.

RESULTS

Nine patients aged between 23 and 35 years visited our hospital from August 2017 to December 2019 (Table 1). All patients had a history of N₂O inhalation during the 6 months prior to admission. The interval between the last N₂O inhalation and symptom onset varied from 2 weeks to 4 months, while the interval between symptom onset and hospital visit varied from 3 days to 1 month, with the majority of patients visiting 1 week after symptom onset. Five patients were female. Sensory change was the initial symptom of all patients. These sensory symptoms varied between patients and included an ascending tingling sensation in both legs (patient no. 1), numbness in both legs (patient no. 3 and 7), and acroparesthesia (patient no. 2, 4, 5, 8, and 9). Five patients experienced muscle weakness, three of which only had lower limb weakness (patient no. 3, 6, and 9), and two had both upper and lower limb weakness (patient no. 1 and 4). Muscle weakness only in the ankles was found in patient no. 5. One patient had dyspepsia. None of the patients were vegetarians or had previously received gastrointestinal surgery.

Neurological examinations indicated that seven of the nine patients had limb paresis. Three had mild weakness in ankle dorsiflexion and the other four had quadriparesis. Sensory changes were detected in patient no. 1, while patient no. 7 and 9 had a loss of vibration sensation in both legs. Among the other patients, six had stocking-glove hypesthesia (patient no. 2, 4, 5, 6, 8, and 9). Hypoactivity of the deep tendon reflex (DTR) occurred in four cases (patient no. 4, 5, 6, and 7), four had normoactive DTR, and one had hyperactive DTR (patient no. 9). Patient no. 2 had dysmetria of the upper limbs and all patients except no. 5 showed abnormal results in the Romberg test. All patients had an impaired tandem gait. Digital rectal examinations indicated that patient no. 4 had decreased anal tone.

Laboratory findings revealed low hemoglobin levels and large mean corpuscular volumes in four and six patients, respectively. Only one patient had a low serum vitamin B₁₂ level (patient no. 7). Elevated serum homocysteine levels were indicated in seven cases (patient no. 1, 2, 3, 5, 6, 7, and 9), and five patients had high blood MMA levels.

NCSs were performed on eight patients (Table 2). Among them, four had axonal neuropathies (patient nos. 3, 4, 5, and 6) and one had longer F-wave and H-reflex latencies in both lower limbs (patient no. 7). Seven patients had a decreased sural nerve conduction velocity or longer H-reflex latency.

Most patients had more abnormalities in the lower limbs than in the upper limbs, distal limb regions were affected more than were proximal regions, and sensory nerves were involved more frequently than were motor nerves. Demyelination was not observed in any patient. The reference values and raw data of patients' nerve conduction study are shown respectively on Supplementary Table 1, 2.

Seven patients received spinal MRI, five of whom had signal changes in the dorsal column of the cervical spine, as indicated in T2-weighted images (Fig. 1). Patient no. 9 had concurrent hyperintensity lesions in the anterior, lateral, and

posterior spinal column (Fig. 2). Two patients (patient no. 5 and 7) showed normal results in spinal MRI.

All patients received hydroxocobalamin as a vitamin B₁₂ supplement. Three patients received additional steroid therapy. Intravenous immunoglobulin G was administered to one patient (patient no. 5) due to their observed clinical features being similar to those associated with early Guillain-Barré syndrome. Patient no.1 suffered from N₂O addiction and depression, so they received psychiatric consulting.

A literature search identified five articles describing SCD attributed to recreational N₂O abuse, including three male

Table 2. Abnormal findings in NCSs of nine patients

Pt no.	Median nerve (motor)	Median nerve (sensory)	Ulnar nerve (motor)	Ulnar nerve (sensory)	Posterior tibial nerve (motor)	Fibular nerve (motor)	Sural nerve (sensory)	H-reflex latency	Conclusion
1			F-wave latency ↑ (Rt)			CMAP ↓ (both)	CV ↓ (both)		Sensorimotor polyneuropathy in leg
2					F-wave latency ↑ (both)	F-wave latency ↑ (both)	CV ↓ (both)	H-reflex latency ↑ (both)	Sensorimotor polyneuropathy
3		CV ↓ (both)		CV ↓ (Lt)	F-wave latency ↑ (Lt)	CMAP ↓ (both) CV ↓ (Lt) F-wave latency ↑ (Rt)	CV ↓ (both)	H-reflex latency ↑ (both)	AMSAN
4		CV ↓ (Lt)		CV ↓ (both)	CV ↓ (Rt) F-wave latency ↑ (both)	CMAP ↓ (both) CV ↓ (both) F-wave latency ↑ (both)	CV ↓ (both)	H-reflex latency ↑ (both)	AMSAN
5		CV ↓ (both)	CV ↓ (Lt) TL ↑ (Rt)	CV ↓ (both)	CMAP ↓ (both) TL ↑ (both) CV ↓ (Rt)	No CMAP (both)	CV ↓ (Rt)	H-reflex latency ↑ (both)	AMSAN
6	CMAP ↓ (Lt) CV ↓ (both)	CV ↓ (both)	TL ↑ (Rt)	CV ↓ (both)	No CMAP (both)	No CMAP (both)	CV ↓ (Lt)	No H-reflex (both)	AMSAN
7					F-wave latency ↑ (both)	F-wave latency ↑ (both)		H-reflex latency ↑ (both)	Normal
8		CV ↓ (Rt)		CV ↓ (both)		CMAP ↓ (Lt) F-wave latency ↑ (both)	CV ↓ (both)	H-reflex latency ↑ (both)	Sensory dominant polyneuropathy
9	Not checked								

Undocumented findings were normal.

NCSs, nerve conduction studies; H-reflex, Hoffman's reflex; Rt, right; CMAP, compound motor action potential amplitude; CV, conduction velocity; Lt, left; AMSAN, acute motor-sensory axonal neuropathy; TL, terminal latency.

and seven female cases. All of these cases had gait disturbances or sensory changes as initial symptoms accompanied by signal changes in cervical MRI. NCSs indicated neuropathic patterns or early-stage polyneuropathy. One patient presented with incidental PTE and lung infarction. Table 3 summarizes the details of the published cases.^{5,9,10}

DISCUSSION

N₂O is known to selectively oxidize folate and vitamin B₁₂, rendering them inactive and unable to degrade homocysteine into methionine, which is required for normal myelin production.¹¹ Active vitamin B₁₂ is also required to convert MMA into succinyl-CoA. Serum levels of both homocysteine

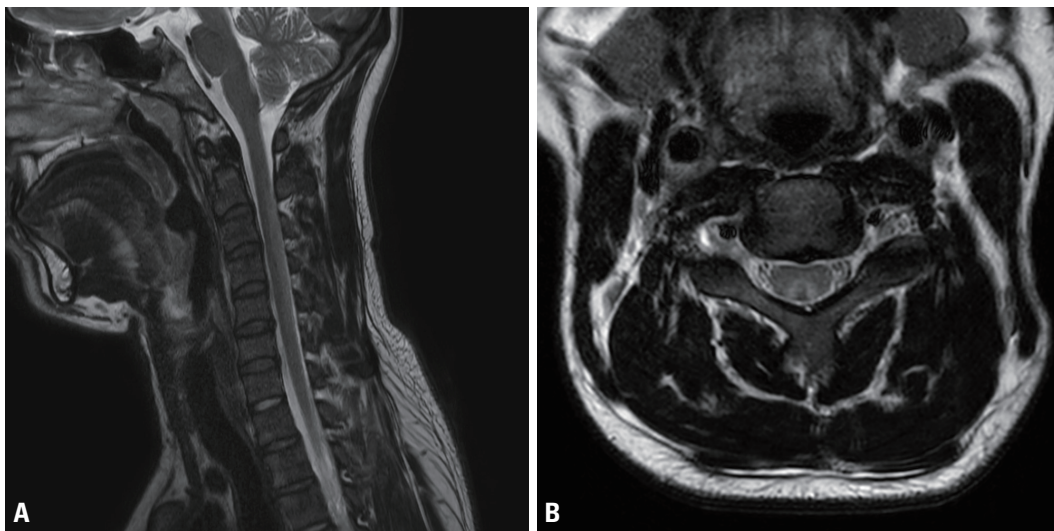


Fig. 1. T2-weighted cervical spinal magnetic resonance imaging (patient no. 1). (A) In the sagittal series, abnormal hyperintensities were observed in the dorsal cervical spinal cord (C2-C5) without enhancement. (B) In the axial series, high signal intensity (inverted-V sign) and cord swelling were observed.

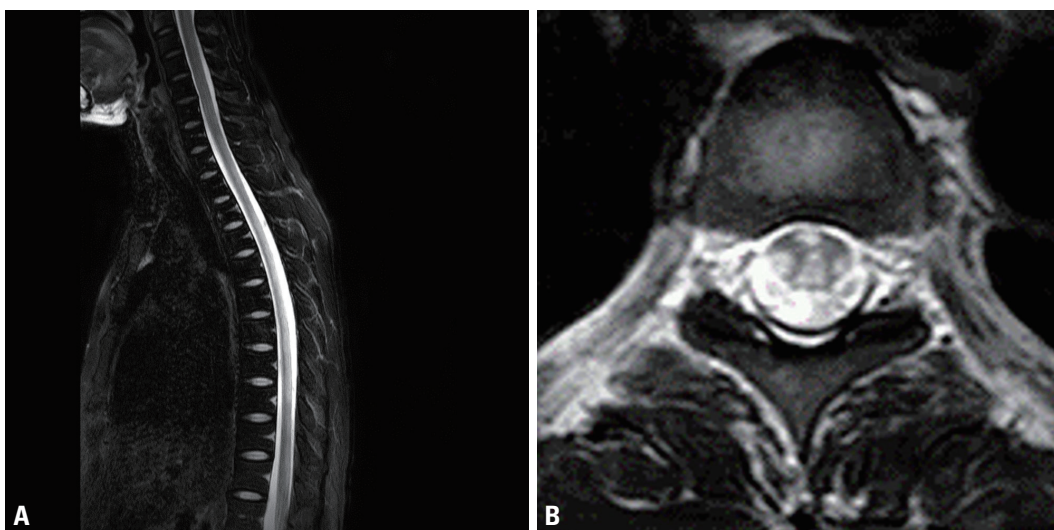


Fig. 2. T2-weighted spinal magnetic resonance imaging (patient no. 9). (A) T2-weighted sagittal image, indicating high signal intensities within the posterior spinal cord from C7 to the conus medullaris. (B) T2-weighted axial image indicating high signal intensities in the anterior, lateral, and posterior spinal column.

Table 3. Published cases of nitrous oxide intoxication with neurological manifestations

Year	Ref.	Age ^a / sex	Symptoms	Neurological examination	Laboratory findings	MRI changes	NCS	Others
2019	Lee et al. ¹⁰	32/F	Gait disturbance	Romberg's sign (+), sensory ataxia	Low Vit B ₁₂ High homocysteine	Posterior column of C1 and C2	Not mentioned	
2018	Kang et al. ¹⁹	?/F	Progressive limb paralysis	Motor weakness in lower extremities	Increased MCV Low Vit B ₁₂ High homocysteine	Posterior column of cervical cord	Demyelinating polyneuropathy	
		?/F	Progressive limb paralysis, paresthesia	Romberg's sign (+), motor weakness in lower extremities, hypesthesia to vibration, position	Increased MCV Low Vit B ₁₂ High homocysteine	Posterior column of cervical cord	Demyelinating polyneuropathy	
		?/F	Progressive limb paralysis, paresthesia	Romberg's sign (+), motor weakness in lower extremities, hypesthesia to vibration, position	Increased MCV Low Vit B ₁₂ High homocysteine	Posterior column of cervical cord	Normal	
		?/F	Progressive limb paralysis, paresthesia	Motor weakness in lower extremities, paresthesia	Macrocytic anemia Low Vit B ₁₂ High homocysteine	Posterior column of cervical cord	Axonal polyneuropathy	Incidental PTE with lung infarction
2018	Kwon et al. ¹⁸	22/F	Gait disturbance, progressive paresthesia in legs and hands	Paraparesis (MRC grade III) ^b Romberg's sign (+), decomposition, hypesthesia to vibration, tactile	Increased MCV Low Vit B ₁₂	Posterior column of cervical cord	Axonal motor neuropathy	
		33/M	Gait disturbance, progressive numbness in legs	Romberg's sign (+), sensory ataxia, hypesthesia to vibration, position, hyporeflexia	Increased MCV Low Vit B ₁₂	Posterior column of cervical cord	Axonal motor neuropathy	
2018	Choi et al. ⁹	24/M	Gait disturbance, paresthesia in all limbs, voiding difficulty	Romberg's sign (+), gait ataxia, hypesthesia, paresthesia to tactile, hyperreflexia	Increased MCV High homocysteine	Posterior column of cervical cord	Sensorimotor polyneuropathy in lower limbs	
		22/F	Progressive leg paralysis, voiding difficulty, paresthesia in legs	Paraparesis (MRC grade II), hypesthesia to tactile, areflexia	Low Vit B ₁₂ High homocysteine	C2-C5	Sensorimotor polyneuropathy in lower limbs	
2006	Kwoun et al. ⁵	40/M	Gait disturbance, numbness in hands and feet	Hypesthesia to pain, vibration, position, Romberg's sign (+), gait ataxia, hyperreflexia	Microcytic hypochromic anemia Low Vit B ₁₂ High homocysteine	Posterior column and lateral column of cervical cord	Demyelinating polyneuropathy	

Ref., reference number; MRI, magnetic resonance imaging; NCS, nerve conduction study; F, female; Vit B₁₂, vitamin B₁₂; MCV, mean corpuscular volume; PTE, pulmonary thromboembolism; MRC, Medical Research Council; M, male.

^aAll patients were aged 21-36 years; ^bActive movement against gravity.

and MMA are elevated during vitamin B₁₂ deficiency. Previous *in vitro* studies have demonstrated the cytotoxic effect of homocysteine on cortical astrocytes and that of MMA on primary neuronal cultures.^{12,13} This interference with vitamin B₁₂ metabolism could lead to demyelination in the central or peripheral nervous system and also to megaloblastic anemia. These pathophysiological mechanisms result in N₂O intoxication being associated with clinical features such as numbness in the extremities, ataxia, and psychomotor symptoms (including impaired memory function and depression).¹⁴

There were marked variations in clinical symptoms, laboratory findings, electrophysiological findings, and MRI results associated with N₂O usage among the cases examined in this study. Sensory nerve fibers are generally affected more frequently by toxins.¹⁵ Similar to other toxic neuropathies, we found that all of our patients experienced sensory changes in their distal limbs, and that these changes were correlated with NCS abnormalities. Motor weakness was observed in 50% of cases, but motor NCS abnormalities were not found to be correlated with these symptoms. In two cases (patient no. 1 and 7), only F-wave and H-reflex latency changes were identified. These findings resembled the early clinical features of Guillain-Barré syndrome, but our results indicated no demyelinating patterns. Considering the relationships between N₂O, vitamin B₁₂ deficiency, and hypomyelination, these axonal patterns detected through NCSs suggest that an alternative mechanism of N₂O directly contributes to axonal damage.¹⁶

Most of the patients had high serum homocysteine or MMA levels despite normal vitamin B₁₂ levels. Due to the illegality of recreational N₂O use in Korea, most patients with neurological symptoms were assumed to have ingested vitamin B₁₂ prior to visiting our hospital. A previous case report indicated that homocysteine and MMA levels could be normalized by vitamin B₁₂ treatment.¹⁷

MRI findings in previously reported cases of N₂O intoxication related to SCD have frequently identified symmetric bilateral T2-weighted hyperintensity lesions at the posterior spinal cord. This specific finding is known as the “inverted-V sign.” In the present case series, the MRI findings of about half of the patients were compatible with SCD. However, two patients who had no detected MRI signal changes had abnormal NCS results, which represents the first report of

this phenomenon in Korea. One patient also had concurrent involvement in the anterior, lateral, and posterior spinal column.

There have been several reports of the deleterious effects of N₂O abuse in Korea. Kwoun et al.⁵ reported the first case of myeloneuropathy following chronic N₂O abuse in 2003. In that report, the patient had paresthesia in both distal limbs and ataxia. Spinal MRI indicated high signal intensities from segments C2 to C5 on a T2-weighted image. Furthermore, NCSs indicated a demyelinating neuropathic pattern. Serum vitamin B₁₂ levels were low and those of homocysteine were high. Two other cases of SCD caused by N₂O gas were reported by Kwon et al.¹⁸ in 2019. Both patients had sensory changes in their limbs and the inverted-V sign was visible in T2-weighted spinal MRI. NCSs indicated axonal motor polyneuropathy in that case. In all previous cases of N₂O intoxication in Korea, spinal cord MRI indicated signal changes similar to those observed in SCD. Unlike previously reported cases, we found two patients who had abnormal NCS results despite having normal spinal MRI results. We therefore suggest that clinicians need to consider the possibility of N₂O inhalation in patients whose NCSs produce axonal degeneration findings, even if signal changes are not observed in spinal cord MRI.

The present study has revealed that N₂O abuse may be associated with a wide range of clinical features, including psychiatric problems such as addiction and depression, especially among adolescents and young adults. Due to the illegality of recreational N₂O use in Korea, patients tend to hide their history of N₂O use or inaccurately report symptom onset. Addressing this issue requires treatments for neurological deficits, the careful recording of the medical histories, and psychiatric support for patients.

Our study had several limitations. First, its retrospective design made it difficult to precisely evaluate and quantify the data analyzed for each patient. Second, this study included only nine cases from a single center, so it might not be representative of all patients experiencing N₂O intoxication in Korea. Third, all patients had supplemented their vitamin B₁₂ intake before the clinical evaluations, which makes it difficult to accurately interpret the results. Fourth, the patients tended to not reveal their history of N₂O inhalation because it is currently illegal to use N₂O gas for recreational purposes in Korea. It was therefore difficult to evaluate the correlations

between clinical features and the exact amount and duration of N₂O inhalation.

The clinical manifestations of N₂O intoxication related to neurological disorders varied between the included patients, but had a general commonality. Several clinical indicators may include young adults with progressive subacute weakness and lower-extremity-dominant sensory changes. Increased serum MMA, homocysteine, axonal-type sensorimotor polyneuropathy patterns in electrophysiological tests, and predominant posterior column involvement observed in MRI may indicate the presence of N₂O intoxication related to neurological disorders. Careful evaluations of the clinical history of N₂O abuse are therefore warranted when these clinical findings are observed.

Conflicts of Interest

The authors have no conflicts to disclose.

Acknowledgements

This work was supported by the research fund of Hanyang University(HY-202100000001136).

Supplementary Material

Supplementary Materials can be found with this article online <https://doi.org/10.14253/acn.2021.23.2.108>.

REFERENCES

- Sethi NK, Mullin P, Torgovnick J, Capasso G. Nitrous oxide "whippit" abuse presenting with cobalamin responsive psychosis. *J Med Toxicol* 2006;2:71-74.
- Eldibany MM, Caprini JA. Hyperhomocysteinemia and thrombosis: an overview. *Arch Pathol Lab Med* 2007;131:872-884.
- Dong X, Ba F, Wang R, Zheng D. Imaging appearance of myelopathy secondary to nitrous oxide abuse: a case report and review of the literature. *Int J Neurosci* 2019;129:225-229.
- Lan SY, Kuo CY, Chou CC, Kong SS, Hung PC, Tsai HY, et al. Recreational nitrous oxide abuse related subacute combined degeneration of the spinal cord in adolescents-a case series and literature review. *Brain Dev* 2019;41:428-435.
- Kwoun YJ, Choi YJ, Oh JY, Park KD, Choi KG. Myeloneuropathy following chronic abuse of nitrous oxide. *J Korean Neurol Assoc* 2003;21:432-435.
- Sun W, Liao JP, Hu Y, Zhang W, Ma J, Wang GF. Pulmonary embolism and deep vein thrombosis caused by nitrous oxide abuse: a case report. *World J Clin Cases* 2019;7:4057-4062.
- Feng LY, Yu WJ, Chang WT, Han E, Chung H, Li JH. Comparison of illegal drug use pattern in Taiwan and Korea from 2006 to 2014. *Subst Abuse Treat Prev Policy* 2016;11:34.
- American Association of Electrodiagnostic Medicine, Olney RK. Guidelines in electrodiagnostic medicine. Consensus criteria for the diagnosis of partial conduction block. *Muscle Nerve Suppl* 1999;8:S225-S229.
- Choi C, Kim T, Park KD, Lim OK, Lee JK. Subacute combined degeneration caused by nitrous oxide intoxication: a report of two cases. *Ann Rehabil Med* 2019;43:530-534.
- Lee HL, Lee SJ, Nam TS, Min SH, Kim JM, Kang KW. Acute cervical myelopathy following laughing gas abuse. *Chonnam Med J* 2019;55:118-119.
- Richardson PG. Peripheral neuropathy following nitrous oxide abuse. *Emerg Med Australas* 2010;22:88-90.
- Maler JM, Seifert W, Hüther G, Wiltfang J, Rütther E, Kornhuber J, et al. Homocysteine induces cell death of rat astrocytes in vitro. *Neurosci Lett* 2003;347:85-88.
- Kölker S, Ahlemeyer B, Kriegelstein J, Hoffmann GF. Methylmalonic acid induces excitotoxic neuronal damage in vitro. *J Inher Metab Dis* 2000;23:355-358.
- Weimann J. Toxicity of nitrous oxide. *Best Pract Res Clin Anaesthesiol* 2003;17:47-61.
- Pleasure D. Toxic neuropathies. In: Darras BT, Jones HR, Ryan MM, De Vivo DC, eds. *Neuromuscular disorders of infancy, childhood, adolescence: a clin approach*. 2nd ed. Oxford: Elsevier, 2015:431-437.
- Tani J, Weng HY, Chen HJ, Chang TS, Sung JY, Lin CS. Elucidating unique axonal dysfunction between nitrous oxide abuse and Vitamin B12 deficiency. *Front Neurol* 2019;10:704.
- Waclawik AJ, Luzzio CC, Juhasz-Pocsine K, Hamilton V. Myeloneuropathy from nitrous oxide abuse: unusually high methylmalonic acid and homocysteine levels. *WMJ* 2003;102:43-45.
- Kwon YJ, Rho JH, Hwang J, Baek SH. Unhappy end of 'happy balloons': subacute combined degeneration caused by nitrous oxide gas. *J Clin Neurol* 2019;15:118-119.
- Kang SW, Hong JM, Namgung DW, Choi Y. Neurological manifestations of myeloneuropathy in patients with nitrous oxide intoxication. *J Clin Neurol* 2019;15:116-117.