









# Giant Infrascapular Rheumatoid Nodules Mimicking Elastofibroma Dorsi: A Case Report

배부 탄성섬유종과 유사한 견갑하부에 발생한 류마티스 결절: 증례 보고

Hyuk Gi Hong, MD<sup>1</sup> , Seung-Jin Yoo, MD<sup>2\*</sup> , Yo Won Choi, MD<sup>2</sup> ,  
Seung Sam Paik, MD<sup>3</sup> , Seung Yun Jee, MD<sup>3</sup> , Yeo Eun Kim, MD<sup>1</sup> 

<sup>1</sup>Department of Radiology, Seoul Medical Center, Seoul, Korea  
Departments of <sup>2</sup>Radiology and <sup>3</sup>Pathology, Hanyang University Hospital, Hanyang University College of Medicine, Seoul, Korea

Rheumatoid nodules are the most common extra-articular presentations of rheumatoid arthritis. Although rheumatoid nodules can develop anywhere in the body, they develop most commonly in the subcutaneous region, where they are easily exposed to repetitive trauma or pressure. However, an infrascapular presentation has not yet been reported. We report a case of giant bilateral rheumatoid nodules that developed in the infrascapular area, complicating its distinction from elastofibroma dorsi on radiological examination.

**Index terms** Rheumatoid Nodule; Thoracic Wall; Rheumatoid Arthritis

## INTRODUCTION

Rheumatoid arthritis is one of the most prevalent chronic inflammatory diseases. Primarily involving the joints, it can cause damage to the cartilage or bone (1). The prevalence of rheumatoid arthritis ranges from 0.5% to 1.0% in the general population and can involve extra-articular regions, which present as rheumatoid nodules, pulmonary involvement, or vasculitis (1, 2).

Rheumatoid nodules are the most common extra-articular presentation of rheumatoid arthritis, and they can be found anywhere in the body, both in cutaneous and non-cutaneous regions (1). We report a case of large bilateral rheumatoid nodules in the infrascapular area, which was initially thought to be elastofibroma dorsi. Since it caused serious problems in the daily life performance of patients, the masses were surgically

Received December 24, 2020  
Revised January 28, 2021  
Accepted February 8, 2021







### \*Corresponding author

Seung-Jin Yoo, MD  
Department of Radiology,  
Hanyang University Hospital,  
Hanyang University  
College of Medicine,  
222-1 Wangsimni-ro,  
Seongdong-gu, Seoul 04763,  
Korea.

Tel 82-2-2290-9182  
Fax 82-2-2290-2111  
E-mail seungjinyoo@hanyang.ac.kr

This is an Open Access article distributed under the terms of the Creative Commons Attribution Non-Commercial License (<https://creativecommons.org/licenses/by-nc/4.0>) which permits unrestricted non-commercial use, distribution, and reproduction in any medium, provided the original work is properly cited.

### ORCID iDs

Hyuk Gi Hong   
<https://orcid.org/0000-0001-9283-3285>  
Seung-Jin Yoo   
<https://orcid.org/0000-0002-0779-3889>  
Yo Won Choi   
<https://orcid.org/0000-0003-0508-9430>  
Seung Sam Paik   
<https://orcid.org/0000-0002-8607-4072>  
Seung Yun Jee   
<https://orcid.org/0000-0003-3895-817X>  
Yeo Eun Kim   
<https://orcid.org/0000-0002-6876-8871>

removed and pathologically confirmed as rheumatoid nodules.

## CASE REPORT

This study was approved by the Institutional Review Board of our hospital, and the requirement for informed consent was waived (IRB No. 2020-11-033).

A 59-year-old male presented with a slowly growing bilateral hump at his lower back with aggravated pain for 1 year. Non-tender masses were palpable on the surface. The patient had been diagnosed with rheumatoid arthritis 4 years earlier and was undergoing treatment with methotrexate. He did not smoke or drink alcohol and denied a previous traumatic event affecting the locations of the masses. The patient had no history of surgical intervention. He was admitted to our institution for a better evaluation and more aggressive treatment. Informed consent for the clinical data was not obtained from the patient for this retrospective study.

Initial chest radiography showed deformities of the left 4th, 5th, and 6th ribs, which were probably due to the extrinsic compression of the mass (Fig. 1A). For further evaluation, chest CT with contrast material was performed. Contrast material-enhanced CT on the axial and

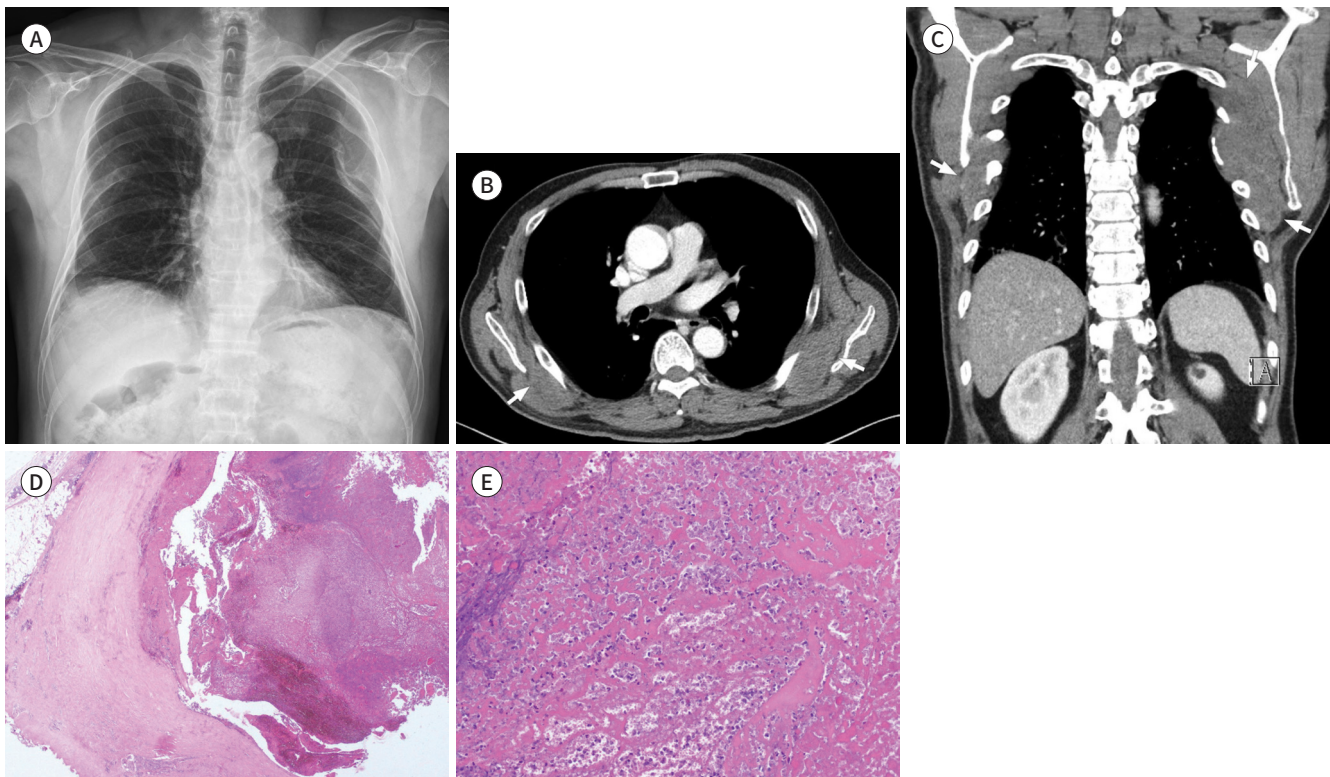
**Fig. 1.** A 59-year old male with giant bilateral infrascapular rheumatoid nodules mimicking elastofibroma dorsi.

**A.** Chest radiography shows severe deformity of the posterior arc of the left 4th, 5th, and 6th ribs.

**B, C.** Contrast-enhanced chest CT axial (**B**) and coronal reformatted (**C**) images show bilateral homogeneous soft tissue masses between the thoracic cage and the subscapularis (arrows).

**D.** Microscopic examination of the pathologic specimens of the mass shows necrotizing granulomatous inflammation with fibrosis in the surrounding stroma, and the absence of the characteristic palisading histiocytes suggests an old lesion (H&E stain,  $\times 20$ ).

**E.** On higher magnification, the lesion consists of degenerated collagen, nuclear fragments, and basophilic material (H&E stain,  $\times 200$ ).  
H&E = hematoxylin and eosin



coronal sections revealed a large soft tissue mass in the bilateral infrascapular area with dimensions of 13.5 cm × 5.0 cm at the right side and 8.2 cm × 4.2 cm at the left side (Fig. 1B, C). The mass did not invade the adjacent structure while preserving the fat plane, but pressure erosion and deformity were detected in the surrounding ribs (Fig. 1B, C). The mass showed no significant contrast enhancement with homogeneous attenuation (Fig. 1B, C).

The bilateral mass was initially diagnosed as elastofibroma dorsi because of its typical location and benign appearance. Although it was considered a benign lesion, it caused a severe limitation of motion due to pain and cosmetic problems. This could lead to a significant interruption of the patient's daily life. Exploratory excision was recommended and initiated later to resolve the patient's medical complaints and improve his day-to-day performance. Pathologic analysis of the surgical specimen showed necrotizing granulomatous inflammation with fibrosis in the surrounding stroma (Fig. 1D, E), which was consistent with a rheumatoid nodule.

The patient was discharged from the hospital healthy with no complications or sequelae, and he showed better life performance without recurrence at follow-up after 1 year.

## DISCUSSION

Rheumatoid nodules constitute the most common extra-articular presentation of rheumatoid arthritis, with an incidence of approximately 7% in patients at the time of diagnosis (2). Most patients with rheumatoid nodules show a positive serum rheumatoid factor, which does not correlate with the severity of the symptoms (3). Smoking is a known risk factor for rheumatoid nodules possibly mediated by an increase in rheumatoid factor production. The pathogenesis of rheumatoid nodules is still unclear (1, 4). Histologic features of rheumatoid nodules include fibrous tissue encircling the central necrotic material (1).

Rheumatoid nodules are usually found on extensor surfaces and areas of pressure or repetitive trauma, especially on the olecranon and the dorsal side of the hand, but they can be found anywhere in the body, including the lung, myocardium, and even the buccal submucosa (1, 5). Rheumatoid nodules are mostly asymptomatic and do not present with major clinical problems; therefore, no medical or surgical treatment is required unless they are symptomatic (3). When they cause pain, nerve entrapment, or functional interference, they need to be surgically resected or reduced in size (1). Treatment options for rheumatoid nodules include direct injection of corticosteroids or surgical resection, and the effectiveness of anti-rheumatic agents is unclear (3, 6). However, local injections have a risk of infection and do not show an immediate effect; therefore, surgical resection is preferred (1).

In our case, since the patient was suffering because of the pain and limited range of motion, certain treatments were necessary and the patient's discomfort resolved after surgery without any complications. Moreover, due to the size of the mass, only surgical resection would have been possible in this case. It was initially thought to be elastofibrodorsi due to its characteristic location and radiologic findings. Elastofibroma dorsi is a benign soft tissue tumor that almost exclusively develops in the infrascapular area and deep to the serratus anterior and latissimus dorsi (7). Up to 60% of elastofibroma dorsi cases grow bilaterally and show similar attenuation as near skeletal muscles (7), and the features mentioned above

closely match our case. However, unlike in our case, elastofibroma dorsi showed relatively poorly defined margins without adjacent bone change (7).

Given the relatively large size and adjacent bone change in our case, we considered soft tissue sarcomas or metastatic disease (7, 8). Soft tissue sarcomas are the second most common primary malignant tumors of the chest wall after bone sarcomas, which are characterized by heterogeneous internal contents, adjacent structure invasions, and enhancement after the intravenous administration of contrast material (8). Soft tissue metastatic disease can be diagnosed based on manifestations including aggressive invasion of adjacent structures and image characteristics specific to the primary neoplasm from which it is derived (8). However, as the masses of our patient did not invade the adjacent structures and showed no contrast enhancement, a primary or secondary malignancy was less likely. Furthermore, the bone change in our case was due to mechanical pressure by the mass and not by tumor invasion.

After a pathological study, the masses of our patient were unexpectedly determined to be rheumatoid nodules. Rheumatoid nodules are usually 2–5 cm in size, and they rarely present with adjacent bone change. However, pressure erosion of the adjacent bones can occur with repeated mechanical pressure (1, 9). However, in our case of rheumatoid nodules, the maximum diameter of the lesions was 13.5 cm, and the masses showed adjacent bone change, which made the radiological diagnosis of rheumatoid nodules difficult. In this case, surgical resection was required because of the pain and functional interference. However, a percutaneous core needle biopsy can help in making a diagnosis and preventing unnecessary surgery. In addition, methotrexate has been reported to accelerate rheumatoid nodule formation in some patients (10); therefore, a switch to alternative antirheumatic agents was considered to prevent the recurrence of the rheumatoid nodules.

Several case reports have shown unusual presentations of rheumatoid nodules; however, to the best of our knowledge, subcutaneous rheumatoid nodules within the infrascapular area, mimicking benign soft tissue tumors such as elastofibroma dorsi, have not been reported. Our case is an example of how the extra-articular masses found in rheumatic patients are likely to be rheumatic nodules, and clinicians should keep this in mind and consider percutaneous biopsy or the changing of medications before unnecessary surgical procedures in such patients.

### Author Contributions

Conceptualization, Y.S.; data curation, H.H.G., Y.S., C.Y.W., P.S.S., J.S.Y.; visualization, H.H.G., Y.S., C.Y.W., J.S.Y., P.S.S.; writing—original draft, H.H.G., Y.S.; and writing—review & editing, Y.S., C.Y.W., P.S.S., K.Y.E.

### Conflicts of Interest

Yo Won Choi has been a Section Editor of the Journal of the Korean Society of Radiology since 2015; however, he was not involved in the peer reviewer selection, evaluation, or decision process of this article. Otherwise, no other potential conflicts of interest relevant to this article were reported.

### Funding

None

## REFERENCES

1. Tilstra JS, Lienesch DW. Rheumatoid nodules. *Dermatol Clin* 2015;33:361-371
2. Nyhäll-Wåhlin BM, Turesson C, Jacobsson LT, Nilsson JÅ, Forslind K, Albertsson K, et al. The presence of rheumatoid nodules at early rheumatoid arthritis diagnosis is a sign of extra-articular disease and predicts radiographic progression of joint destruction over 5 years. *Scand J Rheumatol* 2011;40:81-87
3. Sayah A, English JC 3rd. Rheumatoid arthritis: a review of the cutaneous manifestations. *J Am Acad Dermatol* 2005;53:191-209
4. Nyhäll-Wåhlin BM, Jacobsson LT, Petersson IF, Turesson C; BARFOT study group. Smoking is a strong risk factor for rheumatoid nodules in early rheumatoid arthritis. *Ann Rheum Dis* 2006;65:601-606
5. Tay GC, Sauer DA, Andersen PE. Rheumatoid nodule presenting as a buccal submucosal nodule: a rare presentation of a common disease. *Head Neck* 2017;39:E12-E14
6. Kaiser MJ, Bozonnat MC, Jorgensen C, Daurès JP, Sany J. Effect of etanercept on tenosynovitis and nodules in rheumatoid arthritis. *Arthritis Rheum* 2002;46:559-560
7. Ochsner JE, Sewall SA, Brooks GN, Agni R. Best cases from the AFIP: elastofibroma dorsi. *Radiographics* 2006;26:1873-1876
8. Carter BW, Benveniste MF, Betancourt SL, de Groot PM, Lichtenberger JP 3rd, Amini B, et al. Imaging evaluation of malignant chest wall neoplasms. *Radiographics* 2016;36:1285-1306
9. Dorfman HD, Norman A, Smith RJ. Bone erosion in relation to subcutaneous rheumatoid nodules. *Arthritis Rheum* 1970;13:69-73
10. Patatianian E, Thompson DF. A review of methotrexate-induced accelerated nodulosis. *Pharmacotherapy* 2002;22:1157-1162

## 배부 탄성섬유종과 유사한 견갑하부에 발생한 류마티스 결절: 증례 보고

홍혁기<sup>1</sup> · 유승진<sup>2\*</sup> · 최요원<sup>2</sup> · 백승삼<sup>3</sup> · 지승윤<sup>3</sup> · 김여은<sup>1</sup>

류마티스 결절은 류마티스관절염의 가장 흔한 관절 외 증상이다. 류마티스 결절은 우리 몸의 어느 곳에서나 발생할 수 있지만 반복적인 외상이나 압력에 쉽게 노출되는 피하 부위에서 가장 흔하게 발생한다. 그러나 견갑하부에 자란 류마티스 결절은 보고된 바가 없었고, 이에 저자는 배부 탄성섬유종과 영상의학적으로 구분이 어려웠던 견갑하부에 발생한 류마티스 결절의 사례를 보고하고자 한다.

<sup>1</sup>서울의료원 영상의학과, <sup>2</sup>한양대학교 의과대학 한양대학교병원 <sup>2</sup>영상의학과, <sup>3</sup>병리학과