


# Brain activation in response to visual sexual stimuli in male patients with right middle cerebral artery infarction

## The first case-control functional magnetic resonance imaging study

Jae Hyeon Park, MD<sup>a</sup>, Eunkyung Kim, PhD<sup>b</sup>, Hyungpil Cho, MD<sup>a</sup>, Dong Woo Park, MD, PhD<sup>c</sup>, Joonho Choi, MD, PhD<sup>d</sup>, Seong Ho Jang, MD, PhD<sup>a,\*</sup> 

### Abstract

Sexual dysfunction is a common problem after cerebral infarction; however, little is known about sexual arousal in poststroke patients. Thus, this study aimed to investigate brain activation in response to visual sexual stimuli in patients with right middle cerebral artery (MCA) territory infarction using functional magnetic resonance imaging (fMRI). Using fMRI in 20 participants (11 right MCA infarction patients and 9 age-matched healthy controls), we assessed brain activation elicited by visual sexual stimuli (erotic images) and visual nonsexual stimuli (landscape images). In right MCA infarction patients, the left dorsolateral prefrontal cortex and the left frontal subgyral area were more strongly activated by visual sexual stimuli than by nonvisual sexual stimuli. Brain areas that were more activated by visual sexual stimuli in right MCA infarction patients than in controls included the right parahippocampal gyrus and the bilateral frontal subgyral area. These fMRI results suggest that brain activation patterns in response to visual sexual stimuli might be influenced by right MCA infarction. Further research is needed to explore the association between sexual dysfunction and brain activation in poststroke patients.

**Abbreviations:** fMRI = functional magnetic resonance imaging, MCA = middle cerebral artery, PET = positron emission tomography.

**Keywords:** brain activation, brain mapping, cerebral infarction, functional magnetic resonance imaging, visual sexual stimulation

Editor: Narayan Subramanian.

This work received support from the Medical Device Technology Development Program (201900000002517, Development of Patient Custom Active Rehabilitation Total Solution) funded by the Ministry of Trade, Industry, and Energy (MOTIE, Korea).

The authors have no conflicts of interest to disclose.

The datasets generated during and/or analyzed during the current study are available from the corresponding author on reasonable request.

<sup>a</sup> Department of Rehabilitation Medicine, Hanyang University Guri Hospital, Gyeonggi-do, <sup>b</sup> Department of Rehabilitation Medicine, Seoul National University Hospital, Seoul, <sup>c</sup> Department of Radiology, <sup>d</sup> Department of Psychiatry, Hanyang University Guri Hospital, Gyeonggi-do, Republic of Korea.

\* Correspondence: Seong Ho Jang, Department of Rehabilitation Medicine, Hanyang University Guri Hospital, Guri-si, Gyeonggi-do, Republic of Korea (e-mail: systole77@hanmail.net).

Copyright © 2021 the Author(s). Published by Wolters Kluwer Health, Inc. This is an open access article distributed under the terms of the Creative Commons Attribution-Non Commercial License 4.0 (CCBY-NC), where it is permissible to download, share, remix, transform, and build upon the work provided it is properly cited. The work cannot be used commercially without permission from the journal.

How to cite this article: Park JH, Kim E, Cho H, Park DW, Choi J, Jang SH. Brain activation in response to visual sexual stimuli in male patients with right middle cerebral artery infarction: the first case-control functional magnetic resonance imaging study. *Medicine* 2021;100:21(e25823).

Received: 8 April 2020 / Received in final form: 23 October 2020 / Accepted: 13 April 2021

<http://dx.doi.org/10.1097/MD.00000000000025823>

## 1. Introduction

Stroke is one of the major causes of disability and can lead to impaired psychological and physical function.<sup>[1–3]</sup> Following a stroke, patients often suffer from sexual dysfunction, including decreased libido, decreased coital frequency, erectile dysfunction, and sexual dissatisfaction.<sup>[4–6]</sup> Although sexual dysfunction causes poorer quality of life in poststroke patients, patients are often reluctant to discuss sexual dysfunction with physicians.<sup>[7,8]</sup> As a result, sexual dysfunction in poststroke patients is under-recognized.

There are numerous suggested causes of sexual dysfunction in poststroke patients, both psychological (such as depression, anxiety, or low self-esteem) and organic (such as stroke location, comorbidities, or medications).<sup>[7–9]</sup> However, the association between the location of the stroke and sexual dysfunction is still not well understood. Some studies have reported that sexual dysfunction is more common in poststroke patients with right hemispheric lesions than those with left hemispheric lesions,<sup>[10,11]</sup> while another study has reported the opposite result.<sup>[6]</sup> Furthermore, little is known about which brain regions are activated during sexual response in poststroke patients.

Several neuroimaging studies using functional magnetic resonance imaging (fMRI) or positron emission tomography (PET) have been conducted to evaluate the activation of brain regions during sexual response in heterosexual males.<sup>[12–18]</sup> Of

these 2 neuroimaging modalities, fMRI has been more widely performed due to advantages over PET such as higher temporal resolution and lower invasiveness.<sup>[14]</sup> Using fMRI, brain activation in response to sexual visual stimuli has been measured in heterosexual males, homosexual males, male-to-female transsexual individuals, and psychogenic erectile dysfunction patients.<sup>[19–22]</sup> In healthy heterosexual males, using fMRI, the activated brain regions in response to visual sexual stimuli included the parietal lobe, occipitotemporal area, orbitofrontal cortex, anterior cingulate gyrus, insula, amygdala, thalamus, and caudate nucleus.<sup>[14–16,18,23]</sup> However, literature on brain activation during sexual response in poststroke patients is scarce.

Thus, the aims of this study were to use fMRI to investigate

- (1) which brain regions are activated in response to visual sexual stimuli in male patients with chronic right middle cerebral artery (MCA) territory infarction, and
- (2) differences in brain activation patterns during sexual response between chronic right MCA infarction patients and healthy controls.

In this study, we recruited patients with chronic right MCA infarction because MCA territory infarction is a common cause of stroke, and some patients with infarction of the dominant hemisphere (usually left) suffer from aphasia which could lead to difficulty in an fMRI study.<sup>[24,25]</sup>

## 2. Methods

### 2.1. Participants

Thirteen male participants who had a history of right MCA territory infarction were recruited. The inclusion criteria were:

- (1) first-episode cerebral infarction,
- (2) elapsed time since onset of cerebral infarction  $\geq 6$  months,
- (3) sufficient cognitive and communication function to understand the study protocol, and
- (4) heterosexual male.

The exclusion criteria were:

- (1) pre-existing sexual dysfunction before cerebral infarction,
- (2) recurrent cerebral infarction,
- (3) cerebral infarction in multiple arterial territories,
- (4) cognitive dysfunction (Mini-Mental Status Examination Score  $< 23$ ),
- (5) hemispatial neglect,
- (6) psychiatric problems such as mood disorders or substance abuse,
- (7) use of medications that may affect sexual response including antidepressants, or
- (8) other coexisting neurological disorders that can influence sexual functions.

Eleven healthy heterosexual male participants were recruited as age-matched controls. This study was approved by the Institutional Review Board of our hospital. All participants provided written informed consents before participation.

### 2.2. Visual stimulation and image acquisition

Two sets of photographs were used for visual stimulation:

- (1) erotic images, showing naked, sexually interacting couples of both sexes, and

- (2) nonsexually explicit images of landscapes with a similar hue and brightness to erotic images to be used as controls to assess the effect of nonsexual, nonspecific visual stimulation.

Photographs from the International Affective Picture System were not used because their cultural or ethnic characteristics could influence the patients' perception of images as erotic. Thus, the erotic and landscape image sets each consisted of 10 photographs which were chosen by a group of psychiatrists, psychiatrists, neurologists, and urologists specializing in sexuality and issues related to sexual function, who were not otherwise involved in the study. An fMRI blocked-design paradigm was employed in this study and consisted of rest and task blocks. During rest blocks, a gray screen was shown to the participant for 15 seconds, and during task blocks, a landscape image or an erotic image set was shown to the participant for 30 seconds. The time duration for each photograph was 3 seconds. A total of 12 alternating rest and task blocks were presented followed by 15-second dummy scans. The order of blocks was rest, task (landscape image), rest, task (erotic image), repeated 3 times, and the order of photographs in each set was consistent throughout the experiment. Participants were asked to abstain from alcohol and caffeine 24 hours before the functional image acquisition.

High-resolution T1-weighted anatomical images were obtained with a 3T MRI system (Achieva TX, Philips Medical Systems, Best, Netherlands) using a 32-channel SENSE head coil. After anatomical scanning, whole-brain dynamic functional images (echo-planar imaging, gradient-recalled echo; repetition time (TR)=3000 ms, echo time (TE)=30 ms, flip angle=65°, field of view (FOV)=220 mm, 80 × 80 matrix, thirty 4.5 mm axial sections with no inter-slice gap) with a total of 120 volumes were acquired to measure blood oxygen level-dependent effects.

### 2.3. Data preprocessing and analysis

Image preprocessing involved slice timing correction, realignment, co-registration, normalization, and smoothing. Briefly, after the first 5 dummy scans were discarded to avoid nonequilibrium effects of the MR signal, the functional images were corrected for slice timing differences, followed by within-subject realignment to the mean image to correct motion artifacts with 6 rigid body spatial transformations. Each subject's anatomical T1 image was segmented to obtain a forward deformation map from the individual space to the Montreal Neurological Institute space template. The realigned functional images were spatially normalized to the Montreal Neurological Institute space template using the deformation map. To increase signal to noise ratio, the normalized images underwent smoothing with a Gaussian kernel with a width of 8 mm (full width at half-maximum).

The preprocessed individual data were analyzed using a fixed-effects model, convolved with a canonical hemodynamic response function. The 6 head movement parameters calculated from the realignment procedure were used as nuisance variables. Data were high-pass filtered with a 128 second cutoff period. The effects of the different visual stimuli (gray images, landscape images, and erotic images) on signal changes were evaluated at the voxel level using a general linear model. Contrast images from each subject were the

- (1) landscape image versus erotic image,
- (2) gray image versus erotic image, and
- (3) gray image versus landscape image.

Participants whose fMRI results did not show any difference between contrast images were excluded owing to the concern that participants did not concentrate on the visual stimuli. Group-level analyses were conducted using 1- and 2-sample *t*-tests to assess signal changes for each contrast in each group, and between the groups with age as a nuisance variable. A threshold of  $P < .001$  with cluster-wise false discovery rate correction  $P < .05$  was considered significant for the 1-sample *t*-test. A threshold of  $P < .001$  (uncorrected) was considered significant for the 2-sample *t*-test with a cluster size  $>20$  voxels. Data preprocessing and analyses were performed with Statistical Parametric Mapping 12 (SPM 12) software (Wellcome Trust Centre for Neuroimaging, University College London, London, UK).

### 3. Results

Of 13 stroke patients and 11 healthy controls screened, 2 participants in each group were excluded resulting in a final sample of 11 stroke patients and 9 healthy controls. The mean age of patients was  $56.21 \pm 8.9$  years (range: 45–68 years) and that of controls was  $53.7 \pm 9.3$  years (range: 40–67 years). The mean elapsed time from onset of cerebral infarction was  $48.0 \pm 33.4$  months (range: 8–105 months). All poststroke patients had

left-sided motor weakness, and the mean score of the Korean Modified Barthel Index was 79.3 (range: 52–92). All patients and controls were right-handed.

Brain regions activated by the erotic and landscape images in patients with right MCA infarct are shown in Table 1 and Figure 1. Stronger brain activity during presentation of erotic images compared with landscape images was found in the left frontal subgyral area and left dorsolateral prefrontal cortex ( $P < .001$ , cluster-wise corrected false discovery rate  $P < .05$ ). No areas of the brain showed reduced activity during either the landscape image or the erotic image compared to the rest condition, or the landscape image compared to the erotic image.

Table 2 and Figure 2 show distinct patterns of brain activation during presentation of the erotic images compared to the landscape images between right MCA infarction patients and controls. Patients with right MCA infarction demonstrated significantly higher activation in the right parahippocampal gyrus and both sides of the frontal subgyral area compared to controls ( $P < .001$ ).

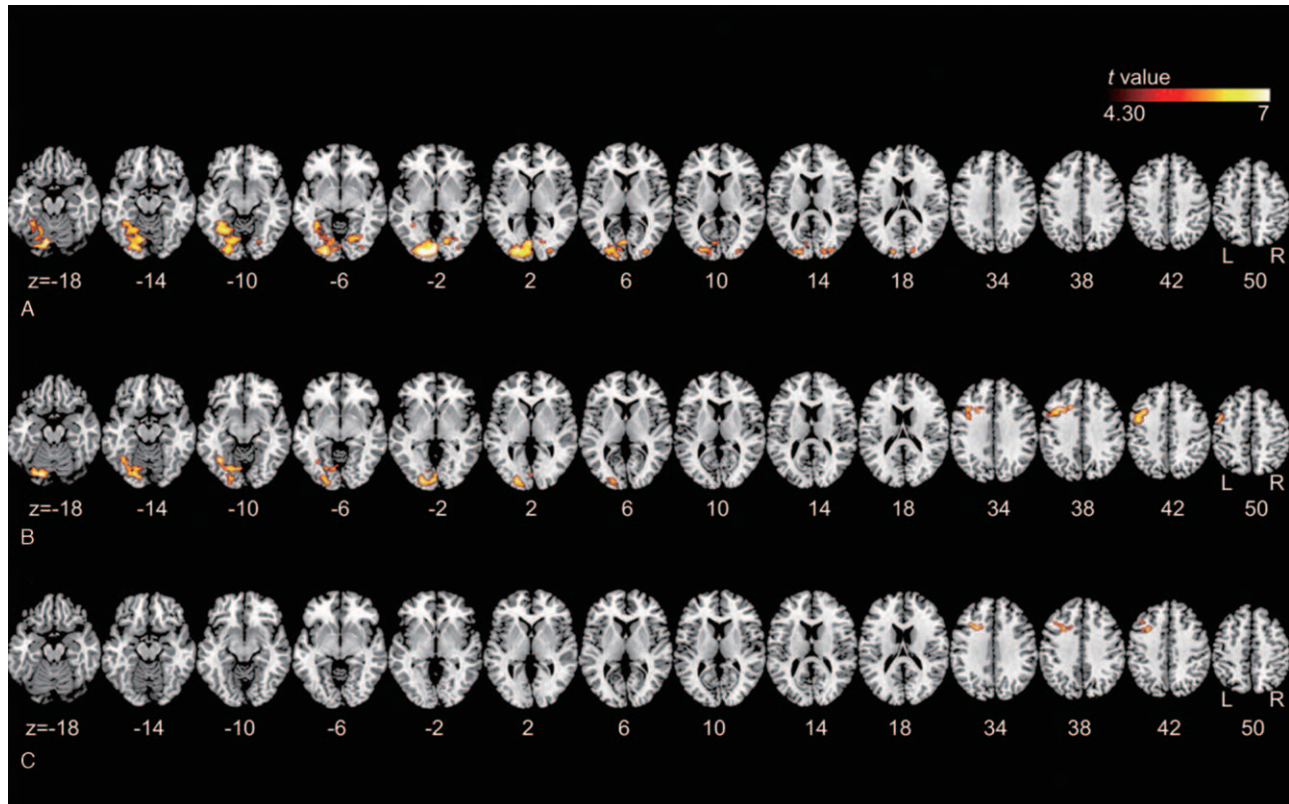
### 4. Discussion

This study aimed to identify the brain regions activated by visual sexual stimuli in patients with right MCA infarction, and to

**Table 1**  
Brain regions activated in patients with right middle cerebral artery territory infarction.

Contrast	Cluster <i>P</i> (FWE corr)	Cluster size	Peak intensity ( <i>T</i> )	MNI coordinates			Region name			
				<i>x</i>	<i>y</i>	<i>z</i>				
Landscape image > Gray screen	.000	2195	9.93	−4	−90	−2	Calcarine area left			
			8.91	−2	−82	−2	Lingual area left			
			8.63	−10	−74	−18	Cerebellum VI left			
			8.52	−18	−92	−2	Middle occipital area left			
			7.04	−14	−84	−16	Lingual area left			
			7.01	−18	−90	18	Middle occipital area left			
	.005	147	6.01	16	−74	0	Lingual area right			
			5.35	22	−68	−6	Lingual area right			
			5.67	32	−90	6	Middle occipital area right			
	.009	130	4.93	14	−86	16	Calcarine area right			
			4.92	34	−84	−4	Inferior occipital area right			
			4.72	32	−88	14	Middle occipital area right			
			4.61	24	−92	12	Superior occipital area right			
			Erotic image > Gray screen	.000	401	12.21	−26	14	36	Ventrolateral prefrontal cortex left
						11.07	−34	18	36	Ventrolateral prefrontal cortex left
9.55	−50	0				50	Precentral area left			
7.88	−16	20				38	Frontal subgyral left			
7.33	−38	10				40	Precentral area/Middle frontal area left			
7.10	−44	4				44	Precentral area left			
.000	878	8.46		−18	−82	−18	Cerebellum VI left			
		8.00		−38	−58	−12	Fusiform area left			
		7.27		−2	−90	−4	Calcarine area left			
		7.27		−28	−80	−16	Cerebellum VI left			
		7.26		−20	−90	0	Middle occipital area left			
		6.17		−22	−72	−8	Lingual area left			
		Erotic image > Landscape image		.013	132	8.67	−24	16	34	Frontal subgyral left
						6.99	−34	20	36	Dorsolateral prefrontal cortex left
						6.77	−30	16	42	Dorsolateral prefrontal cortex left
6.11	−40		24			42	Dorsolateral prefrontal cortex left			
4.78	−38		12			42	Dorsolateral prefrontal cortex left			

A threshold of uncorrected  $P < .001$  with a cluster-based family-wise error rate correction of  $P < .05$  is considered significant; table shows 6 local maxima more than 8.00 mm apart. FWE-corr = family-wise error correction, MNI = Montreal Neurological Institute.



**Figure 1.** Brain areas showing significantly increased activity in patients with right middle cerebral artery infarction. Contrasts of (A) landscape image over gray image, (B) erotic image over gray image, and (C) erotic image over landscape image using a 1-sample *t*-test (significance threshold of  $P < .001$  with a cluster-wise false discovery rate correction of  $P < .05$ ).

investigate differences in these patterns compared with those of healthy controls. Our results showed that the left frontal subgyral area and left dorsolateral prefrontal cortex were more activated by visual sexual stimuli than visual nonsexual stimuli in patients with right MCA infarction. The right parahippocampal gyrus and bilateral frontal subgyral areas were more strongly activated in response to visual sexual stimuli in patients with right MCA infarction than in healthy controls.

Previous studies have demonstrated a relationship between the right hemisphere and sexual function. In PET studies investigating brain activation during ejaculation by penile stimulation, increased regional cerebral blood flow was observed in the right posterior insula and adjacent secondary somatosensory cortex during sexual arousal, and in the right inferior frontal gyrus, temporal cortex, and precuneus during ejaculation.<sup>[12,13]</sup> Fur-

thermore, it has been suggested that the right hemisphere is dominant in comprehending emotional stimuli and attention which is important for sexual arousal; therefore, poststroke patients with right parietal lesions may be prone to emotional disorders.<sup>[26,27]</sup>

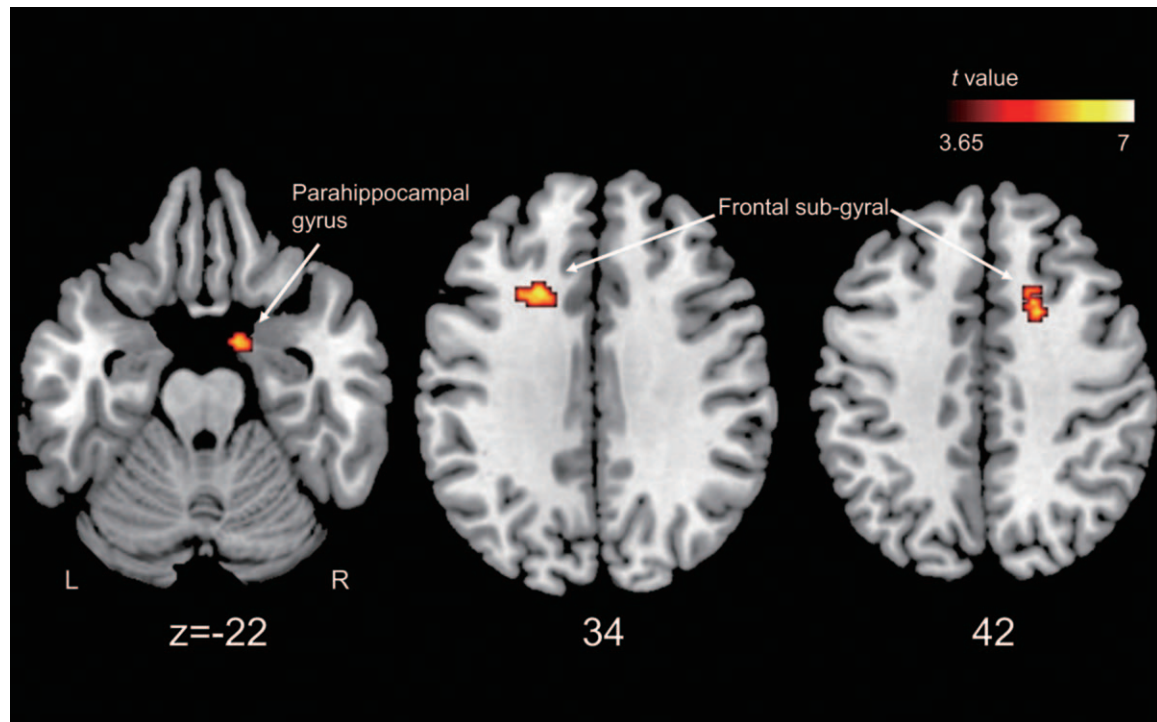
Sexual arousal originates from the interaction of 4 coordinated components: physiological, emotional, motivational, and cognitive mechanisms.<sup>[23,28,29]</sup> Thus, various brain regions are activated by visual sexual stimuli in healthy young heterosexual males, including cortical regions (including the frontal premotor, parietal, inferotemporal, lateral occipitotemporal, orbitofrontal, medial prefrontal, anterior cingulate, and insular cortices) and subcortical regions (including the thalamus, hypothalamus, caudate nucleus, claustrum, amygdala, and cerebellum).<sup>[14,15,18,23]</sup>

**Table 2**

**Differences in brain activation towards visual sexual stimuli between patients with right middle cerebral arterial territory infarct and controls. Contrast: erotic image over landscape image.**

Contrast	Cluster size	Peak intensity ( <i>T</i> )	MNI coordinates			Region name
			<i>x</i>	<i>y</i>	<i>z</i>	
Patients > Controls	69	5.70	-22	18	34	Frontal subgyral left
	32	5.61	18	14	42	Frontal subgyral right
	24	5.14	12	0	-22	Parahippocampal gyrus right

Only significant values (a threshold of uncorrected  $P < .001$  at the voxel level, with  $k > 20$ ) are reported. MNI=Montreal Neurological Institute.



**Figure 2.** Brain areas showing significantly higher activity in the contrast (sexual image over landscape image) in patients with right middle cerebral artery territory infarct than those in control using a 2-sample *t*-test (significance threshold of  $P < .001$ ).

In this study, increased brain activation in the left dorsolateral prefrontal cortex and left frontal subgyral area in right MCA infarction patients was observed during presentation of visual sexual stimuli compared with that of visual nonsexual stimuli. The dorsolateral prefrontal cortex is connected with the other regions of the prefrontal cortex and is critical for the integration of sensory information.<sup>[30]</sup> In a previous study using functional near-infrared spectroscopy, the dorsolateral prefrontal cortex was activated during and after exposure to visual sexual stimuli, whereas exposure to visual nonsexual stimuli did not produce activation in this region.<sup>[31]</sup> These findings suggest that the dorsolateral prefrontal cortex might be associated with preserving the depiction of visual sexual stimuli in working memory and mediating the self-regulation of sexual arousal. Some brain regions, which have been shown to be activated by visual sexual stimuli in healthy heterosexual males, were not activated in this study. These findings might result from direct damage to those brain regions by MCA infarction or from damage to any part of the neural circuit regulating sexual arousal.

Interestingly, the comparison of brain activation patterns in response to visual sexual stimuli between the groups showed that the right parahippocampal gyrus and bilateral frontal subgyral areas were more strongly activated in the right MCA infarction patients. The parahippocampal cortex has been shown to be more strongly activated by environmental scenes than other visual stimuli such as faces or objects,<sup>[32]</sup> and is associated with processing spatial contextual information.<sup>[33–35]</sup> Moreover, meaningless contextual shapes have been shown to activate the right parahippocampal cortex more strongly than the left parahippocampal cortex, while contextual objects predominantly stimulate the left parahippocampal cortex.<sup>[35]</sup> The pathophysiological mechanism of these fMRI findings is largely unknown.

Further research is needed to explore associations between brain activation patterns during sexual arousal and sexual dysfunction in poststroke patients.

A major strength of the current study is that it is the first investigation among poststroke patients of brain regions that are activated while viewing visual sexual stimuli. These results provide valuable information to further elucidate the mechanism of sexual dysfunction in poststroke patients. Nevertheless, several limitations of this study must be noted. First, the study sample size is small, and although we recruited patients with stroke in the same vascular territory, the sample was relatively heterogeneous in terms of age, infarcted area, and time elapsed since the stroke. Second, we did not assess sexual arousal toward visual sexual stimuli using self-report or penile enlargement measures. Third, the duration or type of visual sexual stimuli might be insufficient for sexual arousal in some participants. Fourth, patients with other cerebral territory infarctions, such as left MCA infarction, were not recruited. Thus, further studies with larger sample sizes, including patients with other cerebral artery territory infarctions, as well as investigations of sexual arousal, are needed.

Despite the above limitations, this study is the first to demonstrate the impact of stroke on brain activation patterns during presentation of visual sexual stimuli. Using fMRI, this study revealed that the left frontal subgyral area and left dorsolateral prefrontal cortex were activated by visual sexual stimuli in right MCA infarction patients, and the right parahippocampal gyrus and bilateral frontal subgyral areas were more strongly activated by visual sexual stimuli in patients than in controls. These findings suggest that sexual arousal is affected by right MCA infarction. This study may help physicians to better understand sexual arousal in poststroke patients and provide clues about areas of further investigation.

## Author contributions

**Conceptualization:** Seong Ho Jang.

**Data curation:** Hyungpil Cho.

**Formal analysis:** Jae Hyeon Park, Eunkyung Kim.

**Funding acquisition:** Seong Ho Jang.

**Investigation:** Hyungpil Cho.

**Methodology:** Eunkyung Kim, Dong Woo Park, Joonho Choi.

**Project administration:** Seong Ho Jang.

**Resources:** Dong Woo Park, Seong Ho Jang.

**Software:** Eunkyung Kim.

**Supervision:** Dong Woo Park, Joonho Choi, Seung Hoon Han.

**Visualization:** Eunkyung Kim.

**Writing – original draft:** Jae Hyeon Park.

**Writing – review & editing:** Eunkyung Kim, Hyungpil Cho, Dong Woo Park, Joonho Choi, Seung Hoon Han, Seong Ho Jang.

## References

- [1] Haacke C, Althaus A, Spottke A, Siebert U, Back T, Dodel R. Long-term outcome after stroke: evaluating health-related quality of life using utility measurements. *Stroke* 2006;37:193–8.
- [2] Mukherjee D, Patil CG. Epidemiology and the global burden of stroke. *World Neurosurg* 2011;76(6 Suppl):S85–90.
- [3] Chen Q, Cao C, Gong L, Zhang Y. Health related quality of life in stroke patients and risk factors associated with patients for return to work. *Medicine (Baltimore)* 2019;98:e15130.
- [4] Korpelainen JT, Nieminen P, Myllylä VV. Sexual functioning among stroke patients and their spouses. *Stroke* 1999;30:715–9.
- [5] Kimura M, Murata Y, Shimoda K, Robinson RG. Sexual dysfunction following stroke. *Compr Psychiatry* 2001;42:217–22.
- [6] Giaquinto S, Buzzelli S, Di Francesco L, Nolfi G. Evaluation of sexual changes after stroke. *J Clin Psychiatry* 2003;64:302–7.
- [7] Park JH, Ovbiagele B, Feng W. Stroke and sexual dysfunction - a narrative review. *J Neurol Sci* 2015;350:7–13.
- [8] Calabro RS, Gervasi G, Bramanti P. Male sexual disorders following stroke: an overview. *Int J Neurosci* 2011;121:598–604.
- [9] Rees PM, Fowler CJ, Maas CP. Sexual function in men and women with neurological disorders. *Lancet* 2007;369:512–25.
- [10] Coslett HB, Heilman KM. Male sexual function. Impairment after right hemisphere stroke. *Arch Neurol* 1986;43:1036–9.
- [11] Agarwal A, Jain DC. Male sexual dysfunction after stroke. *J Assoc Physicians India* 1989;37:505–7.
- [12] Holstege G, Georgiadis JR, Paans AM, Meiners LC, van der Graaf FH, Reinders AA. Brain activation during human male ejaculation. *J Neurosci* 2003;23:9185–93.
- [13] Georgiadis JR, Holstege G. Human brain activation during sexual stimulation of the penis. *J Comp Neurol* 2005;493:33–8.
- [14] Mouras H, Stoleru S, Bittoun J, et al. Brain processing of visual sexual stimuli in healthy men: a functional magnetic resonance imaging study. *Neuroimage* 2003;20:855–69.
- [15] Ferretti A, Caulo M, Del Gratta C, et al. Dynamics of male sexual arousal: distinct components of brain activation revealed by fMRI. *Neuroimage* 2005;26:1086–96.
- [16] Kim SW, Sohn DW, Cho YH, et al. Brain activation by visual erotic stimuli in healthy middle aged males. *Int J Impot Res* 2006;18:452–7.
- [17] Seo Y, Jeong B, Kim JW, Choi J. The relationship between age and brain response to visual erotic stimuli in healthy heterosexual males. *Int J Impot Res* 2010;22:234–9.
- [18] Seok JW, Sohn JH, Cheong C. Neural substrates of sexual arousal in heterosexual males: event-related fMRI investigation. *J Physiol Anthropol* 2016;35:8.
- [19] Kagerer S, Klucken T, Wehrum S, et al. Neural activation toward erotic stimuli in homosexual and heterosexual males. *J Sex Med* 2011;8:3132–43.
- [20] Zhang M, Hu S, Xu L, et al. Neural circuits of disgust induced by sexual stimuli in homosexual and heterosexual men: an fMRI study. *Eur J Radiol* 2011;80:418–25.
- [21] Oh SK, Kim GW, Yang JC, Kim SK, Kang HK, Jeong GW. Brain activation in response to visually evoked sexual arousal in male-to-female transsexuals: 3.0 tesla functional magnetic resonance imaging. *Korean J Radiol* 2012;13:257–64.
- [22] Cera N, Di Pierro ED, Sepede G, et al. The role of left superior parietal lobe in male sexual behavior: dynamics of distinct components revealed by FMRI. *J Sex Med* 2012;9:1602–12.
- [23] Stoleru S, Fonteille V, Cornelis C, Joyal C, Joyal V. Functional neuroimaging studies of sexual arousal and orgasm in healthy men and women: a review and meta-analysis. *Neurosci Biobehav Rev* 2012;36:1481–509.
- [24] Caplan LR, Gorelick PB, Hier DB. Race, sex and occlusive cerebrovascular disease: a review. *Stroke* 1986;17:648–55.
- [25] Fridriksson J, den Ouden DB, Hillis AE, et al. Anatomy of aphasia revisited. *Brain* 2018;141:848–62.
- [26] Heilman KM, Van Den Abell T. Right hemisphere dominance for attention: the mechanism underlying hemispheric asymmetries of inattention (neglect). *Neurology* 1980;30:327–30.
- [27] Heilman KM, Bowers D, Valenstein E, Watson RT. The right hemisphere: neuropsychological functions. *J Neurosurg* 1986;64:693–704.
- [28] de Jong DC. The role of attention in sexual arousal: implications for treatment of sexual dysfunction. *J Sex Res* 2009;46:237–48.
- [29] Stoleru S, Gregoire MC, Gerard D, et al. Neuroanatomical correlates of visually evoked sexual arousal in human males. *Arch Sex Behav* 1999;28:1–21.
- [30] Cheng JC, Secondary J, Burke WH, Fedoroff JP, Dwyer RG. Neuroimaging and sexual behavior: identification of regional and functional differences. *Curr Psychiatry Rep* 2015;17:55.
- [31] Leon-Carrion J, Martin-Rodriguez JF, Damas-Lopez J, et al. Does dorsolateral prefrontal cortex (DLPFC) activation return to baseline when sexual stimuli cease? The role of DLPFC in visual sexual stimulation. *Neurosci Lett* 2007;416:55–60.
- [32] Epstein R, Kanwisher N. A cortical representation of the local visual environment. *Nature* 1998;392:598–601.
- [33] Bar M, Aminoff E. Cortical analysis of visual context. *Neuron* 2003;38:347–58.
- [34] Gronau N, Neta M, Bar M. Integrated contextual representation for objects' identities and their locations. *J Cogn Neurosci* 2008;20:371–88.
- [35] Li M, Lu S, Zhong N. The parahippocampal cortex mediates contextual associative memory: evidence from an fMRI study. *Biomed Res Int* 2016;2016:9860604.