



BRIEF REPORT

A Case of Verruciform Xanthoma of the Sole

Hyun-Min Seo, Ju Wang Jang, Se Kwang Park, You Jin Jung, Tae Lim Kim, Young Gyun Kim, Jounge Soo Kim

Department of Dermatology, Hanyang University Guri Hospital, Guri, Korea

Dear Editor:

Verruciform xanthoma (VX) is a rare non-neoplastic lesion characterized histologically by verrucous epithelial proliferation without cellular atypia and foamy histiocytes within elongated dermal papillae. It usually occurs in the oral mucosa as an asymptomatic solitary verrucous, papillomatous papule or plaque¹. Extra-oral manifestation is very rare, and it must be differentiated from other types of verrucous lesions.

A 19-year-old female presented with well circumscribed yellowish verrucous papules and plaques on the bases of the left second and third toes that had been present for 6 months (Fig. 1). She had no history of any preceding skin lesions nor other systemic diseases. Histopathologic examination revealed marked hyperkeratosis, irregular acanthosis, and elongated rete ridges in the epidermis with no cytological atypia (Fig. 2A~C). The papillary dermis was fil-

led with mononucleated foamy cells with a large amount of pale foamy cytoplasm, which is the hallmark of the VX (Fig. 2D). The dermoepidermal junction was focally obscured by the infiltration of the foamy cells. Immunohistochemically, these cells were positive for CD68 (Fig. 2E). Polymerase chain reaction (PCR) for human papillomavirus (HPV) DNA was negative. Immunohistochemistry for p16 was focally positive on epidermal cells, not on the dermal foamy cells (Fig. 2F). From these findings, she was diagnosed with VX. The patient was treated with CO₂ laser for the residual lesions and has shown no evidence of recurrence. We received the patient's consent form about publishing all photographic materials.

First described by Shafer² in 1971, a number of case reports on VX have been published. Most cases presented oral and genital manifestations, and fewer than 40 cases of extraoral/extra anogenital VX have been reported in the

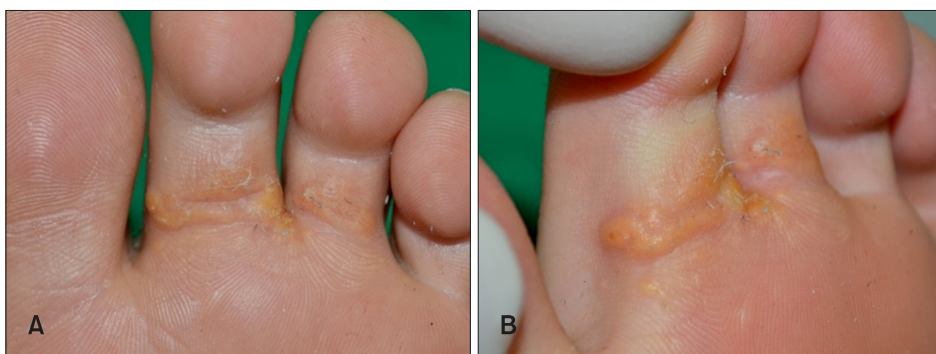


Fig. 1. (A, B) The patient presented with well-circumscribed yellowish verrucous papules and plaques on the base of the left foot by the second and third toes.

Received December 5, 2019, Revised January 3, 2020, Accepted for publication January 9, 2020

Corresponding author: Jounge Soo Kim, Department of Dermatology, Hanyang University Guri Hospital, 153 Gyeongchun-ro, Guri 11923, Korea. Tel: 82-31-560-2284, Fax: 82-31-557-4872, E-mail: tuentuen@hanyang.ac.kr
ORCID: <https://orcid.org/0000-0002-3014-9645>

This is an Open Access article distributed under the terms of the Creative Commons Attribution Non-Commercial License (<http://creativecommons.org/licenses/by-nc/4.0>) which permits unrestricted non-commercial use, distribution, and reproduction in any medium, provided the original work is properly cited.

Copyright © The Korean Dermatological Association and The Korean Society for Investigative Dermatology

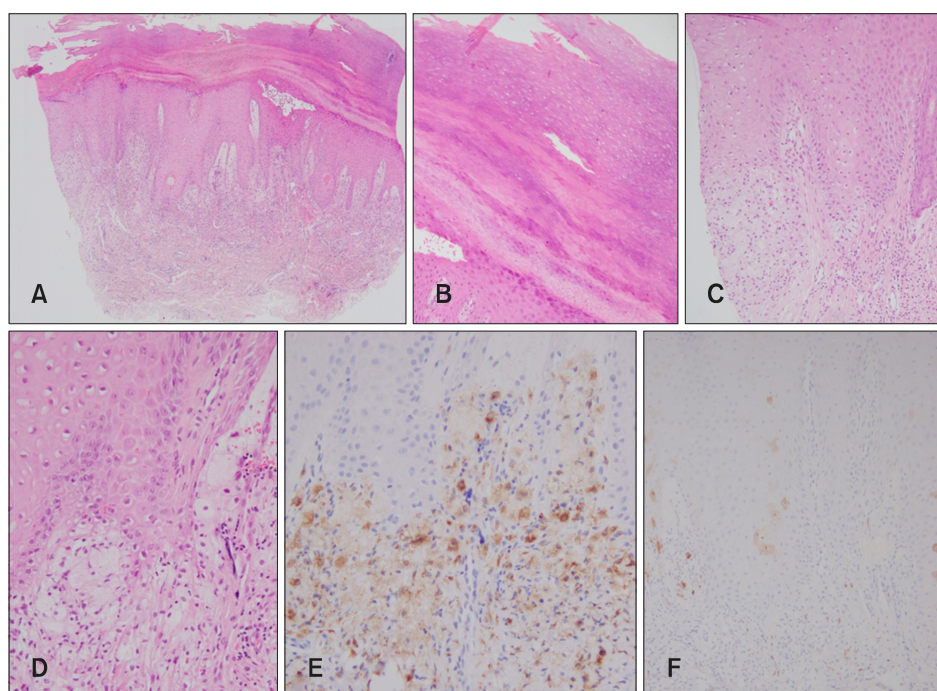


Fig. 2. (A) Histopathological examination revealed epidermal hyperplasia, hyperkeratosis, acanthosis, and cellular infiltration in the upper dermis (H&E, $\times 40$). (B) Compact hyperkeratosis and focal parakeratosis were observed (H&E, $\times 100$). (C, D) Mononucleated foamy cells were found in the papillary dermis (C: H&E, $\times 100$; D: H&E, $\times 200$). (E, F) Foamy cells were CD68 positive (E: CD68 stain, $\times 200$) and p16 negative. Only a few epidermal cells were positive for p16. (F: p16 stain, $\times 100$).

English literature¹. Several explanations for the pathogenesis of VX have been suggested. While some authors regarded the lesion as a benign neoplasm or tumor, others postulated that the lesion results from reactive changes to local trauma and inflammation or occurs in association with impaired lymphatic drainage³. This is further supported by previous reports of VX in the setting of other skin disorders such as Congenital Hemi dysplasia with Ichthyosiform nevus and Limb Defects (CHILD) syndrome, epidermal nevus, and chronic lymphedema⁴. Cutaneous VX, which is not associated with predisposing inflammatory or dystrophic skin disorders, is rare and there are only a few reported cases. Especially, idiopathic VX isolated to the distal extremities is exceptionally rare, and, to our knowledge, there has only been one report of an idiopathic VX on the forearm of an 82-year old male⁴.

There is a controversy as to whether HPV is related to the pathogenesis of VX³. While HPV has been detected in some studies, it was not identified in most studies⁵. In our case, PCR for HPV DNA was negative, and p16 analysis was only positive on rare epithelial cells and negative on the dermal foamy cells, suggesting the absence of HPV infection. Considering the discrepancies between the high incidence of verruca and the extremely rare frequency of VX on distal extremities, a role for HPV in the development of the skin lesions is doubtful.

CONFLICTS OF INTEREST

The authors have nothing to disclose.

FUNDING SOURCE

None.

DATA SHARING STATEMENT

Research data are not shared.

ORCID

Hyun-Min Seo, <https://orcid.org/0000-0002-6897-494X>
 Ju Wang Jang, <https://orcid.org/0000-0001-5885-4250>
 Se Kwang Park, <https://orcid.org/0000-0002-2342-9577>
 You Jin Jung, <https://orcid.org/0000-0002-5336-1868>
 Tae Lim Kim, <https://orcid.org/0000-0002-2639-1973>
 Young Gyun Kim, <https://orcid.org/0000-0003-3488-0811>
 Joung Soo Kim, <https://orcid.org/0000-0002-3014-9645>

REFERENCES

- de Andrade BA, Agostini M, Pires FR, Rumayor A, Carlos R, de Almeida OP, et al. Oral verruciform xanthoma: a clinicopathologic and immunohistochemical study of 20 cases. *J Cutan Pathol* 2015;42:489-495.
- Shafer WG. Verruciform xanthoma. *Oral Surg Oral Med Oral*

Pathol 1971;31:784-789.

- Cumberland L, Dana A, Resh B, Fitzpatrick J, Goldenberg G. Verruciform xanthoma in the setting of cutaneous trauma and chronic inflammation: report of a patient and a brief review of the literature. *J Cutan Pathol* 2010;37:895-900.
- Blankenship DW, Zech L, Mirzabeigi M, Venna S. Verruci-

form xanthoma of the upper-extremity in the absence of chronic skin disease or syndrome: a case report and review of the literature. *J Cutan Pathol* 2013;40:745-752.

- Agarwal-Antal N, Zimmermann J, Scholz T, Noyes RD, Leachman SA. A giant verruciform xanthoma. *J Cutan Pathol* 2002;29:119-124.

<https://doi.org/10.5021/ad.2021.33.1.88>



A Case of the Safety and Efficacy of Guselkumab in Psoriasis with Alcoholic Liver Cirrhosis

Hyun Min Nam, Soo Hyeon Noh, Bo Ra Lim¹, Do Hyeon Kim¹, Seung Yeon Lee¹, Wang Guk Oh²

Department of Dermatology, Design Hospital, Jeonju, ¹Department of Dermatology, Wonkwang University School of Medicine, Iksan, ²Department of Gastroenterology, Design Hospital, Jeonju, Korea

Dear Editor:

Psoriasis is a chronic inflammatory cutaneous disease with a prevalence of approximately 0.5% to 1%. Its treatment varies depending on severity and comorbidities. Owing to concerns of hepatotoxicity, physicians hesitate to prescribe conventional systemic drugs, such as methotrexate and acitretin, to psoriasis patients who have concomitant liver abnormalities. Although biologics have little influence on liver function and are not contraindicated in patients with such abnormalities, few studies specifically address the safety and efficacy of biologics in patients with psoriasis and concomitant liver disease (Table 1)¹⁻³.

A 34-year-old female patient presented at the emergency room of Design Hospital with esophageal varix rupture complicated by alcoholic liver cirrhosis. The patient's Child-Pugh

score was 9 (class B). A dermatological consultation for psoriasis treatment was performed during treatment for alcoholic liver cirrhosis in the intensive care unit (ICU).

The patient showed fine scaly patches and erythematous scaly plaques on her entire body. Results of a skin biopsy of an erythematous scaly plaque on her right thigh were consistent with psoriasis (Fig. 1A, B). She previously received conventional treatments such as cyclosporine and phototherapy in the past, but the lesions had not improved. Topical calcipotriol/betamethasone dipropionate was applied while the patient was in the ICU, but the lesions persisted (Fig. 1C, D). The patient was then transferred to the general ward and prescribed guselkumab, an interleukin (IL)-23 blocker, because other conventional systemic treatments (e.g., methotrexate and acitretin) are contraindicated in patients with liver abnormalities. The patient's psoriatic lesions improved rapidly upon initiation of guselkumab injections. She achieved Psoriasis Area and Severity Index 90 after the third treatment, and she did not have any symptoms or signs suggesting acute exacerbation of liver cirrhosis (Fig. 1E, F). In addition, no opportunistic or mycobacterial infections, spontaneous bacterial peritonitis, or hepatocellular carcinoma were observed during the 20 weeks of observation.

It is known that T helper 17 cells, which are stimulated by IL-23 and produce IL-17 and IL-22, play a critical role in sustaining chronic inflammation in psoriasis⁴. Guselkumab,

Received November 11, 2019, Revised January 20, 2020, Accepted for publication February 1, 2020

Corresponding author: Hyun Min Nam, Department of Dermatology, Design Hospital, 390 Gyeonhwon-ro, Deokjin-gu, Jeonju 54910, Korea. Tel: 82-63-240-2955, Fax: 82-63-240-2019, E-mail: namdan@naver.com
ORCID: <https://orcid.org/0000-0002-0741-9117>

This is an Open Access article distributed under the terms of the Creative Commons Attribution Non-Commercial License (<http://creativecommons.org/licenses/by-nc/4.0>) which permits unrestricted non-commercial use, distribution, and reproduction in any medium, provided the original work is properly cited.

Copyright © The Korean Dermatological Association and The Korean Society for Investigative Dermatology