

A National Consensus Survey for Current Practice in Brain Tumor Management II: Diffuse Midline Glioma and Meningioma

Sung Kwon Kim^{1*} , Hong In Yoon^{2*} , Wan-Soo Yoon^{3*} , Jin Mo Cho^{4*} , Jangsup Moon⁵, Kyung Hwan Kim⁶, Se Hoon Kim⁷, Young Il Kim⁸, Young Zoon Kim⁹, Ho Sung Kim¹⁰, Yun-Sik Dho¹¹, Jae-Sung Park¹², Ji Eun Park¹⁰, Youngbeom Seo¹³, Kyoung Su Sung¹⁴, Jin Ho Song¹⁵, Chan Woo Wee¹⁶, Se-Hoon Lee¹⁷, Do Hoon Lim¹⁸, Jung Ho Im¹⁹, Jong Hee Chang²⁰, Myung-Hoon Han²¹, Je Beom Hong²², Kihwan Hwang²³, Chul-Kee Park^{24†} , Youn Soo Lee^{25†} , Ho-Shin Gwak^{26†} , KSNO Guideline Working Group

Received February 29, 2020

Revised March 2, 2020

Accepted March 16, 2020

Correspondence

Chul-Kee Park

Department of Neurosurgery,
Seoul National University Hospital,
Seoul National University

College of Medicine, 101 Daehak-ro,
Jongno-gu, Seoul 03080, Korea

Tel: +82-2-2072-0347

Fax: +82-504-154-4633

E-mail: nscpark@snu.ac.kr

Youn Soo Lee

Department of Hospital Pathology,
Seoul St. Mary's Hospital,
College of Medicine,

The Catholic University of Korea,
222 Banpo-daero, Seocho-gu,
Seoul 06591, Korea

Tel: +82-2-2258-1626

Fax: +82-2-2258-1628

E-mail: lys9908@catholic.ac.kr

Ho-Shin Gwak

Department of Cancer Control,
Graduate School of Cancer Science
and Policy, National Cancer Center,
323 Ilsan-ro, Ilsandong-gu,
Goyang 10408, Korea

Tel: +82-31-920-1666

Fax: +82-31-920-2798

E-mail: nsghs@ncc.re.kr

*These authors contributed equally to
this work as a first author.

†These authors contributed equally to
this work as a corresponding author.

Background The Guideline Working Group of the Korean Society for Neuro-Oncology (KSNO) conducted a nationwide questionnaire survey for diverse queries faced in the treatment of brain tumors. As part II of the survey, the aim of this study is to evaluate the national patterns of clinical practice for patients with diffuse midline glioma and meningioma.

Methods A web-based survey was sent to all members of the KSNO by email. The survey included 4 questions of diffuse midline glioma and 6 questions of meningioma (including 2 case scenarios). All questions were developed by consensus of the Guideline Working Group.

Results In the survey about diffuse midline glioma, 76% respondents performed histologic confirmation to identify H3K27M mutation on immunohistochemical staining or sequencing methods. For treatment of diffuse midline glioma, respondents preferred concurrent chemoradiotherapy with temozolomide (TMZ) and adjuvant TMZ (63.8%) than radiotherapy alone (34.0%). In the survey about meningioma, respondents prefer wait-and-see policy for the asymptomatic small meningioma without peritumoral edema. However, a greater number of respondents had chosen surgical resection as the first choice for all large size meningiomas without exception, and small size meningiomas with either peritumoral edema or eloquent location. There was no single opinion with major consensus on long-term follow-up plans for asymptomatic meningioma with observation policy. As many as 68.1% of respondents answered that they would not add any adjuvant therapies for World Health Organization grade II meningiomas if the tumor was totally resected including dura.

Conclusion The survey demonstrates the prevailing clinical practice patterns for patients with diffuse midline glioma and meningioma among members of the KSNO. This information provides a point of reference for establishing a practical guideline in the management of diffuse midline glioma and meningioma.

Key Words Korean Society for Neuro-Oncology; Practice patterns; Brain tumors; Diffuse midline glioma; Meningioma, Guideline Working Group.

INTRODUCTION

The Guideline Working Group of Korean Society for Neuro-Oncology (KSNO) conducted a nationwide questionnaire survey on the clinical practice about several topics of brain tumor. The intent of this survey study is described in the previous article of the series in this issue. As part II of the survey, this study deals with practical decisions of specific brain tumors, such as diffuse midline glioma and meningioma.

Diffuse midline glioma is known to be one of dismal high-grade pediatric and adult brain tumors involving midline structures of the central nervous system. In general, most of these tumors are inoperable because of challenging anatomic location, which makes the prognosis even worse to the overall survival no more than 12 months [1-3]. There were few randomized controlled clinical trials to establish the evidence-based standard treatment protocol. Despite several therapeutic options including radiotherapy, chemotherapy and/or surgery, no superior treatment modalities could be recommended alone or in combination [4-6]. In addition, 2016 revised World Health Organization (WHO) classification recently redefined this type of tumors as diffuse midline glioma, H3K27M mutant, a new diagnostic entity based on its unique genetic signature [7]. So, evidence-based and consensus guideline from diagnosis to treatment for this entity is required.

Meningiomas are the most common primary brain tumors. The data from Korean Cancer Registration Statistics Program in 2013 shows that the incidence of meningioma was 37.3% of newly diagnosed brain tumors with median age at diagnosis of 61 years in Korea [8]. Recently, the incidence of meningioma is continuously increasing due to the discovery of incidental meningiomas from expanded inclusion of neuroimaging in routine health check-ups [9-11]. However, the management strategy for incidental meningiomas is controversial among neurosurgeons [12-16]. Meningiomas were histologically classified into three grades by WHO definition from grade I to III. The definition of atypical meningioma (WHO grade II) from 2016 revised WHO classification includes histologically confirmed brain invasion [7]. Contrast to grade I and grade III meningiomas, the adjuvant treatment after surgical resection for grade II meningiomas remains debating issue among physicians. Some studies reported that adjuvant radiotherapy after neurosurgical resection decreased the recurrence rates and improved overall survival [17,18]. However, there are also other studies describing no benefit in recurrence and survival of adjuvant radiotherapy at the cost of its risk of radiation-induced toxicity [19,20].

The aim of this study is to evaluate the tendencies of clinical practice for patients with diffuse midline glioma and meningioma from the nationwide survey in Korea.

MATERIALS AND METHODS

The details of the study design, outline, and implementation are described in the previous article of the series in this issue. Here, the questionnaires about diffuse midline glioma (4 questions) and meningioma (6 questions) were structured around existing controversies regarding real clinical management in patients (Appendix).

Regarding the diffuse midline glioma, the questionnaires were focused on the diagnosis and treatment options in clinical practices. The dose and target of radiotherapy that considered as the significant treatment option were also investigated.

The questionnaires of meningioma included 2 case scenarios asking the management options for the patients with asymptomatic meningioma with different age and radiological finding of the tumor. Other questionnaire consisted of follow-up MRI schedules for asymptomatic meningioma, adjuvant treatment of WHO grade II meningioma according to the extent of surgical resection, adjuvant radiation dose of WHO grade II meningioma after surgical resection, and experience of medical treatment for patients with meningioma.

RESULTS

Diffuse midline glioma

About three quarters of the respondents performed the diagnostic confirmation to identify the H3K27M mutation (n=36, 72%) by the immunohistochemical (IHC) staining or the pathognomonic K27M mutation (n=20, 40%) in the histone 3.3 (H3.3) gene H3F3A, histone 3.2 (H3.2) gene HIST2H3C, and histone 3.1 (H3.1) genes HIST1H3B/C using sequencing methods. Twelve respondents (24%) diagnosed the diffuse midline glioma by using only radiologic findings without detection of H3K27M mutation.

For treatment of diffuse midline glioma, 30 of 47 (63.8%) respondents performed the concurrent chemoradiotherapy with temozolomide (TMZ) and adjuvant TMZ, and 16 respondents (34.0%) treated the patient with radiotherapy alone. One respondent reported that if surgically total resection was performed, no further treatment was given. For radiation dose, 42 of 45 (93.4%) respondents mostly delivered 54–60 Gy in 27–30 fractions. Two (4.4%) respondents delivered 45 Gy in 25 fractions, and one (2.2%) respondent stated in free text response that the radiation dose was decided according to location of lesions (i.e., 54 Gy in 30 fractions for brainstem lesion and 60 Gy in 30 fractions for the others). The target coverage of radiotherapy showed that mainly focused on the high signal intensity lesion of T2-weighted MRI (Fig. 1).

Meningioma

We asked the decision on initial management plan for incidentally found asymptomatic meningiomas based on case scenarios. The preference of treatment modality for a 45-year-old woman with small (3 cm in diameter) meningioma was quite variable according to tumor location and presence of peritumoral edema (Fig. 2). For frontal convexity meningioma without peritumoral edema, respondents preferred observa-

tion with serial MRI follow-up, but for patients with peritumoral edema, surgical resection was preferred. For patients with parasagittal meningioma around the motor cortex, respondents preferred the surgical resection regardless of peritumoral edema. If the tumor was located at skull base, the decision was quite similar to that of frontal convexity tumor, but the role of radiosurgery was emphasized all the more. However, the majority of respondents opted for surgical resection for a 70-year-old woman with meningioma with larger tumor (6 cm in diameter) regardless of tumor location and peritumoral edema (Fig. 2). The responses of case scenarios showed that the radiologic findings, such as tumor location, tumor size, and peritumoral edema, were considered more important factors than age of patient in determining treatment strategies of asymptomatic meningioma.

Fig. 3 shows responses about radiological follow-up plans for patients with asymptomatic meningioma by each respondent. Among 45 respondents who answered to have follow-up plans, 12 respondents (26.7%) had no long-term plans for radiological follow-up after a year if the tumor is stable. We could find that every respondent has different ideas on follow-up plans for the meningiomas with observation policy. There was no single opinion with major consensus on long-term follow-up plans.

Among 47 respondents, 32 (68.1%) respondents choose observation with serial MRI follow-up without adjuvant treatment for patient with WHO grade II meningioma receiving

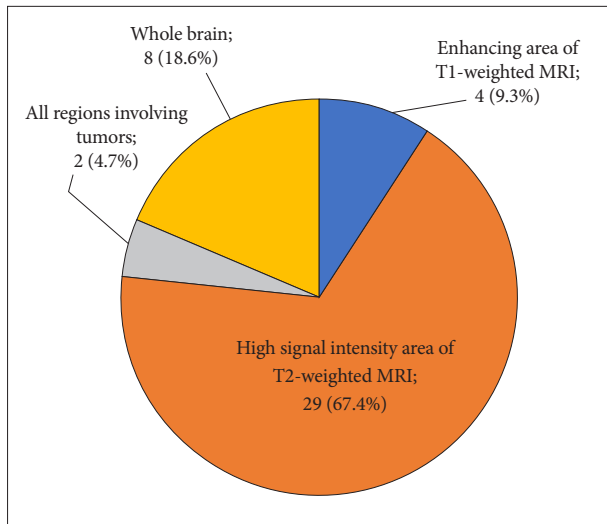


Fig. 1. Pie chart demonstrating target of radiotherapy. Note that over 65% of respondents mainly performed radiotherapy focused on the high signal intensity lesion of T2-weighted MRI.

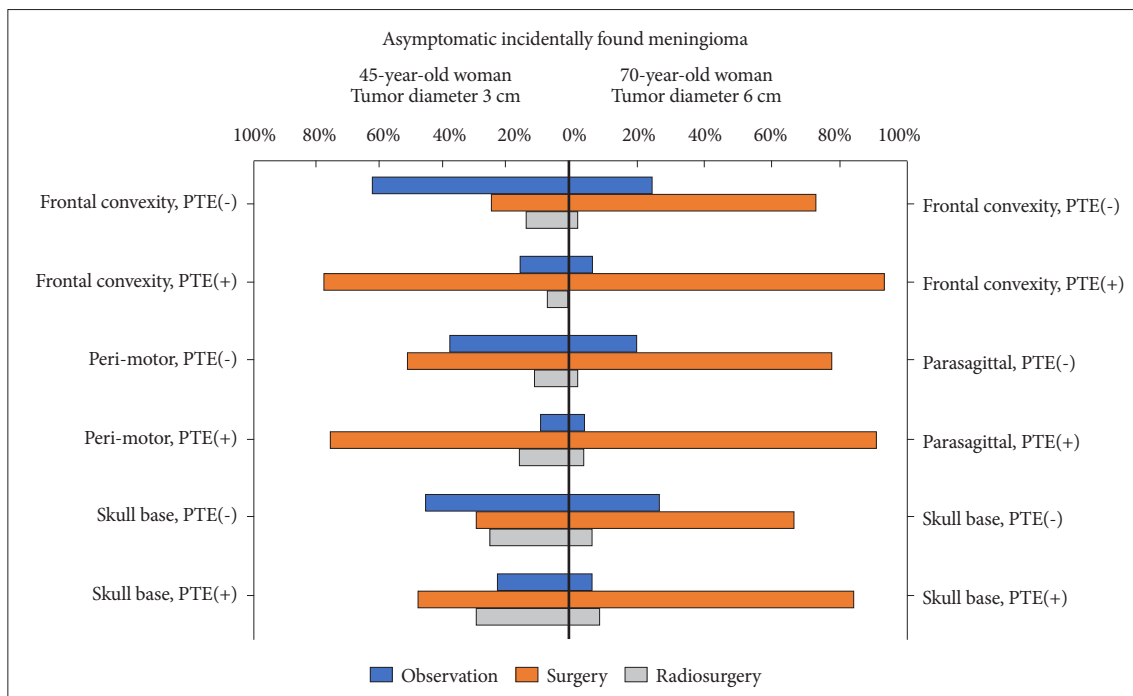


Fig. 2. Treatment modality preference of respondents for a 45-year-old woman with 3-cm-sized asymptomatic meningioma (left), and 70-year-old woman with 6-cm-sized asymptomatic meningioma (right) according to tumor location and presence of peritumoral edema (PTE).

complete tumor resection with removal of affected dura, while 14 (29.8%) respondents performed the radiotherapy and one (2.1%) respondent performed the radiosurgery. For

patients with WHO grade II meningioma receiving complete tumor resection without removal of affected dura, 31 of 47 (66.0%) respondents performed the radiotherapy, and four




Fig. 3. Responses about radiological follow-up plans for patients with asymptomatic meningioma by each respondent. Colored cells are time points to study. Responses with blue cells are answers with any consensus for long-term follow-up plans, while those with grey cells are with no plan for long-term follow ups after a year.

(8.5%) respondents performed the radiosurgery. Twelve (25.5%) respondents choose observation without adjuvant treatment in this setting. For patient with WHO grade II meningioma with residual tumor after surgery, respondents choose the next plan as following: radiotherapy (n=34, 72.4%), radiosurgery (n=12, 25.5%), and observation without adjuvant treatment (n=1, 2.1%). Regarding the radiation dose given after surgical resection, 28 of 42 (66.7%) respondents delivered 54.0 Gy after surgical resection for WHO grade II meningioma. Ten (23.8%) respondents delivered 60.0 Gy and three (7.0%) delivered 58.8 Gy. In free text responses, one respondent stated that the radiation dose was decided according to whether performing complete tumor resection or not. Twelve respondents described their experiences of a medical treatment trial for patients with meningioma. The prescribed medications were the following: hydroxyurea (n=11); nimustine plus cisplatin (n=1); nitrosourea (n=1).

DISCUSSION

The characteristic findings of diffuse midline glioma are known as K27M mutations in the histone H3 gene H3F3A, or less commonly in the related HIST1H3B gene, a diffuse growth pattern, and a midline location of brain (e.g., thalamus, brain stem, and spinal cord) [7,21,22]. Because surgical resection is often difficult due to the location of the tumor, proper imaging and biopsy are required for accurate differential diagnosis. In this survey report, three-quarters of respondents consider that histologic confirmation of the H3K27M mutation is more important for diagnosis, based on the 2016 revised WHO classification [7]. This is in line with the diagnosis of diffuse midline glioma in the European Association for Neuro-Oncology guideline that recommends IHC of histone H3K27M mutation which characterizes diffuse midline glioma, histone H3K27M-mutant [23]. Therefore, if possible, the histologic confirmation of the H3K27M mutation would be considered as a diagnostic criterion.

Current treatment strategy for diffuse midline glioma is that conventional radiotherapy is the important therapeutic option due to the limitation of radical resection [23,24]. The role of chemotherapy remains unclear. Several types of chemotherapeutic regimens such as carboplatin, etoposide, vincristine and TMZ have shown no evidence of survival improvement [25-29]. Some physicians have used chemotherapy with or after radiotherapy following the standards of care for gliomas of the same WHO grade in other anatomical locations. EANO guideline recommends radiotherapy alone or TMZ plus radiotherapy followed by TMZ as first line treatment [23]. Our results also seem to reflect this situation in the real world. The standard radiation dose is 54–60 Gy with a daily conventional frac-

tionation of 1.8–2.0 Gy [24]. Some studies for the altered fractionation schemes including the hypofractionation with shorter treatment duration or hyperfractionation with dose-escalation have shown no distinct survival benefit [1-3,5,30,31]. To overcome the limitation of few therapeutic options, there is a continuing need for new clinical trials to find a new therapeutic strategy and basic research to increase insight to diffuse midline glioma.

This nationwide survey study reflects various opinions on the treatment of asymptomatic meningioma and postoperative treatment of WHO grade II meningioma. There have been many reports about the strategy for asymptomatic meningiomas. The prospective study dealing with the natural history of incidental meningioma reported that asymptomatic tumors can be safely managed by imaging follow-up, although 75% of meningioma had slowly increased on observation period. It was also reported that the growth rate was significantly correlated with the tumor size and the age of patients [32]. Kim et al. [33] reported the comparison result of Gamma Knife surgery (GKS) versus observation in 354 patients with asymptomatic meningiomas. The clinical and radiologic progression-free survival rates at 10 years were 92.9% and 88.5% in GKS group, while those were 42.7% and 7.9% in observation group. Clinical progression was correlated with young age, absence of calcification, peritumoral edema, and high T2 signal intensity in the observation group [33]. In another report, 603 patients with asymptomatic meningiomas were respectively analyzed about the natural course and surgical outcome [16]. A total of 63% of asymptomatic meningiomas did not grow in follow up for longer than 5 years, and only 6% of all patients with these lesions showed symptoms during the observation period. Among the 213 patients underwent the neurosurgical resection, the morbidity rate was 4.4% in patients younger than 70 years of age and 9.4% in those 70 years of age or older, and those were lower compared with those in symptomatic patients [16]. Zeng et al. [34] reported that Simpson I resection rate was significantly high in the cerebral hemispheric tumor compared with skull base lesion (95.2% vs. 66.7%) in the patient with asymptomatic meningiomas. The surgical-related complication rate was 13.6%, which was lower than the rate of 21.7% in the symptomatic patients, and younger patients less than 60 years showed better outcome at 1 year after the operation. In the current survey, the respondents rather choose an aggressive treatment of neurosurgical resection or radiosurgery except for the situations with middle-aged patients having 3-cm-sized frontal convexity without peritumoral edema. The size of tumors rather than age and the peritumoral edema tended to be the determining factors whether to treat or not. Additionally, the neurosurgical resection was more preferred compared to radiosurgery as the treatment strategy

in patients with asymptomatic meningiomas.

There have been several controversies in management of WHO grade II meningiomas, including the significance of extent of surgical resection, the postoperative radiotherapy, and chemotherapy. In the conclusion of previous review on these issues in non-benign meningiomas, gross total resection could improve outcome and should be attempted in grade II meningiomas [35]. They also reported that postoperative radiotherapy following gross total resection did not improve patient outcome of grade II meningioma, but radiotherapy improves outcome following subtotal tumor resection of grade II meningioma. Additionally, no drug therapy was not effective to improve outcome in non-benign meningiomas [35]. Sun et al. [36] reported the treatment algorithm based on the investigation of previous studies in WHO grade II meningiomas. They recommended that adjuvant radiotherapy could be considered when tumors showed high risk features, such as brain invasion, mitotic index ≥ 8 , and sheeting, although gross total resection was performed. And stereotactic radiosurgery as well as radiotherapy could be suitable in the patients after subtotal resection [36]. In this study, there was the opposite opinion about the necessity of postoperative radiotherapy according to the presence of affected dura even if gross total resection was performed. However, respondents concurred with the previous results about the management following subtotal resection.

As with any online survey, the major limitation of this study is response bias that respondents might be influenced by the pressure to follow the published guidelines, especially in the survey of diffuse midline glioma because of a rare disease entity. Additionally, the relatively low response rate may give rise to sampling bias interfering with the valuable interpretation of several questions.

In conclusion, the survey demonstrates the variation and similarity of clinical practice for patients with diffuse midline glioma and meningioma among members of the KSNO. It is important to reduce the variation for establishing the guideline based on the best available evidence.

Conflicts of Interest

The authors have no potential conflicts of interest.

Acknowledgments

None

ORCID iDs

Chul-Kee Park  <https://orcid.org/0000-0002-2350-9876>
 Youn Soo Lee  <https://orcid.org/0000-0002-1653-6315>
 Ho-Shin Gwak  <https://orcid.org/0000-0001-7175-4553>
 Sung Kwon Kim  <https://orcid.org/0000-0002-7074-9290>
 Hong In Yoon  <https://orcid.org/0000-0002-2106-6856>
 Wan-Soo Yoon  <https://orcid.org/0000-0002-2504-4734>
 Jin Mo Cho  <https://orcid.org/0000-0002-1192-8993>

Author Affiliations

¹Department of Neurosurgery, Gyeongsang National University Changwon Hospital, Gyeongsang National University School of Medicine, Changwon, Korea; ²Department of Radiation Oncology, Yonsei Cancer Center, Yonsei University College of Medicine, Seoul, Korea; ³Department of Neurosurgery, Incheon St. Mary's Hospital, College of Medicine, The Catholic University of Korea, Incheon, Korea; ⁴Department of Neurosurgery, International St. Mary's Hospital, Catholic Kwandong University, Incheon, Korea; ⁵Department of Neurology, Rare Disease Center, Seoul National University Hospital, Seoul National University College of Medicine, Seoul, Korea; ⁶Department of Neurosurgery, Chungnam National University Hospital, Chungnam National University School of Medicine, Daejeon, Korea; ⁷Department of Pathology, Severance Hospital, Yonsei University College of Medicine, Seoul, Korea; ⁸Department of Neurosurgery, St. Vincent's Hospital, College of Medicine, The Catholic University of Korea, Suwon, Korea; ⁹Division of Neurooncology and Department of Neurosurgery, Samsung Changwon Hospital, Sungkyunkwan University School of Medicine, Changwon, Korea; ¹⁰Department of Radiology and Research Institute of Radiology, Asan Medical Center, University of Ulsan College of Medicine, Seoul, Korea; ¹¹Department of Neurosurgery, Chungbuk National University Hospital, Chungbuk National University College of Medicine, Cheongju, Korea; ¹²Department of Neurosurgery, Seoul St. Mary's Hospital, College of Medicine, The Catholic University of Korea, Seoul, Korea; ¹³Department of Neurosurgery, Yeungnam University Hospital, Yeungnam University College of Medicine, Daegu, Korea; ¹⁴Department of Neurosurgery, Dong-A University Hospital, Dong-A University College of Medicine, Busan, Korea; ¹⁵Departments of Radiation Oncology, Seoul St. Mary's Hospital, College of Medicine, The Catholic University of Korea, Seoul, Korea; ¹⁶Department of Radiation Oncology, SMG-SNU Boramae Medical Center, Seoul National University College of Medicine, Seoul, Korea; ¹⁷Division of Hematology/Oncology, Department of Medicine, Samsung Medical Center, Sungkyunkwan University School of Medicine, Seoul, Korea; ¹⁸Department of Radiation Oncology, Samsung Medical Center, Sungkyunkwan University School of Medicine, Seoul, Korea; ¹⁹Department of Radiation Oncology, CHA Bundang Medical Center, CHA University School of Medicine, Seongnam, Korea; ²⁰Department of Neurosurgery, Severance Hospital, Yonsei University College of Medicine, Seoul, Korea; ²¹Department of Neurosurgery, Hanyang University Guri Hospital, Hanyang University College of Medicine, Guri, Korea; ²²Department of Neurosurgery, Kangbuk Samsung Hospital, Sungkyunkwan University School of Medicine, Seoul, Korea; ²³Department of Neurosurgery, Seoul National University Bundang Hospital, Seoul National University College of Medicine, Seongnam, Korea; ²⁴Department of Neurosurgery, Seoul National University Hospital, Seoul National University College of Medicine, Seoul, Korea; ²⁵Department of Hospital Pathology, Seoul St. Mary's Hospital, College of Medicine, The Catholic University of Korea, Seoul, Korea; ²⁶Department of Cancer Control, Graduate School of Cancer Science and Policy, National Cancer Center, Goyang, Korea

REFERENCES

- Freeman CR, Krischer JP, Sanford RA, et al. Final results of a study of escalating doses of hyperfractionated radiotherapy in brain stem tumors in children: a Pediatric Oncology Group study. *Int J Radiat Oncol Biol Phys* 1993;27:197-206.
- Janssens GO, Jansen MH, Lauwers SJ, et al. Hypofractionation vs conventional radiation therapy for newly diagnosed diffuse intrinsic pontine glioma: a matched-cohort analysis. *Int J Radiat Oncol Biol Phys* 2013; 85:315-20.
- Lewis J, Lucraft H, Gholkar A. UKCCSG study of accelerated radiotherapy for pediatric brain stem gliomas. United Kingdom Childhood Cancer Study Group. *Int J Radiat Oncol Biol Phys* 1997;38:925-9.
- Mandell LR, Kadota R, Freeman C, et al. There is no role for hyperfractionated radiotherapy in the management of children with newly diagnosed diffuse intrinsic brainstem tumors: results of a Pediatric Oncology Group phase III trial comparing conventional vs. hyperfractionated

- radiotherapy. *Int J Radiat Oncol Biol Phys* 1999;43:959-64.
5. Zaghoul MS, Eldebawy E, Ahmed S, et al. Hypofractionated conformal radiotherapy for pediatric diffuse intrinsic pontine glioma (DIPG): a randomized controlled trial. *Radiother Oncol* 2014;111:35-40.
 6. Marcus KJ, Dutton SC, Barnes P, et al. A phase I trial of etanidazole and hyperfractionated radiotherapy in children with diffuse brainstem glioma. *Int J Radiat Oncol Biol Phys* 2003;55:1182-5.
 7. Louis DN, Perry A, Reifenberger G, et al. The 2016 World Health Organization Classification of Tumors of the Central Nervous System: a summary. *Acta Neuropathol* 2016;131:803-20.
 8. Dho YS, Jung KW, Ha J, et al. An updated nationwide epidemiology of primary brain tumors in Republic of Korea, 2013. *Brain Tumor Res Treat* 2017;5:16-23.
 9. Chamoun R, Krisht KM, Couldwell WT. Incidental meningiomas. *Neurosurg Focus* 2011;31:E19.
 10. Niiro M, Yatsushiro K, Nakamura K, Kawahara Y, Kuratsu J. Natural history of elderly patients with asymptomatic meningiomas. *J Neurol Neurosurg Psychiatry* 2000;68:25-8.
 11. Onizuka M, Suyama K, Shibayama A, Hiura T, Horie N, Miyazaki H. Asymptomatic brain tumor detected at brain check-up. *Neurol Med Chir (Tokyo)* 2001;41:431-4; discussion 435.
 12. Jo KW, Kim CH, Kong DS, et al. Treatment modalities and outcomes for asymptomatic meningiomas. *Acta Neurochir (Wien)* 2011;153:62-7; discussion 67.
 13. Herscovici Z, Rappaport Z, Sulkes J, Danaila L, Rubin G. Natural history of conservatively treated meningiomas. *Neurology* 2004;63:1133-4.
 14. Nabika S, Kiya K, Satoh H, Mizoue T, Oshita J, Kondo H. [Strategy for the treatment of incidental meningiomas]. *No Shinkei Geka* 2007;35:27-32.
 15. Sonoda Y, Sakurada K, Saino M, Kondo R, Sato S, Kayama T. Multimodal strategy for managing meningiomas in the elderly. *Acta Neurochir (Wien)* 2005;147:131-6; discussion 136.
 16. Yano S, Kuratsu J, Kumamoto Brain Tumor Research Group. Indications for surgery in patients with asymptomatic meningiomas based on an extensive experience. *J Neurosurg* 2006;105:538-43.
 17. Aghi MK, Carter BS, Cosgrove GR, et al. Long-term recurrence rates of atypical meningiomas after gross total resection with or without postoperative adjuvant radiation. *Neurosurgery* 2009;64:56-60; discussion 60.
 18. Park HJ, Kang HC, Kim IH, et al. The role of adjuvant radiotherapy in atypical meningioma. *J Neurooncol* 2013;115:241-7.
 19. Graffeo CS, Leeper HE, Perry A, et al. Revisiting adjuvant radiotherapy after gross total resection of World Health Organization grade II meningioma. *World Neurosurg* 2017;103:655-63.
 20. Champeaux C, Houston D, Dunn L. Atypical meningioma. A study on recurrence and disease-specific survival. *Neurochirurgie* 2017;63:273-81.
 21. Wu G, Broniscer A, McEachron TA. Somatic histone H3 alterations in pediatric diffuse intrinsic pontine gliomas and non-brainstem glioblastomas. *Nat Genet* 2012;44:251-3.
 22. Khuong-Quang DA, Buczkowicz P, Rakopoulos P, et al. K27M mutation in histone H3.3 defines clinically and biologically distinct subgroups of pediatric diffuse intrinsic pontine gliomas. *Acta Neuropathol* 2012;124:439-47.
 23. Weller M, van den Bent M, Tonn JC, et al. European Association for Neuro-Oncology (EANO) guideline on the diagnosis and treatment of adult astrocytic and oligodendroglial gliomas. *Lancet Oncol* 2017;18:e315-29.
 24. Cohen KJ, Jabado N, Grill J. Diffuse intrinsic pontine gliomas-current management and new biologic insights. Is there a glimmer of hope? *Neuro Oncol* 2017;19:1025-34.
 25. Packer RJ, Krailo M, Mehta M, et al. A phase I study of concurrent RMP-7 and carboplatin with radiation therapy for children with newly diagnosed brainstem gliomas. *Cancer* 2005;104:1968-74.
 26. Walter AW, Gajjar A, Ochs JS, et al. Carboplatin and etoposide with hyperfractionated radiotherapy in children with newly diagnosed diffuse pontine gliomas: a phase I/II study. *Med Pediatr Oncol* 1998;30:28-33.
 27. Korones DN, Fisher PG, Kretschmar C, et al. Treatment of children with diffuse intrinsic brain stem glioma with radiotherapy, vincristine and oral VP-16: a Children's Oncology Group phase II study. *Pediatr Blood Cancer* 2008;50:227-30.
 28. Jalali R, Raut N, Arora B, et al. Prospective evaluation of radiotherapy with concurrent and adjuvant temozolomide in children with newly diagnosed diffuse intrinsic pontine glioma. *Int J Radiat Oncol Biol Phys* 2010;77:113-8.
 29. Bailey S, Howman A, Wheatley K, et al. Diffuse intrinsic pontine glioma treated with prolonged temozolomide and radiotherapy--results of a United Kingdom phase II trial (CNS 2007 04). *Eur J Cancer* 2013;49:3856-62.
 30. Janssens GO, Gidding CE, Van Lindert EJ, et al. The role of hypofractionation radiotherapy for diffuse intrinsic brainstem glioma in children: a pilot study. *Int J Radiat Oncol Biol Phys* 2009;73:722-6.
 31. Kretschmar CS, Tarbell NJ, Barnes PD, Krischer JP, Burger PC, Kun L. Pre-irradiation chemotherapy and hyperfractionated radiation therapy 66 Gy for children with brain stem tumors. A phase II study of the Pediatric Oncology Group, Protocol 8833. *Cancer* 1993;72:1404-13.
 32. Behbahani M, Skeie GO, Eide GE, Hausken A, Lund-Johansen M, Skeie BS. A prospective study of the natural history of incidental meningioma--Hold your horses! *Neurooncol Pract* 2019;6:438-50.
 33. Kim KH, Kang SJ, Choi JW, et al. Clinical and radiological outcomes of proactive Gamma Knife surgery for asymptomatic meningiomas compared with the natural course without intervention. *J Neurosurg* 2019;130:1740-9.
 34. Zeng L, Wang L, Ye F, Chen J, Lei T, Chen J. Clinical characteristics of patients with asymptomatic intracranial meningiomas and results of their surgical management. *Neurosurg Rev* 2015;38:481-8; discussion 488.
 35. Paldor I, Awad M, Sufaro YZ, Kaye AH, Shoshan Y. Review of controversies in management of non-benign meningioma. *J Clin Neurosci* 2016;31:37-46.
 36. Sun SQ, Hawasli AH, Huang J, Chicoine MR, Kim AH. An evidence-based treatment algorithm for the management of WHO grade II and III meningiomas. *Neurosurg Focus* 2015;38:E3.

Appendix

Diffuse midline glioma

1. How is diffuse midline glioma diagnosed in your institution? (Choose all that apply)
 - By using only radiologic finding
 - By identifying the H3K27M mutation on the IHC staining
 - By identifying the H3F3A, HIST1H3B, HIST1H3C mutation on the sequencing method
2. How do you treat diffuse midline glioma after diagnosis?
 - Radiotherapy only
 - Concurrent chemoradiotherapy with TMZ and adjuvant TMZ (standard treatment protocol of glioblastoma)
3. What is the dose fractionation schedule of radiotherapy for diffuse midline glioma in your institution? (Skip the question if you don't perform the radiotherapy for diffuse midline glioma)
 - 45 Gy/25 fractions
 - 54 Gy/27 fractions
 - 60 Gy/30 fractions
 - Other
4. What is the target coverage of radiotherapy for diffuse midline glioma in your institution? (Skip the question if you don't perform the radiotherapy for diffuse midline glioma)
 - Enhancing area of T1-weighted MRI
 - High signal intensity area of T2-weighted MRI
 - All regions involving tumors
 - Whole brain

Meningioma

1. For a 45-year-old female with incidentally found meningioma of 3 cm in size, what treatment would you recommend for a patient according to tumor location and peritumoral edema (+presence, -absence)?
 - a) Frontal convexity, peritumoral edema (-)
 - Observation with serial MRI follow-up
 - Surgical resection
 - Radiosurgery
 - b) Frontal convexity, peritumoral edema (+)
 - Observation with serial MRI follow-up
 - Surgical resection
 - Radiosurgery
 - c) Motor cortex/parasagittal, peritumoral edema (-)
 - Observation with serial MRI follow-up
 - Surgical resection
 - Radiosurgery
 - d) Motor cortex/parasagittal, peritumoral edema (+)
 - Observation with serial MRI follow-up
 - Surgical resection
 - Radiosurgery
 - e) Skull base, peritumoral edema (-)
 - Observation with serial MRI follow-up
 - Surgical resection
 - Radiosurgery
 - f) Skull base, peritumoral edema (+)
 - Observation with serial MRI follow-up
 - Surgical resection
 - Radiosurgery

2. For a 70-year-old female with incidentally found meningioma of 6 cm in size, what treatment would you recommend for a patient according to tumor location and peritumoral edema (+presence, -absence)?
- a) Frontal convexity, peritumoral edema (-)
- Observation with serial MRI follow-up
 - Surgical resection
 - Radiosurgery
- b) Frontal convexity, peritumoral edema (+)
- Observation with serial MRI follow-up
 - Surgical resection
 - Radiosurgery
- c) Motor cortex/parasagittal, peritumoral edema (-)
- Observation with serial MRI follow-up
 - Surgical resection
 - Radiosurgery
- d) Motor cortex/parasagittal, peritumoral edema (+)
- Observation with serial MRI follow-up
 - Surgical resection
 - Radiosurgery
- e) Skull base, peritumoral edema (-)
- Observation with serial MRI follow-up
 - Surgical resection
 - Radiosurgery
- f) Skull base, peritumoral edema (+)
- Observation with serial MRI follow-up
 - Surgical resection
 - Radiosurgery
3. What is your favorite follow-up MRI schedule of asymptomatic meningioma? (Choose all the time that you prefer to perform MRI)
- 6 months, 1 year, 2 years, 3 years, 4 years, 5 years,
 6 years, 7 years, 8 years, 9 years, 10 years
4. What adjuvant treatment would you recommend for patients with WHO grade II meningioma according to the extent of surgical resection?
- a) Complete tumor resection with removal of affected dura
- Close observation with serial MRI follow-up
 - Radiosurgery
 - Radiotherapy
- b) Complete tumor resection without removal of affected dura
- Close observation with serial MRI follow-up
 - Radiosurgery
 - Radiotherapy
- c) Presence of residual tumor
- Close observation with serial MRI follow-up
 - Radiosurgery
 - Radiotherapy
5. What is the radiation dose of adjuvant radiotherapy after surgical resection for patients with WHO grade II meningioma in your institution?
- 54 Gy 58.8 Gy 60 Gy Other
6. Have you ever tried chemotherapy for patients with WHO grade II meningioma? If you have, describe the regimen of chemotherapy.
- No
 Yes ()