

McGrath[®] videolaryngoscopy in an awake patient with a huge dangling vocal papilloma: a case report

Journal of International Medical Research

2019, Vol. 47(7) 3416–3420

© The Author(s) 2019

Article reuse guidelines:

sagepub.com/journals-permissions

DOI: 10.1177/0300060519851355

journals.sagepub.com/home/imrSung Min Lee  and Hyunyoung Lim 

Abstract

A 68-year-old patient with a huge dangling vocal papilloma was admitted for surgical resection. Preoperative data regarding the patient's mass-related symptoms, endoscopic view, and radiological evaluation indicated that airway management would be difficult. Fiberoptic intubation has been considered an ideal primary approach to managing problematic airways, but blind advancement of the endotracheal tube without a clear, consistent view of the mass presents a significant threat to patient safety. This report describes how safe intubation was accomplished while the patient was awake using laryngeal nerve blocks and a McGrath[®] videolaryngoscope.

Keywords

Awake intubation, difficult airway, McGrath, vocal papilloma, videolaryngoscopy, laryngeal nerve block

Date received: 17 September 2018; accepted: 26 April 2019

Introduction

A huge dangling mass on the vocal cords, usually seen during otolaryngologic surgery, can present a great challenge to anesthesiologists because of issues ranging from safe ventilation to precise intubation.^{1–3} Many techniques and devices have been developed during the past several decades as alternatives to conventional direct laryngoscopy, one of which is awake intubation.^{1,4} The use of a flexible fiberoptic bronchoscope and various videolaryngoscopes may also help to better visualize the airway.^{1,5–7}

The following case report describes a patient with a long history of coughing and dyspnea caused by a large recurrent

Department of Anesthesiology and Pain Medicine,
Hanyang University Medical Center, Hanyang University
College of Medicine, Seoul, Korea

Corresponding author:

Hyunyoung Lim, Department of Anesthesiology and Pain
Medicine, Hanyang University Medical Center, Hanyang
University College of Medicine, 222-1, Wangsimni-ro,
Seongdong-gu, Seoul 04763, Korea.
Email: zemma0512@gmail.com



vocal papilloma. The patient consented to awake intubation, which was performed using a McGrath[®] videolaryngoscope (Aircraft Medical Ltd., Edinburgh, UK). This report describes how we prepared for and managed this case of difficult intubation.

Case report

A 68-year-old woman (166 cm, 67 kg) with chief complaints of hoarseness, frequent coughing, and mild orthopnea was diagnosed with a recurrent vocal papilloma. The patient provided written informed consent for publication of her information and images. Approval by an ethics committee

was unnecessary because of the nature of this study (case report). The tumor had been first recognized 16 years ago, and she underwent two surgical resections in 1996 and 2002. In 2002, a 6.0-mm internal diameter cuffed oral preformed tube was used to intubate the patient without problems. At the current presentation, however, the recurrent mass had grown to approximately 1 × 2 cm, which was larger than that during the previous surgeries. The pedunculated papilloma seemed to originate in the left vocal cord and extended to the subglottis, occupying most of the glottic airway (Figure 1). During the preoperative visit, the patient's airway was classified as Mallampati class 2 and her neck extension

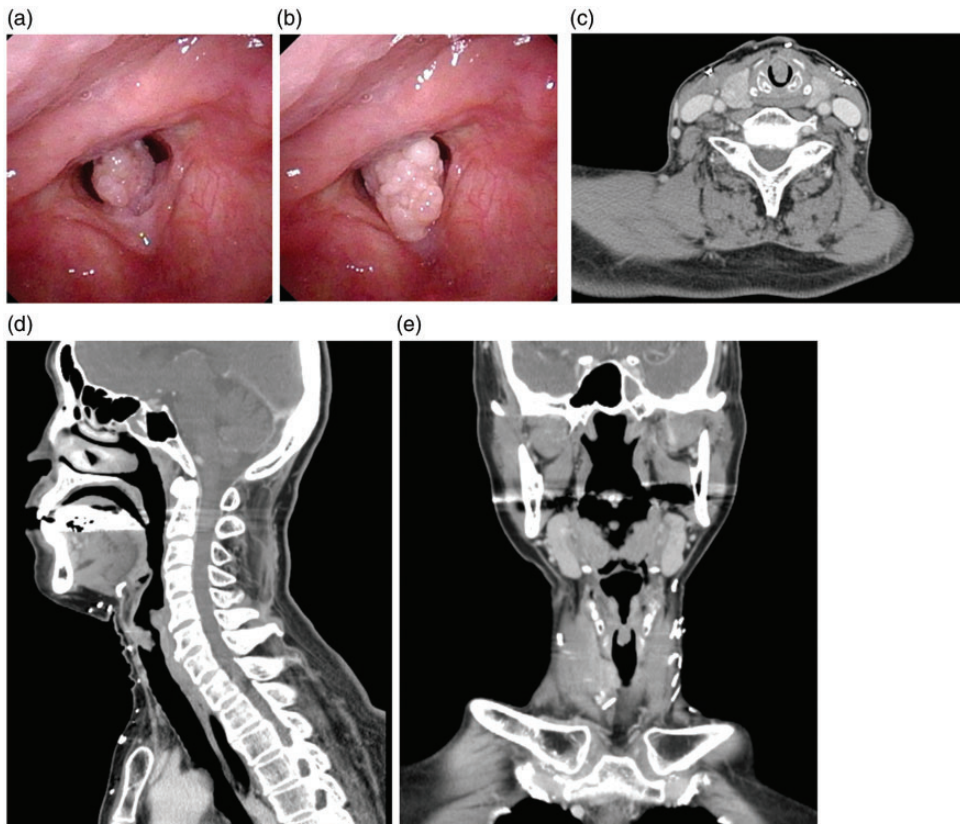


Figure 1. (a, b) Direct endoscopic view of the papilloma. (c–e) Axial, sagittal, and coronal views of the airway, which is nearly obstructed by the mass.

was slightly stiff. Her lung sounds were clear, but she constantly coughed while sitting upright and expressed that her breathing was uncomfortable while in the supine position. The anesthetic plan regarding the use of a flexible fiberoptic bronchoscope and McGrath[®] videolaryngoscope and the possibility of awake intubation were explained to the patient. The patient understood and agreed to undergo the procedure.

The patient was premedicated with intramuscular injections of 0.5 mg atropine and 1.5 mg midazolam. On arrival in the operating room, the patient was sufficiently pre-oxygenated and subject to monitoring. Simple bipolar electrocardiographic monitoring and a finger pulse oximeter were applied, while noninvasive blood pressure was measured with a cuff on her upper arm. Her body temperature was monitored with an axillary temperature probe. In the operating room, the patient was still intermittently coughing and seemed to struggle with secretions. To stabilize the patient and obtain a better view of the airway, an intravenous bolus injection of 0.2 mg glycopyrrolate and an infusion of remifentanyl were given. A commercial 10% lidocaine oral spray was applied for oropharyngeal topical anesthesia. Right and left superior laryngeal nerve blocks and translaryngeal nerve blocks for the recurrent laryngeal nerve were performed, each with an injection of 2 mL of 2% lidocaine.^{5,7,10} Supplemental oxygen was administered by

a nasal cannula throughout the nerve block procedure.

To visualize the actual mass and plan the most appropriate intubation technique, a flexible fiberoptic bronchoscope (LF-GP; Olympus, Tokyo, Japan) was carefully inserted into the patient's oropharynx. The endoscopic view of the huge vocal cord mass nearly obstructing the airway indicated that the size of the glottic opening was too small for even a 6.0-mm tube. Furthermore, advancing the endotracheal tube (ETT) through the fiberoptic bronchoscope could not show whether the tube itself was damaging the tumor or pushing tumor particles deeper into the airway, which could cause major problems such as endobronchial occlusion. Thus, the McGrath[®] videolaryngoscope and a smaller 5.5-mm internal diameter ETT were used. With a clear view of the vocal cord area, the 5.5-mm ETT was advanced safely through the space between the vocal papilloma and the glottis. The tumor was not damaged, and no bleeding occurred. As soon as successful intubation was confirmed by capnography, general anesthesia was induced with propofol, sevoflurane, and rocuronium. Pulse oximetry did not show a decrease in the patient's oxygen saturation at any point during the intubation procedure.

The surgeon removed the vocal papilloma using the Jackson laryngoscope for visualization and microscissors for resection (Figure 2). Bleeding was well controlled with epinephrine-impregnated cotton balls

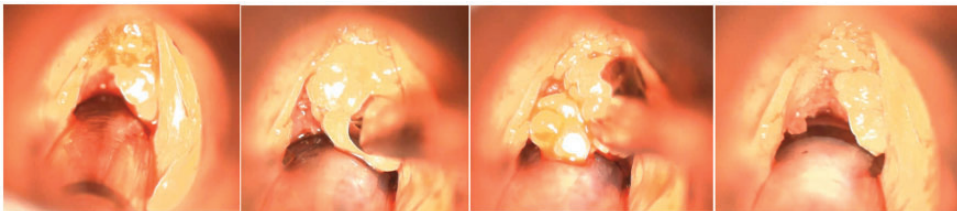


Figure 2. The endotracheal tube was safely intubated without affecting the vocal papilloma. Microforceps were used to pull the whole mass out into the field of view, and microscissors were then used to cut down the mass.

and electrocauterization. The operation time was 35 minutes, and the total anesthetic time was 80 minutes. A safe reversal agent (2 mg/kg of sugammadex) was administered, and the extubation was uneventful. Pathological examination confirmed that the mass was a squamous papilloma. There was no recurrence at the 2-month follow-up visit (Figure 3).

Discussion

Large masses positioned around the vocal cord area cause major difficulty for anesthesiologists. When patients are sedated in the supine position, the mass may fall backward by its own weight, obstructing the airway. Therefore, it may suddenly become difficult to apply mask ventilation even to asymptomatic patients after they have fallen asleep. The volume of the mass itself may block most of the vocal cords, leaving little space for the ETT to pass through.^{2,3,8} Moreover, there is a risk that mass particles may be dislodged and become aspirated deeper in the airway along with the tip of the ETT. These problems pose hardships for anesthesiologists because they can affect surgical outcomes, and they may even threaten the patient's life.^{5,7,9}

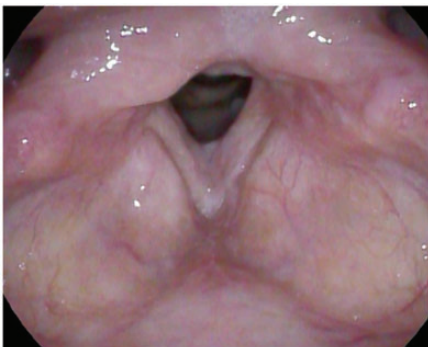

Figure 3. Endoscopic view shows no sign of mass recurrence 2 months after the surgery.

The two major advantages of awake intubation are airway patency and reversibility. The patient undergoes conscious sedation that enables spontaneous respiration, which allows the patient to be supplied with oxygen during intubation attempts. Under general anesthesia, situations such as repeated intubation failure, total obstruction of the airway, and impossible mask ventilation are extreme hazards, especially because immediate reversal cannot be easily achieved.^{5,7,10}

Fiberoptic bronchoscopy is widely accepted as the best practice for managing difficult airways and awake intubation.^{1,5,6} However, the fiberoptic technique itself is difficult because part of the device must pass through a limited glottic space, causing major patient discomfort. Moreover, while introducing the ETT into the glottis, the tip of the tube is not visualized; thus, it is unclear whether the tumor has been damaged or pushed into the airway by the tube.^{5,8}

Awake intubation using a McGrath[®] videolaryngoscope has several benefits over fiberoptic bronchoscopy. The McGrath[®] blade is relatively small, so less force is required for it to enter the oropharynx. Additionally, the device does not have to pass through the narrow vocal cords, reducing both anesthesiologist and patient distress.^{6,8,9} More importantly, the laryngoscopic view provides full visualization of the ETT tip for more controlled and safer advancement into the glottic aperture. It also allows for the identification of any masses remaining after ETT insertion. The videolaryngoscope monitor can be viewed not only by the operator but also by the assistants, allowing additional assistance to be provided more efficiently if necessary.^{5,7,8}

In conclusion, airways that are thought to be difficult because of the involvement of a bulky dangling mass around the vocal cords should be approached carefully. Although fiberoptic intubation remains the

only possible method for intubating patients with limited or no oral access, blind passage of the ETT over the fiberoptic bronchoscope puts the patient at risk for further severe complications, such as endobronchial occlusion and lung collapse. As described in the present case, awake intubation using a McGrath[®] videolaryngoscope can facilitate safe and easy intubation through narrowed vocal cords. However, the device alone will not lead to success in all clinical cases. Close preanesthetic assessment of the airway features is crucial. Besides simply estimating the Mallampati classification and neck extension, as in our case, further evaluation of the thyromental distance, inter-incisor gap, and upper lip bite test would better help to predict difficulties of intubation. Moreover, the patient must receive sufficient preanesthetic education, local nerve blocks must be conducted effectively, the patient must be adequately sedated, and the operator must have sufficient dexterity. Alternative intubation plans should also be prepared in the event that the primary plan fails.

Declaration of conflicting interest

The authors declare that there is no conflict of interest.

Funding

This research received no specific grant from any funding agency in the public, commercial, or not-for-profit sectors.

ORCID iD

Sung Min Lee  <https://orcid.org/0000-0002-7194-3941>

Hyunyoung Lim  <https://orcid.org/0000-0003-0343-6750>

References

1. Apfelbaum JL, Hagberg CA, Caplan RA, et al. Practice guidelines for management of the difficult airway: an updated report by the American Society of Anesthesiologists task force on management of the difficult airway. *Anesthesiology* 2013; 118: 251–270.
2. Mason RA and Fielder CP. The obstructed airway in head and neck surgery. *Anaesthesia* 1999; 54: 625–628.
3. Rees L and Mason RA. Advanced upper airway obstruction in ENT surgery. *Br J Anaesth CEPD Reviews* 2002; 2: 134–138.
4. Benumof JL. Management of the difficult adult airway. With special emphasis on awake tracheal intubation. *Anesthesiology* 1991; 75: 1087–1110.
5. Seo H, Lee G, Ha SI, et al. An awake double lumen endotracheal tube intubation using the Clarus Video System in a patient with and epiglottic cyst. *Korean J Anesthesiol* 2014; 66: 157–159.
6. McGuire BE. Use of the McGrath video laryngoscope in awake patients. *Anaesthesia* 2009; 64: 912–914.
7. Kramer A, Müller D, Pfortner R, et al. Fiberoptic vs videolaryngoscopic (C-MAC[®] D-BLADE) nasal awake intubation under local anaesthesia. *Anaesthesia* 2015; 70: 400–406.
8. Takenaka I, Aoyama K, Nakamura M, et al. Oral styletted intubation under video control in a patient with a large mobile glottic tumour and a difficult airway. *Can J Anaesth* 2002; 49: 203–206.
9. España Fuente L, Mella Pérez G, Laserna Cocina B, et al. Can videolaryngoscopy be a first option in a patient with laryngeal amyloidosis? *Rev Esp Anestesiología Reanimación* 2018; 65: 160–164.
10. Pani N and Kumar Rath S. Regional & topical anaesthesia of upper airways. *Indian J Anaesth* 2009; 53: 641–648.