

# Efficacy of <sup>18</sup>F-fluorodeoxyglucose PET/CT for Detecting Lymph Node Metastasis in Papillary Thyroid Carcinoma

Dong Won Lee, MD<sup>1</sup>, Chang Myeon Song, MD, PhD<sup>1</sup>,  
 Yong Bae Ji, MD, PhD<sup>1</sup>, Ji Young Kim, MD, PhD<sup>2</sup>,  
 Yun Young Choi, MD, PhD<sup>2</sup>, Ji Young Lee, MD<sup>3</sup>,  
 and Kyung Tae, MD, PhD<sup>1</sup>

OTO Open

1-7

© The Authors 2018

Reprints and permission:

sagepub.com/journalsPermissions.nav

DOI: 10.1177/2473974X18788545

http://oto-open.org



No sponsorships or competing interests have been disclosed for this article.

## Abstract

**Objective.** To evaluate the efficacy of preoperative <sup>18</sup>F-fluorodeoxyglucose positron emission tomography/computed tomography (PET/CT) for detecting cervical lymph node (LN) metastasis in papillary thyroid carcinoma (PTC).

**Study Design.** Case series with chart review.

**Setting.** University tertiary care facility.

**Subjects and Methods.** We retrospectively compared the pathologic results for 409 cervical LN levels in 140 patients who underwent thyroidectomy and central neck dissection with/without lateral neck dissection with the findings of preoperative PET/CT, ultrasonography (US), and CT. We judged LN metastasis in PET/CT using the maximum standardized uptake value (SUVmax) at the optimal cutoff value in receiver operating characteristic curves and compared the sensitivity, specificity, and diagnostic accuracy of the 3 imaging tools.

**Results.** At all neck levels (central and lateral compartments), PET/CT had a sensitivity of 57.5%, specificity of 68.6%, and diagnostic accuracy of 63.6% when the cutoff value of SUVmax was 1.125. The corresponding values were 59.1%, 90.6%, and 76.3%, respectively, for US and 53.8%, 91.9%, and 74.6% for CT. In the central compartment (level VI), sensitivity, specificity, and diagnostic accuracy were 48.9%, 67.4%, and 59.9% for PET/CT (cutoff SUVmax 1.125); 47.8%, 96.3%, and 76.7% for US; and 41.3%, 97.0%, and 74.4% for CT, respectively. In the lateral compartment (levels II-V), the corresponding values of sensitivity, specificity, and diagnostic accuracy were 70.2%, 69.3%, and 69.8% for PET/CT (cutoff SUVmax 1.055); 70.2%, 81.8%, and 75.8% for US; and 65.9%, 84.1%, and 74.7% for CT.

**Conclusion.** PET/CT is less effective as a preoperative diagnostic tool for detecting cervical lymph node metastasis in PTC than US or CT.

## Keywords

positron emission tomography, fluorodeoxyglucose F18, ultrasonography, computed tomography, lymph node, papillary thyroid carcinoma

Received March 18, 2018; revised May 14, 2018; accepted June 22, 2018.

Cervical lymph node (LN) metastasis of papillary thyroid carcinomas (PTCs) occurs in about 30% to 80% of patients<sup>1,2</sup> and is an important prognostic factor for local or regional recurrence of PTC.<sup>3,4</sup> It also has an adverse prognostic effect on survival, especially in older patients.<sup>5</sup> American Thyroid Association guidelines recommend that therapeutic central neck dissection (CND) for patients with clinically involved central LNs should accompany total thyroidectomy. Prophylactic CND should be considered for advanced primary tumors (T3 or T4) or clinically involved lateral neck nodes (cN1b), or if the information obtained will be used to plan further steps in therapy, although this is still controversial.<sup>6</sup> For lateral compartment LNs, most surgeons recommend therapeutic lateral compartmental LN dissection for clinically proven metastases. However, prophylactic lateral neck dissection

<sup>1</sup>Department of Otolaryngology-Head and Neck Surgery, College of Medicine, Hanyang University, Seoul, Republic of Korea

<sup>2</sup>Department of Nuclear Medicine, College of Medicine, Hanyang University, Seoul, Republic of Korea

<sup>3</sup>Department of Radiology, College of Medicine, Hanyang University, Seoul, Republic of Korea

## Corresponding Author:

Kyung Tae, MD, PhD, Department of Otolaryngology-Head and Neck Surgery, College of Medicine, Hanyang University, 222 Wangsimni-ro, Seongdong-gu, Seoul, 04763, Republic of Korea.  
 Email: kytae@hanyang.ac.kr



Creative Commons CC-BY-NC: This article is distributed under the terms of the Creative Commons Attribution 4.0 License (<http://www.creativecommons.org/licenses/by/4.0/>) which permits any use, reproduction and distribution of the work without

further permission provided the original work is attributed as specified on the SAGE and Open Access pages (<https://us.sagepub.com/en-us/nam/open-access-at-sage>).

for PTC is usually not recommended.<sup>7,8</sup> Therefore, strict evaluation of cervical LN metastases is important for accurate staging and for planning the appropriate treatment before surgery and to minimize unnecessary neck dissection.

Cervical LN metastasis of PTC can be evaluated by physical examination and imaging tests such as ultrasonography (US), computed tomography (CT), magnetic resonance imaging (MRI), and <sup>18</sup>F-fluorodeoxyglucose (<sup>18</sup>F-FDG) positron emission tomography/computed tomography (PET/CT). Ultrasonography and CT are currently the most popular diagnostic imaging methods for preoperative evaluation of cervical LN metastasis of PTC.<sup>9,10</sup>

In recent years, <sup>18</sup>F-FDG PET/CT has become widely used to detect primary tumors, occult LN metastasis, and distant metastasis in a variety of malignancies, including thyroid cancer. It is especially useful in establishing recurrence in patients with elevated serum thyroglobulin and negative radioiodine whole-body scans after total thyroidectomy.<sup>11,12</sup> There have been a few studies analyzing the features and diagnostic value of <sup>18</sup>F-FDG PET/CT in evaluating cervical LN metastasis in PTC, but most of these studies were based on low numbers of patients or contained bias because they were multicenter studies. Also, they set an arbitrary maximum standardized uptake value (SUVmax) of 2.0, which is the general cancer uptake criterion for thyroid nodules themselves. Also, FDG uptake was graded on a subjective visual scale. Therefore, the exact effectiveness of <sup>18</sup>F-FDG PET/CT in evaluating cervical LN metastasis has not been fully established.

The purpose of this study was to evaluate the diagnostic value of preoperative <sup>18</sup>F-FDG PET/CT for detecting cervical LN metastasis in PTC by comparing it with US and CT. We also aimed to establish the optimal value of SUVmax of LNs for use in the differential diagnosis of metastatic and benign LNs.

## Materials and Methods

### Patients and Operation

We retrospectively analyzed the medical records and preoperative <sup>18</sup>F-FDG PET/CT, US, and contrast-enhanced CT imaging findings for 140 patients with PTC who underwent thyroidectomy and CND with/without lateral neck dissection (LND) and who underwent preoperative <sup>18</sup>F-FDG PET/CT in a tertiary hospital from March 2007 to December 2012. Preoperative <sup>18</sup>F-FDG PET/CT was not performed routinely in all patients with PTC in our hospital: some patients underwent <sup>18</sup>F-FDG PET/CT preoperatively to evaluate distant and regional metastasis after diagnosis with PTC by fine-needle aspiration cytology; others underwent <sup>18</sup>F-FDG PET/CT during a routine health examination and PTC was found incidentally. Exclusion criteria were other types of thyroid cancer, distant metastases, recurrent cases, cancer of other organs, and histories of head and neck irradiation and surgery. This study was approved by the Institutional Review Board of Hanyang University Guri Hospital (GURI 2017-08-002-001).

### Ultrasonography and Contrast-Enhanced CT

Preoperative US and CT with contrast enhancement were carried out routinely in all patients with PTC. All US and CT examinations and their interpretation were performed by 1 expert radiologist. The criteria for identifying metastases in US images were as follows: round shape (ratio of long/short diameter, <2), extracapsular spread, cystic change, calcification (microcalcification), hyperechogenicity, and heterogeneous inner structure.<sup>13</sup> The criteria in the case of CT images were round shape, enhancement, heterogeneity, and cystic and necrotic change. The size criteria for both US and CT were nodal diameter >1.5 cm for the long axes of the jugulodigastric and submandibular nodes and >1.0 cm for all other cervical lymph nodes except for level VI.<sup>14</sup>

### <sup>18</sup>F-FDG PET/CT

A dedicated whole-body <sup>18</sup>F-FDG PET/CT system (Biograph 6; Siemens Medical Systems, Knoxville, Tennessee) was used. Before the injection of <sup>18</sup>F-FDG, all patients fasted for at least 6 hours to maintain serum glucose concentrations below 200 mg/dL. Sugar-free liquids were permitted. After the intravenous injection of <sup>18</sup>F-FDG (0.21 mCi/kg), a CT scan was used to adjust attenuation before the PET scan. PET scans were acquired from the proximal thigh to the base of the skull. <sup>18</sup>F-FDG uptake by cervical lymph nodes was evaluated by the naked eye and by quantitative measurement using SUVmax. If any focally increased uptake lesion was detected by eye in the neck on maximum-intensity projection images, uptake by lymph nodes was assessed by careful examination of the axial <sup>18</sup>F-FDG PET/CT images by 2 expert nuclear medicine physicians. Then SUVmax was calculated from the following formula:  $SUV = [FDG \text{ activity concentration (Bq/mL)}] \times [total \text{ lean body mass (kg)}] / [injected \text{ FDG activity (Bq)}]$ . If the uptake was not distinct from the blood or muscle tissue, it was excluded.

### Data Analysis

We analyzed both cervical LNs on a per level basis, using the cervical LN levels in the American Joint Committee on Cancer staging manual.<sup>15</sup> A total of 409 cervical LN levels in 140 patients with findings of preoperative <sup>18</sup>F-FDG PET/CT, US, and CT were evaluated. The neck levels were divided into 3 groups: total (central and lateral compartments), central (level VI), and lateral (levels II-V) compartments. We used receiver operating characteristic (ROC) curve analysis to determine the optimal SUVmax for differential diagnosis between benign and malignant LNs. We analyzed and compared the sensitivity, specificity, and diagnostic accuracy of the 3 imaging tools as applied to the total, central, and lateral neck compartments. The McNemar test was used to determine whether the sensitivities, specificities, and diagnostic accuracies of US, CT, and <sup>18</sup>F-FDG PET/CT differed significantly. All analyses were performed using SPSS Statistics for Windows, Version 18.0 (SPSS, Inc, an IBM Company, Chicago, Illinois).

## Results

Patient demographics and tumor characteristics are summarized in **Table 1**. Of the total of 140 patients, 131 underwent total thyroidectomy and 9 unilateral lobectomy. All patients underwent ipsilateral (39 cases, 27.9%) or bilateral (101 cases, 72.1%) CND with thyroidectomy. Of total 241 central LN levels, 227 levels were analyzed. Fourteen central LN levels were excluded because of no distinct SUV uptake compared to the blood vessels or muscle tissue. Therapeutic lateral neck dissection was performed in 51 patients with LN metastasis suspected on the imaging findings. Ipsilateral lateral neck dissection was performed in 44 patients (31.4%) and bilateral lateral neck dissection in 7 patients (5%). Of 58 lateral necks, the extent of lateral neck dissection was levels II, III, IV, and V in 30 necks; levels II, III, and IV in 5 necks; levels III, IV, and V in 5 necks; and others in 18 necks. No patients underwent level I dissection with suspected metastatic LNs at level I. Therefore, total 182 lateral LN levels were analyzed in this study.

### Cervical LN Metastasis Rate

Pathologic examination showed that of the total of 409 neck LN levels, 186 (45.5%) contained metastatic LNs. In the central compartment (level VI), 92 of 227 LN levels were positive for metastatic LNs; in the lateral compartment, 94 of 182 LN levels were positive (**Table 2**).

### Diagnostic Efficacies of <sup>18</sup>F-FDG PET/CT, US, and CT

The diagnostic power of <sup>18</sup>F-FDG PET/CT was highest at SUVmax 1.125 in the total and central compartments and 1.055 in the lateral compartments, based on the ROC curve analysis (**Table 3**). We compared the results of US, CT, and <sup>18</sup>F-FDG PET/CT using these cutoff values of SUVmax. **Figure 1** shows the diagnostic values for each imaging modality in the total, central, and lateral compartments. In the total and central compartments, the specificity of <sup>18</sup>F-FDG PET/CT was significantly lower than those of US and CT ( $P < .001$ ,  $P < .001$ ), as was the diagnostic accuracy of <sup>18</sup>F-FDG PET/CT ( $P < .001$ ,  $P < .001$ ). In the lateral compartment, the specificity of <sup>18</sup>F-FDG PET/CT was significantly lower than that of CT ( $P < .001$ ).

The SUVmax value that reduced false positives to zero (specificity 100%) was 2.585 in the total compartment, 2.27 in the central compartment, and 2.585 in the lateral compartment. Sensitivities were 14%, 8%, and 22.3%, respectively.

### Comparison of the Mean Sizes and SUVmax Values of the Central and Lateral LN Compartments

The sizes and SUVmax values of the malignant metastatic LNs of the lateral compartments were significantly larger than those of the central compartment (**Table 4**). However, the sizes and SUVmax values of benign LNs in the central and lateral compartments were not significantly different (**Table 4**).

**Table 1.** Demographic and Clinicopathologic Characteristics of the Patients.<sup>a</sup>

Characteristic	Value
Sex	
Male	28 (20.0)
Female	112 (80.0)
Age, mean $\pm$ SD (range), y	48.82 $\pm$ 13.08 (15-76)
Type of thyroidectomy	
Total thyroidectomy	131 (93.6)
Hemithyroidectomy	9 (6.4)
Extent of ND	
Central ND	140 (100)
Ipsilateral	39 (27.9)
Bilateral	101 (72.1)
Lateral ND	51 (36.4)
Ipsilateral	44 (31.4)
Bilateral	7 (5.0)
Primary tumor	
Size, median (range), cm	0.95 (0.2-5.0)
Multifocal	19 (13.6)
Bilateral	28 (20.0)
Minimal ETE	87 (62.1)
T classification	
T1	46 (32.9)
T2	5 (3.6)
T3	86 (61.4)
T4	3 (2.1)
N classification	
N0	58 (41.4)
N1a	38 (27.1)
N1b	44 (31.4)
TNM stage	
I	79 (56.4)
II	0 (0)
III	41 (29.3)
IVA	20 (14.3)

Abbreviations: ETE, extrathyroidal extension; ND, neck dissection.

<sup>a</sup>Values are presented as number (%) unless otherwise indicated.

## Discussion

Conventional US, CT, and MRI are useful methods for visualizing morphological and anatomical structures in cancer. On the other hand, <sup>18</sup>F-FDG PET is able to identify cancers by visualizing changes in the metabolism of cells, so-called functional changes, which can be detected prior to anatomical changes. In addition to <sup>18</sup>F-FDG PET, <sup>18</sup>F-FDG PET/CT can provide anatomical information based on synthetic images from CT.<sup>16</sup>

A few studies have evaluated the ability of <sup>18</sup>F-FDG PET/CT to detect cervical LN metastases in patients with PTC. Chong et al<sup>17</sup> compared preoperative LN staging using contrast-enhanced <sup>18</sup>F-FDG PET/CT and neck CT at 4 institutions and found that contrast-enhanced <sup>18</sup>F-FDG PET/

**Table 2.** Pathologic Results for Cervical Lymph Node Metastasis According to Lymph Node (LN) Level.

Level	Number of LN Levels	Positive LN Levels, No. (%)	Negative LN Levels, No. (%)
II	41	22 (53.7)	19 (46.3)
III	51	34 (66.7)	17 (33.3)
IV	52	31 (59.6)	21 (40.4)
V	38	7 (18.4)	31 (81.6)
VI (central)	227	92 (40.5)	135 (59.5)
Total	409 (100)	186 (45.5)	223 (54.5)

**Table 3.** Cutoff Values of SUVmax for Metastatic Lymph Nodes Based on Receiver Operating Characteristic Curves and the Sensitivity, Specificity, and Diagnostic Accuracy of  $^{18}\text{F}$ -fluorodeoxyglucose Positron Emission Tomography/Computed Tomography.

Characteristic	Total	Central Compartment	Lateral Compartment
SUV cutoff value	1.125	1.125	1.055
Sensitivity, %	57.5	48.9	70.2
Specificity, %	68.6	67.4	69.3
Diagnostic accuracy, %	63.6	59.9	69.8

Abbreviation: SUV, standardized uptake value.

CT was more sensitive and reliable than CT for preoperative LN staging, using a cutoff value of SUVmax of 2.0. Some authors used the SUVmax of the primary tumor (pSUVmax) to predict LN metastasis in patients with PTC. Jung et al<sup>18</sup> reported that pSUVmax >4.6 was associated with central LN metastasis. Byun et al<sup>19</sup> similarly reported that pSUVmax >2.8 was associated with central LN metastasis and that the pSUVmax values of both  $^{18}\text{F}$ -FDG PET/CT and US were effective in preoperative prediction of central LN metastasis from papillary thyroid microcarcinomas.

However, other studies have reported that preoperative  $^{18}\text{F}$ -FDG PET/CT in patients with PTC is not effective in preoperative regional LN staging. Morita et al<sup>20</sup> reported that US was better for preoperative LN evaluation than  $^{18}\text{F}$ -FDG PET/CT and CT, using a subjective visual scale of FDG uptake in  $^{18}\text{F}$ -FDG PET/CT. Jeong et al<sup>21</sup> showed that the diagnostic results of US, CT, and  $^{18}\text{F}$ -FDG PET/CT did not differ significantly:  $^{18}\text{F}$ -FDG PET/CT did not provide any additional benefit for the initial evaluation of LN in patients with PTC. Choi et al<sup>22</sup> also reported that  $^{18}\text{F}$ -FDG PET/CT afforded no additional information to US. Both Jeong et al and Choi et al used SUVmax 2.0 as the cutoff value of LN metastasis in  $^{18}\text{F}$ -FDG PET/CT.

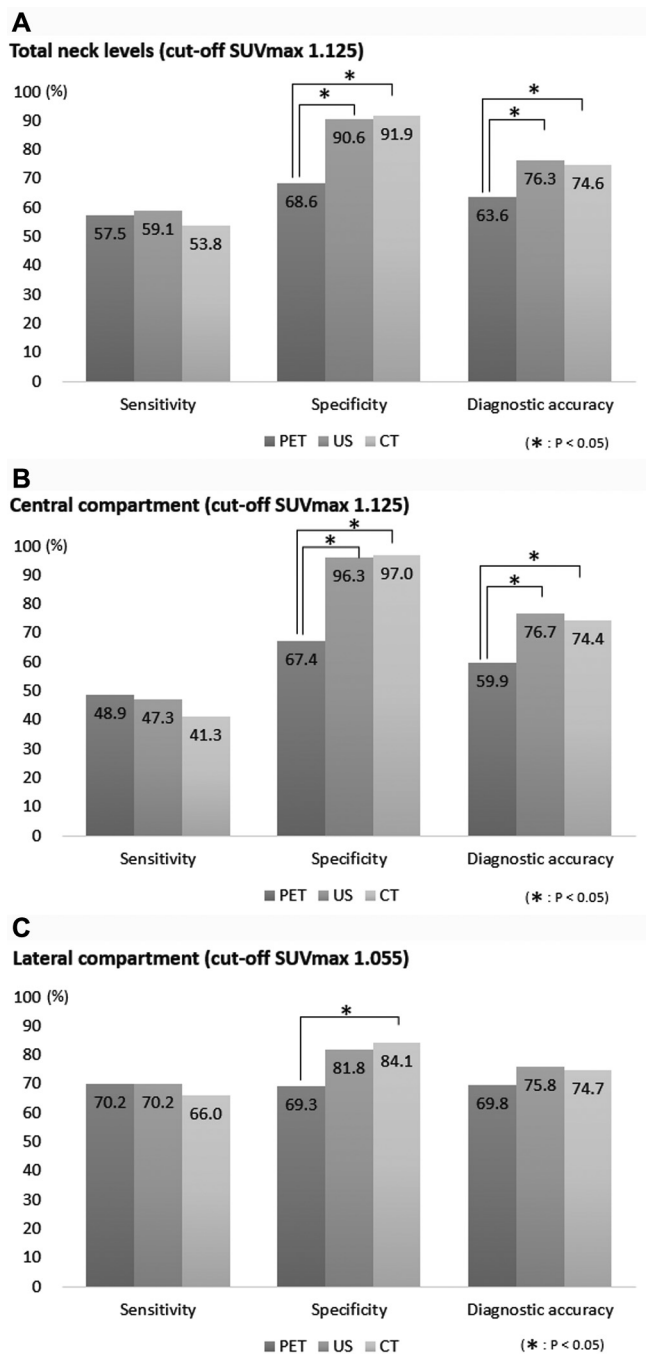
The previous studies that evaluated the effectiveness of  $^{18}\text{F}$ -FDG PET/CT for detecting cervical LN metastasis in PTC have major limitations. Some of the studies used the SUVmax of the primary thyroid tumor instead of the SUVmax of LNs, and most of the studies used arbitrary values of SUVmax, such as 2.0, or a subjective visual scale for LNs instead of the optimal cutoff value of SUVmax. As far as we are aware, there are no studies using the optimal SUVmax cutoff value of LN itself as an indicator of LN

metastasis. In the present study, we used the optimal cutoff value of SUVmax of LNs derived from an ROC curve to evaluate cervical LN metastasis. That is an important advantage of the present study. Actually, the optimal cutoff value of SUVmax may vary from machine to machine in different institutions. Therefore, the appropriate cutoff value of SUVmax in a given institution should be determined.

In the current study, sensitivity did not differ significantly between US, CT, and  $^{18}\text{F}$ -FDG PET/CT, and the specificity and diagnostic accuracy of  $^{18}\text{F}$ -FDG PET/CT were lower than those of US and CT in the central and lateral compartments, even though we applied the optimal SUVmax of LNs. This implies that  $^{18}\text{F}$ -FDG PET/CT does not provide any additional benefit over conventional US or CT. Therefore,  $^{18}\text{F}$ -FDG PET/CT should not be considered the primary test for cervical LN metastasis in PTC; moreover,  $^{18}\text{F}$ -FDG PET/CT is costly. However, the high cutoff values of SUVmax that gave 100% specificity (such as 2.585 in the total compartment, 2.27 in the central compartment, and 2.585 in the lateral compartment) might be helpful to identify PTC if some patients had higher SUVmax values than these.

The overall sensitivity of all 3 methodologies tended to be lower for the central LN compartment than for the lateral LN compartments in this study. This is similar to the results of previous studies.<sup>20,23,24</sup> This could be due to the anatomical complexity of the thoracic inlet, which makes it more difficult to evaluate LN metastasis in the central compartment than in the lateral compartments.<sup>20,23</sup>

Actually identifying metastatic LNs with  $^{18}\text{F}$ -FDG PET/CT is difficult because many nonspecific, enlarged LNs show increased uptake. Also, a cutoff SUVmax value of



**Figure 1.** Diagnostic accuracies of ultrasonography (US), computed tomography (CT), and <sup>18</sup>F-fluorodeoxyglucose positron emission tomography/computed tomography (PET/CT) in the total compartment (A), the central compartment (B), and the lateral compartment (C). SUVmax, maximum standardized uptake value.

LN of <1.5 is actually similar to that of the blood, so it is not easy to evaluate the uptake signals in <sup>18</sup>F-FDG PET/CT images. Well-differentiated thyroid carcinomas are also associated with reduced glucose metabolism, which results in reduced SUV uptake. On the other hand, dedifferentiated thyroid carcinomas that do not accumulate <sup>131</sup>I show elevated glucose utilization, and metastatic tumors in the LNs

**Table 4.** Comparison of the Sizes and SUVmax Values of Malignant and Benign Lymph Nodes in the Central and Lateral Compartments.

Pathology/Compartment	Size, Mean ± SD, cm	P Value
Malignant LNs (n = 186)		
Central (n = 92)	0.942 ± 0.389	.023
Lateral (n = 94)	1.091 ± 0.492	
Benign LNs (n = 223)		
Central (n = 135)	0.834 ± 0.295	.780
Lateral (n = 88)	0.845 ± 0.308	
Pathology/Compartment	SUVmax, Mean ± SD	P Value
Malignant LNs (n = 186)		
Central (n = 92)	1.408 ± 1.209	.002
Lateral (n = 94)	2.415 ± 2.862	
Benign LNs (n = 223)		
Central (n = 135)	1.046 ± 0.334	.341
Lateral (n = 88)	0.995 ± 0.42	

Abbreviations: LN, lymph node; SUVmax, maximum standardized uptake value.

tend to grow slowly and have a lower glucose metabolism than primary tumors.<sup>25,26</sup> Also, the partial volume effect can influence the results of <sup>18</sup>F-FDG PET/CT. This effect is defined as the loss in apparent activity due to the limited spatial resolution of PET scanners (typically 5-7 mm full-width at half-maximum).<sup>27</sup> The smaller the tumor, the greater the underestimate of SUVmax.<sup>28</sup> Correction for the partial volume effect may improve the accuracy of SUVmax for LN metastasis.<sup>27</sup> To test this idea, we also analyzed and compared the sensitivity, specificity, and diagnostic accuracy of <sup>18</sup>F-FDG PET/CT with those of US and CT in LNs that exceeded 6 mm to avoid the partial volume effect, but the results were similar to the results for the total cases. In the total and central compartments, the specificity and diagnostic accuracy of <sup>18</sup>F-FDG PET/CT were significantly lower than those of US (*P* < .001 in both) and CT (*P* < .001 and *P* = .003, respectively). In the lateral compartment, there were no significant differences between the 3 methodologies, except the specificity between <sup>18</sup>F-FDG PET/CT and CT.

This study has several limitations. First, there was inevitable selection bias because it was a retrospective nonrandomized study. Second, we analyzed cervical LN metastasis on a per level basis rather than in individual LNs. Therefore, we do not know whether the metastatic LNs at each level of the pathologic results exactly matched the positive LNs in the imaging studies. Third, the optimal cutoff value of SUVmax used for differential diagnosis between malignant and benign LNs was too low. Therefore, it was difficult to interpret the signals.

**Conclusion**

<sup>18</sup>F-FDG PET/CT is less effective as the primary preoperative diagnostic tool for detecting cervical LN metastasis in PTC than US and CT.

## Author Contributions

**Dong Won Lee**, conception and design, analysis and interpretation of data, drafting the article, final approval, agreement; **Chang Myeon Song**, conception and design, analysis and interpretation of data, manuscript revision, final approval, agreement; **Yong Bae Ji**, acquisition of data, manuscript revision, final approval, agreement; **Ji Young Kim**, interpretation of data, critical revision of the article, final approval, agreement; **Yun Young Choi**, interpretation of data, critical revision of the article, final approval, agreement; **Ji Young Lee**, interpretation of data, critical revision of the article, final approval, agreement; **Kyung Tae**, conception and design, interpretation of data, critical revision of the article, final approval, agreement.

## Disclosures

**Competing interests:** None.

**Sponsorships:** None.

**Funding source:** None.

## References

- Mazzaferri EL, Jhiang SM. Long-term impact of initial surgical and medical therapy on papillary and follicular thyroid cancer. *Am J Med.* 1994;97:418-428.
- Shaha AR, Shah JP, Loree TR. Patterns of nodal and distant metastasis based on histologic varieties in differentiated carcinoma of the thyroid. *Am J Surg.* 1996;172:692-694.
- Mazzaferri EL, Kloos RT. Clinical review 128: current approaches to primary therapy for papillary and follicular thyroid cancer. *J Clin Endocrinol Metab.* 2001;86:1447-1463.
- Grebe SK, Hay ID. Thyroid cancer nodal metastases: biologic significance and therapeutic considerations. *Surg Oncol Clin North Am.* 1996;5:43-63.
- Zaydfudim V, Feurer ID, Griffin MR, et al. The impact of lymph node involvement on survival in patients with papillary and follicular thyroid carcinoma. *Surgery.* 2008;144:1070-1078.
- Haugen BR, Alexander EK, Bible KC, et al. 2015 American Thyroid Association management guidelines for adult patients with thyroid nodules and differentiated thyroid cancer: the American Thyroid Association Guidelines Task Force on Thyroid Nodules and Differentiated Thyroid Cancer. *Thyroid.* 2016;26:1-133.
- Ito Y, Miyauchi A. Lateral lymph node dissection guided by preoperative and intraoperative findings in differentiated thyroid carcinoma. *World J Surg.* 2008;32:729-739.
- Keum HS, Ji YB, Kim JM, et al. Optimal surgical extent of lateral and central neck dissection for papillary thyroid carcinoma located in one lobe with clinical lateral lymph node metastasis. *World J Surg Oncol.* 2012;10:221.
- Cooper DS, Doherty GM, Haugen BR, et al. Revised American Thyroid Association management guidelines for patients with thyroid nodules and differentiated thyroid cancer. *Thyroid.* 2009;19:1167-1214.
- Lee DW, Ji YB, Sung ES, et al. Roles of ultrasonography and computed tomography in the surgical management of cervical lymph node metastases in papillary thyroid carcinoma. *Eur J Surg Oncol.* 2013;39:191-196.
- Yeo JS, Chung JK, So Y, et al. F-18-fluorodeoxyglucose positron emission tomography as a presurgical evaluation modality for I-131 scan-negative thyroid carcinoma patients with local recurrence in cervical lymph nodes. *Head Neck.* 2001;23:94-103.
- Kim TH, Ji YB, Song CM, et al. SUVmax of 18F-FDG PET/CT in the differential diagnosis of benign and malignant thyroid nodules according to tumor volume. *World J Surg Oncol.* 2015;13:217.
- Leboulleux S, Girard E, Rose M, et al. Ultrasound criteria of malignancy for cervical lymph nodes in patients followed up for differentiated thyroid cancer. *J Clin Endocrinol Metab.* 2007;92:3590-3594.
- Som PM, Brandwein M, Lidov M, et al. The varied presentations of papillary thyroid carcinoma cervical nodal disease: CT and MR findings. *AJNR Am J Neuroradiol.* 1994;15:1123-1128.
- Edge S, Byrd DR, Compton CC, et al. *AJCC Cancer Staging Handbook: From the AJCC Cancer Staging Manual.* New York, NY: Springer; 2010.
- Gutzeit A, Antoch G, Köhl H, et al. Unknown primary tumors: detection with dual-modality PET/CT—initial experience. *Radiology.* 2005;234:227-234.
- Chong A, Ha JM, Han YH, et al. Preoperative lymph node staging by FDG PET/CT with contrast enhancement for thyroid cancer: a multicenter study and comparison with neck CT. *Clin Exp Otorhinolaryngol.* 2017;10:121-128.
- Jung JH, Kim CY, Son SH, et al. Preoperative prediction of cervical lymph node metastasis using primary tumor SUVmax on 18F-FDG PET/CT in patients with papillary thyroid carcinoma. *PLoS One.* 2015;10:e0144152.
- Byun BH, Jeong UG, Hong SP, et al. Prediction of central lymph node metastasis from papillary thyroid microcarcinoma by 18F-fluorodeoxyglucose PET/CT and ultrasonography. *Ann Nucl Med.* 2012;26:471-477.
- Morita S, Mizoguchi K, Suzuki M, et al. The accuracy of (18)[F]-fluoro-2-deoxy-D-glucose-positron emission tomography/computed tomography, ultrasonography, and enhanced computed tomography alone in the preoperative diagnosis of cervical lymph node metastasis in patients with papillary thyroid carcinoma. *World J Surg.* 2010;34:2564-2569.
- Jeong HS, Baek CH, Son YI, et al. Integrated 18F-FDG PET/CT for the initial evaluation of cervical node level of patients with papillary thyroid carcinoma: comparison with ultrasound and contrast-enhanced CT. *Clin Endocrinol (Oxf).* 2006;65:402-407.
- Choi WH, Chung YA, Han EJ, et al. Clinical value of integrated [18F]fluoro-2-deoxy-D-glucose positron emission tomography/computed tomography in the preoperative assessment of papillary thyroid carcinoma: comparison with sonography. *J Ultrasound Med.* 2011;30:1267-1273.
- Ahn JE, Lee JH, Yi JS, et al. Diagnostic accuracy of CT and ultrasonography for evaluating metastatic cervical lymph nodes in patients with thyroid cancer. *World J Surg.* 2008;32:1552-1558.
- Kouvaraki MA, Shapiro SE, Fornage BD, et al. Role of preoperative ultrasonography in the surgical management of patients with thyroid cancer. *Surgery.* 2003;134:946-955.

25. Frilling A, Tecklenborg K, Görges R, et al. Preoperative diagnostic value of [(18)F] fluorodeoxyglucose positron emission tomography in patients with radioiodine-negative recurrent well-differentiated thyroid carcinoma. *Ann Surg.* 2001;234:804-811.
26. Nahas Z, Goldenberg D, Fakhry C, et al. The role of positron emission tomography/computed tomography in the management of recurrent papillary thyroid carcinoma. *Laryngoscope.* 2005;115:237-243.
27. Hoetjes NJ, van Velden FH, Hoekstra OS, et al. Partial volume correction strategies for quantitative FDG PET in oncology. *Eur J Nucl Med Mol Imaging.* 2010;37:1679-1687.
28. Soret M, Bacharach SL, Buvat I. Partial-volume effect in PET tumor imaging. *J Nucl Med.* 2007;48:932-945.