

# Sciatic neuropathy and rhabdomyolysis after carbon monoxide intoxication

## A case report

Hyeok Dong Lee, MD, Sung Young Lee, MD, Young-Shin Cho, MD, Seung Hoon Han, MD, PhD, Si-Bog Park, MD, PhD, Kyu Hoon Lee, MD, PhD\*

### Abstract

**Rationale:** Peripheral neuropathy is a rare complication of carbon monoxide intoxication. Peripheral neuropathy following carbon monoxide intoxication is known to completely recover within a few months.

**Patient concerns:** A 40-year-old man complained of motor weakness and hypoesthesia of the right lower extremity with swelling of his right thigh after carbon monoxide intoxication resulting from a suicide attempt.

**Diagnoses:** Following nerve conduction and electromyographic studies, the patient was diagnosed with sciatic neuropathy with severe axonopathy. Clinical and laboratory findings led to a diagnosis of rhabdomyolysis.

**Interventions:** The patient was treated conservatively for rhabdomyolysis and underwent comprehensive rehabilitation for sciatic neuropathy during hospitalization.

**Outcomes:** After discharge, he underwent serial follow-up tests with nerve conduction and electromyographic studies, which showed prolonged persistence of sciatic neuropathy; however, he showed significant improvement at his 26-month post-discharge follow-up.

**Lesson:** Patients presenting with peripheral neuropathy secondary to carbon monoxide intoxication may show variable recovery periods; however, a favorable prognosis can be expected regardless of the concomitant occurrence of rhabdomyolysis and/or compartment syndrome.

**Abbreviations:** AFO = ankle-foot orthoses, CMAP = compound muscle action potential, EMG = electromyography, MMT = manual muscle testing, MRI = magnetic resonance imaging, NCS = nerve conduction study.

**Keywords:** carbon monoxide intoxication, electromyography, rhabdomyolysis, sciatic neuropathy

## 1. Introduction

Carbon monoxide intoxication had been reported in Korea until the 1980s when briquettes were widely used for heating and cooking purposes; however, the replacement of briquettes with oil and gas as fuel has led to a decline in the occurrence of carbon monoxide intoxication. Recently, charcoal-burning suicide rates are observed to be increasing.<sup>[1]</sup> Carbon monoxide intoxication affects the brain, heart, kidneys, skeletal muscles, skin, and peripheral nerves.<sup>[2]</sup> Depending on the duration of exposure and the concentration of carbon monoxide inhaled, patient with headache, fatigue, malaise, neuropsychological impairment,

anxiety or depression, nausea, vomiting, confusion, dizziness, convulsion, ataxia, loss of consciousness, brain infarction, and myocardial infarction, or are reported to die.<sup>[3]</sup> Peripheral neuropathy is a rare complication of carbon monoxide intoxication, and previous studies have reported the prevalence rate of peripheral neuropathy to be 0.84% in 2360 patients diagnosed with carbon monoxide intoxication.<sup>[2]</sup> Peripheral neuropathy caused by carbon monoxide intoxication is known to show complete recovery within a few months.<sup>[2]</sup> Furthermore, to our knowledge, no report has described a case of peripheral neuropathy secondary to carbon monoxide intoxication, wherein the patient has not recovered within a year. We describe the case of a patient diagnosed with sciatic neuropathy after carbon monoxide intoxication secondary to a charcoal-burning suicide attempt, who showed significant recovery at his 26-month postdischarge follow-up examination.

## 2. Case presentation

A 40-year-old man presented to the emergency department from another hospital with a swelling of his right thigh after a charcoal-burning suicide attempt in his car. He had been rescued after having remained in the car for 4 hours and received hyperbaric oxygen therapy at the previous hospital. When he arrived at the emergency department, physical examination revealed motor weakness and hypoesthesia of his right lower extremity and anesthesia of his right foot. Manual muscle testing (MMT) showed the following strengths of his individual muscle group: hip flexors, and extensors and knee flexors, grade 2; knee

Editor: N/A.

The authors have no conflicts of interest. The authors alone are responsible for the content and writing of the article.

Department of Rehabilitation Medicine, Hanyang University College of Medicine, Seoul, Republic of Korea.

\* Correspondence: Kyu Hoon Lee, Department of Rehabilitation Medicine, Hanyang University Hospital, 222-1, Wangsimni-ro, Seongdong-gu, Seoul 04763, Republic of Korea (e-mail: dumitru1@hanyang.ac.kr).

Copyright © 2018 the Author(s). Published by Wolters Kluwer Health, Inc. This is an open access article distributed under the terms of the Creative Commons Attribution-Non Commercial-No Derivatives License 4.0 (CCBY-NC-ND), where it is permissible to download and share the work provided it is properly cited. The work cannot be changed in any way or used commercially without permission from the journal.

Medicine (2018) 97:23(e11051)

Received: 26 February 2018 / Accepted: 18 May 2018

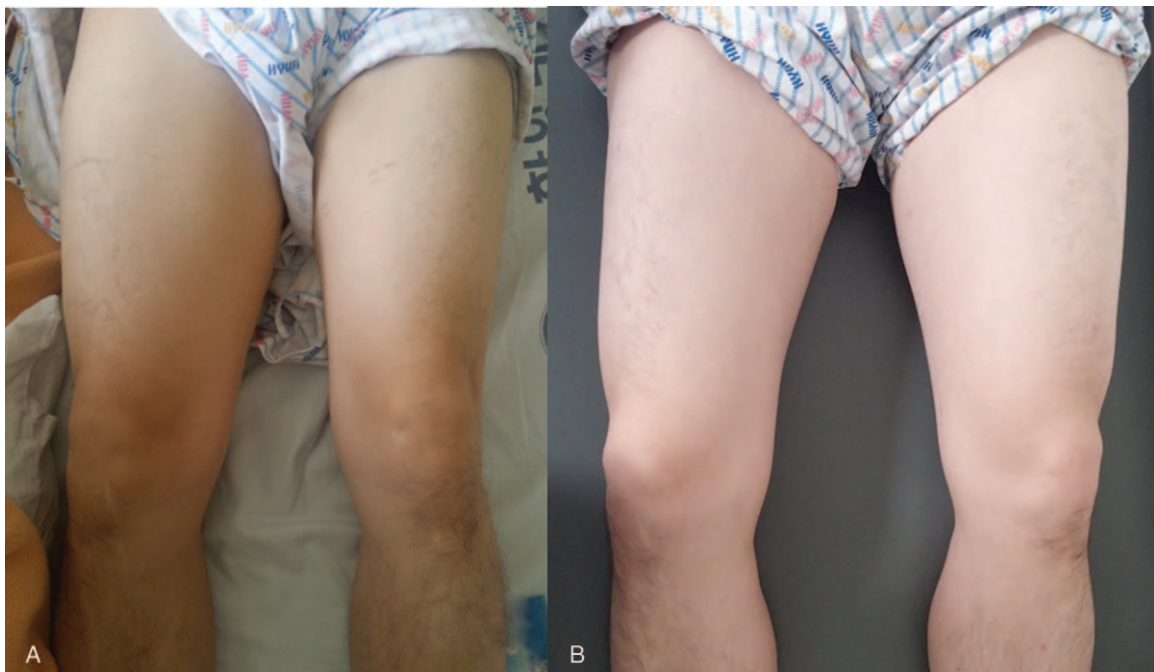
<http://dx.doi.org/10.1097/MD.00000000000011051>

extensors, grade 3; ankle dorsi-flexors and great toe dorsi-flexors, grade 1; and ankle plantar-flexors, grade 0. The circumference of his right thigh was 63 cm, which was 14 cm larger than that of the left thigh (Fig. 1). Second-degree burns were observed on his right thigh, upper arm, and scalp. Laboratory investigations showed elevated serum levels of creatine phosphokinase (79,800 U/L), lactate dehydrogenase (1949 U/L), aspartate aminotransferase (1132 U/L), alanine aminotransferase (353 U/L), blood urea nitrogen (41.6), creatinine (2.83 mg/dL), white blood cells (12,400 cells/mm<sup>3</sup>), C-reactive protein (11.17 mg/dL), and myoglobin (>4000 ng/mL). Magnetic resonance imaging (MRI) showed swelling and diffusely increased signal intensity in the muscles of the right thigh, and also the gluteal muscles with a signal abnormality was observed in the right sciatic nerve (Fig. 2). Additionally, fluid-attenuated inversion recovery-MRI of the brain showed bilateral hyperintensities in the globus pallidus and cerebellum.

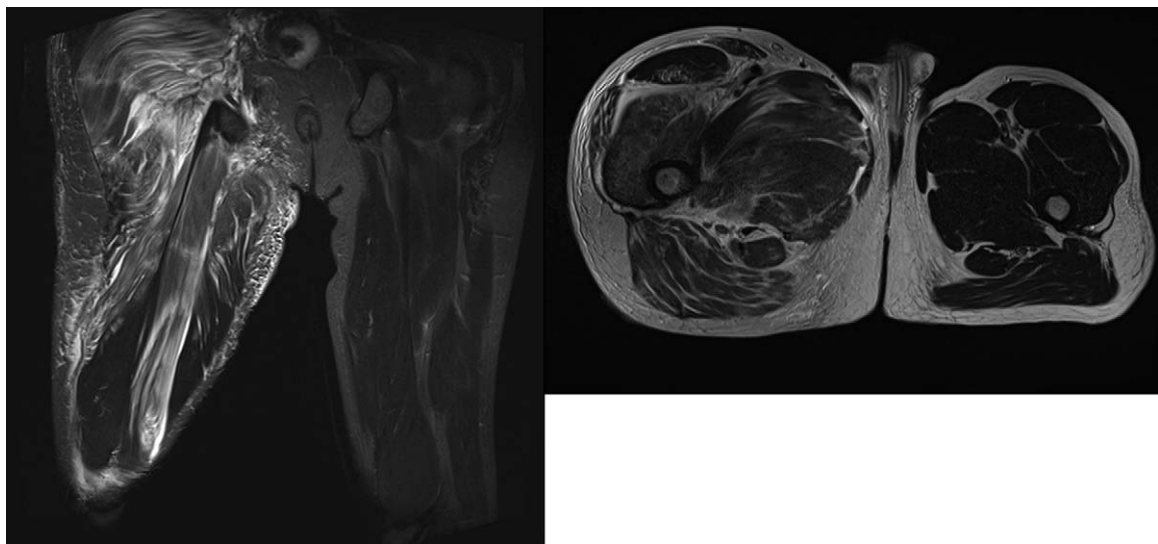
Rhabdomyolysis was treated with adequate hydration and urinary alkalization using sodium bicarbonate. Nerve conduction study (NCS) and electromyography (EMG) were performed 3 weeks after admission. The right-sided sural sensory nerve action potential and the peroneal and tibial compound muscle action potential (CMAP) were unobtainable after performing the NCS. Additionally, the right-sided tibial F-wave response and the H-reflex could not be obtained. Abnormal spontaneous activity was observed in the right medial gastrocnemius, peroneus longus, anterior tibialis, and biceps femoris. On the basis of these results, he was diagnosed with sciatic neuropathy with severe axonopathy. He was discharged after receiving comprehensive rehabilitation for 3 weeks. At the time of discharge, his hip flexor and extensor strength had improved to grade 3 (based on MMT), and he was able to walk with a cane wearing ankle-foot orthoses (AFO). The circumference of his right thigh was nearly the same as that of his left thigh and measured 51 cm. However, there was

no improvement in the strength of his ankle dorsi-flexors and plantar-flexors, and also his great toe dorsi-flexors. After discharge, he did home exercise without physical therapy session. Although he underwent follow-up NCS and EMG testing 4 times after discharge, MRI was not performed. EMG performed 2 months after discharge showed newly developed abnormal spontaneous activity in his gastrocnemius muscle. EMG performed 10 months after discharge showed no difference except an improved interference pattern, and newly developed polyphasic motor unit action potential patterns were observed in the long and short head of the biceps femoris muscle. MMT showed an improvement in the strength of the right knee flexors and ankle plantar-flexors to grade 3+ and 2, respectively; however, weakness of his ankle dorsi-flexors and great toe dorsi-flexors persisted. At 21 months after discharge, the strength of right ankle dorsi-flexors was improved to grade 2+ on MMT. Moreover, NCS now showed a small amplitude of the right peroneal CMAP recorded over the tibialis anterior, in contrast to previous testing that had not shown any response in the right peroneal CMAP. The amplitudes recorded were 0.8 and 0.5 mA, respectively, after stimulation at the fibular head and the popliteal fossa. MMT performed 26 months after discharge showed that the strength of his right-sided dorsiflexors had significantly improved to grade 4. The amplitudes of peroneal CMAP recorded over the tibialis anterior were 2.3 mA at both the sites that were stimulated. Table 1 and Table 2 show the summary of the results of NCS and EMG test mentioned above. Notably, the patient was now able to walk independently without using an AFO, and we could conclude that his sciatic neuropathy was in the process of recovery. Considering that the results of NCS and EMG test appear after clinical improvement, it is expected that further examination will show better results.

Written informed consent was obtained for publication of this case report from the patient. The Ethics Approval/Institutional



**Figure 1.** Comparison of the right and left thighs at admission (A) and at 2 months after discharge (B).



**Figure 2.** Magnetic resonance imaging (MRI) of the right thigh shows a diffusely increased signal intensity of the muscles of the right thigh and gluteal muscles, with abnormal signal changes in the right sciatic nerve.

**Table 1**

**Summary of nerve conduction study.**

Date	Rt. peroneal motor (R: tibialis anterior) (S: fibular head/popliteal fossa)			Rt. tibial motor (R: abductor hallucis) (S: med malleolus/popliteal fossa)			Rt. sural sensory (R: lateral malleolus) (S: posterior lower leg)			Rt. superficial peroneal sensory (R: anterior ankle) (S: anterior lower leg)		
	Latency	Amplitude	Velocity	Latency	Amplitude	Velocity	Latency	Amplitude	Velocity	Latency	Amplitude	Velocity
August 18, 2015	No response			No response			No response			No response		
October 27, 2015	No response			No response			No response			No response		
June 11, 2016	No response			No response			No response			No response		
May 20, 2017	5.8 ms	9.2 ms	0.8 mV/0.5 mV	21 ms	No response		No response			No response		
October 14, 2017	4.8 ms	6.6 ms	2.3 mV/2.3 mV	44 ms	No response		No response			No response		

Med = medial, R = recording site, Rt = right, S = stimulation site.

Review Board (IRB) is not needed because this is not a case of new intervention is performed.

**3. Discussion**

The pathomechanisms causing peripheral neuropathy secondary to carbon monoxide intoxication are as follows: toxicity of carbon monoxide itself, nerve compression, ischemia related to hypoxia, and petechial hemorrhages.<sup>[2,4]</sup> Choi<sup>[5]</sup> suggested that

peripheral neuropathy is usually associated with local swelling secondary to muscle necrosis, which is an important factor contributing to the development of peripheral neuropathy after carbon monoxide intoxication. Rahmani et al<sup>[6]</sup> reported bilateral brachial plexus injury after carbon monoxide intoxication after failed use of a water heater. They attributed the bilateral plexopathy to a combination of ischemic and toxic factors. In our patient, the onset of sciatic neuropathy could be attributed to the

**Table 2**

**Summary of electromyography.**

Date	At rest					On volition				
	Rt. PL	Rt. TA	Rt. GCM	Rt. BF-L	Rt. BF-S	Rt. PL	Rt. TA	Rt. GCM	Rt. BF-L	Rt. BF-S
August 18, 2015	P	P&F	Silent	P	P	N/C	N/C	N/C	Nml	Nml
October 27, 2015	P	P&F	P&F	P	P	N/C	N/C	N/C	DI	DI
June 11, 2016	P&F	P&F	P&F	P	P	N/C	N/C	N/C	Poly, DI	Poly, DI
May 20, 2017	P&F	P&F	P&F	Silent	Silent	Poly, LA, LD RR, DI	Poly, LD RR, DI	Poly, LD RR, DI	Poly, LA, LD RR, DI	Poly, LA, LD RR, DI
October 14, 2017	Silent	P	P	Silent	Silent	Poly, LA, LD RR, DI	Poly, LA, LD RR, DI	Poly, LA, LD RR, DI	Poly, LA, LD RR, DI	Poly, LA, LD RR, DI

BF-L = biceps femoris long head, BF-S = biceps femoris short head, DI = decreased interference patterns, F = fibrillation potential, GCM = medial gastrocnemius, LA = large amplitude, LD = large duration, N/C = not checkable due to low volitional activity, Nml = normal, P = positive sharp wave, PL = peroneus longus, Poly = polyphasic motor unit action potential, RR = reduced recruitment, Rt = right, TA = tibialis anterior.

toxicity of carbon monoxide itself in that carbon monoxide-induced hypoxia may have led to nerve damage. Additionally, direct nerve compression and ischemic damage to the nerve owing to decreased blood flow could have contributed to the development of sciatic neuropathy, considering the concomitant occurrence of rhabdomyolysis and compartment syndrome in our patient. However, it is difficult to attribute the pathomechanism to only 1 of the aforementioned hypotheses, and a multifactorial theory appears more plausible.

Carbon monoxide intoxication is an important cause of rhabdomyolysis and compartment syndrome.<sup>[7–9]</sup> Acute renal failure may occur as a result of rhabdomyolysis caused by carbon monoxide intoxication.<sup>[10,11]</sup> Ojike et al<sup>[12]</sup> have reported blunt trauma as being the most common cause of compartment syndrome of the thigh and neurological deficits as being the most common complication of compartment syndrome. Compartment syndrome can be diagnosed based on clinical manifestations or pressure measurements. Fasciotomy is required to achieve emergency decompression in patients presenting with compartment syndrome. The difference between diastolic pressure and the measured compartment pressure is used to determine the optimal timing to perform the fasciotomy.<sup>[13]</sup> Ji<sup>[14]</sup> reported a case of sciatic neuropathy related to acute compartment syndrome after carbon monoxide intoxication in which the patient underwent a fasciotomy. Physical examination performed on this patient a year after admission showed good recovery of the strength of the extensor hallucis longus, extensor digitorum, and plantar extensors and flexors, that is, from grade 1 at the time of admission to grade 4.

Choi<sup>[2]</sup> reported 20 cases of patients with peripheral neuropathy after carbon monoxide intoxication. Despite the occurrence of local swelling in 10 of these 20 patients and the occurrence of delayed neurological sequelae in 3 of 20 patients, complete recovery was achieved within 3 to 6 months in all patients. The patient reported by Rahmani et al,<sup>[6]</sup> who had been diagnosed with bilateral brachial plexus injury after carbon monoxide intoxication, was observed to recover without any sequelae within 4 months. Choi and Lim<sup>[15]</sup> reported a patient with peripheral neuropathy involving the bilateral lower extremities after carbon monoxide intoxication who did not develop local swelling. Weakness of bilateral knee and ankle extensors and flexors showed recovery within 5 months. Kuo et al<sup>[16]</sup> reported on a patient with bilateral femoral neuropathy concomitant with rhabdomyolysis after carbon monoxide intoxication. MMT performed in this patient showed recovery of the strength of knee extensors from grade 2 to grade 4.

In our patient, the sequelae associated with peripheral neuropathy showed prolonged persistence after discharge; however, significant improvement was observed at the 26-month postdischarge follow-up. This finding differs from that of previous reports that describe carbon monoxide intoxication-induced peripheral neuropathy that recovered within a few months. To date, recovery of peripheral neuropathy after a period of prolonged persistence has never been reported. Local swelling is an important factor contributing to the development of peripheral neuropathy after carbon monoxide intoxication. Thus, it can be deduced that peripheral neuropathy concomitant with rhabdomyolysis and compartment syndrome is likely to have a more serious presentation. However, it is difficult to predicate the factor that determine whether peripheral neuropathy

is accompanied or not in carbon monoxide intoxication just based on this assumption. Moreover, in the aforementioned patients, peripheral neuropathy showed complete recovery within a few months, regardless of the concomitant presence of rhabdomyolysis and compartment syndrome. As we followed up for a long time, we observed that the sequelae of peripheral neuropathy that occurred after carbon monoxide intoxication, accompanied by severe unilateral compartment syndrome and rhabdomyolysis, persisted for a long period of time, but recovered eventually. In patients presenting with peripheral neuropathy after carbon monoxide intoxication, although the recovery period might differ between cases, the prognosis remains favorable regardless of the concomitant occurrence of rhabdomyolysis and/or compartment syndrome.

## Author contributions

**Conceptualization:** Hyeok Dong Lee, Kyu Hoon Lee, Seung Hoon Han, Si-bog Park, Sung Young Lee.

**Methodology:** Hyeok Dong Lee.

**Supervision:** Kyu Hoon Lee.

**Writing – original draft:** Hyeok Dong Lee, Young-Shin Cho, Sung Young Lee.

**Writing – review & editing:** Hyeok Dong Lee, Kyu Hoon Lee.

## References

- [1] Chang SS, Chen YY, Yip PS, et al. Regional changes in charcoal-burning suicide rates in East/Southeast Asia from 1995 to 2011: a time trend analysis. *PLoS Med* 2014;11:e1001622.
- [2] Choi IS. A clinical study of peripheral neuropathy in carbon monoxide intoxication. *Yonsei Med J* 1982;23:174–7.
- [3] Weaver LK. Carbon monoxide poisoning. *N Engl J Med* 2009;360:1217–25.
- [4] Snyder RD. Carbon monoxide intoxication with peripheral neuropathy. *Neurology* 1970;20:177–80.
- [5] Choi IS. Carbon monoxide poisoning: systemic manifestations and complications. *J Korean Med Sci* 2001;16:253–61.
- [6] Rahmani M, Belaidi H, Benabdeljlil M, et al. Bilateral brachial plexus injury following acute carbon monoxide poisoning. *BMC Pharmacol Toxicol* 2013;14:61.
- [7] Sungur M, Güven M. Rhabdomyolysis due to carbon monoxide poisoning. *Clin Nephrol* 2001;55:336–7.
- [8] Sefer S, Degoricija V, Bilić B, et al. Acute carbon monoxide poisoning as the cause of rhabdomyolysis and acute renal failure. *Acta Med Croatica* 1999;53:199–202.
- [9] Abdul-Ghaffar NU, Farghaly MM, Swamy AS. Acute renal failure, compartment syndrome, and systemic capillary leak syndrome complicating carbon monoxide poisoning. *J Toxicol Clin Toxicol* 1996;34:713–9.
- [10] Loughridge L, Leader L, Bowen DAL. Acute renal failure due to muscle necrosis in carbon-monoxide poisoning. *Lancet* 1958;272:349–51.
- [11] Serbest S, Belhan O, Gürger M, et al. Compartment syndrome resulting from carbon monoxide poisoning. *A&A Case Rep* 2015;5:199–201.
- [12] Ojike NI, Roberts CS, Giannoudis PV. Compartment syndrome of the thigh: a systematic review. *Injury* 2010;41:133–6.
- [13] McQueen MM, Court-Brown CM. Compartment monitoring in tibial fractures: the pressure threshold for decompression. *Bone Joint J* 1996;78:99–104.
- [14] Ji JW. Acute compartment syndrome which causes rhabdomyolysis by carbon monoxide poisoning and sciatic nerve injury associated with it: a case report. *Hip Pelvis* 2017;29:204–9.
- [15] Choi JH, Lim H. Motor peripheral neuropathy involved bilateral lower extremities following acute carbon monoxide poisoning: a case report. *J Korean Soc Clin Toxicol* 2015;13:46–9.
- [16] Kuo SH, Leong CP, Wang LY, et al. Symmetrical femoral neuropathy and rhabdomyolysis complicating carbon monoxide poisoning. *Chang Gung Med J* 2006;29(suppl 4):103–8.