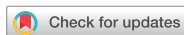

Original Article
Gastroenterology &
Hepatology



Feasibility and Stability of Liver Biopsy before Treatment for Preclinical Nonalcoholic Fatty Liver Studies

Yeon Ji Chae ,¹ Dae Won Jun ,^{1,2} Waqar Khalid Saeed ,² Hyeon Tae Kang ,¹ Ju Hee Oh ,¹ Seung Min Lee ,¹ and Kiseok Jang ³

¹Department Translational Medicine, Hanyang University Graduate School of Biomedical Science and Engineering, Seoul, Korea

²Department of Internal Medicine, College of Medicine, Hanyang University, Seoul, Korea

³Department of Pathology, College of Medicine, Hanyang University, Seoul, Korea



Received: Jun 25, 2018

Accepted: Oct 22, 2018

Address for Correspondence:

Dae Won Jun, MD, PhD

Department of Internal Medicine, Hanyang University College of Medicine, 222 Wangsimni-ro, Seongdong-gu, Seoul 04763, Korea.

E-mail: noshin@hanyang.ac.kr

Kiseok Jang, MD, PhD

Department of Pathology, College of Medicine, Hanyang University, 222 Wangsimni-ro, Seongdong-gu, Seoul 04763, Korea.

E-mail: medartisan@hanyang.ac.kr

© 2019 The Korean Academy of Medical Sciences.

This is an Open Access article distributed under the terms of the Creative Commons Attribution Non-Commercial License (<https://creativecommons.org/licenses/by-nc/4.0/>) which permits unrestricted non-commercial use, distribution, and reproduction in any medium, provided the original work is properly cited.

ORCID iDs

Yeon Ji Chae

<https://orcid.org/0000-0001-8609-7082>

Dae Won Jun

<https://orcid.org/0000-0002-2875-6139>

Waqar Khalid Saeed

<https://orcid.org/0000-0002-7888-9108>

Hyeon Tae Kang

<https://orcid.org/0000-0002-4771-3388>

Ju Hee Oh

<https://orcid.org/0000-0003-2864-7677>

ABSTRACT

Background: The heterogeneity of histological findings in preclinical diet-induced nonalcoholic fatty liver disease (NAFLD) animal models is highly challenging. Here, we aimed to evaluate the feasibility and stability of repeated liver biopsy in NAFLD animal models.

Methods: Heterogeneity of diet-induced NAFLD was evaluated at different time points in 52 high-fat diet (HFD), 35 methionine choline-deficiency diet (MCD), and 166 western diet (WD) induced NAFLD mice. Serial liver biopsies (left lateral, right medial, and left medial lobes) were performed monthly for up to 3 months. Mortality rates and changes in food intake, body weight, and liver enzymes were assessed.


Results: At 12 weeks, of the HFD animals, 14% and 30% did not develop steatosis and lobular inflammation, respectively; of the MCD animals, 7% did not develop lobular inflammation; and of the WD animals, 14% and 51% did not develop steatosis and lobular inflammation, respectively. The mortality rate of repeated liver biopsy was 1.62% (2/123 mice died). Repeated liver biopsy can be used to trace disease progression. Although body weight, food intake, and liver enzymes slightly changed after biopsy, all recovered within a week. Repeated liver biopsy did not affect the degrees of inflammation and steatosis of the other liver lobes.

Conclusion: The diet-induced NAFLD models were quite heterogeneous. Our results suggest that the repeated liver biopsy before treatment was applicable and stable in this NAFLD animal study.

Keywords: Animal Model; Nonalcoholic Fatty Liver Disease; Biopsy

INTRODUCTION

Nonalcoholic fatty liver disease (NAFLD) is common in adolescents as well as adults.¹ The use of an animal model of NAFLD is critical to increasing our understanding of its pathogenesis. However, despite the proposal of many dietary animal models for NAFLD, none is perfect.² It is very well known that there is considerable heterogeneity among diet-induced NAFLD animal models. For example, it is common for some mice not to develop fatty liver after 12–16

Seung Min Lee <https://orcid.org/0000-0002-7029-1814>Kiseok Jang <https://orcid.org/0000-0002-6585-3990>**Funding**

This research was supported by a grant of the Korea Health Technology R&D Project through the Korea Health Industry Development Institute (KHIDI), funded by the Ministry of Health and Welfare, Republic of Korea (HI17C2262).

Disclosures

The authors have no potential conflicts of interest to disclose.

Author Contributions

Conceptualization: Jun DW, Chae YJ. Data curation: Jun DW, Jang K, Saeed WK. Formal analysis: Chae YJ, Kang HT, Oh JH, Lee SM. Validation: Jun DW, Oh JH. Software: Saeed WK. Writing - original draft: Chae YJ. Writing - review & editing: Jun DW, Jang K.

weeks of a high-fat diet (HFD).³ However, the exact degree of heterogeneity in dietary NAFLD models remains largely unknown.

Ideally, the preclinical animal models should mimic a human clinical trial. Only biopsy-proven NAFLD patients can be included in clinical trials. However, biopsy confirmation is not usually done in preclinical diet-induced NAFLD animal models. Moreover, baseline steatosis, inflammation, and fibrosis degrees should be similar in patients included in clinical trial. Baseline characteristics of conventional diet-induced NAFLD are usually unknown in diet-induced NAFLD animal models since histological confirmation of animal models and randomizations are not performed prior to such studies. Liver biopsy in NAFLD animal studies can apply inclusion and exclusion criteria (e.g., degrees of steatosis and inflammation). Histological assessment before active drug treatment is critical to the mimicking of a human clinical trial setting and improving study quality. Moreover, it allows for the evaluation of individual responses to treatment. Additionally, the animals should be stratified by disease severity. The development of a biopsy-confirmed NAFLD animal model is essential to reducing the uncertainty associated with animal studies.

Few recent studies have used biopsy-proven NAFLD animal models.^{4,5} However, there are no data about model feasibility and stability. The other strength of repeated liver biopsy is its ability to trace disease progression and identify new biomarkers for predicting treatment responses. To the best of our knowledge, the degrees of heterogeneity of diet-induced NAFLD models have never been studied on a large scale and the feasibility and stability of repeated liver biopsy models have never been evaluated.

Here we aimed to investigate the heterogeneity of disease severity in various diet-induced NAFLD animal models and demonstrate the feasibility and stability of repeated liver biopsy used therein.

METHODS

Variation in diet-induced NAFLD models

C57BL/6N mice (8 weeks old, male) were obtained from OrientBio (Seongnam, Korea). The mice were maintained in a temperature-controlled (23°C ± 2°C) and specific-pathogen-free room under a 12 hours light/dark cycle. The histology of 52 HFD (60% kcal fat, 58Y1)-induced NAFLD models was evaluated at 12 weeks (n = 44) and 18 weeks (n = 8). Thirty-five methionine choline-deficiency diet (MCD) (research diets, A02082002B)-induced NAFLD models were evaluated at 8 weeks (n = 6) and 12 weeks (n = 29). One hundred and sixty-six western diet (WD; Research Diets, D12079B)-induced NAFLD models were evaluated at 12 weeks (n = 43) and 17 weeks (n = 123). Body weights were assessed weekly.

Repeated liver biopsy protocol

All surgical instruments were sterilized before the procedure. The mice were anesthetized with an intraperitoneal injection of Zoletil (Virbac Laboratories, Carros, France) and Rompun (Bayer Korea, Seoul, Korea). After being shaved, the abdominal site was disinfected using 10% iodine solution. An abdominal midline incision (< 1 cm long) was made and the liver was carefully exposed using a cotton swab. The obtained liver tissue biopsy specimens were < 3% of the total liver weight and about 0.9 cm long. Immediately thereafter, a heated spatula was applied to the biopsy site to arrest the bleeding (**Fig. 1**). The incision site was sutured with 5-0 synthetic absorbable braided

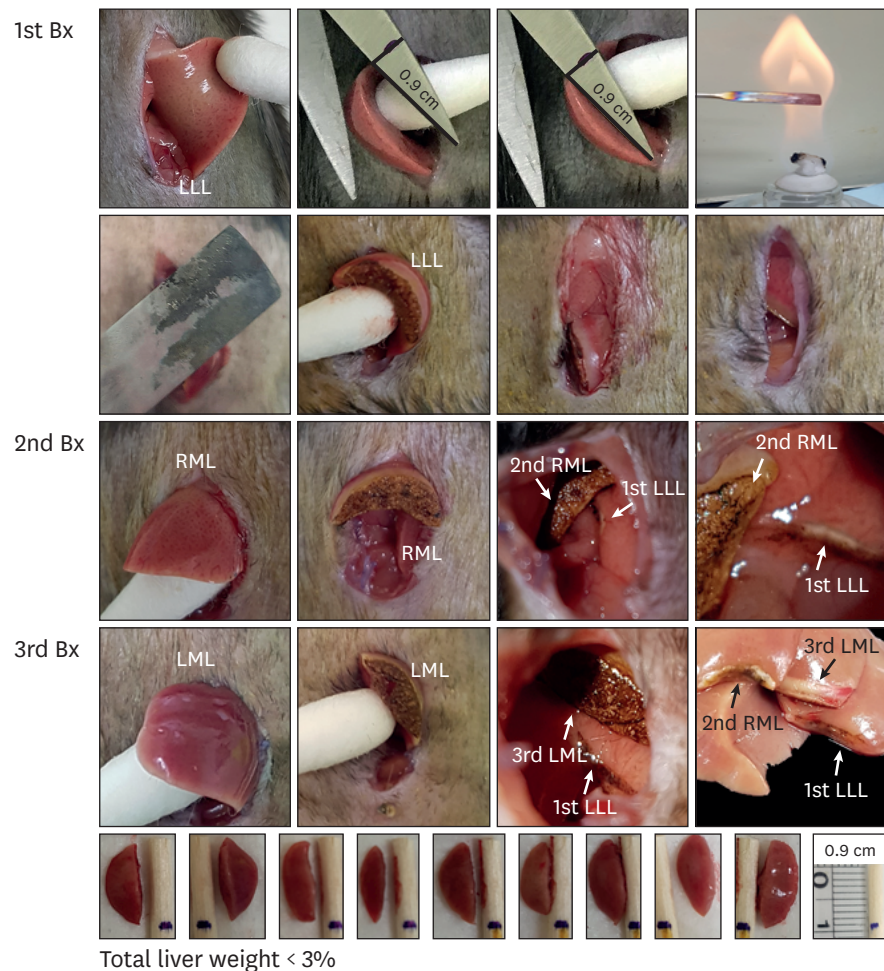


Fig. 1. Multiple liver Bx procedure.
Bx = biopsy, LLL = left lateral lobe, RML = right medial lobe, LML = left medial lobe.

polyglycolic acid sutures. After surgery, the animals were kept warm under a heat lamp and treated with tetracycline in water as an antibiotic for 3 days. Repeated liver biopsies were performed three times during the 3 months of feeding. The liver biopsy sites included distal portions of the left lateral lobe (LLL), right medial lobe (RML), and left medial lobe (LML) (Figs. 1 and 2).

Histological analysis

For hematoxylin and eosin staining, biopsy specimens were fixed in 4% paraformaldehyde, paraffin-embedded, and sectioned (4 μ m). Hematoxylin and eosin-stained liver samples and biopsy specimens were analyzed by a single pathologist, who graded the degrees of steatosis and lobular inflammation. Steatosis was scored as follows: < 5% (score 0); 5%–33% (score 1); > 33%–66% (score 2); > 66% (score 3). Lobular inflammation was graded as follows: no foci (score 0); < 2 foci/200 \times (score 1); 2–4 foci/200 \times (score 2); and > 4 foci/200 \times (score 3).

Feasibly and stability

Body weights and food intakes were measured weekly. Blood samples were collected immediately after the third biopsy and on days 2, 5, and 7 thereafter. Serum alanine aminotransferase and aspartate aminotransferase levels were assessed by an automated chemical analyzer (Hitachi-747; Hitachi, Tokyo, Japan).

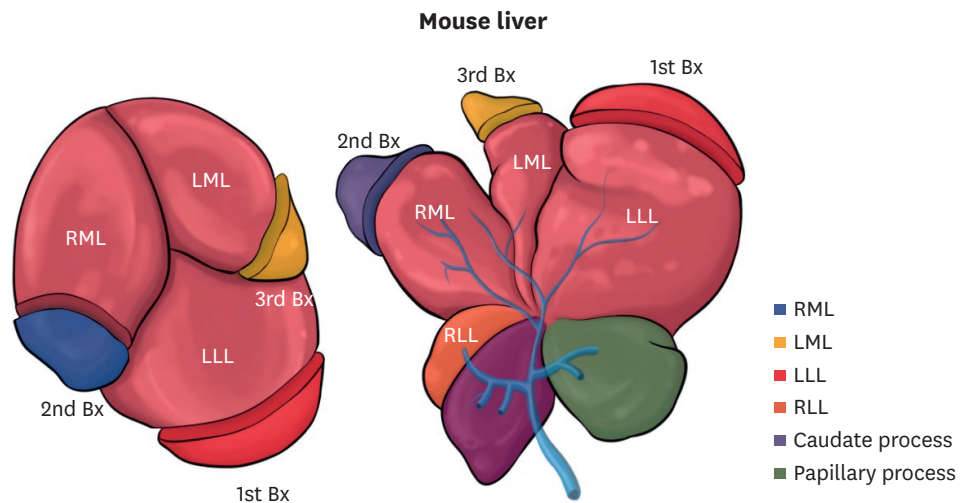


Fig. 2. Anatomic location of repeated liver Bx.
RML = right medial lobe, LML = left medial lobe, LLL = left lateral lobe, RLL = right lateral lobe, Bx = biopsy.

Statistical analysis

The measurements were independently repeated three times and the average values are expressed as mean \pm standard deviation (SD). The statistical analysis was performed using SPSS version 18.0 for Windows (SPSS Inc., Chicago, IL, USA). One-way analysis of variance was performed to compare the means of the different values. *P* values < 0.05 were considered statistically significant.

Ethics statement

All of the experimental protocols were approved by The Hanyang Institutional Animal Care and Use Committee (HY-IACUC-16-0028, HY-IACUC-18-0013). All animals received humane care according to the criteria outlined in the "Guide for the Care and Use of Laboratory Animals."

RESULTS

Histologic heterogeneity of diet-induced NAFLD

Degree of steatosis (grade 0, 14%; grade 1, 20%; grade 2, 20%; and grade 3, 45%) and inflammation (grade 0, 30%; grade 1, 52%; and grade 2, 18%) were quite diverse at 12 weeks in the HF group (**Fig. 3**). Both 8- and 12-weeks MCD diet-fed mice showed a higher steatosis grade than the HFD-fed mice. At 12 weeks, in the MCD group, the degrees of steatosis (grade 1, 21%; grade 2, 24%; and grade 3, 55%) and inflammation (grade 0, 7%; grade 1, 24%; grade 2, 24%; and grade 3, 45%) were quite diverse. Likewise, at 12 weeks in the WD group, the degrees of steatosis (grade 0, 14%; grade 1, 12%; grade 2, 49%; and grade 3, 26%) and inflammation (grade 0, 51%; grade 1, 23%; grade 2, 16%; and grade 3, 9%) were quite diverse. The 17-week WD-fed group also showed heterogeneous steatosis and lobular inflammation scores.

Stability of repeated liver biopsy

The biopsies were performed as shown in **Fig. 1**. For the repeat liver biopsy, we determined the liver fragment's mean size was 0.9 cm and the positions by frequency were LLL, RML, and LML (**Figs. 1 and 2**). The degrees of steatosis and hepatic inflammation progressed with

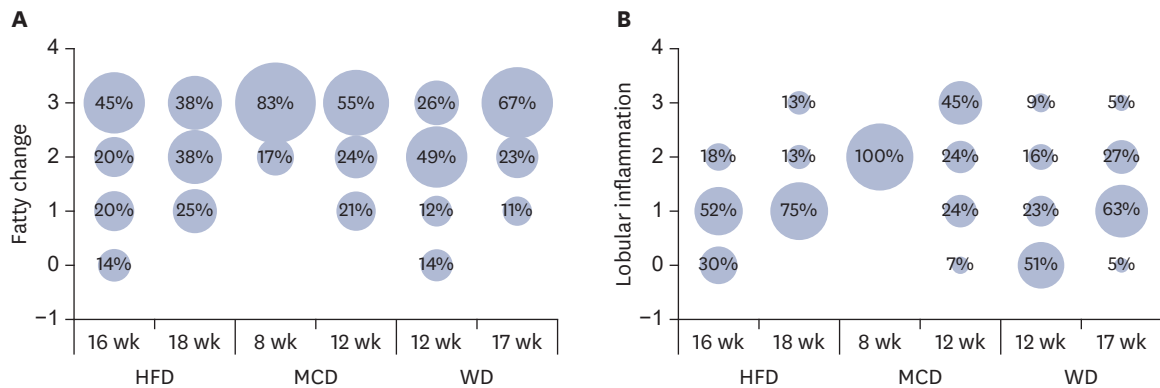


Fig. 3. Variation of the diet-induced NAFLD model. (A, B) The heterogeneity of NAS score in a dietary NAFLD model. The steatosis score and lobular inflammation score evaluated by hematoxylin and eosin staining. HFD for 16 weeks (n = 44), HF for 18 weeks (n = 8). MCD for 8 weeks (n = 6), MCD for 12 weeks (n = 29). WD with fructose (55 g/L final concentration) for 12 weeks (n = 43), WD with fructose (55 g/L final concentration) for 17 weeks (n = 123). Steatosis score (grade: 0–3); lobular inflammation score (grade: 0–3). NAFLD = nonalcoholic fatty liver disease, NAS = nonalcoholic fatty liver disease activity score, NC = normal chow, HFD = high-fat diet 60%, MCD = methionine choline-deficient diet, WD = western diet.

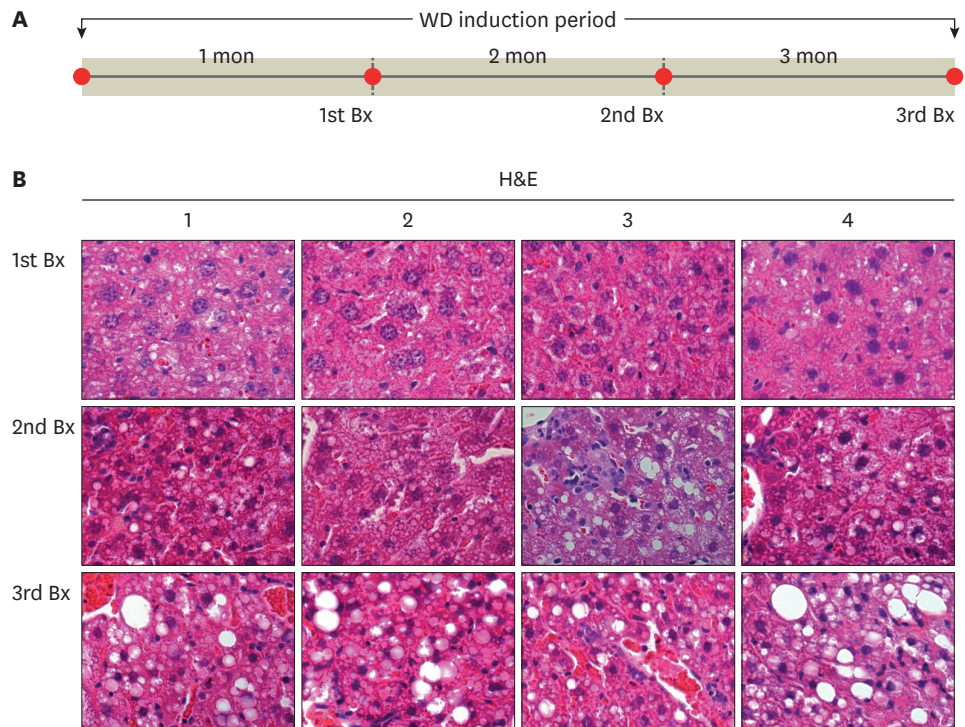


Fig. 4. Tracing disease progression using repeated liver Bx. (A) Timing of multiple liver biopsies. (B) Changes in intrahepatic fat accumulation and inflammation by time. Bx = biopsy, WD = western diet.

time (Fig. 4). Overall, 123 mice underwent biopsy. Two mice died for a mortality rate of 1.62%. Nonalcoholic fatty liver activity score (NAS) was < 2 points in 27 (21.9%) of 123 WD mice. The serum alanine aminotransferase and aspartate aminotransferase levels were evaluated to assess liver damage after the third biopsy but had not increased in the normal chow (NC) and WD groups on days 2, 5, and 7 after biopsy (Fig. 5). Hepatic steatosis and inflammation increased with time. Although the mean body weight slightly decreased after biopsy, the difference was not statistically significant on a linear mixed-effects model (Fig. 5A). Body weight steadily increased during the experiment period showing statistically significant differences.

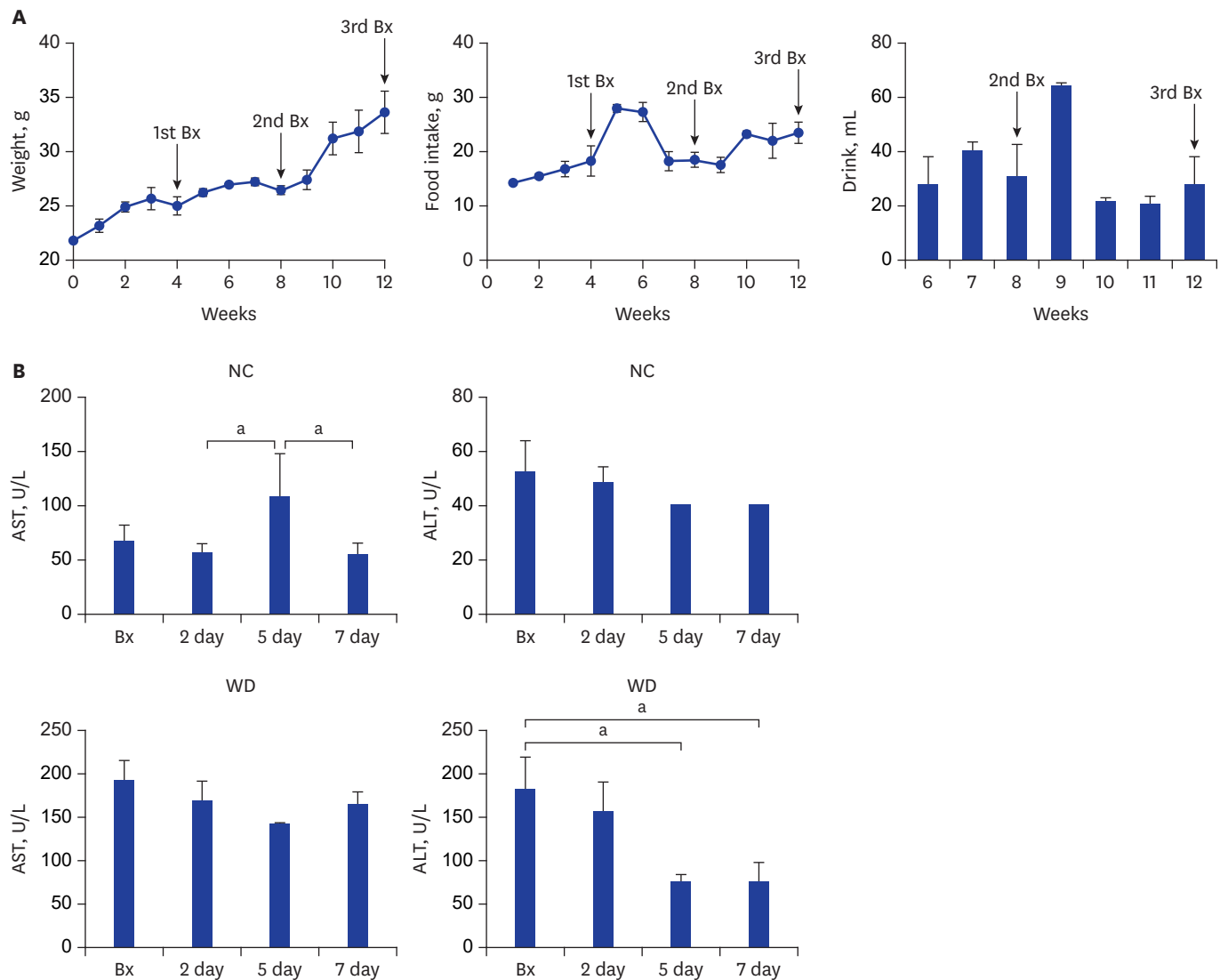


Fig. 5. Changes in body weight, food intake, and liver enzyme during repeated liver Bx. **(A)** Changes in body weight and food intake. **(B)** Changes in hepatic enzymes.

Bx = biopsy, NC = normal chow, WD = western diet.

*P < 0.05.

Tracking liver resection margin

Changes in biopsy resection margins were traced over time. The animals were sacrificed at 2, 5, and 7 days as well as at 1 and 2 months after liver biopsy for evaluation of the changes in biopsy margins (Fig. 6). After 2 and 5 days, a necrotic area and inflammatory cells were observed in the biopsy resection margins. After 7 days, the inflammatory cell counts were reduced and fat was observed in the necrotic area. After 1 month, the necrotic area was decreased. After 2 months, the necrotic area and inflammation in the resection margins had disappeared completely.

Effects of repeated resection on other lobes

Next, we investigated whether liver resection or anesthesia could cause inflammation in the other liver lobes. After the liver resection, we performed an autopsy on the remaining four sites (LLL containing the first biopsy resection margin, portal vein side of the LLL, RML,

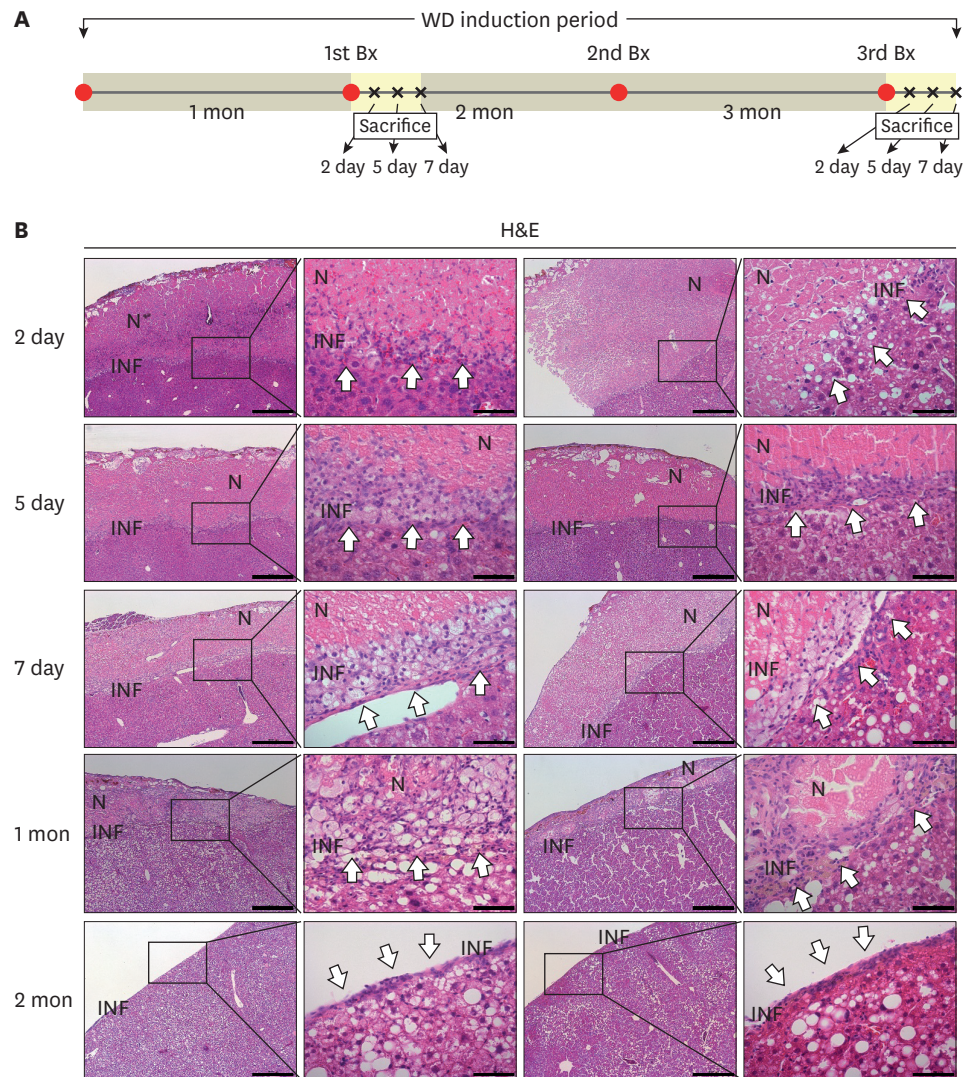


Fig. 6. Tracing changes of resection margins. **(A)** To trace resection margins, autopsies were performed on days 2, 5, and 7. **(B)** Hematoxylin and eosin staining was performed to determine that the hemorrhage caused by the heated spatula caused damage to the liver and then recovered. The arrow indicates inflammatory cells. Magnification: 50× and 400×. Bx = biopsy, WD = western diet, N = necrosis, INF = inflammatory cell.

and LML) at 2, 5, and 7 days (**Fig. 7A**). The collected liver specimens for damage assessment included the following: first section, area of the first biopsy; second section, from the LLL containing the first biopsy resection margins; third section, from the portal vein part of the LLL, which is usually the site for liver sampling; fourth section, RML; and fifth section, LML. Repeated liver biopsy did not affect the degrees of inflammation and steatosis of the other liver lobes (**Fig. 7B**).

DISCUSSION

Heterogeneity in the histological findings was considerable in these diet-induced NAFLD models. Twenty percent of the diet-induced NAFLD models did not develop steatohepatitis ($NAS \leq 2$ points). Thus, the use of repeated liver biopsy in this NAFLD animal model was

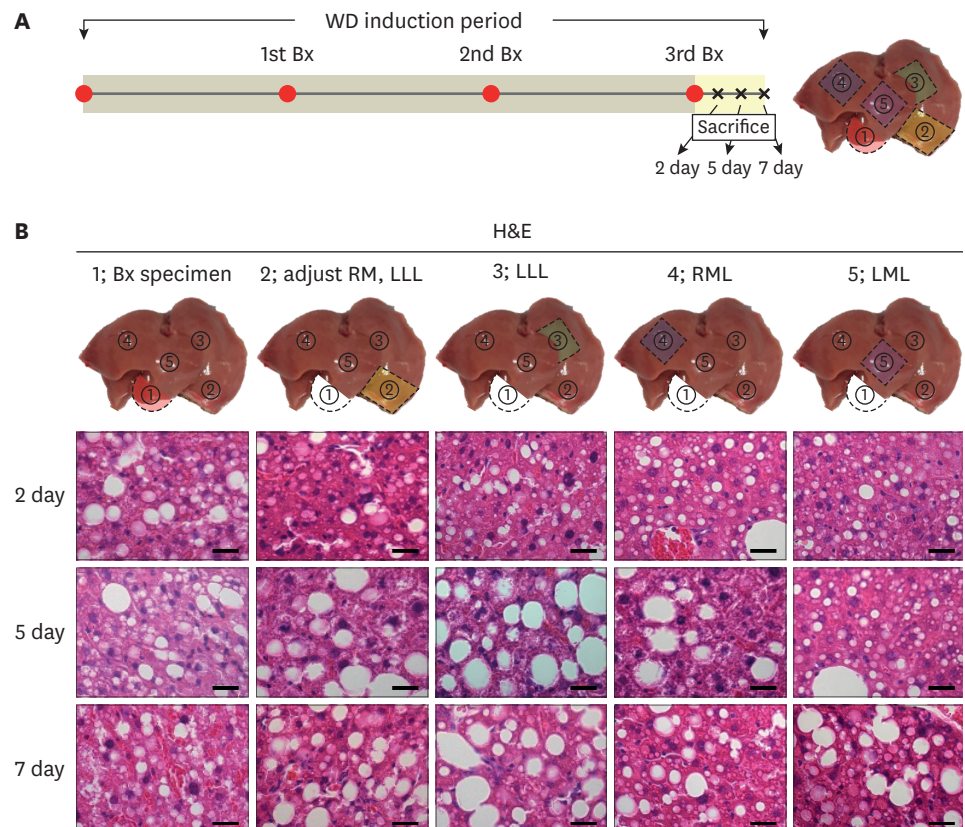


Fig. 7. Intrahepatic inflammation of remnant liver during repeated liver Bx. **(A)** To assess the effects of repeated liver Bx on remnant disease liver, autopsies were performed on days 2, 5, and 7 to collect samples from five sites. **(B)** Hematoxylin and eosin staining showed that the inflammation score does not differ among the five remnant lobes. Bx = biopsy, WD = western diet, RM = resection margin, LLL = left lateral lobe, RML = right medial lobe, LML = left medial lobe.

feasible and stable. The overall mortality rate was 1.6%, and the changes in body weight, dietary intake, and liver enzymes were transient after the third liver biopsy.

A previous cohort showed that the NAFLD phenotypes vary quite widely among murine species.⁶⁻⁸ Around 30% of the animals did not develop sufficient hepatic inflammation and fibrosis.⁹ However, the exact percentages of NAFLD animal model failure and inadequacy remain largely unknown. In our study, we used three kinds of diet-induced NAFLD models. Heterogeneity in the histologic findings was lower in the MCD model than in the other models. Our findings were quite comparable to those of a previous report.¹⁰ Although the MCD model induced weight loss and did not cause insulin resistance, a key pathophysiologic risk factor for NAFLD,¹¹ it is a very reproducible model. The WD model with enriched cholesterol and fructose showed more severe hepatic steatosis and hepatic inflammation than the HFD model in this study, but the heterogeneity of disease severity was considerable.

Our repeated biopsy model can mimic the clinical trial setting in NAFLD animal studies. The use of liver biopsy before the intervention can balance the basic characteristics between the control and active arms. Its use can involve the application of inclusion and exclusion criteria as in human clinical trials. Our data showed that 21.9% of the 17-week WD animal models had a NAS of < 2 points. Additionally, the use of liver biopsy before the intervention

can help with the identification of biomarkers to identify responders versus non-responders using the baseline liver tissue and serum samples. Human NAFLD shows a very heterogeneous spectrum. Although many candidate chemicals has been applied in NAFLD, the resolution rate of nonalcoholic steatohepatitis was < 50%.¹²⁻¹⁶ Thus, it is very important to select subjects who are expected to have a good response. Although preclinical NAFLD animal models are homogenous entities compared to humans, not all animals respond to candidate chemicals. Metabolomic or RNA sequencing data from the pre-treatment liver tissue can be used to identify new biomarkers to predict good responders to candidate chemicals. Comprehensive data from pre-treated liver tissues facilitate our understanding of the mode of action and identify optimal target population. Metabolomic and (micro/long non-coding) RNA sequencing tests using pre-treatment liver tissue will facilitate the development of new prognostic biomarkers for certain target drugs. The use of liver biopsy before the intervention can help with following up on individual histological changes from the baseline point (pre) to the study end (post). Finally, a repeated liver biopsy can track the effects of the target drug.

Several investigators recently attempted to perform a biopsy to match the NAFLD severity in models between the experimental groups.^{4,7} However, a standard protocol for biopsy-confirmed NAFLD model as well as its safety and reproducibility data were unavailable but necessary. To the best of our knowledge, this is the first study to clarify the feasibility and stability of repeated liver biopsy. We suggested the exact biopsy site, sample size, and antibiotic use duration. Moreover, we also evaluated the possible unexpected effects of repeated biopsy on the other lobes. Although our protocol seemed generally safe, liver biopsy can cause transient inflammation, pain-induced starvation, or weight reductions in animal models. Thus, careful observation after liver tissue biopsy is necessary.

There were several limitations to this study. First, we used a short-term antibiotic duration. Antibiotic treatment can affect the microbiome and be a limitation for microbiota studies. Second, although we carefully investigated changes in intrahepatic inflammation in the remnant disease lobes (Fig. 6), sham-operated control group is also needed to investigate the safety of repeated liver biopsy and its effect on the remnant liver. Moreover, transaminase, bilirubin, and albumin levels are important. Unfortunately, we did not analyze changes in synthetic function (albumin and bilirubin). Third, various strains of mice contribute to an individual's susceptibility to developing hepatosteatosis. Although A/J mice showed insulin resistance and hypercholesterolemia during HFD treatment, glucose levels remained normal.¹⁷ BALB/c mice showed resistance to developing fatty liver and insulin resistance.¹⁸ Thus, use of C57BL/6 strain mice is generally preferred because of their intrinsic predilection to develop steatosis under HFD treatment.¹⁹ C57BL/6J and C57BL/6N are the most widely used mice in animal studies. C57BL/6J mice showed the deletion of several functional genes (nicotinamide nucleotide transhydrogenase) and different patterns of single-nucleotide polymorphism compared to C57BL/6N mice.²⁰ C57BL/6J mice showed moderately impaired glucose metabolism compared to C57BL/6N.²¹ We used BL/6N mice for all experimental periods. Thus, our findings might be limited to C57BL/6N mice. Further studies including various murine strains are needed to verify our findings.

Our findings suggest that this repeated liver biopsy model was applicable in this NAFLD animal study. Biopsy-proven NAFLD is clinically feasible and can be applied in preclinical drug testing studies.

REFERENCES

1. Kang Y, Park S, Kim S, Koh H. Estimated prevalence of adolescents with nonalcoholic fatty liver disease in Korea. *J Korean Med Sci* 2018;33(14):e109.
[PUBMED](#) | [CROSSREF](#)
2. Santhekadur PK, Kumar DP, Sanyal AJ. Preclinical models of non-alcoholic fatty liver disease. *J Hepatol* 2018;68(2):230-7.
[PUBMED](#) | [CROSSREF](#)
3. Lee JS, Jun DW, Kim EK, Jeon HJ, Nam HH, Saeed WK. Histologic and metabolic derangement in high-fat, high-fructose, and combination diet animal models. *Sci World J* 2015;2015:306326.
[PUBMED](#) | [CROSSREF](#)
4. Kristiansen MN, Veidal SS, Rigbolt KT, Tølbøl KS, Roth JD, Jelsing J, et al. Obese diet-induced mouse models of nonalcoholic steatohepatitis-tracking disease by liver biopsy. *World J Hepatol* 2016;8(16):673-84.
[PUBMED](#) | [CROSSREF](#)
5. Tølbøl KS, Kristiansen MN, Hansen HH, Veidal SS, Rigbolt KT, Gillum MP, et al. Metabolic and hepatic effects of liraglutide, obeticholic acid and elafibranor in diet-induced obese mouse models of biopsy-confirmed nonalcoholic steatohepatitis. *World J Gastroenterol* 2018;24(2):179-94.
[PUBMED](#) | [CROSSREF](#)
6. Farrell GC, Mridha AR, Yeh MM, Arsov T, Van Rooyen DM, Brooling J, et al. Strain dependence of diet-induced NASH and liver fibrosis in obese mice is linked to diabetes and inflammatory phenotype. *Liver Int* 2014;34(7):1084-93.
[PUBMED](#) | [CROSSREF](#)
7. Clapper JR, Hendricks MD, Gu G, Wittmer C, Dolman CS, Herich J, et al. Diet-induced mouse model of fatty liver disease and nonalcoholic steatohepatitis reflecting clinical disease progression and methods of assessment. *Am J Physiol Gastrointest Liver Physiol* 2013;305(7):G483-95.
[PUBMED](#) | [CROSSREF](#)
8. Haczeyni F, Poekes L, Wang H, Mridha AR, Barn V, Geoffrey Haigh W, et al. Obeticholic acid improves adipose morphometry and inflammation and reduces steatosis in dietary but not metabolic obesity in mice. *Obesity (Silver Spring)* 2017;25(1):155-65.
[PUBMED](#) | [CROSSREF](#)
9. Hansen HH, Feigh M, Veidal SS, Rigbolt KT, Vrang N, Fosgerau K. Mouse models of nonalcoholic steatohepatitis in preclinical drug development. *Drug Discov Today* 2017;22(11):1707-18.
[PUBMED](#) | [CROSSREF](#)
10. Itagaki H, Shimizu K, Morikawa S, Ogawa K, Ezaki T. Morphological and functional characterization of non-alcoholic fatty liver disease induced by a methionine-choline-deficient diet in C57BL/6 mice. *Int J Clin Exp Pathol* 2013;6(12):2683-96.
[PUBMED](#)
11. Machado MV, Cortez-Pinto H. Non-alcoholic fatty liver disease: what the clinician needs to know. *World J Gastroenterol* 2014;20(36):12956-80.
[PUBMED](#) | [CROSSREF](#)
12. Armstrong MJ, Gaunt P, Aithal GP, Barton D, Hull D, Parker R, et al. Liraglutide safety and efficacy in patients with non-alcoholic steatohepatitis (LEAN): a multicentre, double-blind, randomised, placebo-controlled phase 2 study. *Lancet* 2016;387(10019):679-90.
[PUBMED](#) | [CROSSREF](#)
13. Lassailly G, Caiazzo R, Buob D, Pigeyre M, Verkindt H, Labreuche J, et al. Bariatric surgery reduces features of nonalcoholic steatohepatitis in morbidly obese patients. *Gastroenterology* 2015;149(2):379-88.
[PUBMED](#) | [CROSSREF](#)
14. Neuschwander-Tetri BA, Loomba R, Sanyal AJ, Lavine JE, Van Natta ML, Abdelmalek MF, et al. Farnesoid X nuclear receptor ligand obeticholic acid for non-cirrhotic, non-alcoholic steatohepatitis (FLINT): a multicentre, randomised, placebo-controlled trial. *Lancet* 2015;385(9972):956-65.
[PUBMED](#) | [CROSSREF](#)
15. Ratziu V, Harrison SA, Francque S, Bedossa P, Leher P, Serfaty L, et al. Elafibranor, an agonist of the peroxisome proliferator-activated receptor-alpha and -delta, induces resolution of nonalcoholic steatohepatitis without fibrosis worsening. *Gastroenterology* 2016;150(5):1147-1159.e5.
[PUBMED](#) | [CROSSREF](#)
16. Sanyal AJ, Chalasani N, Kowdley KV, McCullough A, Diehl AM, Bass NM, et al. Pioglitazone, vitamin E, or placebo for nonalcoholic steatohepatitis. *N Engl J Med* 2010;362(18):1675-85.
[PUBMED](#) | [CROSSREF](#)

17. Gallou-Kabani C, Vigé A, Gross MS, Rabès JP, Boileau C, Larue-Achagiotis C, et al. C57BL/6J and A/J mice fed a high-fat diet delineate components of metabolic syndrome. *Obesity (Silver Spring)* 2007;15(8):1996-2005.
[PUBMED](#) | [CROSSREF](#)
18. Tessitore A, Ciccirelli G, Del Vecchio F, Gaggiano A, Verzella D, Fischietti M, et al. MicroRNA expression analysis in high fat diet-induced NAFLD-NASH-HCC progression: study on C57BL/6J mice. *BMC Cancer* 2016;16(1):3.
[PUBMED](#) | [CROSSREF](#)
19. Takahashi Y, Soejima Y, Fukusato T. Animal models of nonalcoholic fatty liver disease/nonalcoholic steatohepatitis. *World J Gastroenterol* 2012;18(19):2300-8.
[PUBMED](#) | [CROSSREF](#)
20. Mekada K, Abe K, Murakami A, Nakamura S, Nakata H, Moriwaki K, et al. Genetic differences among C57BL/6 substrains. *Exp Anim* 2009;58(2):141-9.
[PUBMED](#) | [CROSSREF](#)
21. Toye AA, Lippiat JD, Proks P, Shimomura K, Bentley L, Hugill A, et al. A genetic and physiological study of impaired glucose homeostasis control in C57BL/6J mice. *Diabetologia* 2005;48(4):675-86.
[PUBMED](#) | [CROSSREF](#)