



Arthroscopic Lateral Meniscal Allograft Transplantation With the Key-Hole Technique

Dhong Won Lee, M.D., Jung Ho Park, M.D., Kyu Sung Chung, M.D., Jeong Ku Ha, M.D., and Jin Goo Kim, M.D., Ph.D.

Abstract: The efficacy of meniscus allograft transplantation (MAT) for the meniscus-deficient knee has been widely recognized as being excellent in terms of pain relief and functional improvement. Lateral MAT is usually performed with the bone bridge technique that uses a bone bridge connecting the anterior and posterior horns of an allograft. The slot position for the meniscal graft insertion is of great importance with the bone bridge technique, especially in the key-hole method. The purpose of this Technical Note is to describe lateral MAT using the key-hole technique in which an allograft with a bone bridge carved to accommodate the key-hole-shaped slot is properly secured to the slot.

Since the clinical results were reported after meniscal allograft transplantation (MAT) in 1989, numerous biomechanical, clinical studies about MAT have been published.¹⁻⁵ MAT has been widely performed after total or subtotal meniscectomy in relatively young patients, and has been shown to reduce pain, improve function, and potentially delay the progression of cartilage degeneration.⁶⁻⁹

Even though there are several graft fixation methods, it is known that bone fixation is superior to soft tissue fixation.¹⁰⁻¹³ Lateral MAT is usually performed with the bone bridge technique, because the anterior and posterior horns of the lateral meniscus are close to each other and there is a risk of tunnel communication in the bone plug technique using 2 tibial tunnels.^{11,14,15}

The slot position is of great importance with the bone bridge technique, especially in the key-hole method to

restore the anatomic footprints of the anterior and posterior roots of the lateral meniscus. We describe the effective surgical technique of arthroscopic lateral MAT using the key-hole technique to secure the meniscal allograft to the slot and the peripheral rim properly ([Video 1](#)).

Surgical Technique

The surgical indications are shown in [Table 1](#). [Table 2](#) describes the pitfalls and tips of the present technique.

Intra-articular Preparation and Skin Incision

An arthroscope is introduced through the antero-lateral portal, and a thorough examination is performed. The remnant meniscus is resected leaving 1 to 2 mm of bleeding peripheral rim, and the exact anterior and posterior root footprints are marked using an electrocautery (ArthroCare, Austin, TX). After diagnostic arthroscopy, a 4-cm longitudinal arthrotomy is made just lateral to the lateral border of the patellar tendon in line with the previous anterolateral portal. Then, a vertical incision is made using a routine posterolateral approach to expose the posterolateral capsule releasing from the lateral head of the gastrocnemius, and to repair the lateral meniscal allograft avoiding neurovascular injury. An elevator is used to release soft tissue adhesion between the anterolateral and posterolateral side to make the same interval.

Tibial Slot Preparation

The centers of the anterior and posterior root attachment sites are connected with a line using an electrocautery. With this line as a guide, a guide pin is inserted in the anteroposterior direction under the

From the Department of Orthopedic Surgery, Konkuk University Medical Center (D.W.L., J.H.P., J.G.K.); Department of Orthopedic Surgery, KEPCO Medical Center (K.S.C.); and Department of Orthopedic Surgery, Inje University Seoul Paik Hospital (J.K.H.), Seoul, Republic of Korea.

The authors report that they have no conflicts of interest in the authorship and publication of this article. Full ICMJE author disclosure forms are available for this article online, as [supplementary material](#).

Received March 29, 2017; accepted June 29, 2017.

Address correspondence to Jin Goo Kim, M.D., Ph.D., Department of Orthopedic Surgery, Konkuk University Medical Center, 120-1, Neungdong-ro, Gwangjin-gu, Seoul 143-729, Republic of Korea. E-mail: boram107@hanmail.net

© 2017 by the Arthroscopy Association of North America. Published by Elsevier. Open access under [CC BY-NC-ND license](#).

2212-6287/17422

<http://dx.doi.org/10.1016/j.eats.2017.06.057>

Table 1. Lateral Meniscal Allograft Transplantation Indications

Indications
Age: between 20 and 45 yr
Body mass index <30
Symptomatic knee more than 6 mo after previous total or subtotal meniscectomy
Outerbridge classification of less than grade III, repairable focal grade 4
Kellgren-Lawrence grade I or II, some salvage cases for grade III
Symmetric alignment (<3°)
Ability to endure a relatively high-demand activity

lateral eminence of the tibial articular surface, and approximately 15° above the tibial slope (Fig 1). The guide pin inserted is confirmed to be positioned at approximately 8 mm under the articular surface of the lateral tibial plateau using C-arm fluoroscopy. After the guide pin, a 10-mm reamer (Arthrex, Naples, FL) is inserted to create a tibial hole (Fig 2). Then, a key-hole-shaped slot is made using our customized osteotome and dilator (Cellumed, Seoul, Republic of Korea) via the previous tibial hole (Fig 3). Beveling is arthroscopically performed at the posterior root area of the slot with a pituitary rongeur to achieve stable fitting of the allograft (Fig 4). Through an anterior arthrotomy, 2 suture passing wires with the loop positioned posteriorly for the leading suture for traction are passed through the posterolateral capsule in an inside-to-out fashion at superior and inferior of the remnant meniscus, and the ends of the suture passing wires are held by Kelly clamps (Fig 5).

Graft Preparation

Fresh-frozen and nonirradiated grafts are used in all cases, and graft size is determined preoperatively on anteroposterior and lateral radiographs with a

Table 2. Pitfalls and Tips for Lateral Meniscal Allograft Transplantation With the Key-Hole Technique

Pitfalls
1. Misplaced bone tunnel can cause allograft subluxation or cartilage damage.
2. The lateral posterior slope is different from the medial posterior slope because the lateral side has a more inclination than the medial side.
3. With the key-hole method, care should be taken to fix the posterior part of the bone bridge suitably.
Tips
1. The slot should not be either laterally or medially centered for the anatomic position.
2. The slot is placed 15° higher on the sagittal plane than the horizontal surface of the tibial plateau.
3. Our instruments designed to make a key-hole-shaped slot help the slot to be smoothed and refined.
4. Stable fixation is achieved through beveling at the posterior horn area of the slot with a pituitary rongeur.

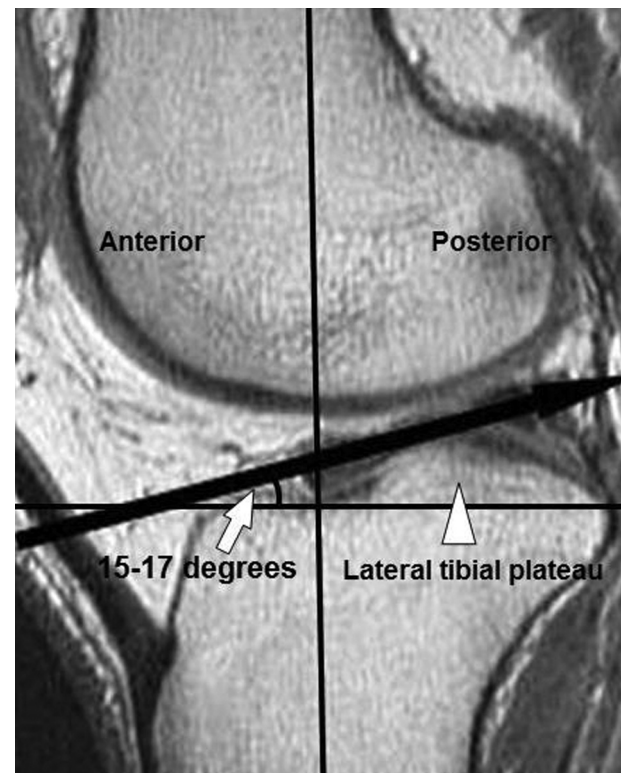


Fig 1. Magnetic resonance imaging of the right knee shows that tibial slope measurement is ranged from approximately 15° to 17° (white arrow) on the lateral side. The white arrow indicates the lateral tibial plateau.

scanogram for correction of magnification, as described in a previous paper.¹⁶ This modified method of measurement suggested that reducing the graft size by 5% using the method by Pollard et al.¹⁷ decreases the percentage of meniscal extrusion after MAT without any adverse outcome clinically or radiographically.¹⁶ The bone bridge that has a key-hole-shaped bone block is carved to match with the key-hole-shaped slot using a microsaw, rongeur, and burr on a back table. The posterior leading suture is placed 10 mm laterally from the posterior root for later traction and spreading using No. 2 Ethibond (Fig 6).

Allograft Insertion and Fixation

The graft, with the leading suture connected to the loop of each suture passing wire, is inserted into the joint through the anterior arthrotomy by pulling out the opposite side of the loop of the suture passing wire. The bone bridge is advanced into the key-hole-shaped slot, and the allograft is manually reduced under the condyle with a finger introduced via the arthrotomy under traction of the posterior leading suture through the capsule; finally, the whole lateral meniscus allograft is spread evenly (Fig 7). Occasionally, graft passage is facilitated by applying varus stress with the figure four position. Once the meniscal allograft is reduced, the knee is cycled 20 times to achieve its proper placement.

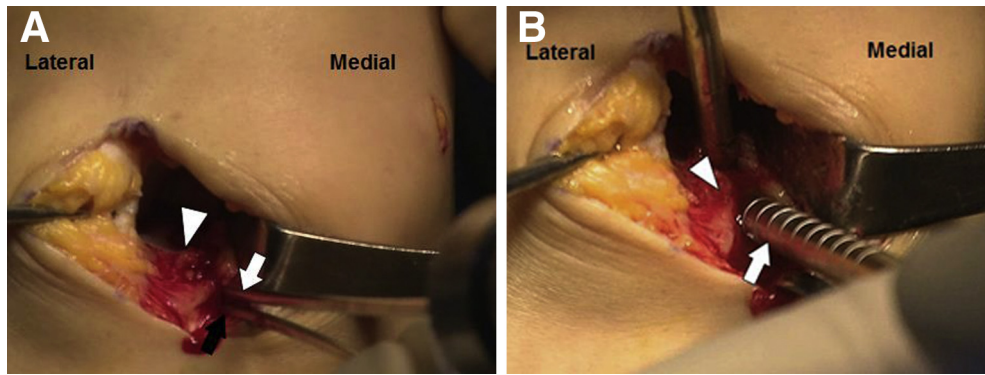


Fig 2. (A) On the right knee, the guide pin (white arrow) inserted is confirmed to be positioned at approximately 8 mm under the articular surface (white arrowhead) of the lateral tibial plateau followed by the previous pin (black arrow) as a reference. (B) After the guide pin, a 10-mm reamer (white arrow) is inserted to make the tibial hole. The white arrowhead describes the articular surface of the lateral tibial plateau.

Viewing from the anterolateral portal, the posterior one-third and middle horn are repaired with 2 superior and 1 inferior obliquely arranged sutures in an inside-out fashion with double-armed needles containing nonabsorbable suture materials. Then, the leading sutures are tied on the capsule. This repair procedure allows the allograft to secure to the remnant meniscus and the capsule firmly. The anterior one-third is repaired with 3 or 4 direct sutures using No. 2 polydioxanone (Ethicon, Somerville, NJ) through the anterior arthrotomy in an outside-in fashion. Once graft fixation is confirmed with arthroscopy, the sutures are ligated. A final arthroscopic evaluation is performed to confirm the fixed posterior and anterior roots and tension of the entire lateral meniscus (Fig 8).

Discussion

The purpose of this Technical Note is to describe an arthroscopic lateral MAT with a key-hole technique.

In carefully selected patients, MAT can restore nearly normal anatomy and biomechanics, provide successful pain relief, and improve function.^{6,7,17} A recent systematic review for MAT concluded that MAT successfully improved symptoms, function, and quality of life at 7 to 14 years of follow-up (Level IV evidence), and the overall failure rate is 10% to 29% at long-term follow-up.⁷ Kim et al.¹⁸ reported that the 10-year survival rate was 98.0% (95% confidence interval, 94.1%-100%), and the 15-year survival rate was 93.3% (95% confidence interval, 83.7%-100%) according to the Kaplan-Meier analysis after MAT.

In MAT, bone fixation better restores contact mechanics than soft tissue fixation, although there are no differences in pullout strength or functional results, and soft tissue fixation has more risk of graft extrusion than bone fixation.⁹ Even though soft tissue fixation alone is technically easier, several studies have reported that load transmission is superior when the graft is secured with bone fixation.^{11,19} In addition, Sekiya et al.²⁰

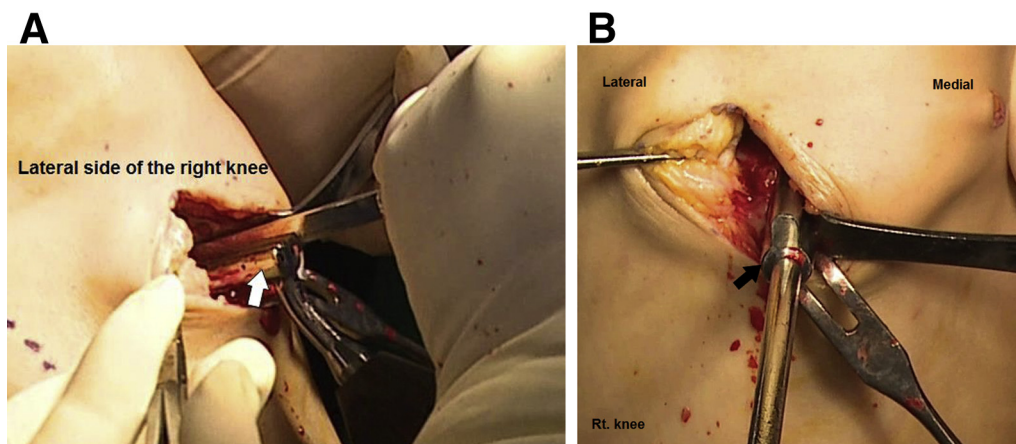


Fig 3. The key-hole-shaped slot for the lateral meniscal allograft is created using our customized osteotome (A, white arrow) and dilator (B, black arrow) via the previous tibial hole on the right knee.

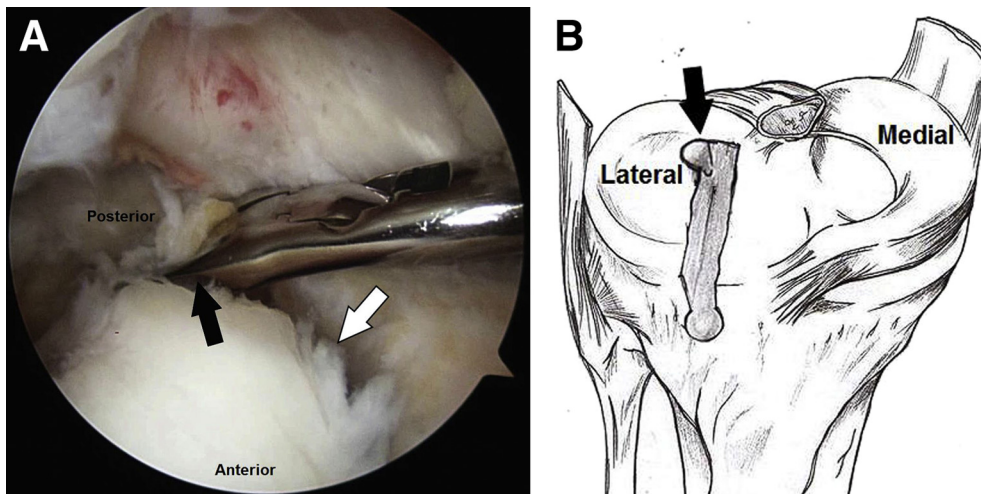


Fig 4. (A) Beveling is performed at the posterior horn area (black arrow) of the slot (white arrow) with a pituitary rongeur via the anteromedial portal to promote a stable fitting of the right lateral meniscal allograft viewing from the anterolateral portal. (B) Schema of the beveling at the posterior horn area (black arrow) of the key-hole-shaped slot for the lateral meniscus allograft on the right knee.

showed that the bony fixation group obtained significantly better range of motion than the suture fixation group at the final follow-up.

The medial and lateral menisci have distinct anatomic characteristics; the anterior and posterior horns of the lateral meniscus have a short distance between them, and there is a risk of tunnel communication in the bone plug technique using 2 tibial tunnels.^{11,14,15} Hence, lateral MAT has been preferred to perform the bone bridge technique that connects the anterior and posterior horns.^{14,17,18} There are several methods of the bone bridge technique including bone trough, key-hole, and dovetail techniques according to the

configuration of the bone block and the tibial slot.^{6,7,17} Kim et al.¹⁸ suggested that the key-hole technique that provides firm press fit has superior stability even without pulling out sutures through the bone block to the proximal tibia than the bone trough technique. Regardless of the techniques, the tibial slot position is of great importance with the bone bridge technique, especially with the key-hole method.^{21,22} Anatomic placement of the meniscal allograft, especially of the anterior and posterior roots, is decisive for restoring biomechanics and improving longevity of the allograft (Table 2).^{11,22,23} A laterally centered slot would cause meniscal allograft subluxation as in the case of an oversized allograft, which leads to articular cartilage wear, whereas a medially centered slot would cause increased tension as in the case of an undersized

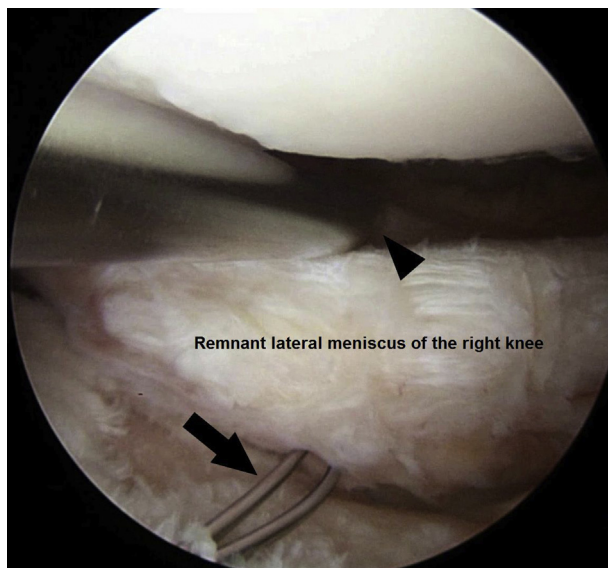


Fig 5. Two suture passing wires for the leading suture are passed through the posterolateral capsule in an inside-to-out fashion via the anteromedial portal at superior (black arrowhead) and inferior (black arrow) of the right remnant lateral meniscus viewing from the anterolateral portal.

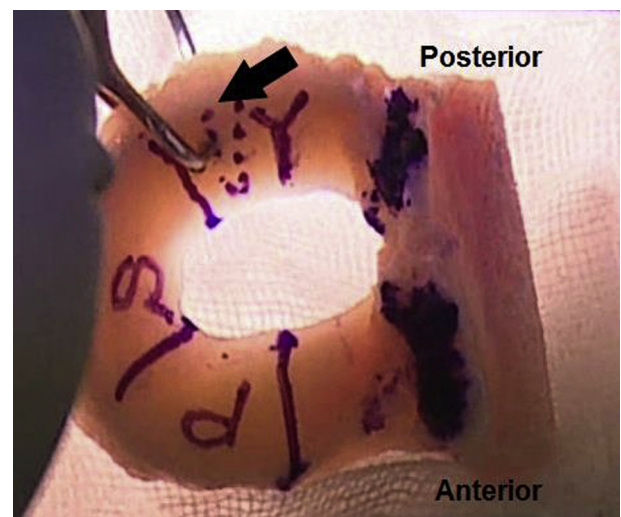


Fig 6. The posterior leading suture (black arrow) is placed 10 mm laterally from the posterior root of the right lateral meniscal allograft.

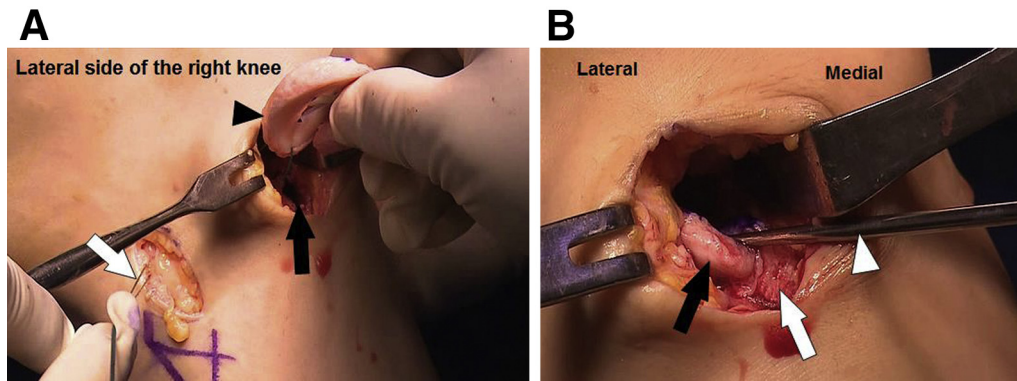


Fig 7. (A) The bone bridge of the lateral meniscal allograft (black arrowhead) is advanced into the slot (black arrow) under traction of the posterior leading suture (white arrow) through the capsule on the right knee. (B) After the bone bridge (white arrow) of the lateral meniscal allograft (black arrow) is manually fitted via the arthrotomy under traction of the posterior leading suture, the whole medial meniscus allograft is spread evenly using the probe (white arrowhead).

allograft and could cause damage to the anterior cruciate ligament origin during drilling or beveling.^{21,22,24} Sekaran et al.²⁵ revealed the nonanatomic placement of the posterior horn over 5 mm compared with the anatomic position that significantly altered the contact pressure, which may affect the ability to prevent cartilage degeneration. Choi et al.²² reported that the nonanatomic placement of the bone bridge was the main cause of midbody extrusion, and the midbody of the meniscal allograft would increase according to the degree of lateral placement of the bone bridge. They showed that the more closely the center of the bone bridge approached half of the whole tibial plateau, the less extrusion of the midbody occurred.²² Kim et al.²³ supported that the relative anatomic

positions of the anterior and posterior horns compared with the preoperative positions showed a mean change of less than 5 mm of absolute values and less than 5% of relative values in both the coronal and sagittal planes on magnetic resonance imaging after lateral MAT with the key-hole technique. However, they warned that the posterior horn could be slightly displaced more laterally in the coronal plane, because there is poor visualization of the posterior part, and interference by the guide and the posterior cruciate ligament made it difficult to place the guide medially.²³ Differences in tibial posterior slope measurement are ranged from 15° to 17° on the lateral side, and from 5° to 7° on the medial side on the sagittal plane.²⁶ Accordingly, the guide pin would be targeted to approximately 15° higher than the horizontal surface of the tibial plateau during slot preparation (Table 2).²¹ We performed beveling at the posterior horn area of the slot with a pituitary rongeur trying to achieve more anatomic and stable fitting of the allograft (Table 2).

In conclusion, lateral MAT with the key-hole technique described here is an effective technique to restore relatively normal anatomy of the lateral meniscus and could be a curative procedure to delay articular cartilage degeneration.

References

1. Hannon MG, Ryan MK, Strauss EJ. Meniscal allograft transplantation a comprehensive historical and current review. *Bull Hosp Jt Dis* (2013) 2015;73:100-108.
2. Moens K, Dhollander A, Moens P, et al. Meniscal transplantation: Still experimental surgery? A review. *Acta Orthop Belg* 2014;80:403-413.
3. Oh KJ, Sobti AS, Yoon JR, Ko YB. Current status of second-look arthroscopy after meniscal allograft transplantation: Review of the literature. *Arch Orthop Trauma Surg* 2015;135:1411-1418.
4. Rongen JJ, Hannink G, van Tienen TG, van Luijk J, Hooijmans CR. The protective effect of meniscus allograft

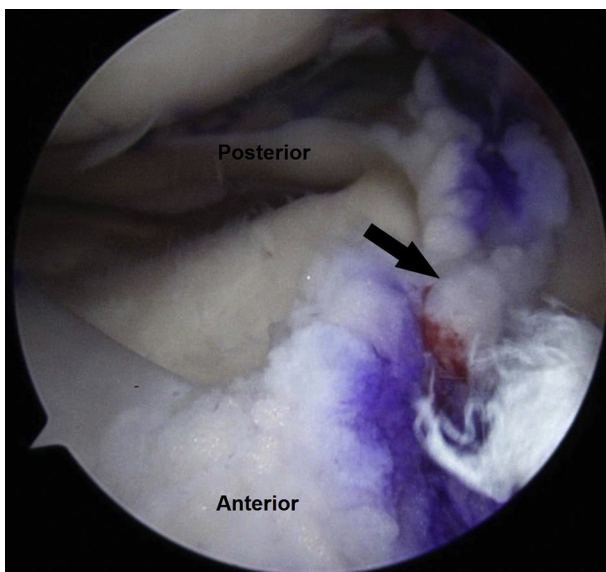


Fig 8. Final arthroscopic evaluation viewing from the anterolateral portal is performed to confirm the fixed bone bridge (black arrow) of the right lateral meniscal allograft and tension of the entire lateral meniscus.

- transplantation on articular cartilage: A systematic review of animal studies. *Osteoarthritis Cartilage* 2015;23:1242-1253.
5. Smith NA, Parkinson B, Hutchinson CE, Costa ML, Spalding T. Is meniscal allograft transplantation chondroprotective? A systematic review of radiological outcomes. *Knee Surg Sports Traumatol Arthrosc* 2016;24:2923-2935.
 6. Rosso F, Bisicchia S, Bonasia DE, Amendola A. Meniscal allograft transplantation: A systematic review. *Am J Sports Med* 2015;43:998-1007.
 7. Samitier G, Alentorn-Geli E, Taylor DC, et al. Meniscal allograft transplantation. Part 2: Systematic review of transplant timing, outcomes, return to competition, associated procedures, and prevention of osteoarthritis. *Knee Surg Sports Traumatol Arthrosc* 2015;23:323-333.
 8. Smith NA, MacKay N, Costa M, Spalding T. Meniscal allograft transplantation in a symptomatic meniscal deficient knee: A systematic review. *Knee Surg Sports Traumatol Arthrosc* 2015;23:270-279.
 9. Samitier G, Alentorn-Geli E, Taylor DC, et al. Meniscal allograft transplantation. Part 1: Systematic review of graft biology, graft shrinkage, graft extrusion, graft sizing, and graft fixation. *Knee Surg Sports Traumatol Arthrosc* 2015;23:310-322.
 10. Abat F, Gelber PE, Erquicia JI, Pelfort X, Gonzalez-Lucena G, Monllau JC. Suture-only fixation technique leads to a higher degree of extrusion than bony fixation in meniscal allograft transplantation. *Am J Sports Med* 2012;40:1591-1596.
 11. Rodeo SA. Meniscal allografts—Where do we stand? *Am J Sports Med* 2001;29:246-261.
 12. Wang H, Gee AO, Hutchinson ID, et al. Bone plug versus suture-only fixation of meniscal grafts: Effect on joint contact mechanics during simulated gait. *Am J Sports Med* 2014;42:1682-1689.
 13. Abat F, Gelber PE, Erquicia JI, Tey M, Gonzalez-Lucena G, Monllau JC. Prospective comparative study between two different fixation techniques in meniscal allograft transplantation. *Knee Surg Sports Traumatol Arthrosc* 2013;21:1516-1522.
 14. Yoon KH, Lee SH, Park SY, Kim HJ, Chung KY. Meniscus allograft transplantation: A comparison of medial and lateral procedures. *Am J Sports Med* 2014;42:200-207.
 15. Wilcox TR, Goble EM. Indications for meniscal allograft reconstruction. *Am J Knee Surg* 1996;9:35-36.
 16. Ha JK, Jang HW, Jung JE, Cho SI, Kim JG. Clinical and radiologic outcomes after meniscus allograft transplantation at 1-year and 4-year follow-up. *Arthroscopy* 2014;30:1424-1429.
 17. Pollard ME, Kang Q, Berg EE. Radiographic sizing for meniscal transplantation. *Arthroscopy* 1995;11:684-687.
 18. Kim JM, Bin SI, Lee BS, et al. Long-term survival analysis of meniscus allograft transplantation with bone fixation. *Arthroscopy* 2017;33:387-393.
 19. Paletta GA Jr, Manning T, Snell E, Parker R, Bergfeld J. The effect of allograft meniscal replacement on intra-articular contact area and pressures in the human knee. A biomechanical study. *Am J Sports Med* 1997;25:692-698.
 20. Sekiya JK, West RV, Groff YJ, Irrgang JJ, Fu FH, Harner CD. Clinical outcomes following isolated lateral meniscal allograft transplantation. *Arthroscopy* 2006;22:771-780.
 21. Lee SR, Kim JG, Nam SW. The tips and pitfalls of meniscus allograft transplantation. *Knee Surg Relat Res* 2012;24:137-145.
 22. Choi NH, Yoo SY, Victoroff BN. Position of the bony bridge of lateral meniscal transplants can affect meniscal extrusion. *Am J Sports Med* 2011;39:1955-1959.
 23. Kim NK, Bin SI, Kim JM, Lee CR. Does lateral meniscal allograft transplantation using the keyhole technique restore the anatomic location of the native lateral meniscus? *Am J Sports Med* 2016;44:1744-1752.
 24. Jung YH, Choi NH, Victoroff BN. Arthroscopic stabilization of the lateral capsule of the knee in meniscal transplantation. *Knee Surg Sports Traumatol Arthrosc* 2011;19:189-191.
 25. Sekaran SV, Hull ML, Howell SM. Nonanatomic location of the posterior horn of a medial meniscal autograft implanted in a cadaveric knee adversely affects the pressure distribution on the tibial plateau. *Am J Sports Med* 2002;30:74-82.
 26. Lee YS, Kim JG, Lim HC, Park JH, Park JW, Kim JG. The relationship between tibial slope and meniscal insertion. *Knee Surg Sports Traumatol Arthrosc* 2009;17:1416-1420.