

Clinical characteristics and treatment outcome of *Candida* tracheobronchitis

Hyun-Il Gil, MD^a, Bumhee Yang, MD^b, Taebum Lee, MD, PhD^c, Min Yeong Kim, MD, PhD^d, Hayoung Choi, MD, PhD^e, Hongseok Yoo, MD, PhD^f, Hojoong Kim, MD, PhD^f, O. Jung Kwon, MD, PhD^f, Sung Jun Chung, MD^g, Hyun Lee, MD, PhD^{g,*}

Abstract

Although *Candida* species can cause invasive fungal diseases, such as disseminated infection and pneumonia, they rarely cause tracheobronchitis, which is often fatal.

To identify the clinical characteristics of *Candida* tracheobronchitis, we retrospectively evaluated 8 patients who had pathologically proven *Candida* tracheobronchitis.

Their median age was 64 (range: 51–70) years and 5 were females. Three patients had solid cancers and 5 had hematological malignancies. We classified tracheobronchitis into localized and diffuse types. Of the 8 patients, 5 had localized and 3 had diffuse tracheobronchitis. While all patients with diffuse tracheobronchitis had predisposing risk factors for invasive fungal disease, such as prolonged corticosteroid use, recent use of nucleoside analogues, or recent neutropenia (<500/m³), only 2 of the 5 with localized tracheobronchitis had predisposing risk factors. Four of the 5 patients with localized tracheobronchitis had loco-regional bronchial mucosal damage (e.g., radiation or photodynamic therapy). Although all 8 patients ultimately died, some improved with or without antifungal treatment. Two of the 5 patients (1 with localized and the other with diffuse tracheobronchitis) who received antifungal agents improved after treatment, and 1 patient with localized tracheobronchitis who did not receive antifungal treatment improved spontaneously. Two of the 3 patients with diffuse tracheobronchitis did not respond to antifungal treatment.

Candida tracheobronchitis can present as both localized and diffuse types. While the former was influenced more by loco-regional mucosal damage, the latter was influenced more by the patient's immune status. The treatment outcomes were especially poor in patients with diffuse tracheobronchitis.

Abbreviations: CT = computed tomography, IFD = invasive fungal diseases, TEVAR = thoracic endovascular aortic repair.

Keywords: bronchial disease, *Candida*, invasive fungal disease

1. Introduction

The mortality rate is higher in critically ill patients with nosocomial fungal infection than in those without it.^[1] Although the incidence of fungal tracheobronchitis is lower than that of

other invasive fungal diseases (IFD),^[2,3] it can progress rapidly and cause airway obstruction, leading to respiratory failure and death.^[4] Common etiologies of invasive fungal tracheobronchitis are *Aspergillus*, *Coccidioides*, *Cryptococcus*, and *Zygomycota*

Editor: Oana Săndulescu.

HG and BY contributed equally to this manuscript as first authors.

None of the authors received any financial support for this study.

The Institutional Review Board of Samsung Medical Center approved this study (SMC 2018-11-032).

The authors have no conflicts of interests to disclose.

All data generated or analyzed during this study are included in the published article. The datasets used and analyzed during this study are available from the corresponding author on reasonable request.

This study was supported by the National Research Foundation (NRF) funded by the Korean government (MSIT) (No. 2020R1F1A1070468 and 2021M3E5D1A0101517621) and the Korea Medical Device Development Fund grant funded by the Korea government (the Ministry of Science and ICT, the Ministry of Trade, Industry and Energy, the Ministry of Health & Welfare, the Ministry of Food and Drug Safety) (No. 202014X08-03).

^a Division of Pulmonary and Critical Care Medicine, Department of Internal Medicine, Kangbuk Samsung Hospital, Sungkyunkwan University School of Medicine, Seoul,

^b Division of Pulmonary and Critical Care Medicine, Department of Medicine, Chungbuk National University, Cheongju, ^c Department of Pathology, Chonnam National University Medical School, Hwasun Hospital, Hwasun-gun, ^d Department of Radiology, Samsung Medical Center, Sungkyunkwan University School of Medicine,

^e Division of Pulmonary, Allergy, and Critical Care Medicine, Department of Internal Medicine, Hallym University Kangnam Sacred Heart Hospital, ^f Division of Pulmonology and Critical Care Medicine, Department of Medicine, Samsung Medical Center, Sungkyunkwan University School of Medicine, ^g Division of Pulmonary Medicine and Allergy, Department of Internal Medicine, Hanyang University College of Medicine, Seoul, Republic of Korea.

* Correspondence: Hyun Lee, Division of Pulmonary Medicine and Allergy, Department of Internal Medicine, Hanyang University College of Medicine, 222-1 Wangsimni-ro, Seongdong-gu, Seoul 04763, Republic of Korea (e-mail: namuhanayeyo@naver.com).

Copyright © 2021 the Author(s). Published by Wolters Kluwer Health, Inc.

This is an open access article distributed under the terms of the Creative Commons Attribution-Non Commercial License 4.0 (CCBY-NC), where it is permissible to download, share, remix, transform, and buildup the work provided it is properly cited. The work cannot be used commercially without permission from the journal.

How to cite this article: Gil HI, Yang B, Lee T, Kim MY, Choi H, Yoo H, Kim H, Kwon OJ, Chung SJ, Lee H. Clinical characteristics and treatment outcome of *Candida* tracheobronchitis. *Medicine* 2021;100:6(e24606).

Received: 28 August 2020 / Received in final form: 10 December 2020 / Accepted: 7 January 2021

<http://dx.doi.org/10.1097/MD.00000000000024606>

(Mucorales) spp.^[5] *Candida* spp. are often the cause of disseminated IFD, but they rarely invade the lower respiratory tract. Traditionally, *Candida* spp. found in respiratory specimens have been considered nonpathogenic colonizers.^[6] However, recent studies have shown that *Candida* spp. can cause lower respiratory IFD.^[7] However, there are limited data on the clinical characteristics and prognosis of *Candida* tracheobronchitis. The purpose of this study was to elucidate the clinical characteristics and natural course of *Candida* tracheobronchitis.

2. Materials and methods

We retrospectively reviewed the medical records of 196 patients diagnosed with any type of pulmonary IFD between January 1995 and May 2015 at Samsung Medical Center, a referral hospital in Seoul, South Korea. All cases were confirmed histologically by bronchial or lung biopsies. After excluding 185 patients who were diagnosed with a fungal infection other than *Candida* (*Aspergillus* [n=125], *Cryptococcus* [n=22], mucormycosis [n=8], or unspecified [n=30]), 11 cases were found to have invasive *Candida* infection (pneumonia [n=3] or tracheobronchitis [n=8]). The 8 patients with *Candida* tracheobronchitis were reviewed. This study was approved by the Institutional Review Board of Samsung Medical Center (IRB number SMC 2018-11-032).

To identify invasive candidiasis, we followed the guidelines of the European Organization for Research and Treatment of Cancer/Invasive Fungal Infections Cooperative Group and the National Institute of Allergy and Infectious Diseases Mycoses Study Group for invasive fungal infection diagnosis. Tracheobronchitis was defined as an ulceration, nodule, pseudomembrane, plaque, or eschar in the trachea, or a bronchus revealed by bronchoscopy.^[8]

Plain chest radiography and computed tomography (CT) were performed at the time of *Candida* tracheobronchitis diagnosis in all patients except patient no. 7. All 8 patients underwent bronchoscopic biopsy for diagnosis. The radiological and bronchoscopic findings were reviewed by 4 physicians (H Gil, B Yang, MY Kim, and H Lee). Based on the CT and bronchoscopic findings, we classified *Candida* tracheobronchitis as localized or diffuse.^[9,10] Localized tracheobronchitis was defined as an endobronchial nodule, mass, pseudomembrane, or necrotic change not affecting more than 2 spurs of the bronchi. Diffuse tracheobronchitis was defined as a diffuse pseudomembrane spreading over an entire tracheobronchial segment or more than 2 spurs of the bronchi. A pathologist (T Lee) reevaluated all bronchial tissue samples obtained from the 8 patients to confirm invasive fungal infection.

3. Results

The median patient age was 64 (range: 51–70) years and 5 were female. Three patients had solid-tumor cancer (lung cancer [n=2] or tracheal adenoid cystic carcinoma [n=1]). Five patients had hematological malignancies (lymphoma [n=2], multiple myeloma [n=1], or acute leukemia [n=2]). Five patients had localized tracheobronchitis and 3 had diffuse tracheobronchitis. Five patients (2 with localized and 3 with diffuse tracheobronchitis) had predisposing host factors for IFD, such as prolonged corticosteroid use (>0.3 mg/kg/day of prednisone equivalent for >3 weeks), use of nucleoside analogues within the past 90 days, or recent history of neutropenia (<500/mm³) for >10 days at the

Table 1 Clinical characteristics and prognoses of patients with *Candida* tracheobronchitis.

Patient No.	Sex/Age (years)	Underlying disease	Host factors predisposing to IFD	Previous locoregional treatment	Morphological classification of tracheobronchitis	Antifungal treatment	Improvement of <i>Candida</i> tracheobronchitis	Survival time (days) after diagnosis of tracheobronchitis	Cause of death
1	F/63	Tracheal ACC	No	Endobronchial brachytherapy	Localized	No	No	9	ACC
2	M/70	NSCLC	No	Chemoradiation	Localized	No	Yes	1130	NSCLC
3	F/60	DLBCL	No	Radiation therapy of thoracic vertebra	Localized	Yes	No	52	DLBCL
4	M/70	NSCLC	Corticosteroid	Endobronchial photodynamic therapy	Localized	No	No	35	Pneumonia
5	F/51	MM	Corticosteroid	No	Localized	Yes	Yes	111	MM
6	F/59	AML	Neutropenia & nucleoside analogue	No	Diffuse	Yes	No	3	Pneumonia
7	F/67	Burkitt's lymphoma	Neutropenia	No	Diffuse	Yes	No	4	Airway obstruction by <i>Candida</i> tracheobronchitis
8	M/65	AML	Neutropenia & nucleoside analogue	No	Diffuse	Yes	Yes	203	AML

ACC = adenoid cystic carcinoma, AML = acute myeloid leukemia, DLBCL = diffuse large B cell lymphoma, IFD = invasive fungal disease, MM = multiple myeloma, NSCLC = non-small cell lung cancer.

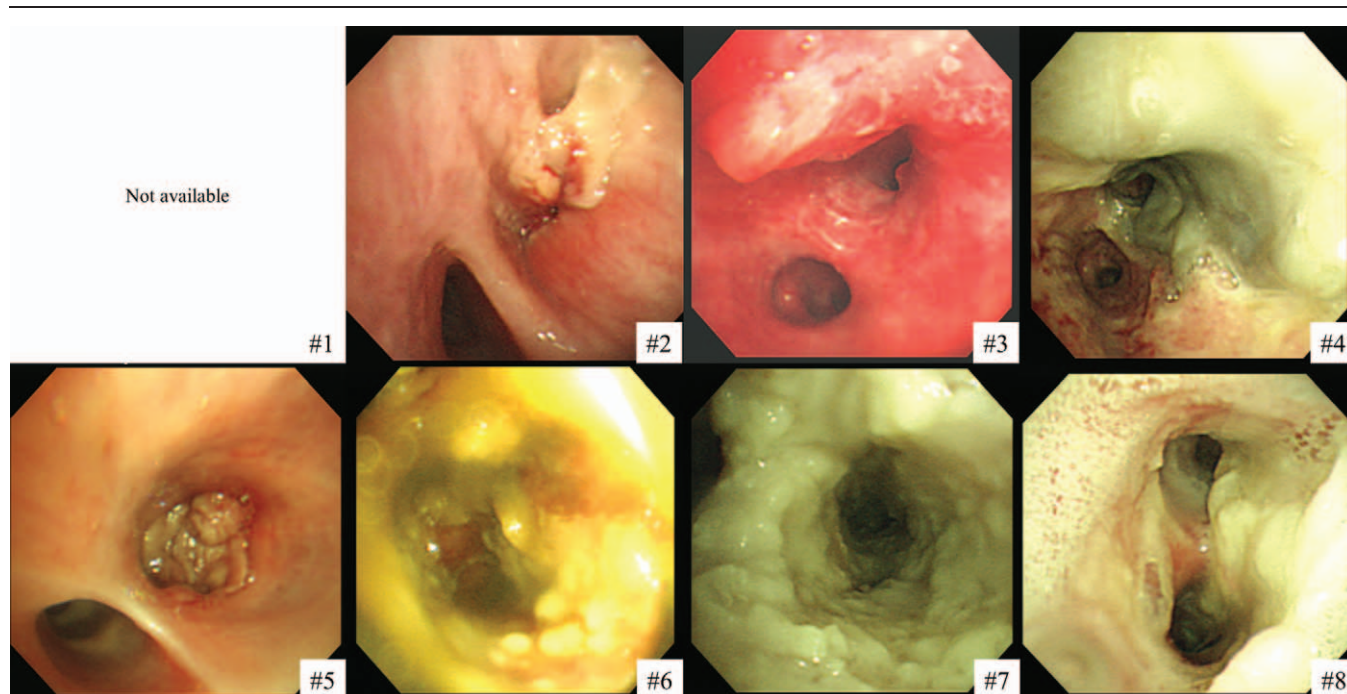


Figure 1. Bronchoscopic findings of *Candida* tracheobronchitis. Numbers are the patient numbers: #1 to #5 had localized tracheobronchitis and #6 to #8 had diffuse tracheobronchitis. No bronchoscopy image was available for patient no. 1.

time of *Candida* tracheobronchitis diagnosis.^[8] However, 3 of the 5 patients with localized tracheobronchitis had no known host factors for IFD (Table 1). Figures 1 and 2 show the bronchoscopic and pathological findings.

Of the 5 patients with localized tracheobronchitis, 3 did not receive antifungal treatment because the attending physicians did not consider the localized *Candida* infection to be serious. Despite the lack of antifungal treatment, the *Candida* tracheobronchitis

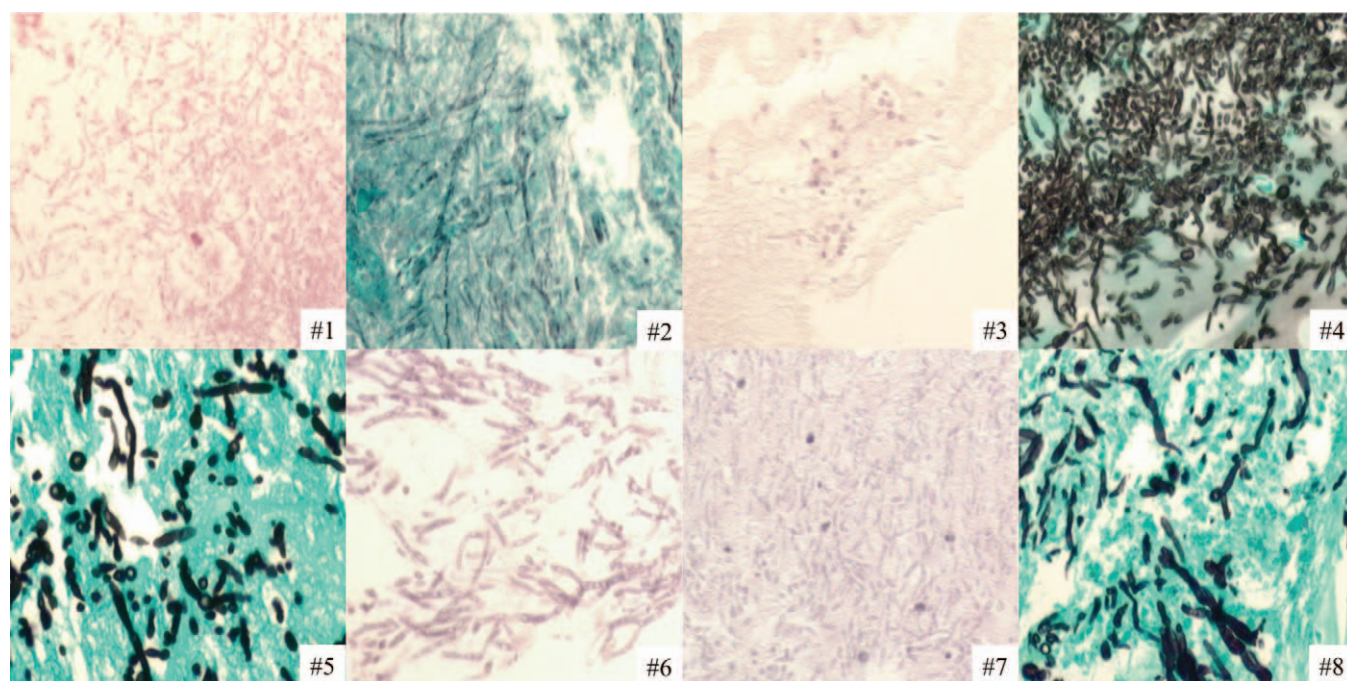


Figure 2. Pathological findings of *Candida* tracheobronchitis. Each bronchial specimen was subject to hematoxylin and eosin or Grocott's methenamine silver staining. Numbers are the patient numbers.

Downloaded from http://journals.lww.com/md-journal by BNDMfsePHKav1ZEoum1tIQINa+kLLNEZgbsiHo4XM10hCY WcX1AWnYQpHlOHD33D00dfy7TVSfACf3V/C1y0abgqQZxdtmwfkZBYtws= on 04/18/2023

improved spontaneously in 1 patient (patient no. 2), who survived for more than 3 years after the initial diagnosis of *Candida* tracheobronchitis. Of the 2 patients who received antifungal treatment, 1 improved (patient no. 5).

Of 3 patients with diffuse *Candida* tracheobronchitis who received antifungal treatment, 1 improved, but all ultimately died after 3, 4, and 203 days due to pneumonia-associated septic shock, airway obstruction caused by *Candida* tracheobronchitis, and progression of underlying lymphoma, respectively. One patient with diffuse tracheobronchitis and another with localized tracheobronchitis improved after antifungal treatment, but ultimately died from their underlying malignant diseases.

4. Discussion

Here, we present the results of a retrospective study of the clinical manifestations and natural course of *Candida* tracheobronchitis. To our knowledge, this is the first study to comprehensively describe the 2 types of *Candida* tracheobronchitis. Whereas localized *Candida* tracheobronchitis was associated with loco-regional mucosal damage rather than immunosuppression, diffuse *Candida* tracheobronchitis was mainly associated with immunosuppressive conditions, particularly neutropenia.

Among immunocompromised patients, those with IFD had a poor prognosis regardless of the site of infection.^[11] However, few studies have focused on fungal tracheobronchitis caused by *Candida* spp. Compared with invasive tracheobronchitis caused by *Aspergillus* spp., *Candida* tracheobronchitis is not well-recognized because most reports describing this entity are principally concerned with other fungal diseases.

Although a few studies have reported *Candida* tracheobronchitis,^[2,5,12–15] they included small numbers of cases and did not fully describe the presentation or clinical course of *Candida* tracheobronchitis. In addition, previous studies did not clearly demonstrate tissue invasion by *Candida* spp., which is crucial for diagnosing tracheobronchitis.^[2,4,5] In this study, we assessed the clinical presentation and course of both the localized and diffuse types of (pathologically confirmed) *Candida* tracheobronchitis.

As shown by our results, the development of localized tracheobronchitis is associated with local mucosal damage. In 1 case report, localized *Candida* tracheobronchitis occurred several days after thoracic endovascular aortic repair (TEVAR).^[13] The patient did not have predisposing factors for systemic IFD; loco-regional ischemic damage to the airway mucosa appeared to be the cause of the tracheobronchitis,

consistent with our finding that loco-regional damage may be a risk factor for this condition. In that case, localized tracheobronchitis occurred as a result of ischemic changes in the airway mucosa caused by a reduction in bronchial artery blood flow due to graft placement during TEVAR. Other studies reported *Candida* tracheobronchitis at the anastomosis site in lung transplant patients.^[2,5,15,16] We also found that local mucosal injuries caused by endobronchial brachytherapy, photodynamic therapy, and radiation therapy can contribute to *Candida* tracheobronchitis.

Other studies reported cases of *Candida* tracheobronchitis not associated with local mucosal damage.^[12,17] Our study, and several previous ones, showed that diffuse *Candida* tracheobronchitis can occur in immunocompromised patients. Previous studies also showed that immunocompromised patients, including those with neutropenia, poorly controlled diabetes mellitus, and heavy alcohol consumption, can suffer from IFD caused by *Candida* spp.^[8,12,17] We summarize the reported cases of *Candida* tracheobronchitis in Table 2.^[4,12–14,16–19]

It is generally considered that the presence of *Candida* spp. in lower respiratory tract samples is not indicative of severe infection or associated with treatment outcomes.^[20] However, recent studies have shown that *Candida* spp. can cause lower-respiratory IFD, such as *Candida* pneumonia.^[6] However, *Candida* tracheobronchitis is rarely reported and not well recognized. Although rare, our study, and previous ones, clearly showed that *Candida* infection can manifest as tracheobronchitis, similar to other fungal infections. Our results indicate that clinicians should be aware that loco-regional mucosal damage and a severely compromised immune system can predispose patients to localized and diffuse *Candida* tracheobronchitis, respectively, and that the prognosis of this disease is poor (especially for diffuse *Candida* tracheobronchitis).

This study had several limitations. First, it used a retrospective, single-center design. Second, the number of cases analyzed was small because of the rarity of the disease. Further studies with more patients are needed. However, our study was the first to comprehensively assess pathologically proven *Candida* tracheobronchitis, in terms of its presentation, histopathology, treatment, and natural course.

5. Conclusions

Candida tracheobronchitis can present in localized and diffuse forms. The former is mainly associated with loco-regional mucosal damage, while the latter is more dependent on the

Table 2
Reported cases of *Candida* tracheobronchitis.

Study	Number of cases	Diagnostic method	Form of tracheobronchitis	Suspected predisposing factor
Spear, 1976 ^[18]	1	EBBx	Diffuse	Broad-spectrum antibiotics
Clarke, 1991 ^[19]	2	EBBx (1 case) Autopsy (1 case)	Diffuse	Metastatic cancer (1 case) Unknown (1 case)
Nunley, 2002 ^[16]	2	EBBx	Localized	Lung transplantation
Khan, 2016 ^[17]	1	EBBx	Diffuse	Fulminant hepatic failure
Schaenman, 2009 ^[14]	12	EBBx (4 cases) BAL (8 cases)	NA	Lung transplantation
Lin, 2017 ^[4]	2	EBBx and/or BAL	NA	NA
Tanaka, 2017 ^[12]	1	BAL	Diffuse	Uncontrolled DM
Takaki, 2018 ^[13]	1	EBBx	Localized	Ischemia after TEVAR

BAL = bronchoalveolar lavage, DM = diabetes mellitus, EBBx = endobronchial biopsy, NA = not available, TEVAR = thoracic endovascular aortic repair.

Downloaded from http://journals.lww.com/med/FullText/2021/04000/Gil_et_al._Candida_tracheobronchitis.aspx by BMDMSEPHKAVI7E0UMT1QIN4a+kLHEZgjsH04XM0N0Cj WCX1AWNYQpI0IH0HD33DD0DFy7TVSFA3C3V/C1y0abgqzXdtwntKZBYtws= on 04/18/2023

patient's immune status. The treatment outcomes were especially poor in patients with diffuse tracheobronchitis.

Author contributions

HG and BY were the major contributors to the writing of the manuscript. They also analyzed and interpreted the data on invasive fungal tracheobronchitis and contributed equally to this work. TL performed the histological examinations of bronchial tissue and contributed to the writing of the manuscript. MYK performed the radiological review of the cases. HC and HY helped with the writing and substantively revised the manuscript. HK, OJK, and SJC reviewed the manuscript and provided medical advice. HL designed the study and served as the principal investigator and corresponding author. All authors read and approved the final manuscript.

Conceptualization: Hyun-Il Gil, Bumhee Yang, Taebum Lee, Min Yeong Kim, Hayoung Choi, Hojoong Kim, Sung Jun Chung, Hyun Lee.

Data curation: Hyun-Il Gil, Bumhee Yang, Taebum Lee, Min Yeong Kim, Hyun Lee.

Formal analysis: Hyun-Il Gil, Bumhee Yang, Taebum Lee, Min Yeong Kim, Hyun Lee.

Investigation: Hyun-Il Gil, Bumhee Yang, Hyun Lee.

Methodology: Hayoung Choi, Hojoong Kim, O Jung Kwon, Hyun Lee.

Project administration: Hongseok Yoo, Hyun Lee.

Resources: Hongseok Yoo.

Supervision: Hayoung Choi, Hojoong Kim, O Jung Kwon, Sung Jun Chung, Hyun Lee.

Visualization: Taebum Lee, Min Yeong Kim.

Writing – original draft: Hyun-Il Gil, Bumhee Yang, Taebum Lee, Min Yeong Kim.

Writing – review & editing: Hyun-Il Gil, Bumhee Yang, Hayoung Choi, Hongseok Yoo, Hojoong Kim, O Jung Kwon, Sung Jun Chung, Hyun Lee.

References

- [1] Adiguzel N, Karakurt Z, Gungor G, et al. Mortality rates and risk factors associated with nosocomial *Candida* infection in a respiratory intensive care unit. *Tuberk Toraks* 2010;58:35–43.
- [2] Grossi P, Farina C, Fiocchi R, et al. Prevalence and outcome of invasive fungal infections in 1,963 thoracic organ transplant recipients: a multicenter retrospective study. *Italian Study Group of Fungal Infections*

- in Thoracic Organ Transplant Recipients. *Transplantation* 2000;70:112–6.
- [3] Garnacho-Montero J, Olaechea P, Alvarez-Lerma F, et al. Epidemiology, diagnosis and treatment of fungal respiratory infections in the critically ill patient. *Rev Esp Quimioter* 2013;26:173–88.
- [4] Lin CY, Liu WL, Chang CC, et al. Invasive fungal tracheobronchitis in mechanically ventilated critically ill patients: underlying conditions, diagnosis, and outcomes. *Ann Intensive Care* 2017;7:9.
- [5] Karnak D, Avery RK, Gildea TR, et al. Endobronchial fungal disease: an under-recognized entity. *Respiration* 2007;74:88–104.
- [6] Pendleton KM, Huffnagle GB, Dickson RP. The significance of *Candida* in the human respiratory tract: our evolving understanding. *Pathog Dis* 2017;75.
- [7] Kontoyiannis DP, Reddy BT, Torres HA, et al. Pulmonary candidiasis in patients with cancer: an autopsy study. *Clin Infect Dis* 2002;34:400–3.
- [8] De Pauw B, Walsh TJ, Donnelly JP, et al. Revised definitions of invasive fungal disease from the European Organization for Research and Treatment of Cancer/Invasive Fungal Infections Cooperative Group and the National Institute of Allergy and Infectious Diseases Mycoses Study Group (EORTC/MSG) Consensus Group. *Clin Infect Dis* 2008;46:1813–21.
- [9] Franquet T, Muller NL, Oikonomou A, et al. Aspergillus infection of the airways: computed tomography and pathologic findings. *J Comput Assist Tomogr* 2004;28:10–6.
- [10] Kang EY. Large airway diseases. *J Thorac Imaging* 2011;26:249–62.
- [11] Valentine JC, Morrissey CO, Tacey MA, et al. A population-based analysis of invasive fungal disease in haematology-oncology patients using data linkage of state-wide registries and administrative databases: 2005–2016. *BMC Infect Dis* 2019;19:274.
- [12] Tanaka K, Goto H, Tsubakihara M, et al. Candidal tracheobronchitis in poorly controlled diabetes mellitus. *Intern Med* 2017;56:121–2.
- [13] Takaki M, Tanaka T, Matsui K, et al. Candidal tracheobronchitis after total aortic replacement and thoracic endovascular aortic repair. *Respirology* 2018;23:306–7.
- [14] Schaeferman JM, Rosso F, Austin JM, et al. Trends in invasive disease due to *Candida* species following heart and lung transplantation. *Transpl Infect Dis* 2009;11:112–21.
- [15] Hosseini-Moghaddam SM, Husain S. Fungi and molds following lung transplantation. *Semin Respir Crit Care Med* 2010;31:222–33.
- [16] Nunley DR, Gal AA, Vega JD, et al. Saprophytic fungal infections and complications involving the bronchial anastomosis following human lung transplantation. *Chest* 2002;122:1185–91.
- [17] Khan AH, Tandon R. *Candida* tracheobronchitis: a case report of a rare disease. *Am J Resp Crit Care Med* 2016;193:A1875.
- [18] Spear RK, Walker PD, Lampton LM. Tracheal obstruction associated with a fungus ball. A case of primary tracheal candidiasis. *Chest* 1976;70:662–3.
- [19] Clarke A, Skelton J, Fraser RS. Fungal tracheobronchitis. Report of 9 cases and review of the literature. *Medicine (Baltimore)* 1991;70:1–4.
- [20] Terraneo S, Ferrer M, Martin-Loeches I, et al. Impact of *Candida* spp. isolation in the respiratory tract in patients with intensive care unit-acquired pneumonia. *Clin Microbiol Infect* 2016;22:94e91–94 e98.