

Postoperative nausea and vomiting after capsicum plaster at the P6 acupoint after laparoscopic cholecystectomy according to gender

Department of Anesthesiology and Pain Medicine, Hanyang University School of Medicine, Seoul, Korea

Kyu Nam Kim, Kyo Sang Kim, Hee Jong Lee, and Song Yee Oh

Background: Postoperative nausea and vomiting (PONV) has a remarkably high reported incidence (70%) in female patients after anesthesia. This study aims to evaluate the clinical effect of capsicum plaster at the P6 acupoint with respect to gender in preventing PONV after laparoscopic cholecystectomy.

Methods: A prospective, placebo-controlled, double-blind study was conducted with 120 patients undergoing laparoscopic cholecystectomy and who were randomly assigned to four groups (n = 30 each): Group MC = male patients with capsicum plaster at the P6 acupoint; Group MP = male patients with placebo tape at the P6 acupoint; Group FC = female patients with capsicum plaster at the P6 acupoint; Group FP = female patients with placebo tape at the P6 acupoint. The treatment tape was applied before the induction of anesthesia and was removed eight hours after the operation.

Results: The incidence of nausea was reduced in both genders with application of capsicum plaster at P6 acupoint. No change in vomiting or use of anti-emetics was observed. Satisfaction scores with PONV control were improved with this intervention. No gender difference was observed which actually the initial objective of this study was.

Conclusions: The application of capsicum plaster at the P6 acupoint is a proven antiemetic method in both gender after laparoscopic cholecystectomy, however there are no intergender differences. (*Anesth Pain Med* 2015; 10: 261-266)

Key Words: Acupuncture, Capsaicin, Gender, Laparoscopic cholecystectomy, Nausea and vomiting.

Received: April 30, 2015.

Revised: 1st, May 27, 2015; 2nd, June 15, 2015.

Accepted: June 15, 2015.

Corresponding author: Kyo Sang Kim, M.D., Ph.D., Department of Anesthesiology and Pain Medicine, Hanyang University School of Medicine, 222, Wangsimni-ro, Seongdong-gu, Seoul 04763, Korea. Tel: 82-2-2290-8680, Fax: 82-2-2299-8692, E-mail: kimks@hanyang.ac.kr

This is an Open Access article distributed under the terms of the Creative Commons Attribution Non-Commercial License (<http://creativecommons.org/licenses/by-nc/4.0>) which permits unrestricted non-commercial use, distribution, and reproduction in any medium, provided the original work is properly cited.

INTRODUCTION

Postoperative nausea and vomiting (PONV) frequently occurs after general anesthesia, especially in women, and necessitates further study for its prevention and treatment [1]. The incidence of PONV is much higher (75%) in patients undergoing laparoscopic cholecystectomy [2]. Recently it has been shown that female gender was one of the main determinants of PONV, questioning the need for routine PONV prophylaxis. Prophylactic antiemetic therapy decreases the incidence of PONV relative to placebo in patients at high risk of PONV after laparoscopic cholecystectomy [3].

The Chinese acupuncture point Pericardium 6 (P6, Nei Guan) has been reported in many papers as an acupuncture point that can suppress PONV [4-6]. Recently, it has been reported that transcutaneous electroacupoint stimulation or acustimulation applied at the P6 acupoint suppressed PONV after laparoscopic cholecystectomy [7,8]. Capsicum plaster attached at the acupoints is known to be an effective method for the prevention and treatment of PONV after several types of surgeries and is also an alternative type of pain treatment [6,9-12]. We demonstrated that capsicum plaster reduced the incidence of PONV in female gender after abdominal hysterectomy [6]. However, there were no direct comparative studies with male gender for preventing PONV.

Therefore, this study was undertaken to assess the efficacy of capsicum plaster with respect to gender in preventing PONV in the 24 hours (h) after laparoscopic cholecystectomy. We aimed to test the hypothesis that the preventing PONV with capsicum plaster is greater in women than in men.

MATERIALS AND METHODS

The study protocol was approved by our Hospital Ethics Committee (IRB File No.: 2012-11-030), and written informed consent was obtained from all patients. All American Society of Anesthesiologists class I or II patients between the ages of 20 and 65 years who were scheduled for elective laparoscopic cholecystectomy were assessed for inclusion in the study. Exclusion criteria included obesity (weight > 130% of ideal body weight); cardiopulmonary, endocrine, central nervous system, neuromuscular, renal, or hepatic disease; menstruating or pregnant patients; patients taking antiemetic medications 72 h before surgery; or a documented allergic reaction to any of the medications used during anesthesia.

This prospective, placebo-controlled, double-blind study was randomized to four groups of 30 patients each: the MC group (male patients with capsicum plaster at the P6 acupoint), the MP group (male patients with placebo tape at the P6 acupoint), the FC group (female patients with capsicum plaster at the P6 acupoint), or the FP group (female patients with placebo tape at the P6 acupoint). These groupings were based on a computer-generated randomization table, and the enrolled patients underwent general anesthesia for elective laparoscopic cholecystectomy (Fig. 1).

In each group, capsicum plaster (Sinsin Capsicum Hot Round Plaster[®], Sinsin Pharm., Seongnam, Korea) (1 × 1 cm²), which contains 60.44 mg methyl salicylate, 201.45 mg powdered capsicum and 20.15 mg capsicum tincture on a sheet

(12.4 × 9.4 cm²), or inactive tape (1 × 1 cm²) was applied at the P6 (Nei Guan) acupoint, located three finger-widths up from the wrist crease between the palmaris longus and flexor carpi radialis tendons on the inside of the wrist [4]. Both the plaster and tape were covered with a plastic adhesive. The experimenter who attached the tapes and classified the subjects was not further involved in the experiment. The patients, researchers, anesthesiologists, and nurses were blinded to the patient groups. The capsicum plaster and placebo tape were applied 30 minutes (min) before the induction of anesthesia and were maintained for 8 h. The capsicum plaster contains 0.49 mg methyl salicylate, 1.64 mg powdered capsicum, and 0.16 mg capsicum tincture prepared on a round sheet (diameter 1 cm) [6,11,12]. Routine monitoring (non-invasive blood pressure monitoring, electrocardiography, pulse oximetry, and bispectral index [BIS] monitoring) was conducted prior to the induction of anesthesia.

No premedication was administered. A standard protocol for general anesthesia was used: induction was performed with 0.5 µg/kg/min of remifentanyl, 2 mg/kg of propofol, and rocuronium 0.6 mg/kg, with all patients receiving tracheal intubation; anesthesia was maintained with 5% desflurane and additional analgesic medications (0.05–0.20 µg/kg/min remifentanyl) and 50% oxygen-enriched air in order to maintain the BIS between 40 and 50. The neuromuscular block was reversed at the end of anesthesia with a combination of neostigmine 1.5 mg and glycopyrrolate 0.4 mg, and confirmed the recovery of train-of-four ratio more than 90%. Dexamethasone and antiemetics were not used during or after the surgery. To control

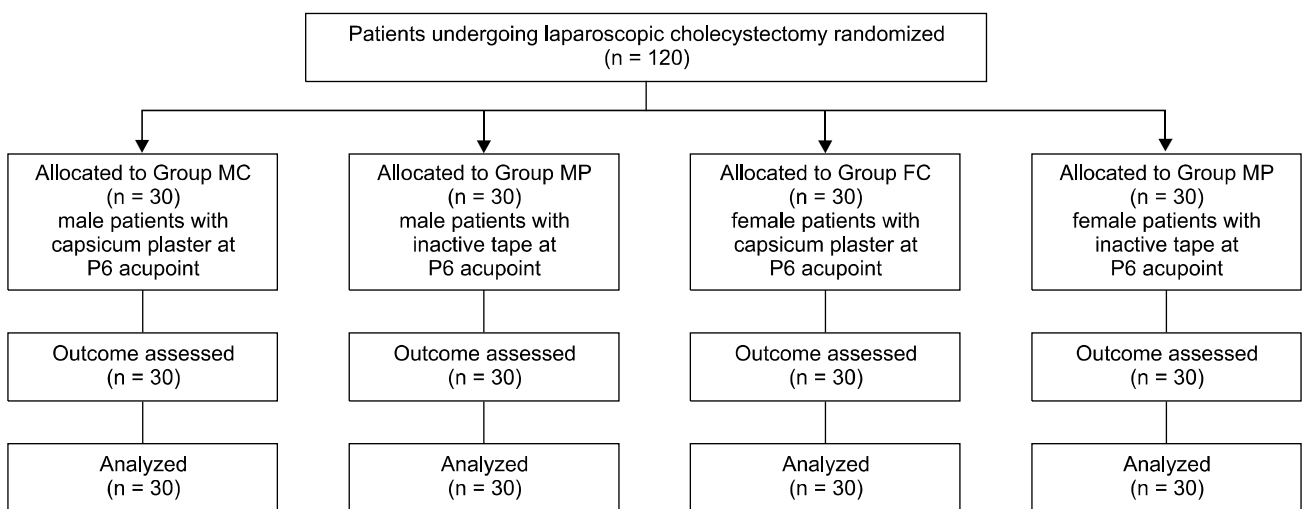


Fig. 1. Trial flow chart. P6 acupoint = three finger-widths up from the wrist crease between the palmaris longus and flexor carpi radialis tendons on the inside of the wrist.

postoperative pain, intravenous patient controlled analgesia (PCA, WalkMed PCA, Mckinley Medical, Wheat Ridge, USA) was used to administer fentanyl. The mode of PCA was a continuous infusion of 0.2 µg/kg/hr with boluses of 0.2 µg/kg and a lockout interval of 15 min with normal saline for a total of 100 ml.

A doctor blinded to the patient groups evaluated the frequency of PONV and the use of antiemetics at 1, 6, and 24 h after the operation. Nausea was defined as an unpleasant sensation associated with the awareness of vomiting. Vomiting was defined as forceful expulsion of contents through the mouth. Metoclopramide 10 mg IV was administered as a rescue antiemetic at the request of the patient or at the discretion of an independent observer who was blinded to the patient grouping. PONV was assessed based on the following verbal descriptive scale (VDS; 0-3 point): Grade 0 indicated no nausea/vomiting, Grade 1 was nausea only, Grade 2 was one episode of vomiting, and Grade 3 was more than one episode of vomiting [2]. Patients were assessed for the characteristics of smoking, history of motion sickness, Apfel risk score for PONV [13], procedure duration, antiemetic, and analgesic use. Patient satisfaction with PONV control was assessed on a 11-step visual analogue scale (VAS) from "extreme dissatisfaction" (0) to "complete satisfaction" (10) at 24 h postoperatively.

The primary outcome was the frequency of PONV and the use of antiemetics according to gender until 24 h after elective laparoscopic cholecystectomy. The secondary outcome was the patient satisfaction with PONV control according to gender.

Power analyses from a previous study [14] indicated that 26 patients in each group were necessary to detect a 30% reduction in PONV from a basal incidence of 68% (from 68.0% to 47.6%) at a 5% level of significance ($\alpha = 0.05$) and an 80% power ($\beta = 0.20$). We increased the sample size to 30 patients in each group based on the possibility of a 10% dropout rate. Patient characteristics and intra- and post-operative variables were analyzed by one-way ANOVA with post hoc analysis using the Bonferroni test. Categorical variables were assessed with a Chi-square test or Fisher's exact test, as appropriate. Data are presented as mean with standard deviation (SD) or frequency distribution and percentage (%) as appropriate. All statistical analyses were performed using SPSS version 18.0 (SPSS Inc., Chicago, IL, USA). Significance for all tests was considered for a P value less than 0.05.

RESULTS

None of the 120 enrolled subjects withdrew from the study (Fig. 1). The patients' characteristics such as age, duration of anesthesia, duration of surgery, crystalloid infusion, and total fentanyl dose were comparable between groups, but weight, height, history of PONV, history of motion sickness, nonsmoking status, and Apfel risk score for PONV were significantly different between the male and female groups ($P < 0.05$) (Table 1).

The difference in PONV between the four study groups during the 0-1 h, 1-6 h and 0-24 h interval was not significant. During the 0-24 h interval postoperatively, the capsicum plaster reduced the incidence of nausea compared to the placebo significantly (Group MC [10%] vs. Group MP [47%], Group FC [20%] vs. Group FP [73%]) ($P < 0.001$), but there was no difference in reducing rate of nausea between male and female (Fig. 2). In the same period, the incidence of vomiting was reduced in Group MC (3%, $P < 0.001$), Group FC (10%, $P = 0.004$) and Group MP (15%, $P = 0.026$) than in Group FP (40%), however there were no gender differences by the capsicum plaster in reducing rate of vomiting (Fig. 2).

The use of antiemetics for 24 h after surgery compared with Group FP (40%) was decreased in Group MC (3%, $P < 0.001$), Group FC (13%, $P = 0.011$) and Group MP (15%, $P = 0.026$), however there were no gender differences by the capsicum plaster in use of antiemetics (Fig. 3). Overall satisfaction scores with PONV control on VAS were higher in Group MC (8.5 ± 1.2 , $P < 0.001$) and Group FC (8.5 ± 1.3 , $P < 0.001$) compared to Group FP (7.1 ± 1.7) and Group MP (7.2 ± 1.9), but there were no gender differences by the capsicum plaster in satisfaction scores (Table 1, Fig. 3).

DISCUSSION

Capsicum plaster at the P6 acupoint decreased the incidence of nausea in both gender, however reduced vomiting and anti-emetic use were not more apparent in female than male gender. Satisfaction scores with PONV control were improved with this intervention. No gender difference was observed which actually the initial objective of this study was.

Nausea and vomiting are protective responses that reflect the absorption of toxins or the application of specific stimuli [15]. A selectively high incidence of PONV (40-75%) is the most common complication in patients after laparoscopic

Table 1. Patients' Characteristics, Perioperative Parameters, Postoperative Analgesic Consumption, Patient Satisfaction

	Group MC	Group MP	Group FC	Group FP	P
No. of patients	30	30	30	30	
Age (yr)	48 ± 11 (22-64)	42 ± 10 (24-60)	45 ± 12 (20-60)	46 ± 9 (25-65)	0.187
Weight (kg)	73 ± 9*	74 ± 11*	59 ± 10	61 ± 11	< 0.001
Height (cm)	170 ± 7*	173 ± 7*	160 ± 6	157 ± 5	< 0.001
Duration of anesthesia (min)	109 ± 23	113 ± 21	108 ± 22	106 ± 17	0.612
Duration of surgery (min)	84 ± 24	87 ± 21	85 ± 21	81 ± 15	0.669
Crystalloids infused (ml)	720 ± 200	742 ± 192	676 ± 218	642 ± 209	0.235
Total fentanyl administered (µg)	362.5 ± 42.5	369.1 ± 47.8	381.3 ± 48.9	378.5 ± 49.1	0.391
History of PONV, n (%)	3 (10)	2 (6.7)	11 (36.7)	9 (30)	0.008
History of motion sickness, n (%)	1 (3.3)	1 (3.3)	9 (30)	8 (26.7)	0.003
Nonsmoking status, n (%)	14 (46.7)*	16 (53.3)*	28 (93.3)	27 (90)	< 0.001
Apfel risk score for PONV, n (%)					< 0.001
0	3 (10)	4 (13.4)			
1	14 (46.7)	10 (33.3)	0 (0)	0 (0)	
2	12 (40)	15 (50)	16 (53.3)	13 (43.3)	
3	1 (3.3)	1 (3.3)	12 (40)	14 (46.7)	
4	0 (0)	0 (0)	2 (6.7)	3 (10)	
Patient satisfaction on VAS at 24 h	8.5 ± 1.2	7.2 ± 1.9	8.5 ± 1.3	7.1 ± 1.7	< 0.001

Values are presented as mean ± SD (range) or n (%). PONV: postoperative nausea and vomiting, VAS: visual analog scale, Group MC: male patients with capsicum plaster at P6 acupoint, Group MP: male patients with placebo plaster at P6 acupoint, Group FC: female patients with capsicum plaster at P6 acupoint, Group FP: female patients with placebo plaster at P6 acupoint. *P < 0.001 vs Group FC and Group FP.

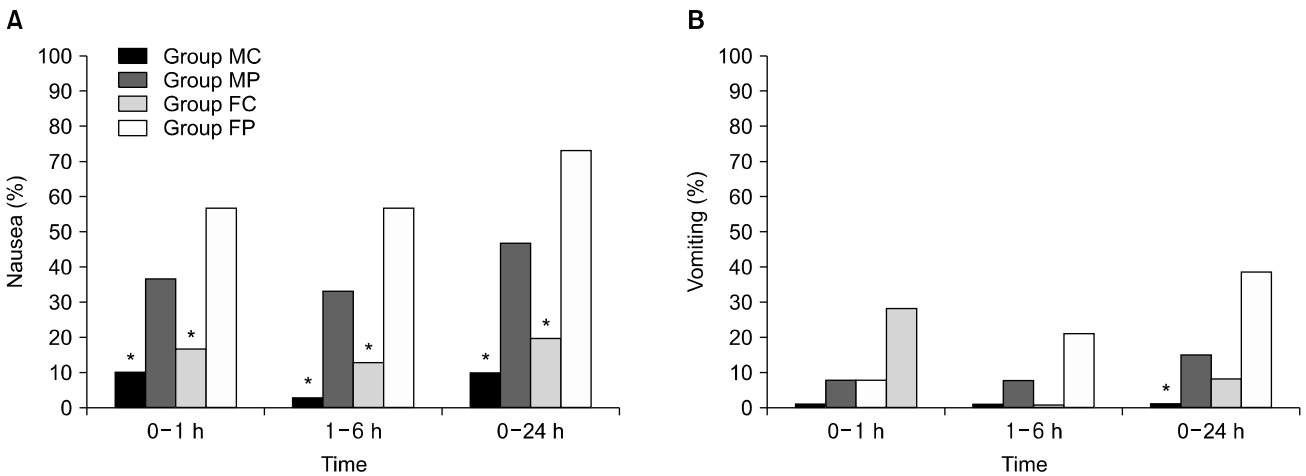


Fig. 2. Incidence of nausea (A) and vomiting (B) over the first 24 hours postoperatively. Group MC: male patients with capsicum plaster at the P6 acupoint, Group MP: male patients with placebo plaster at the P6 acupoint, Group FC: female patients with capsicum plaster at the P6 acupoint, Group FP: female patients with placebo plaster at the P6 acupoint. *P < 0.001 compared with Group FP. †P < 0.001 compared with Group MP.

cholecystectomy [2,16]. The main predisposing factors of PONV include age (more prevalent in children), gender (female), history of nausea and vomiting, history of motion sickness, high level of anxiety, longer durations of surgery and anesthesia, the surgical procedure, and the accumulation of carbon dioxide [17]. Female gender has a two- to fourfold higher incidence of PONV compared with male gender, possibly due to circulating gonadotropin levels [18]. The phase

of the menstrual cycle and menstrual hormonal fluctuations are unlikely to be responsible for the incidence of PONV. However, the mechanism relating female gender to the increased incidence of PONV is not yet known [18]. We also found higher patient-specific risk factors in women compared with men, as well as higher Apfel risk scores for PONV.

Capsicum plaster is a frequently used analgesic technique for the treatment of muscular pain and neuralgia because of its

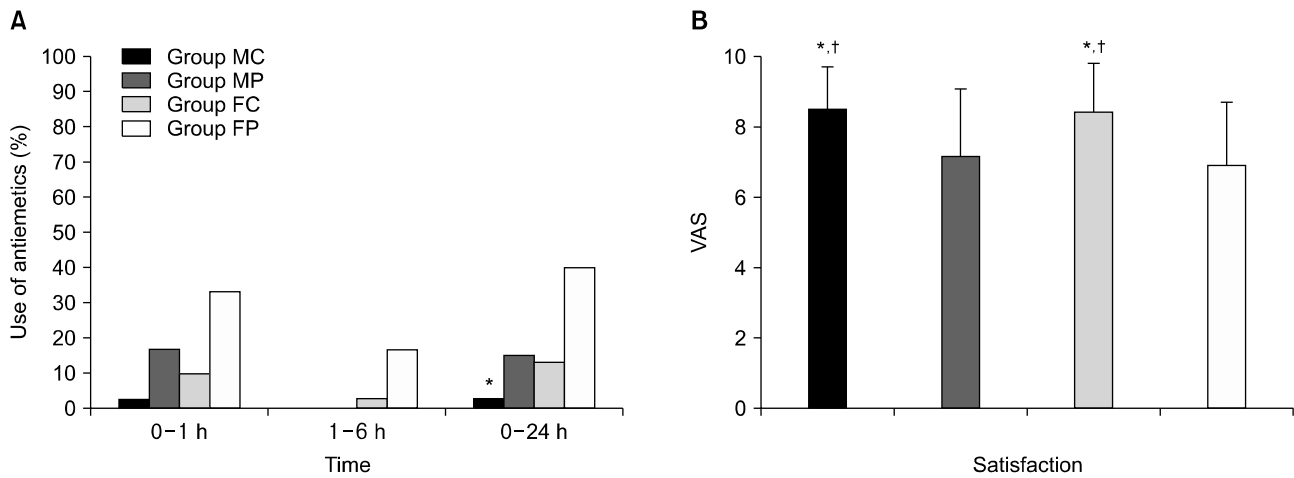


Fig. 3. Use of antiemetics (metoclopramide) (A) and satisfaction scores (B) (mean \pm SD) over the first 24 hours postoperatively. VAS: visual analog scale. Group MC: male patients with capsicum plaster at the P6 acupoint, Group MP: male patients with placebo plaster at the P6 acupoint, Group FC: female patients with capsicum plaster at the P6 acupoint, Group FP: female patients with placebo plaster at the P6 acupoint. * $P < 0.001$ compared with Group FP. † $P < 0.001$ compared with Group MP.

efficacy and affordability in Korea [11]. Capsicum plaster's mechanisms of action on the stimulation at acupuncture point P6 are not yet understood, but the A- β and A- δ fibers may be activated by low-frequency stimulation of skin sensory fibers, resulting in the release of endorphins in the hypothalamus that activate the serotonergic and norepinephrine receptors [19]. Continuous low-intensity stimulation of the P6 acupoint by capsaicin was reported to be effective in reducing the incidence of PONV, and its effects are similar to those of ondansetron for the first 6 h after surgery [10]. PONV was also directly inhibited by capsaicin, which activates vagal modulation and gastric relaxation [6]. The use of capsicum plaster as an antiemetic treatment has many advantages given that it is noninvasive, simple, painless, and easy to apply at the correct point compared with acupuncture and is available at low cost [6]. De-Qi, the typical sense of exact needle position, is known to be important for achieving the effects of acupuncture [20]. However, De-Qi is not usually elicited when the capsicum plaster is applied to the P6 acupoint due to the former's larger size compared with a needle point.

As anti-emetics tend to have greater efficacy when risk is high, it might be expected that this intervention would have greater effect in female compared than male gender. However reduced PONV and anti-emetic use were not more apparent in female than male gender in the present study. We cannot exclude that the intergender differences failed to achieve the statistical significance simply because the number studied was not large enough. Regardless of the sample size, a relative

nausea reduction of 53 and 37% in female and male gender, respectively, for a given clinical outcome as a result of a prophylactic treatment is of clinical importance and improved patient satisfaction.

Combination therapy with other antiemetics has been shown to be more effective than a single antiemetic to treat or prevent PONV in patients undergoing laparoscopic cholecystectomy [21]. We suspect that combination therapy with capsicum plaster and other antiemetics such as dexamethasone, metoclopramide, or 5-HT₃ antagonists may be more effective in treating or preventing PONV, especially in high-risk patients. Further study is needed.

The limitations of the current trial were a local heating sensation of capsicum plaster which would interfere with a blinding although covered with a plastic adhesive, and a limited sample size.

In conclusion, capsicum plaster at the P6 acupoint is a proven antiemetic method in both gender, however reduced PONV and anti-emetic use is not more apparent in female than male gender in groups receiving capsicum undergoing laparoscopic cholecystectomy.

REFERENCES

1. Kerger H, Turan A, Kredel M, Stuckert U, Alsip N, Gan TJ, et al. Patients' willingness to pay for antiemetic treatment. *Acta Anaesthesiol Scand* 2007; 51: 38-43.
2. Cekmen N, Salman B, Keles Z, Aslan M, Akcabay M. Transcutaneous electrical nerve stimulation in the prevention of

- postoperative nausea and vomiting after elective laparoscopic cholecystectomy. *J Clin Anesth* 2007; 19: 49-52.
3. Karanicolas PJ, Smith SE, Kanbur B, Davies E, Guyatt GH. The impact of prophylactic dexamethasone on nausea and vomiting after laparoscopic cholecystectomy: a systematic review and meta-analysis. *Ann Surg* 2008; 248: 751-62.
 4. Dundee JW, McMillan CM. Clinical uses of P6 acupuncture antiemesis. *Acupunct Electrother Res* 1990; 15: 211-5.
 5. Arnberger M, Stadelmann K, Alischer P, Ponert R, Melber A, Greif R. Monitoring of neuromuscular blockade at the P6 acupuncture point reduces the incidence of postoperative nausea and vomiting. *Anesthesiology* 2007; 107: 903-8.
 6. Kim KS, Koo MS, Jeon JW, Park HS, Seung IS. Capsicum plaster at the Korean hand acupuncture point reduces postoperative nausea and vomiting after abdominal hysterectomy. *Anesth Analg* 2002; 95: 1103-7.
 7. Liu YY, Duan SE, Cai MX, Zou P, Lai Y, Li YL. Evaluation of transcutaneous electroacupoint stimulation with the train-of-four mode for preventing nausea and vomiting after laparoscopic cholecystectomy. *Chin J Integr Med* 2008; 14: 94-7.
 8. Frey UH, Funk M, Löhlein C, Peters J. Effect of P6 acustimulation on post-operative nausea and vomiting in patients undergoing a laparoscopic cholecystectomy. *Acta Anaesthesiol Scand* 2009; 53: 1341-7.
 9. Frerick H, Keitel W, Kuhn U, Schmidt S, Bredehorst A, Kuhlmann M. Topical treatment of chronic low back pain with a capsicum plaster. *Pain* 2003; 106: 59-64.
 10. Misra MN, Pullani AJ, Mohamed ZU. Prevention of PONV by acustimulation with capsicum plaster is comparable to ondansetron after middle ear surgery. *Can J Anaesth* 2005; 52: 485-9.
 11. Kim KS, Kim KN, Hwang KG, Park CJ. Capsicum plaster at the Hegu point reduces postoperative analgesic requirement after orthognathic surgery. *Anesth Analg* 2009; 108: 992-6.
 12. Koo MS, Kim KS, Lee HJ, Jeong JS, Lee JW. Antiemetic efficacy of capsicum plaster on acupuncture points in patients undergoing thyroid operation. *Korean J Anesthesiol* 2013; 65: 539-43.
 13. Apfel CC, Läärä E, Koivuranta M, Greim CA, Roewer N. A simplified risk score for predicting postoperative nausea and vomiting: conclusions from cross-validations between two centers. *Anesthesiology* 1999; 91: 693-700.
 14. Jo YY, Lee JW, Shim JK, Lee WK, Choi YS. Ramosetron, dexamethasone, and their combination for the prevention of postoperative nausea and vomiting in women undergoing laparoscopic cholecystectomy. *Surg Endosc* 2012; 26: 2306-11.
 15. Davis CJ, Harding RK, Leslie RA, Andrews PL. The organisation of vomiting as a protective reflex nausea and vomiting: mechanisms and treatment. In: *Advances in applied neurological sciences*. Edited by Davis CJ, Lake-Bakaar GV, Grahame-Smith DG. Cham, Springer International Publishing AG. 1986, volume 3, pp 65-75.
 16. Kim YS, Lee WK, Choi YS, Chae YK, Ahn SW, Lee A, et al. A comparison of the recovery characteristics of propofol-remifentanyl and desflurane-remifentanyl anesthesia under bispectral index (BIS) monitoring following laparoscopic cholecystectomy. *Anesth Pain Med* 2011; 6: 331-5.
 17. Kenny GN. Risk factors for postoperative nausea and vomiting. *Anaesthesia* 1994; 49 Suppl: 6-10.
 18. Ahmed N, Muslim M, Aurangzeb M, Zarin M. Prevention of postoperative nausea and vomiting in laparoscopic cholecystectomy. *J Med Sci* 2012; 20: 33-6.
 19. Stein DJ, Birnbach DJ, Danzer BI, Kuroda MM, Grunebaum A, Thys DM. Acupressure versus intravenous metoclopramide to prevent nausea and vomiting during spinal anesthesia for cesarean section. *Anesth Analg* 1997; 84: 342-5.
 20. Vincent CA, Richardson PH, Black JJ, Pither CE. The significance of needle placement site in acupuncture. *J Psychosom Res* 1989; 33: 489-96.
 21. Si XY, Wu LP, Li XD, Li B, Zhou YM. Dexamethasone combined with other antiemetics for prophylaxis after laparoscopic cholecystectomy. *Asian J Surg* 2015; 38: 21-7.