

Herpes Zoster in a Free Transverse Rectus Abdominis Myocutaneous Flap After Delayed Breast Reconstruction

Evidence of Spontaneous Reinnervation

Jeong Hui Lee, MD,* Hee Chang Ahn, MD, PhD,† and Min Sung Chung, MD, PhD*

Abstract: In concert with advances in surgical reconstruction techniques and improved survival after breast cancer, both the aesthetic and functional outcomes, especially sensory recovery, of breast reconstruction have been addressed. Most studies on sensory recovery in reconstructed breasts have utilized patients' subjective responses to touch, pain, temperature, and pressure. In contrast, this report describes a case of herpes zoster that developed in a free transverse rectus abdominis myocutaneous flap, which provides objective evidence of spontaneous reinnervation after breast reconstruction.

Key Words: herpes zoster, transverse rectus abdominis myocutaneous flap, spontaneous reinnervation

(*Ann Plast Surg* 2015;74: 693–694)

Breast reconstruction after mastectomy is a well-established part of the surgical treatment of breast cancer. In concert with advances in surgical reconstruction techniques and improved survival after breast cancer treatment, both the aesthetic and functional outcomes, especially sensory recovery, of breast reconstruction have been addressed.^{1–4} Most studies on sensory recovery in reconstructed breasts have used patients' subjective responses to touch, pain, temperature, and pressure.^{2–4} In contrast, this report describes a case of herpes zoster that developed in a free transverse rectus abdominis myocutaneous (TRAM) flap, which objectively demonstrates the pathway of spontaneous reinnervation after breast reconstruction.

PATIENT REPORT

A 50-year-old woman underwent a left modified radical mastectomy for stage II breast cancer. After surgery, the patient received 6 cycles of chemotherapy, radiation therapy, and 5 years of endocrine therapy with tamoxifen. Six years after surgery, the patient underwent breast reconstruction using a muscle-sparing free TRAM flap. Another 6 years after the reconstructive surgery, the patient presented to our clinic with 1 week of a painful rash on her chest wall. Physical examination revealed an erythematous vesicular rash along the T5 dermatome of her left hemithorax, crossing over her surgical scars to reach the edge of her reconstructed areola (Fig. 1). Because the rash had the classic appearance and symptoms of herpes

zoster, a skin biopsy was not performed to rule out metastasis. There was no evidence of breast cancer recurrence on laboratory evaluation or imaging studies. The patient was treated with antiviral therapy and the skin lesions disappeared without sequelae (Fig. 2).

A sensory test was performed in the left reconstructed breast and compared with the result of the right nonoperated breast. The pressure threshold was measured with Semmes-Weinstein monofilaments (Touch-Test 20 piece Full kit; North Coast Medical, Inc) at 9 points of each breast. A single point was used for the nipple, and the 12-, 3-, 6-, and 9-o'clock areas were measured at the 3- and 6-cm distance from the nipple (Fig. 3).

Although general sensation was reduced compared with the normal right breast, sensation was recovered in the left reconstructed breast and almost the same pressure threshold was observed in the area within 3 cm of the nipple (Fig. 4).

DISCUSSION

The varicella zoster virus, the virus that causes chickenpox, remains latent in the dorsal root ganglia after primary infection. When the host's immune system fails to contain the virus, it usually spreads along a single sensory nerve and results in a localized painful rash in a dermatomal distribution.

Spontaneous reinnervation of a flap after breast reconstruction with autologous tissue has been described by many authors, but the mechanisms of the return of cutaneous sensation after breast reconstruction still remain unclear. It is not known whether the spontaneous ingrowth of the sensory nerves starts from the skin margins of the flap or from the deep surface of the mastectomy bed. However, some authors conclude that the return of sensation seems to come from both sides.^{3,5}

The patient in our case underwent reconstruction with a free TRAM flap, which leads to the hypothesis that the zoster virus spread along a regenerated sensory nerve that reinnervated the reconstructed breast. The presence of the herpes zoster around the reconstructed areola of the TRAM flap indicates continuity from the dorsal ganglia, through the intercostal nerves, and into the skin of the flap.

Shridharani et al⁶ systematically reviewed the literature addressing breast sensation after reconstruction. Their review showed that there was a consensus that sensation after breast reconstruction was considerably impaired in all groups and procedure types. In general, sensation to the deep inferior epigastric artery perforator (DIEP) flaps may recover better sensation than the TRAM flaps,

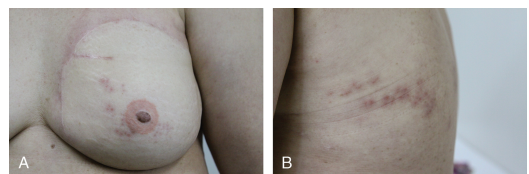


FIGURE 1. A, Herpes zoster eruption on the left chest wall involving the TRAM flap. B, Eruption on the left back along the distribution of the T5 dermatome.

Received November 8, 2013, and accepted for publication, after revision, May 27, 2014.

From the Departments of *Surgery, and †Plastic Surgery, Hanyang University Medical Center, Seoul, South Korea.

Conflicts of interest and sources of funding: none declared.

Reprints: Min Sung Chung, MD, PhD, Department of Surgery, Hanyang University Medical Center, 17 Haendang-dong, Seongdong-ku, Seoul 133-792, South Korea. E-mail: bovie@hanyang.ac.kr.

This is an open-access article distributed under the terms of the Creative Commons Attribution-NonCommercial-NoDerivatives 3.0 License, where it is permissible to download and share the work provided it is properly cited. The work cannot be changed in any way or used commercially.

Copyright © 2014 Wolters Kluwer Health, Inc. All rights reserved.

ISSN: 0148-7043/15/7406-0693

DOI: 10.1097/SAP.0000000000000289

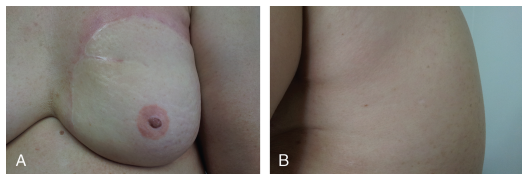


FIGURE 2. A, After antiviral therapy. The eruption on the left chest wall involving the TRAM flap disappeared. B, Eruption on the left back disappeared after antiviral therapy.

followed by the latissimus dorsi flaps, and finally implants. Innervated flaps have a greater magnitude of recovery, which occurs at an earlier stage compared with noninnervated flaps.

There have also been conflicting results about the areas with better sensory recovery in the free TRAM flap. Liew et al² found the best sensory recovery in the inferomedial part of the flap. Tindholdt and Tonseth⁷ reported significant pressure sensitivity when the medial was compared to the lateral side and the inferior to the superior of the flap. Blondeel et al⁸ found the lowest thresholds for non-innervated free TRAM in the medial half of the breast with slightly better sensory recovery superiorly. In our case, the central area within 3 cm of the nipple showed equally better sensory recovery compared to the outer, 6-cm distance area (Fig. 4). Although the result is quite different from other reports, the site with the best sensory recovery was consistent with the distribution of a herpes zoster eruption, which also objectively demonstrates spontaneous reinnervation after breast reconstruction.

Among the different types of breast reconstruction using the TRAM flap, the innervated free TRAM flaps show more sensate and earlier recovery than the noninnervated free TRAM flaps, whereas the free TRAM flaps are more sensate than pedicled TRAM flaps.^{1,3} In our case, the patient showed adequate return of sensation after 6 years with the delayed breast reconstruction using noninnervated free TRAM flap.

Tomita and Inoue⁹ first reported a case of herpes zoster in a TRAM flap 14 months after a chest wall reconstruction for recurrent breast cancer. Their case differs from ours in that they used a pedicled

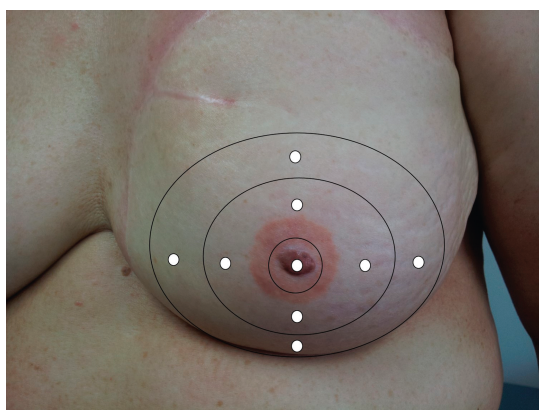


FIGURE 3. Nine sites were tested for sensation of the reconstructed, left breast and the nonoperated, right breast.

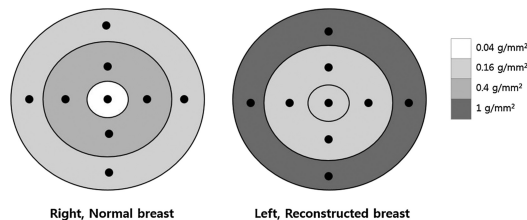


FIGURE 4. Pressure threshold scores from the Semmes-Weinstein test for the 9 sites of both breasts.

TRAM flap, the reconstruction was not for aesthetic purposes, and the patient was gravely ill, unconscious, and known to have disseminated metastases, preventing sensory examination of the flap. No skin biopsy was taken, and the rash did not resolve, therefore making it difficult to rule out skin metastasis.

Skin rashes in patients with breast cancer should raise suspicion for metastasis, which can be confused with herpes zoster.¹⁰ A skin biopsy is strongly recommended to exclude metastasis if the lesions are painless papules or nodules, rather than the classic painful vesicopustules of herpes zoster, or if the rash follows an atypical clinical course or distribution. In the present case, biopsy was not performed on the lesions because of the classic presentation and the complete resolution with antiviral therapy.

This seems to be the first case report of herpes zoster arising in a free TRAM flap after breast reconstruction, providing objective evidence of spontaneous reinnervation and sensory recovery in a reconstructed breast.

REFERENCES

1. Temple CL, Tse R, Bettger-Hahn M, et al. Sensibility following innervated free TRAM flap for breast reconstruction. *Plast Reconstr Surg*. 2006;117:2119–2127 discussion 2128–2130.
2. Liew S, Hunt J, Pennington D. Sensory recovery following free TRAM flap breast reconstruction. *Br J Plast Surg*. 1996;49:210–213.
3. Shaw WW, Orringer JS, Ko CY, et al. The spontaneous return of sensibility in breasts reconstructed with autologous tissues. *Plast Reconstr Surg*. 1997;99:394–399.
4. Santanelli F, Longo B, Angelini M, et al. Prospective computerized analyses of sensibility in breast reconstruction with non-reinnervated DIEP flap. *Plast Reconstr Surg*. 2011;127:1790–1795.
5. Place MJ, Song T, Hardesty RA, et al. Sensory reinnervation of autologous tissue TRAM flaps after breast reconstruction. *Ann Plast Surg*. 1997;38:19–22.
6. Shridharani SM, Magarakis M, Stapleton SM, et al. Breast sensation after breast reconstruction: a systematic review. *J Reconstr Microsurg*. 2010;26:303–310.
7. Tindholdt TT, Tonseth KA. Spontaneous reinnervation of deep inferior epigastric artery perforator flaps after secondary breast reconstruction. *Scand J Plast Reconstr Surg Hand Surg*. 2008;42:28–31.
8. Blondeel PN, Demuyneck M, Mete D, et al. Sensory nerve repair in perforator flaps for autologous breast reconstruction: sensational or senseless? *Br J Plast Surg*. 1999;52:37–44.
9. Tomita K, Inoue K. Cutaneous reinnervation of the rectus abdominis musculocutaneous flap after chest wall reconstruction: development of herpes zoster in the transplanted musculocutaneous flap. *Ann Plast Surg*. 1998;41:191–193.
10. Williams LR, Levine LJ, Kauh YC. Cutaneous malignancies mimicking herpes zoster. *Int J Dermatol*. 1991;30:432–434.