



## Case Report

# Pancreaticoduodenectomy in Patients With a History of Total Gastrectomy for Stomach Cancers

Sangchul Yun<sup>1</sup>, Dongho Choi<sup>2</sup>

<sup>1</sup>Department of Surgery, Soonchunhyang University College of Medicine, Seoul, Korea

<sup>2</sup>Department of Surgery, Hanyang Medical Center, Hanyang University School of Medicine, Seoul, Korea

Stomach cancer is one of the most common cancers, with the highest incidence occurring in South Korea. Total gastrectomy is a not uncommon operative procedure in the majority of cases. Recent reports demonstrate improved long-term survival following gastrectomy for the treatment of stomach cancer. Improvement in overall survival following gastrectomy has meant that pancreaticoduodenectomy (PD) will be increasingly encountered in surgical practice, with a greater need to appreciate postgastrectomy anatomy. Pancreaticoduodenal resection, in the setting of a previous gastrectomy and Roux-en Y esophagojejunostomy, may present major difficulties during the assessment, resection, and reconstruction phases of the operation if the altered gastrointestinal anatomy is not fully appreciated. The approach to pancreaticoduodenal resection in patients following total gastrectomy is not well described. Here we report PD in 2 patients with a history of total gastrectomy.

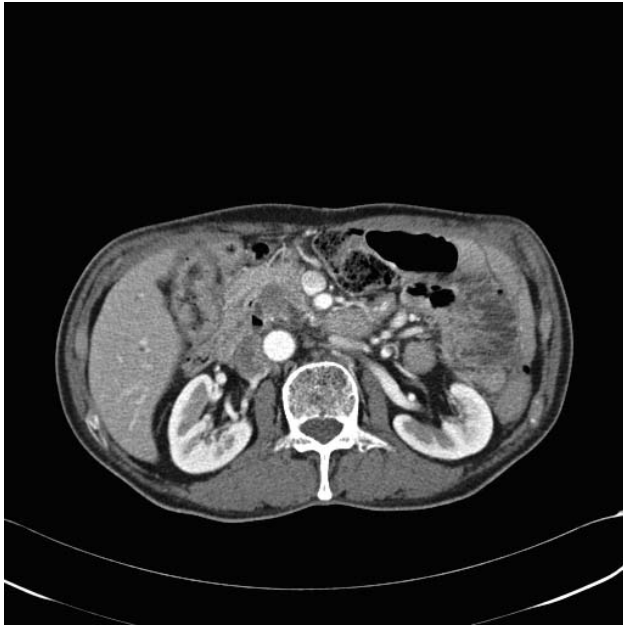### Case 1

Newly developed pancreatic head cancer was found during restaging abdominal computed tomography

(CT) in a 72-year-old male patient, whose history included distal gastrectomy and Billroth II anastomosis for stomach cancer 42 years ago and total gastrectomy with Roux-en Y esophagojejunostomy for recurrent stomach cancer 10 years ago (Fig. 1). He didn't present with specific symptoms. The physical examination revealed nonspecific findings. Gastrofiberscope showed a total gastrectomy state with esophagojejunostomy. Colonoscopy revealed a transverse colon polyp, and biopsy proved tubular adenoma. Positron emission tomography-CT (PET CT) revealed a 1.6 × 1.6 × 1.8-cm hypermetabolic mass in the pancreatic head due to pancreatic head cancer as well as reactive lymph nodes in the retropancreatic region without abnormal fluorodeoxyglucose uptake (Fig. 2). The blood tests determined the following measurements: hemoglobin, 13.6 g/dL; platelets, 276,000/mL; international normalized ratio (INR), 1.00; albumin, 4.2 g/dL; total bilirubin, 0.7 mg/dL; aspartate aminotransferase, 22 U/L; alanine aminotransferase, 19 U/L; and alkaline phosphatase (ALP), 175 U/L. Hepatitis markers and other tumor markers were negative. The surgical procedure took approximately 7 hours, 30 minutes. Intraoperatively there was a blood loss

Corresponding author: Dongho Choi, Department of Surgery, Hanyang Medical Center, Hanyang University School of Medicine, 222 Wangsimni-ro, Seongdong-gu, Seoul, Republic of Korea.

Tel.: +82-2-2290-8444; Fax: +82-2-2281-0224; E-mail: dhchoi8787@gmail.com



**Fig. 1** Abdominal CT scans of Case 1. An  $\approx$ 1.8-cm ill-defined mass was found in the pancreas head, with distal CBD obliteration and progression of upstream main p-duct dilatation.

of 500 mL, and no blood transfusion was required. The postoperative upper gastrointestinal (GI) series taken after 5 days showed no contrast leakage at the anastomosis site and no evidence of passage disturbance, and he was started on a liquid diet. Voiding difficulty developed postoperatively at 19 days, and a Foley catheter was inserted. There was continuous serous discharge at the main wound, and wound closure was delayed to 30 days postoperation. After 1 month, he complained of poor oral intake and was supported by peripheral nutrition. Finally, he was discharged at 47 days postoperation.

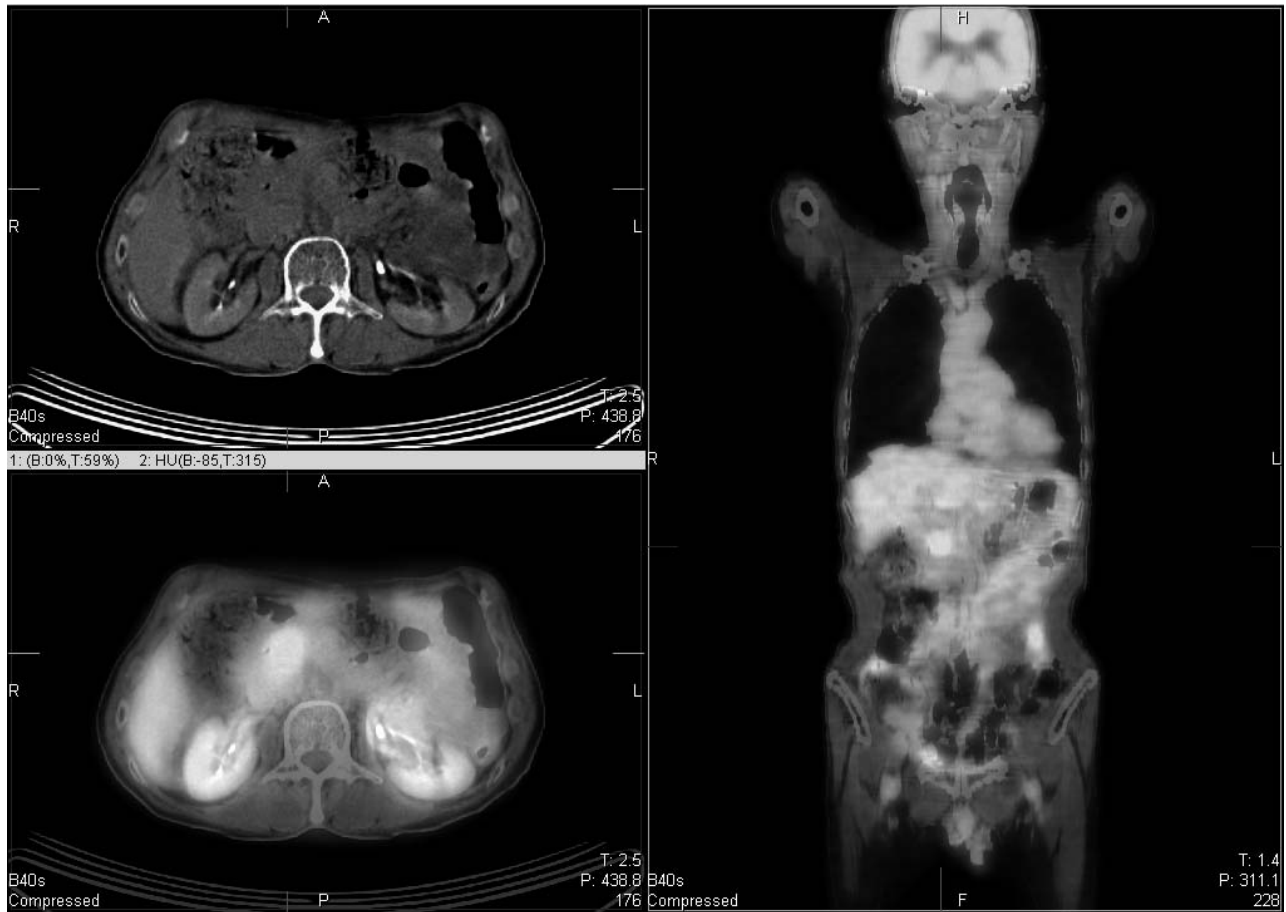## Case 2

Intraductal papillary mucinous neoplasm (IPMN) was found during restaging abdominal CT in an 80-year-old male patient, whose history included a cholecystectomy for a gallbladder stone 40 years ago and total gastrectomy with Roux-en Y esophagojejunostomy for stomach cancer 12 years ago. He didn't present with specific symptoms. The physical examination revealed nonspecific findings. Abdominal CT revealed the pancreas had an  $\approx$ 1.3-cm low-attenuation lesion in the head portion, with mild dilatation. There was marked dilatation of the peripheral portion of the intrahepatic duct (IHD)

and common hepatic duct (CBD). There was a high-attenuation lesion on the precontrast scan in the intraluminal portion of the CBD, with abrupt luminal narrowing of the distal CBD (Figs. 3, 4, and 5). We tried endoscopic retrograde cholangiopancreatography (ERCP), but failed to approach the duodenal papillary portion. Percutaneous transhepatic cholangioscopy (PTCS) using contrast showed both IHD dilatation and multiple filling defects in the CBD. There were many black stones retrieved with a basket, and dilatation of the obstructed distal CBD was performed. Biopsy was done for a papillary-shaped mass at the distal CBD, and the final pathology was tubulovillous adenoma. The blood tests determined the following measurements: hemoglobin, 13.0 g/dL; platelet, 198,000/mL; INR, 1.11; albumin, 3.9 g/dL; total bilirubin, 0.3 mg/dL; aspartate aminotransferase, 22 U/L; alanine aminotransferase, 19 U/L; and ALP, 103 U/L. Hepatitis markers and other tumor markers were negative. The surgical procedure took approximately 9 hours. Intraoperatively there was a blood loss of 1300 mL, and a 2-pint blood transfusion was required. The postoperative upper GI series taken after 7 days showed no contrast leakage at the anastomosis site and no evidence of passage disturbance, and he was started on a liquid diet. After 21 days, he complained of poor oral intake and was supported by peripheral nutrition. Finally, he was discharged at 33 days postoperation.

## Operative Procedure

Both patients had pancreatic cancer and IPMN for which PD was needed for surgical resection. Patients were placed supine on the operating table, and prophylactic antibiotics were administered. Sequential compression stockings were used throughout each case. A rainbow laparotomy was performed and the abdominal cavity explored for signs of metastatic disease and determination of Roux-en Y esophagojejunostomy anatomy. Local tumor respectability was assessed in the standard manner. An extended Kocher maneuver was performed to fully mobilize the duodenum, with an effort to palpate a clear plane between any tumor and the pulsation of the superior mesenteric artery. The gastroepiploic vein was divided as it entered the superior mesenteric vein. The superior mesenteric vein was identified, and a tunnel was created in the plane anterior to it and the portal vein behind the neck of the pancreas. A retrograde cholecystectomy was performed. Next, isolation and retraction



**Fig. 2** PET CT scan of Case 1. There was a  $1.6 \times 1.6 \times 1.8$ -cm hypermetabolic mass in the pancreatic head and small lymph nodes in the retropancreatic region without FDG uptake. Physiologic uptakes of the anastomotic site of the esophagus and small intestinal loops.

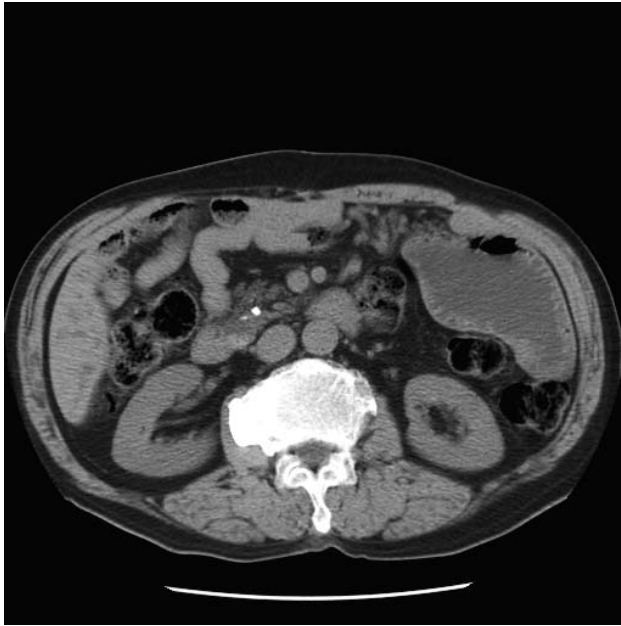of the distal common bile duct and ligation of the gastroduodenal artery were performed. The portal vein was exposed, and a tunnel was created anterior to it and traced to the tunnel made previously inferiorly. A Nelaton catheter was inserted in this groove.

Once resectability was determined, the Roux-en Y esophagojejunostomy anatomy was further delineated. A standard Roux-en Y esophagojejunostomy was identified, with a retrocolic Roux limb passing to the jejunal pouch. The proximal jejunum was divided approximately 5 to 10 cm from the ligament of Treitz at the previous jejunojejunostomy site, and the mesenteric vessels were ligated close to the intestinal wall. The bile duct was divided at this time. The pancreatic neck was then transected across the tunnel previously formed anterior to the portal vein. Portal vein branches arising from the uncinate were divided and ligated. The specimen was then removed from the operative field. Intraoperative

frozen section was performed on the pancreatic and bile duct resection margins.

The jejunum was transected at 10 to 20 cm distal to the previous jejunojejunostomy anastomosis and closed using a linear stapler. The divided jejunum was brought up to the supracolic compartment in a retrocolic position through the mesocolic defect created after dividing the ligament of Treitz. In both cases, the newly made biliopancreatic limb was approximately 40 to 50 cm in length.

Pancreatic and biliary anastomoses were performed in a standard fashion in the supracolic compartment (Fig. 6). An end-to-side, duct-to-mucosa pancreaticojejunostomy was performed. External pancreatic stents were used with a negative suction system, which has been published by our group.<sup>1</sup> An end-to-side biliary anastomosis was formed using interrupted sutures. The previously placed transhepatic biliary stents were positioned across the anastomosis prior to complete reconstruction. New



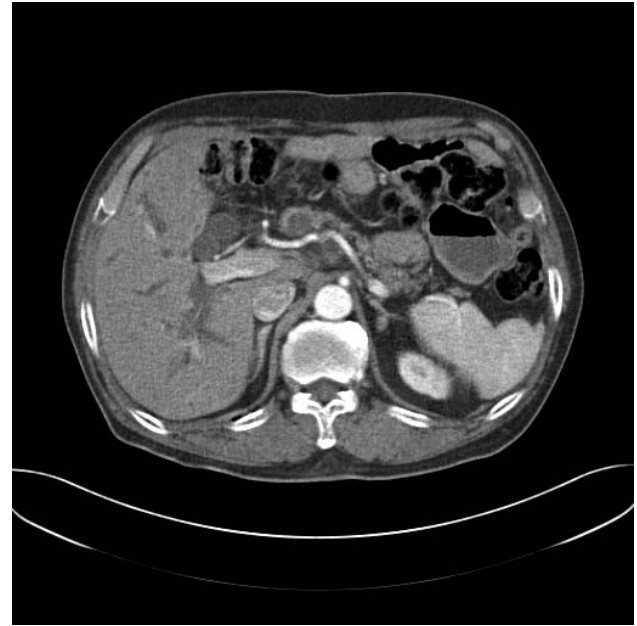**Fig. 3** Abdominal CT scans of Case 2. There is high attenuation lesion on the precontrast scan in the intraluminal portion of the CBD, with abrupt luminal narrowing of the distal CBD. There is no definite wall thickening of the bile ducts. Pancreas shows an 1.3-cm low-attenuation lesion in head portion with mild dilatation.

jejunojunctionostomy was performed. A few interrupted sutures were placed between the jejunum, retroperitoneum, and small bowel mesentery to close small gaps and prevent further jejuna migration into the supracolic compartment. Care was taken to ensure that the previous jejunojunctionostomy was not kinked and that there would be no tension on the pancreatic and biliary anastomoses (Fig. 6).

Abdominal drains were placed adjacent to the biliary and pancreatic anastomoses. Feeding jejunostomy tubes were not used. The previous esophagojejunal anastomosis was checked at the end to ensure to there was no damage to this area.

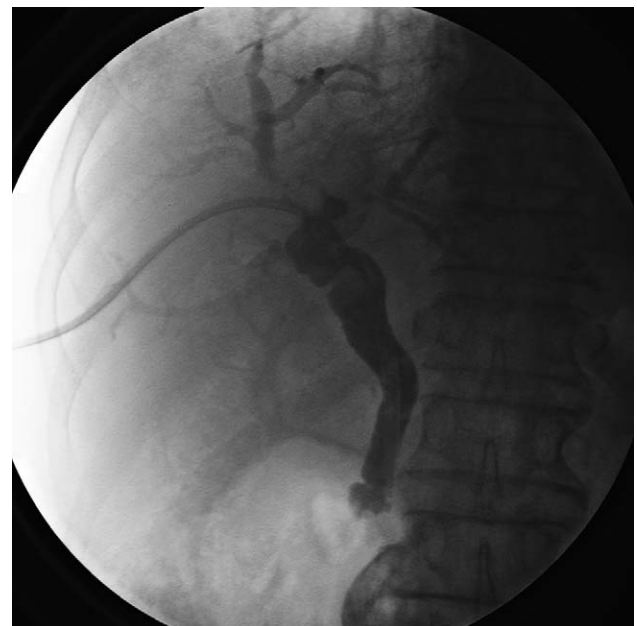Otreotide was not administered in these cases. Nasogastric tubes were not inserted. Patients were managed in an intensive-care setting for 24 hours. A liquid diet was commenced on day 5 postoperatively and progressed as tolerated. Drain amylase levels were measured on days 1, 3, 5, and 10 postoperation, and drains were removed accordingly thereafter.

There were no complications in the 2 patients, and outcomes are summarized (Table 1). The mean operative blood loss was 900 mL. The mean operative time was 8 hours, 15 minutes. There were

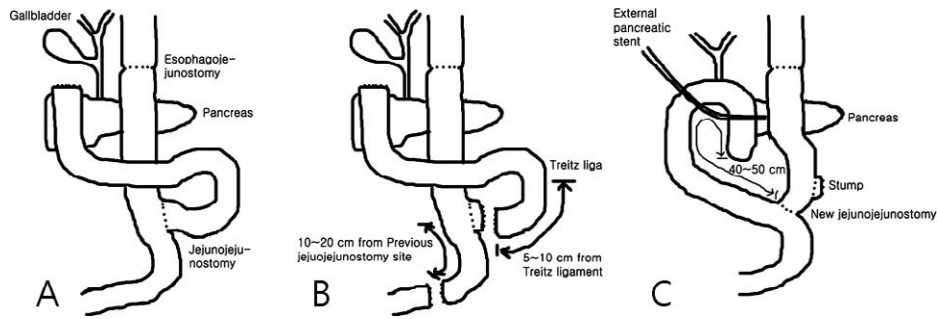


**Fig. 4** There is marked dilatation of the peripheral portion of the IHD and CBD. The patient showed definite IPMN mass, indicating possible cancer change in the mass.

2 intraoperative blood transfusions for 1 patient. The mean length of surgical intensive care stay was 1 day, and patients were discharged home by days 34 and 47 postoperation. The final pathology in both



**Fig. 5** PTCS of Case 2. The PTCS catheter was placed at the distal CBD.



**Fig. 6** (A) Schematic configuration of operative finding of PD after total gastrectomy. Classical Roux-en Y esophagojejunostomy state was found. (B) The previous jejunojejunostomy site was divided for specimen retrieval, and distal jejunum was transected at 10 to 20 cm distal to the previous jejunojejunostomy anastomosis site. (C) An end-to-side, duct-to-mucosa pancreaticojejunostomy was performed with newly made biliopancreatic limb. External pancreatic stents were used with a negative suction system. An end-to-side biliary anastomosis was done using interrupted sutures.

*Table 1 Demographic characteristics of two patients*

	Case 1	Case 2
Sex/age	Male/79 y old	Male/80 y old
Symptoms	None	None
Body mass index	18	19.15
Past operation history	Distal gastrectomy, B-II (42 y ago), total gastrectomy, Roux-en Y esophagojejunostomy (10 y ago, recurrent stomach cancer)	Cholecystectomy (40 y ago), total gastrectomy, Roux-en Y esophagojejunostomy (12 y ago)
Comorbidities	-	Idiopathic pulmonary fibrosis
Smoking	none	54 pack-years
Albumin, g/dL	4.2	3.9
Total protein, g/dL	7.3	6.2
Total bilirubin, mg/dL	0.7	0.3
Hemoglobin, g/dL	13.6	13.0
Carcinoembryonic antigen, ng/mL	2.98	1.39
Carbohydrate antigen 19-9, U/mL	57.87	27.05
a-fetoprotein, ng/dL	Not checked	3.91
Imaging findings	≈1.8-cm ill-defined mass in pancreatic head, with distal CBD obliteration and progression of upstream main pancreatic duct dilatation	≈1.3-cm low-attenuation lesion in head portion with mild dilatation. High-attenuation lesion on precontrast scan in intraluminal portion of the CBD with abrupt luminal narrowing of the distal CBD.
Perioperative biliary drainage	+	+
Estimated blood loss	500 mL	1300 mL
Blood transfusion	none	2 pint
Operation time	7 h 30 min	9 h
Intensive care unit stay	1 day	1 day
Length of hospital stay	47 days	34 days
Final pathology	Pancreas: adenocarcinoma, poorly differentiated; CBD: extension of adenocarcinoma with frequent lymphatic invasion; lymph node: metastatic carcinoma in 1 lymph node	Ampulla of vater: tubulovillous adenoma; pancreas: intraductal papillary mucinous tumor
Complication	None	None
Follow-up	6 mo	6 mo

CBD, common bile duct.

cases was pancreatic head cancer and IPMN. Both patients were well at last follow-up.

## Discussion

With the success of total gastrectomy for the treatment of stomach cancer, the long-term survival of these patients is likely to increase annually. A major resectional surgery for malignancy status post-gastric bypass poses a technical challenge to the surgeon. The approach to PD in patients with a history of Roux-en Y esophagojejunostomy requires a modified surgical approach, which has not been clearly defined. These patients usually have a higher rate of comorbidities. The abdomen is scarred with multiple adhesions from the previous bypass. A major resectional surgery may, hence, become difficult due to the altered planes and anatomy. Naturally, there is an increasing need to understand Roux-en Y esophagojejunostomy anatomy and how it relates to other abdominal operations. But, patients with a gastric bypass who develop periampullary neoplasms are peculiar, as subsequent endoscopic evaluation of the gastric remnant and duodenum is difficult.<sup>2</sup> It hinders routine preoperative assessment, as they cannot undergo an endoscopic ultrasound and ERCP is difficult. These patients, if in need of stenting, require a PTCS and stenting. In this report, both patients had a failed endoscopic approach to the duodenum. One patient underwent dilatation of obstructed distal CBD and received PTCS.

In the report by Rutkoski *et al*,<sup>3</sup> a classic PD was performed in a patient with pancreatic cancer and a history of Roux-en Y gastric bypass. The remnant biliopancreatic limb was anastomosed to the remnant stomach. The small intestine was divided distal to the previous enteroenterostomy, and a second Roux limb was constructed for anastomosis to the pancreas and bile duct.

Nikfarjam *et al*<sup>4</sup> said that division of the jejunum 5 to 10 cm from the ligament of Treitz allows the jejunum to be passed up into the supracolic compartment behind superior mesenteric vessels, in the position that the duodenum normally occupies, without tension. But, in our experience, attempts at bringing the remnant biliopancreatic jejuna limb into the supracolic compartment are more likely to result in tension and produce kinking

at the previous jejunojejunostomy. So, we needed enough length of jejunum to get the pancreatic and biliary anastomoses without tension. In both our cases, the previous jejunojejunostomy was transected just to the enteroenteric anastomosis, and a more distal, new anastomosis of jejunojejunostomy was used, and then the remnant biliopancreatic jejuna limb was easily brought up into the supracolic compartment through the transverse mesocolon and was easily used for biliary and pancreatic anastomosis in a retromesenteric position without tension (Fig. 6). This technique preserved small bowel length and avoided formation of a blind pouch. Both patients made an uncomplicated surgical recovery and tolerated a full diet at the time of hospital discharge.

We have shown that PD can be safely performed following total gastrectomy. In most circumstances, the proximal jejunum is divided close to the ligament of Treitz and passed in a retromesenteric fashion for pancreatic and biliary anastomoses, performing modification of the Roux limb. Although there are possible alternative methods for reconstruction after pancreaticoduodenal resection in the setting of total gastrectomy, the method described appears safe and effective.

In summary, pancreaticoduodenal resection can be successfully performed following total gastrectomy with en-bloc excision of duodenum, gall bladder, and the remnant pancreas and bile duct.

## References

1. Kim Z, Kim J, Min JK, Hur KY, Choi D, Seo D *et al*. Negative pressure external drainage of the pancreatic duct in pancreaticoduodenectomy. *Hepatogastroenterology* 2010;**57**(99-100):625-630
2. Martinez J, Guerrero L, Byers P, Lopez P, Scagnelli T, Azuaje R *et al*. Endoscopic retrograde cholangiopancreatography and gastroduodenoscopy after Roux-en-Y gastric bypass. *Surg Endosc* 2006;**20**(10):1548-1550
3. Rutkoski JD, Gagne DJ, Volpe C, Papasavas PK, Hayetian F, Caushaj PF. Pancreaticoduodenectomy for pancreatic cancer after laparoscopic Roux-en-Y gastric bypass. *Surg Obes Relat Dis* 2008;**4**(4):552-554; discussion 554-555
4. Nikfarjam M, Staveley-O'Carroll KE, Kimchi ET, Hardacre JM. Pancreaticoduodenectomy in patients with a history of Roux-en Y gastric bypass surgery. *JOP* 2009;**10**(2):169-173