

Clinical Characteristics of Microscopic Colitis in Korea: Prospective Multicenter Study by KASID

Young Sook Park^{*,||}, Dae Hyun Baek^{*}, Won Ho Kim^{†,||}, Joo Sung Kim^{‡,||}, Suk-Kyun Yang^{§,||}, Sung-Ae Jung^{||,||}, Byung Ik Jang^{||,||}, Chnag Hwan Choi^{#,||}, Dong Soo Han^{*,*,||}, Young-Ho Kim^{††,||}, Yong Woo Chung^{‡‡,||}, Sang Woo Kim^{‡‡,||}, and You Sun Kim^{§§,||}

Departments of Internal Medicine, ^{*}Eulji University College of Medicine, [†]Yonsei University College of Medicine, [‡]Seoul National University College of Medicine, [§]University of Ulsan College of Medicine, [#]Ehwa Womans University School of Medicine, ^{††}Yeungnam University College of Medicine, ^{‡‡}Chung Ang University College of Medicine, ^{‡‡}Hanyang University College of Medicine, ^{††}Sungkyunkwan University School of Medicine, ^{‡‡}Hallym University College of Medicine, ^{§§}Inje University College of Medicine, and ^{||}Korean Association for the Study of the Intestinal Disease (KASID), Korea

Background/Aims: Microscopic colitis (MC) encompasses collagenous and lymphocytic colitis and is characterized by chronic diarrhea. In cases of MC, colonic mucosae are macroscopically normal, and diagnostic histopathological features are observed only upon microscopic examination. We designed a prospective multicenter study to determine the clinical features, pathological distribution in the colon and prevalence of MC in Korea. **Methods:** We prospectively enrolled patients having watery diarrhea no more than 3 times a day between March 2008 and February 2009. We obtained patient histories and performed colonoscopies with random biopsies at each colon segment. **Results:** A total of 100 patients with chronic diarrhea were enrolled for a normal colonoscopy and stool exam. MC was observed in 22 patients (22%) (M:F 1.2:1; mean age, 47.5 years). Of those 22 patients, 18 had lymphocytic colitis and 4 had collagenous colitis. The entire colon was affected in only 3 cases (13.6%), the ascending colon in 6 cases (27.2%), the transverse colon in 3 cases (13.6%), and the left colon in 3 cases (13.6%). More than 2 segments were affected in 7 cases (31.8%). Nonsteroidal anti-inflammatory drug-associated MCs were observed in 4 cases (18.2%), 3 of which showed improved diarrhea symptoms following discontinuation of the medication. Frequently associated symptoms were abdominal pain and weight loss. Autoimmune diseases were observed in 4 cases (18.2%). Half of the 22 patients with MC improved with conservative care by loperamide or probiotics. **Conclusions:** In a prospective multicenter study of Korean patients with chronic diarrhea, the frequency of MC was found to

be approximately 20%, similar to the percentage observed in Western countries. Therefore, the identification of MC is important for the adequate management of Korean patients with chronic diarrhea. (**Gut Liver 2011;5:181-186**)

Key Words: Chronic diarrhea; Microscopic colitis; Collagenous colitis; Lymphocytic colitis

INTRODUCTION

The main symptom of microscopic colitis is chronic watery diarrhea. Despite the grossly normal mucosa, it displays typical histologic abnormalities. Microscopic colitis is classified as collagenous colitis, in which subepithelial collagen layer thickens around 10 to 100 μ m and lymphocytic colitis, characterized by the presence of a lymphocytes more than 20 in 100 epithelial cells.¹

In Western countries, it has become apparent that microscopic colitis is a common cause of diarrhea, particularly in middle-aged or elderly patients.² Its etiology and pathophysiology has not been proven yet, but it seems to associate with using of various medication such as lansoprazole and non-steroidal anti inflammatory drugs (NSAIDs).^{3,4} Also many reports shows microscopic colitis is associated with celiac disease and autoimmune diseases, such as Type I diabetes and thyroid disease.²

There has been a rapid increase in researches and publications on this disease entity. In Korea, interest about microscopic colitis has been increasing, and some clinical reports by single center are available. Therefore, Korean Association for the Study

Correspondence to: Young Sook Park

Department of Internal Medicine, Eulji Medical Center, Eulji University College of Medicine, 14 Hangeulbiseok-gil, Nowon-gu, Seoul 139-872, Korea
Tel: +82-2-970-8207, Fax: +82-2-970-8621, E-mail: Pys1109@eulji.ac.kr

Received on July 23, 2010. Accepted on January 3, 2011.

pISSN 1976-2283 eISSN 2005-1212 DOI: 10.5009/gnl.2011.5.2.181

© This is an Open Access article distributed under the terms of the Creative Commons Attribution Non-Commercial License (<http://creativecommons.org/licenses/by-nc/3.0>) which permits unrestricted non-commercial use, distribution, and reproduction in any medium, provided the original work is properly cited.

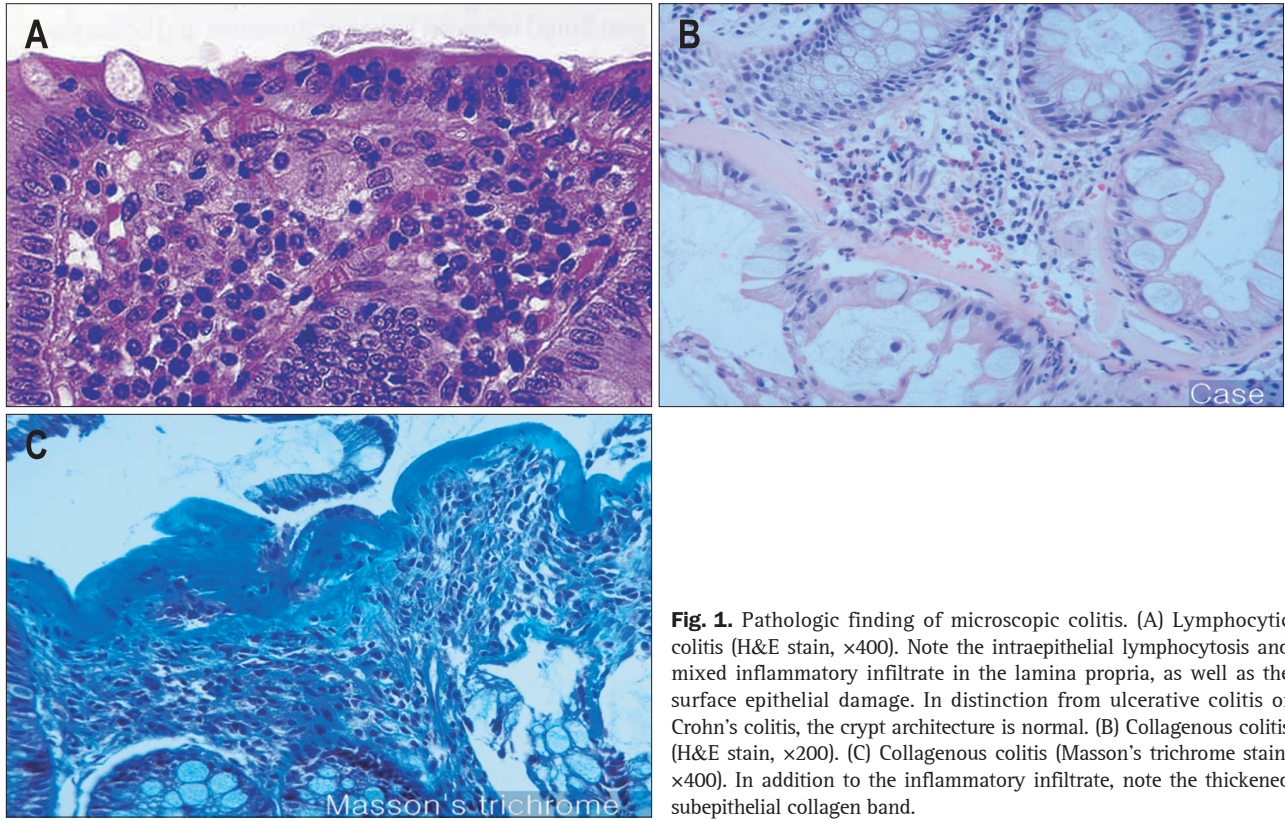


Fig. 1. Pathologic finding of microscopic colitis. (A) Lymphocytic colitis (H&E stain, $\times 400$). Note the intraepithelial lymphocytosis and mixed inflammatory infiltrate in the lamina propria, as well as the surface epithelial damage. In distinction from ulcerative colitis or Crohn's colitis, the crypt architecture is normal. (B) Collagenous colitis (H&E stain, $\times 200$). (C) Collagenous colitis (Masson's trichrome stain, $\times 400$). In addition to the inflammatory infiltrate, note the thickened subepithelial collagen band.

of the Intestinal Disease (KASID) designed of research on frequency of microscopic colitis and clinical pattern of the patient with chronic diarrhea in Korea through the prospective multi-center study.

MATERIALS AND METHODS

1. Subjects

It was a manifold collaboration research from March 2008 to February 2009 with the adults over 15 years old with chronic diarrhea. Chronic diarrhea is defined as watery diarrhea more than 3 times a day at least for 4 weeks. However, those cases showing inflammation in colonic mucosa such as inflammatory bowel disease and abnormal stool exam showing steatorrhea and parasite infection were excluded in the research.

2. Methods

Two mucosal biopsies were taken from every segment of the colon (cecum, ascending colon, transverse colon, descending colon, and sigmoid colon) and from the rectum. The histological features of microscopic colitis are chronic inflammatory cells infiltrating the lamina propria of mucosa, increase of intraepithelial lymphocyte (IEL) and epithelial damage, such as flattening and detachment. The number of IEL is more than 20 in 100 epithelial cells in lymphocytic colitis (LC) (Fig. 1A). The thickness of subepithelial collagen layer is more than 10 μm in collagenous colitis (CC) (Fig. 1B and C). Also we divided into

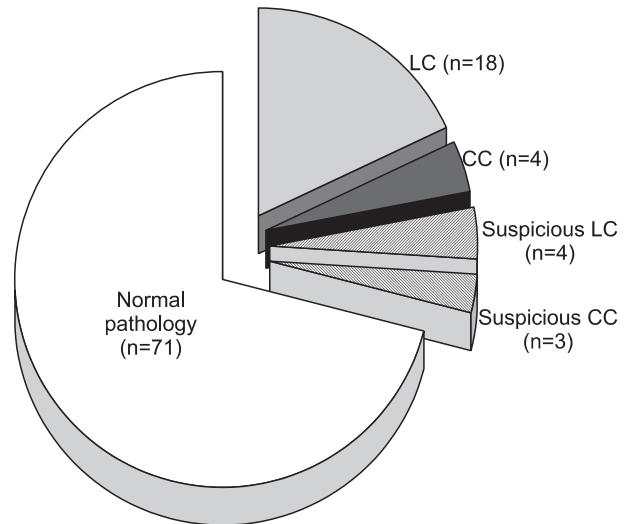


Fig. 2. Diagnostic rate of microscopic colitis. LC, lymphocytic colitis; CC, collagenous colitis.

two subgrouped, if the case shows the number of lymphocyte is 10 to 20 in 100 epithelial cells diagnosed as suspicious LC and the thickness of the collagen layer is 5 to 10 μm diagnosed as suspicious CC.

3. Statistical analysis

Independent t-test was used for ages, the number of diarrhea and the period between microscopic colitis (MC) group

Table 1. Clinical Characteristics of the Enrolled Patients

Feature	Normal pathology (n=71)	Suspicious LC (n=4)	Suspicious CC (n=3)	LC (n=18)	CC (n=4)
Mean age, yr	44.3±17.8	51±14.1	44.67±13.3	43.17±19.0	67.0±9.6
M:F	1.45:1	1:1	2:1	2:1	0:4
Duration, wk	46.0±79.5	131.0±246.0	121.33±155.2	150.7±232.0	16.5±22.4
Frequency	4.60±2.4	6.3±2.6	3.3±0.58	4.1±2.5	5.3±1.9

LC, lymphocytic colitis; CC, collagenous colitis.

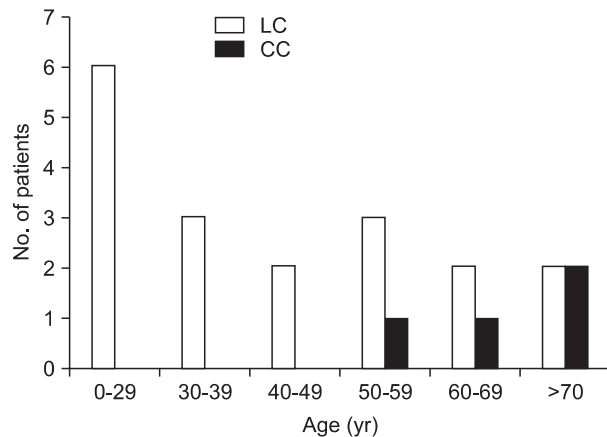


Fig. 3. Age distribution of microscopic colitis. LC, lymphocytic colitis; CC, collagenous colitis.

and normal tissue group. For the comparisons of MC group and suspicious MC group and normal tissue, one-way ANOVA was used. Chi-square test was used for relation between drugs and autoimmune disease, and for statistics, SPSS 12.0 program (SPSS Inc., Chicago, IL, USA) was used.

RESULTS

1. Clinical characteristics of patients

We enrolled 100 patients with chronic diarrhea, 58 males and 42 females, who show normal colonoscopic finding. The mean age was 45 years old. Twenty-two patients were diagnosed as microscopic colitis (22%), 10 were females and mean age was 44.9±18.0 years. Seven patients were diagnosed with suspicious microscopic colitis (7%). There were 18 cases of lymphocytic colitis, 4 cases of collagenous colitis, 4 of suspicious LC and 3 of suspicious CC (Fig. 2). There was no significant difference among MC group, suspicious MC group and normal tissue group in clinical characteristics. All three groups varied in the number of diarrhea and the period of having diarrhea (Table 1). While patients with microscopic colitis with lymphocytic colitis were in their 20s, patients with collagenous colitis were in their 70s (Fig. 3).

Table 2. Distribution of Involved Colonic Segments of Microscopic Colitis

Distribution	LC (n=18)	CC (n=4)
Ascending colon	5 (27.8)	1 (25.0)
Transverse colon	2 (11.1)	1 (25.0)
Descending, sigmoid colon, rectum	3 (16.7)	0
Entire colon	1 (5.5)	2 (50.0)
More than 2 segments	7 (38.9)	0

Data are presented as number (%).

LC, lymphocytic colitis; CC, collagenous colitis.

2. Distribution of microscopic colitis

Followings are the pathological lesions of 22 patients: 6 cases in the ascending colon (30%), 3 in the transverse colon (15%), 3 in the descending colon and the rectum (15%). Only 3 showed diffuse distribution throughout the colon (15%), and more than two segments of the colon were involved in 5 patients (15%) (Table 2).

3. Drug related microscopic colitis

From 100 days prior to the development of diarrhea, we took drug history including NSAIDs, proton pump inhibitor (PPI), lipid lowering agents, aspirin and other anticoagulants for more than 2 weeks. The relation between each medicine and microscopic colitis was not statistically significant. However, 7 of the 22 patients with microscopic colitis (32%) showed suspicious drug consumption. Taking NSAIDs was in 4 cases (18.2%), one case taking aspirin and clopidogrel and another case taking aspirin, simvastatin, and NSAIDs. NSAIDs were related with 2 patients with collagenous colitis and 2 lymphocytic colitis. Two patients with collagenous colitis improved diarrhea a month after discontinuing the suspicious NSAIDs as well as aspirin and clopidogrel.

4. Relation to autoimmune disease

Among 22 patients with microscopic colitis, 4 patients (18.2%) presented autoimmune disease: 2 thyroid disease, 1 type 1 diabetes, and 1 idiopathic hypereosinophilic syndrome. There is significant correlation between microscopic colitis and autoim-

mune disease ($p < 0.05$).

5. Relation to irritable bowel syndrome

There was only one patient showing symptoms of irritable bowel syndrome (ROME III) of 22 patients diagnosed as microscopic colitis.

6. Treatment of microscopic colitis

The improvement of diarrhea after probiotics shown in 4 cases (18.2%), loperamide was medicated in 8 cases (36.4%), budesonide was in one case (4.5%), mesalazine was in one case (4.5%). Other 3 cases show relief after quitting suspicious drug and there were 5 cases were following by conservative treatment.

DISCUSSION

Chronic diarrhea is a common symptom in the division of gastroenterology and, microscopic colitis may be one of the important causes of chronic diarrhea.⁵

The terminology, microscopic colitis, first mentioned in the case of a patient with chronic diarrhea whose colon shows no visible abnormality but infiltration in lymphocyte on tissue biopsy in 1980.⁶ Collagenous colitis was first described by Lindström⁵ in 1976 and lymphocytic colitis by Lazenby *et al.*⁶ in 1989.

In Western countries, the incidence rate of collagenous colitis is 0.6-2.3/100,000, while the prevalence rate is 10-15.7/100,000. The incidence rate of lymphocytic colitis is 3.1/100,000, while the prevalence rate is 14.4/100,000.^{7,8} According to the current report from Olesen *et al.*,² in Western, an incidence rate of collagenous colitis increases from 3.7/100,000 to 6.1/100,000, and that of lymphocytic colitis increase from 3.1/100,000 to 5.7/100,000 every year. In Western countries, the male to female ratio is 1:3 in collagenous colitis and 1:2.5 in lymphocytic colitis. The average age is 63.8 for female and 60.7 for male.⁹

There are no available data in Korea and Asia about the incidence and prevalence of microscopic colitis. However, previous single center study on 2008 reported that the domestic frequency was 15%.⁸ According to this multicenter study, the diagnostic frequency of microscopic colitis among chronic diarrhea is 22%. It means that microscopic colitis is not a rare disease entity any more and shows increasing frequency in Korea as well as in Western countries. This study also shows that there is difference in sex ratio and average age in Korea compared to Western. Especially, lymphocytic colitis was diagnosed among much younger patient, 20s-40s, compared to previous research.^{1,2,5,7-9} It could mean that the young patients with chronic diarrhea might have been misdiagnosed as irritable bowel syndrome without tissue biopsy.¹⁰

The cause of microscopic colitis is not yet clear, bile acids, toxin, infection,¹¹⁻¹³ and especially drugs such as NSAIDs, H₂

blocker, PPI¹⁴ seems to play an important role in microscopic colitis. These factors increase bowel permeability and cause an influx of antigens into lamina propria. And then these induce inflammation, epithelial cell may be involved in immune system additionally.^{15,16} This hypothesis is supported to, in contrast to when exposed to fecal materials, not reaction of inflammation when it was not exposed to fecal materials such as ileostomy. But we could not find accumulation of immune complex, complement, immunoglobulin.

Microscopic colitis patients presented with autoimmune disease such as thyroid disease, type I diabetes and rheumatic arthritis and its rate is 40% to 50%.¹⁷ There is a higher prevalence rate of hypercholesterolemia and thyroid disease among patient with microscopic colitis.⁹ From this study, 18.2% of patient showed an association with autoimmune disease ($p < 0.05$). However, its correlation with each of the autoimmune disease has not been proved so far.

Collagenous colitis occurring group take NSAIDs 5 times more than the control group, and taking NSAIDs worsens the diarrhea and stopping them relieves the symptom. It is suggested that NSAIDs caused the inflammation during the initiative phase of the disease.^{18,19} Two cases of collagenous colitis patient taking NSAIDs in this study also resolved diarrhea after discontinuing the drug. It was reported that other drugs also may cause microscopic colitis. Aacarbose, aspirin, lansoprazole, ranitidine, sertraline, and ticlopidine have higher chance of causing the disease. Also, carbamazepine, flutamide, lisinopril, levodopa, benserazide, oxetorone, paroxetine, simvastatin, tardyferon, vinburnine are categorized as the causing drugs.^{3,4}

There is a theory that bacterial infection is one of the causes of microscopic colitis, based on the facts that biopsy specimen of microscopic colitis shows concomitant acute inflammation, collagenous colitis like a pathology after *C. difficile*²⁰ or *Y. enterocolitica*²¹ infection and relieve of symptom after antibiotics treatment in some patient, but the suspicious bacteria is not found yet.

Also, an increase of nitric oxide production by inducible nitric oxide synthase (iNOS) in colonic epithelium of microscopic colitis patient was observed and budesonide decreases iNOS mRNA, which shows clinical and histological improvement.¹

The cause of collagen deposit in collagenous colitis is not known yet. Basement membrane of epithelium in normal colon is composed of type III collagen and produced by fibroblast between crypts of colon mucosa, then it moves to superior portion of the organ along with the crypts and develop 5 to 7 μ m of collagen layer in subepithelium. However, the collagen layer consists of type I, III and VI and thickens from 7 to 80 μ m in collagenous colitis. A decrease of sodium absorption in lymphocytic colitis and a increase of chloride secretion in collagenous colitis induce diarrhea as a common symptom in both disease.²²

Microscopic colitis has a significant relation with irritable bowel syndrome. Although this study shows only one case fits

the standard criteria of IBS (ROMEIII), the Western study reports the 28% match and claims that colonoscopy with histology confirm is important in patients suspicious irritable bowel syndrome.²³

The distribution of microscopic colitis is not even. In some case of collagenous colitis, thickening of subepithelial collagen layer distributes on ascending and transverse colon, it does not appear in the sigmoid colon and rectum.²⁴ Also in lymphocytic colitis, some of lesion spread in ascending and transverse colon, therefore sigmoidoscopy is not enough to diagnose the microscopic colitis. Nine cases out of 22 cases (40.9%) of microscopic colitis in this study are diagnosed in ascending and transverse colon.

A group of patients with suspicious lymphocytic colitis and suspicious collagenous colitis in this study, who show increase in intraepithelial lymphocytes or thickening of collagen layer which doesn't fit the definition, is still to be concerned about whether the condition will progress or not. There is no report on this, but it should be followed up with concern.

As far as the treatment of microscopic colitis is concerned, patients should avoid caffeine and alcohol which worsen the symptom. The drug therapy should be accompanied with the diet modification. The principle of treatment is step up therapy. When symptom is mild, loperamide and cholestyramine can be administered, if there is no reaction to these drugs, budesonide, and aminosalicilates can be used. Also, when resistance to steroid occurs, immunosuppressive drugs, such as azathioprine and methotrexate, can be administered. It has been suggested that budesonide, 9 mg/day for 6 to 8 weeks, is the most effective.²⁵ However, the limitation of budesonide is that when treatment is stopped, the symptom is recurrent. Therefore there is further research to find the right period of treatment.¹ The symptoms were controlled by stopping causing drugs, and budesonide and mesalazine were added for one case and the treatment result is being observed.

Long term prognosis of microscopic colitis is favorable in general. One study reported that in the case of collagenous colitis, 63% was resolved for 3.5 years and only 29% of the case needed continuing drug therapy.¹⁵ In the case of lymphocytic colitis, more than 80% cases show improvement in clinical symptoms and histology for 38 months. There are reports of malignancy in the cases of collagenous colitis with breast cancer (2.34%), lung cancer (1.75%), and colorectal cancer (2.82%). In the case of lymphocytic colitis, there were patients with breast cancer (5.31%), lung cancer (1.06%), and prostate cancer (1.86%).² However, there were no statistically significant relation yet between microscopic colitis and malignancy including colorectal cancer. Therefore, it will be necessary to keep monitoring the 22 patients diagnosed with microscopic colitis in this study.

There has been an increase of the patients with chronic diarrhea diagnosed as microscopic colitis. This study tries to know

the frequency, clinical characteristics, causing factor and treatment result of microscopic colitis in Korea through multicenter prospective study. Although the frequency might have been higher than the actual case since the enrolled patient were treated in teaching hospital or institutional hospital, it suggests that the frequency of microscopic colitis in Korea is about the same level in Western countries. Further nation-wide study on the incidence and epidemiology, pathophysiology, and treatment of microscopic colitis will be expected in the future.

REFERENCES

1. Read NW, Krejs GJ, Read MG, Santa Ana CA, Morawski SG, Fordtran JS. Chronic diarrhea of unknown origin. *Gastroenterology* 1980;78:264-271.
2. Olesen M, Eriksson S, Bohr J, Järnerot G, Tysk C. Microscopic colitis: a common diarrhoeal disease. An epidemiological study in Örebro, Sweden, 1993-1998. *Gut* 2004;53:346-350.
3. Nyhlin N, Bohr J, Eriksson S, Tysk C. Systematic review: microscopic colitis. *Aliment Pharmacol Ther* 2006;23:1525-1534.
4. Tysk C, Bohr J, Nyhlin N, Wickbom A, Eriksson S. Diagnosis and management of microscopic colitis. *World J Gastroenterol* 2008;14:7280-7288.
5. Lindström CG. 'Collagenous colitis' with watery diarrhea: a new entity? *Pathol Eur* 1976;11:87-89.
6. Lazenby AJ, Yardley JH, Giardiello FM, Jessurun J, Bayless TM. Lymphocytic ("microscopic") colitis: a comparative histopathologic study with particular reference to collagenous colitis. *Hum Pathol* 1989;20:18-28.
7. Kao KT, Pedraza BA, McClune AC, et al. Microscopic colitis: a large retrospective analysis from a health maintenance organization experience. *World J Gastroenterol* 2009;15:3122-3127.
8. Lee SY, Jeon SW, Chung YJ, et al. Microscopic colitis in a single center study: clinical feature & characteristics. *Korean J Med* 2008;74:397-402.
9. Limsui D, Pardi DS, Camilleri M, et al. Symptomatic overlap between irritable bowel syndrome and microscopic colitis. *Inflamm Bowel Dis* 2007;13:175-181.
10. Tagkalidis P, Bhathal P, Gibson P. Microscopic colitis. *J Gastroenterol Hepatol* 2002;17:236-248.
11. Tremaine WJ. Collagenous colitis and lymphocytic colitis. *J Clin Gastroenterol* 2000;30:245-249.
12. Thomson RD, Lestina LS, Bensen SP, Toor A, Maheshwari Y, Ratcliffe NR. Lansoprazole-associated microscopic colitis: a case series. *Am J Gastroenterol* 2002;97:2908-2913.
13. Yagı K, Nakamura A, Sekine A, Watanabe H. Nonsteroidal anti-inflammatory drug-associated colitis with a histology of collagenous colitis. *Endoscopy* 2001;33:629-632.
14. Loftus EV. Microscopic colitis: epidemiology and treatment. *Am J Gastroenterol* 2003;98(12 Suppl):S31-S36.
15. Fernández-Bañares F, Salas A, Esteve M, Espinós J, Forné M, Viver JM. Collagenous and lymphocytic colitis: evaluation of clinical

- and histological features, response to treatment, and long-term follow-up. *Am J Gastroenterol* 2003;98:340-347.
16. Goff JS, Barnett JL, Pelke T, Appelman HD. Collagenous colitis: histopathology and clinical course. *Am J Gastroenterol* 1997;92:57-60.
 17. Bohr J, Tysk C, Eriksson S, Järnerot G. Collagenous colitis in Örebro, Sweden, an epidemiological study 1984-1993. *Gut* 1995;37:394-397.
 18. Fernández-Bañares F, Esteve M, Espinós JC, et al. Drug consumption and the risk of microscopic colitis. *Am J Gastroenterol* 2007;102:324-330.
 19. Beaugerie L, Pardi DS. Review article: drug-induced microscopic colitis - proposal for a scoring system and review of the literature. *Aliment Pharmacol Ther* 2005;22:277-284.
 20. Khan MA, Brunt EM, Longo WE, Presti ME. Persistent *Clostridium difficile* colitis: a possible etiology for the development of collagenous colitis. *Dig Dis Sci* 2000;45:998-1001.
 21. Bohr J, Nordfelth R, Järnerot G, Tysk C. *Yersinia* species in collagenous colitis: a serologic study. *Scand J Gastroenterol* 2002;37:711-714.
 22. Bo-Linn GW, Vendrell DD, Lee E, Fordtran JS. An evaluation of the significance of microscopic colitis in patients with chronic diarrhea. *J Clin Invest* 1985;75:1559-1569.
 23. Madisch A, Bethke B, Stolte M, Miehlke S. Is there an association of microscopic colitis and irritable bowel syndrome--a subgroup analysis of placebo-controlled trials. *World J Gastroenterol* 2005;11:6409.
 24. Tanaka M, Mazzoleni G, Riddell RH. Distribution of collagenous colitis: utility of flexible sigmoidoscopy. *Gut* 1992;33:65-70.
 25. Fernandez-Bañares F, Esteve M, Salas A, et al. Bile acid malabsorption in microscopic colitis and in previously unexplained functional chronic diarrhea. *Dig Dis Sci* 2001;46:2231-2238.