

## Unusual Foreign Bodies in the Urinary Bladder and Urethra Due to Autoerotism

Seung Jin Moon, Dai Hee Kim, Jae Hoon Chung, Jung Ki Jo, Young Woo Son, Hong Yong Choi, Hong Sang Moon

Department of Urology, Hanyang University, College of Medicine, Seoul, Korea

---

Most foreign bodies in the lower genitourinary tract are self-inserted via the urethra as the result of exotic impulses, psychometric problems, sexual curiosity, or sexual practice while intoxicated. Diagnosis of these foreign bodies can be done by clinical history, physical examination, and image studies of the patient. The treatment of foreign bodies is determined by their size, location, shape, and mobility. In most cases, minimally invasive procedures such as endoscopic removal are recommended to prevent bladder and urethral injuries. In some cases, however, surgical treatment should be done if the foreign bodies cannot be removed by the endoscopic procedure or further injuries are expected as a result of the endoscopic procedures. Herein we present 2 cases of self-inserted lower genitourinary foreign bodies with a brief review of the literature. **Int Neurourol J 2010;14:186-9.**

**Key words:** Foreign bodies, Urethra, Urinary bladder

---

Foreign bodies in the lower urinary tract are uncommon, but several cases have been reported. Foreign bodies have been inserted as the result of curiosity, autoerotic stimulation, or medical procedures [1]. The material of the foreign bodies has varied from wire, screw, or ball point pen to animals such as a snake [2]. The foreign body can remain for a long time with minimal discomfort. In most cases, however, the foreign body causes severe pain, hematuria, and urinary tract infection [3]. Procedures to remove such foreign bodies completely should be as simple as possible and result in minimal damage to the bladder and urethra [1]. Herein, we present two cases of self-inserted foreign bodies in the lower urinary tract with a brief review of the literature. In the first case, additional foreign bodies were

inserted by a patient in an attempt to remove a previously inserted rod-shaped foreign body. In the second case, a loop inserted by the patient became spontaneously knotted in the bladder when the patient tried to remove the loop.

### Case

#### Case 1

A 50-year-old man complaining of dysuria was referred to our clinic owing to aggravated frequency that had lasted for 1 week. The patient had a history of insertion of a plastic chopstick into the urethra three years ago for sexual pleasure. Furthermore, the patient had inserted a round magnet into his urethra to remove the chopstick. However, he failed to remove either

---

**Corresponding Author: Hong Sang Moon**

Department of Urology, Hanyang University, College of Medicine,  
249-1 Gyomun-dong, Guri, Gyunggi-do 471-701, Korea  
Tel: +82-31-560-2374 / Fax: +82-31-560-2372 / E-mail: moonuro@hanyang.ac.kr

Submitted: August 21, 2010 / Accepted (with revisions): October 21, 2010

the chopstick or the magnet. He then inserted an additional magnet to remove the previously inserted magnet, and these two magnets had become stuck together 1 week previously.

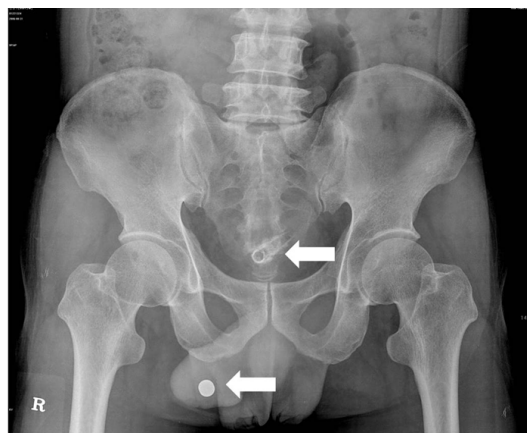
On the physical examination, a hard mass was palpated in the distal portion of the penis. Laboratory findings revealed microscopic hematuria and pyuria in routine urine analysis, but the results of the complete blood count and electrolyte profile were normal. Abnormal radio-opaque densities were observed in the penis and pelvic cavity on a plain X-ray. The radio-opaque density that was round shaped and measured 0.7 cm in diameter was thought to be an inserted magnet (fig. 1). Under the diagnostic impression of foreign bodies in the bladder and urethra, removal of the foreign bodies was planned.

Under general anesthesia, the inserted magnets were removed by meatotomy (fig. 2A). After the meatotomy, a cystoscopic examination was performed. A dark colored slightly curved rod-shaped bladder stone about 10 cm long was observed at the left lateral aspect of bladder cavity. After fragmentation of the bladder stone with an electrohydraulic lithotripter, a foreign body was seen inside the stone. The foreign body was stuck in the bladder wall and could not be removed by cystoscopic forceps. To avoid the risk of bladder and urethral injury, a cystolithotomy was planned and a midline incision on the bladder was made.

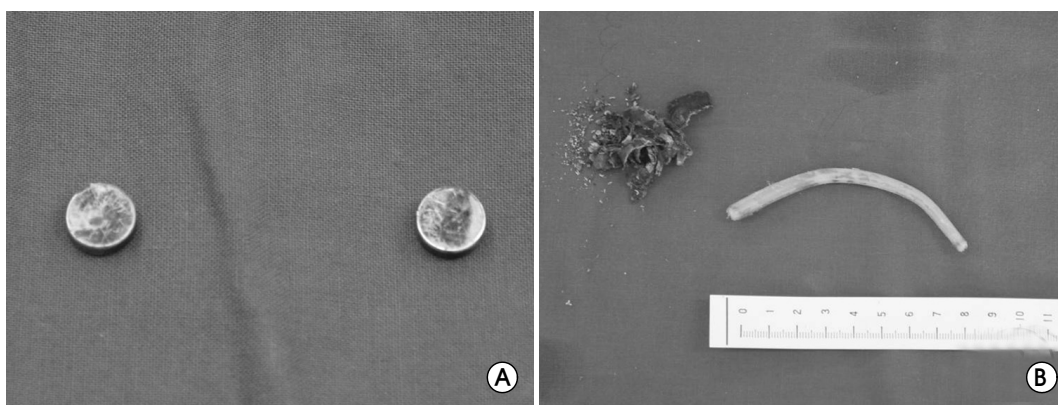
A rod-shaped material that was curved 20 degrees, 10 cm long, and 0.5 cm in diameter was seen and removed by forceps (fig. 2B). The post-operative period was unremarkable and the patient was discharged 10 days after the operation. The patient was recommended to undergo a psychiatric evaluation but he refused. The patient did not follow up with the outpatient department.

#### Case 2

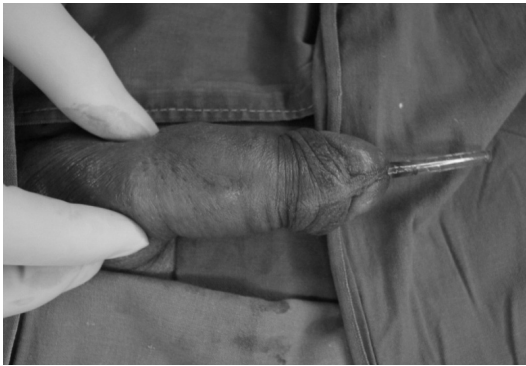A 51-year-old man complaining that he could



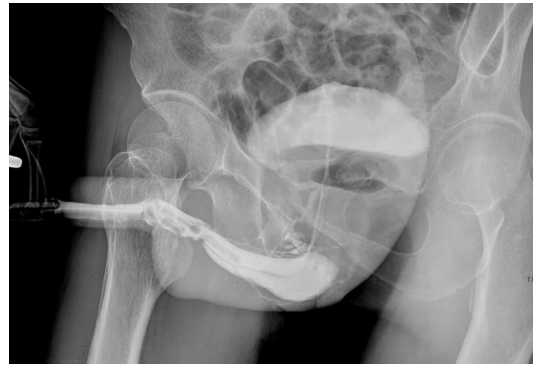**Figure 1.** Abnormal calcifications (white arrow) were observed in urethral meatus and pelvic cavity on plain KUB film.



**Figure 2.** (A) Two magnets were removed from urethral meatus with meatotomy. These two magnets are round shaped and 0.7 cm in diameter. (B) A rod-shaped material that was curved in 20 degrees, 10 cm long and 0.5 cm in diameter.



**Figure 3.** A green colored tube projecting from the external meatus.



**Figure 4.** Abnormal extravasation of contrast in bulbous urethra was seen on retrograde urethrography (RGU).

not pull out a green-colored tube inserted in the urethra 3 hours previously was referred to our clinic for retrieval of the foreign body. A 5cm of green-colored tube was seen projecting from the external urethral meatus (fig. 3).

In the physical examination, the mass was palpated on the ventral side of the penile shaft 5 cm proximal from the urethral meatus. Laboratory findings revealed microscopic hematuria but no pyuria in routine urinalysis. The results of a complete blood count and electrolyte profile were normal. The palpated mass was thought to be a knotted loop. In the retrograde urethrography performed to rule out urethral injury, abnormal dye leakage in the bulbous urethra was observed (fig. 4). Under the diagnostic impression of partial bulbous urethral injury and a urethral foreign body, a suprapubic cystostomy was done immediately. An external urethrotomy to remove the tied green tube was planned.

With the patient under general anesthesia, an external urethrotomy was performed. The green tube was exposed at the incision site. With gentle traction, the 15 cm long knotted green tube was removed from the bulbous urethra. The knotting was thought to have occurred spontaneously in the bladder when the patient pulled the tube in an attempt to remove it. The urethrotomy opening site was sutured with Vicryl 4-0 after removal of the tube. On the sixth postoperative day, debridement and reanastomosis of the external urethrotomy incision site was performed because necrotic changes had developed. On the 30<sup>th</sup> post-

operative day, no extravasation of dye in the urethra was observed in the follow-up retrograde urethrography. The patient was recommended to undergo a psychiatric evaluation but he refused. The patient did not follow up with the outpatient department.

## Discussion

Causes of foreign bodies in lower urinary track include psychological, iatrogenic during urological procedure, traumatic aspect and migration from other organs. In psychological aspect, various circumstances including exotic impulse, mental illness, borderline personality disorder, sexual curiosity, sexual practice while intoxication and so on make self-insertion of foreign bodies in lower urinary tract. Among these, the most common motive for foreign body insertion in the lower urinary tract is sexual or erotic in nature, such as masturbation or other forms of sexual variation or gratification [2,4]. Various materials such as paraffin, a urethral device, metallic cables, plastic tubes, fish, and snake have been reported as foreign bodies in the lower urinary tract [5].

The urethra is the main entrance if the foreign body is inserted into the urinary tract [2]. Urethral foreign bodies usually migrate into the bladder by being pushed further into the urethra to remove them or by involuntary perineal muscle contraction. The length of passage that a foreign body migrates from the urethral meatus to the bladder is approximately 20 to 25 cm in an

adult erected penis. Migration through the bulbous urethral curvature without significant injuries is surprising and still not sufficiently explained [5]. Urethral self-insertion of foreign bodies may be complicated when the inserted object migrates to the proximal urethra or bladder and cannot be retrieved [4].

Our first case was very interesting because the foreign body had remained in the bladder for a long time without causing severe irritating voiding symptoms. Furthermore, the patient himself inserted additional foreign bodies, hoping to remove the previously inserted foreign bodies.

A self-inserted foreign body in the urinary tract is not common. With careful history taking and physical examination, physicians can get information about the type of foreign body and duration of insertion. To determine the exact size, number, and location, radiologic evaluation is necessary [1]. In most cases, pelvic radiographic imaging is sufficient to locate and identify foreign bodies. As would be expected, computed tomography or ultrasonography is useful as the next step [4].

Minimally invasive procedures such as endoscopic management to minimize bladder and urethral injuries are usually successful. In some cases, however, open procedures such as perineal urethrotomy or suprapubic cystostomy without removing the foreign body or dissolution according to the nature of the foreign body are recommended [1,2,6,7].

In our first case, because the foreign body was impacted in the bladder wall, it could not be retrieved by a cystoscopic procedure. Therefore, a cystolithotomy was done to avoid the risk of bladder and urethral injury. In our second case, the foreign body protruding from the external meatus was impacted in the urethra. Thus, the patient could not remove the tube with simple traction, and an endoscopic instrument could not be inserted through the urethra. Therefore, an external urethrotomy was performed.

Foreign bodies in the lower urinary tract can be removed and cured with immediate diagnosis

and proper management. However, if foreign bodies remain persistently, complications such as infection, stones, or fistula formation can occur. There have been case reports of patients who died due to sepsis and uremia caused by foreign bodies in the lower urinary tract [8]. Delayed complications such as urethral stricture can occur, so close follow-up is recommended if possible.

Finally, psychiatric consultation should be done to prevent further attempts at insertion of other foreign bodies in the urinary tract [4]. In our cases, both patients were recommended to undergo psychiatric consultation, but they refused.

### Conflicts of Interest:

The authors have nothing to disclose.

### References

- 1) Johnin K, Kushima M, Koizumi S, Okada Y. Percutaneous transvesical retrieval of foreign bodies penetrating the urethra. *J Urol* 1999;161:915-6
- 2) Cho DS, Kim SJ, Choi JB. Foreign bodies in urethra and bladder by implements used during sex behavior. *Korean J Urol* 2003;44:1131-4
- 3) Van Ophoven A, deKernion JB. Clinical management of foreign bodies of the genitourinary tract. *J Urol* 2000;164:274-87
- 4) Rahman NU, Elliott SP, McAninch JW. Self-inflicted male urethral foreign body insertion: endoscopic management and complications. *BJU Int* 2004;94:1051-3
- 5) Ku JH, Lee CS, Jeon YS, Kim ME, Lee NK. A Foreign body in the urethra: a case report. *Korean J Urol* 1997;38:219-21
- 6) Seong BJ, Kim SJ, Kim HS, Kim DY, Chung JM, Choi S. Acute urinary retention due to urethral foreign bodies. *J Korean Continence Soc* 2006;10:60-2
- 7) Jung TY, Choi NG. 14 cases of foreign bodies in the bladder. *Korean J Urol* 1997;38:76-80
- 8) Sunwoo HS, Kwon CH, Kim YS, Chung KS, Kim JC. Five cases of foreign bodies in the bladder. *Korean J Urol* 1980;21:82-5