

Robotics/Laparoscopy

Initial Experience with Laparoendoscopic Single-Site Surgery by Use of a Homemade Transumbilical Port in Urology

Seok Young Lee, Yong Tae Kim, Hae Young Park, Tchon Yong Lee, Sung Yul Park

Department of Urology, Hanyang University College of Medicine, Seoul, Korea

Purpose: We present our initial experience with laparoendoscopic single-site surgery (LESS) by a single surgeon in the urologic field.

Materials and Methods: From May 2009 to April 2010, 30 consecutive patients underwent LESS including seven cases of nephrectomy, five cases of nephroureterectomy with bladder cuff excision, four cases of ureterolithotomy, eight cases of marsupialization, and six cases of varicocelectomy. We performed a retrospective analysis of the medical records of the above patients. The single port was made with a surgical glove and an Alexis[®] wound retractor (Applied Medical, Rancho Santa Margarita, CA, USA). The wound retractor was put into the peritoneal space through an umbilical incision, and a laparoscopic triangle was secured by crossing both instruments. All operations were performed by the transperitoneal approach.

Results: Mean patient age was 54.8 years. Mean operative time was 171.2±109.1 minutes. Mean estimated blood loss was 265.0±395.5 ml. Mean incision length was 3.2±1.4 cm. Mean length of hospitalization was 5.2±2.9 days. There was one laparoscopic conversion and two open conversions. There were two cases of transient ileus that improved with conservative treatment. Mean visual analogue pain scales on the operative day and first postoperative day were 6.3/10 and 3.1/10, respectively.

Conclusions: In our experience, LESS for urologic surgery is feasible, safe, and clinically applicable. We consider the homemade single-port device to be a relatively cost-effective and convenient device. If surgical instruments for LESS and appropriate ports specified for LESS are developed, LESS would be a surgical treatment technique that could be used as an alternative to the conventional types of laparoscopic surgery.

Key Words: Instrumentation; Laparoscopy; Surgical gloves; Urology

This is an Open Access article distributed under the terms of the Creative Commons Attribution Non-Commercial License (<http://creativecommons.org/licenses/by-nc/3.0>) which permits unrestricted non-commercial use, distribution, and reproduction in any medium, provided the original work is properly cited.

Article History:

received 1 June, 2010

accepted 9 August, 2010

See Editorial on page 618.

Corresponding Author:

Sung Yul Park
Department of Urology, Hanyang
University College of Medicine,
17, Haengdang-dong,
Seongdong-gu, Seoul 133-792,
Korea
TEL: +82-2-2290-8596
FAX: +82-2-2299-2186
E-mail: syparkuro@hanyang.ac.kr

INTRODUCTION

Laparoscopic surgery provides a higher degree of patient satisfaction than does open surgery from a cosmetic perspective, and it is also effective in reducing postoperative pain, operative wound complications, blood loss, and the length of hospital stay. Accordingly, it has been remarkably developed in the field of urology over the past 20 years. It has also been performed prevalently as a treatment regimen, which is comparable to open surgery. Then, it was established as a mainstream modality. Usually, the laparoscopic technique requires three to six ports. With technical

advancements and the increased demand for minimally invasive surgery, however, laparoendoscopic single-site surgery (LESS) performed via a single incision window has recently been introduced. There is still only one type of LESS port that has become commercially available in Korea up to the present. Various studies have been conducted with the R-port[™] (Advanced Surgical Concepts, Dublin, Ireland), which has been frequently used worldwide, but this port cannot be used in a Korean clinical setting. Many surgeons in Korea therefore perform LESS by using a homemade single-port device. In this study, we report our initial experiences with LESS performed by a single surgeon using a

homemade single-port device in the field of urology.

MATERIALS AND METHODS

Between April 2009 and April 2010, a total of 30 patients underwent LESS performed by a single surgeon. Of these, there were seven cases of nephrectomy (5 radical nephrectomies), five cases of nephroureterectomy with bladder cuff excision, four cases of ureterolithotomy, eight cases of marsupialization, and six cases of varicocele. We performed a retrospective analysis of the medical records of the above patients. All surgeries were performed via a transperitoneal approach. As the surgical method, a single incision was made at the umbilicus and the peritoneum was con-

firmed accordingly. Then, after an incision was made, an Alexis® wound retractor (Applied Medical, Rancho Santa Margarita, CA, USA) was placed. The exterior side was connected to a surgical glove and then fixed by using a silk (Fig. 1A). This was followed by the placement of a homemade single-port device (Fig. 1B). The homemade single-port device was prepared by fixing 3 to 4 general type laparoscopic ports in each finger. A 10 mm rigid laparoscope or flexible laparoscope (EndoEye®, Olympus Surgical, Orangeburg, SC, USA) was inserted into the peritoneum through the 12 mm trocar and the flexible laparoscopic instruments (LaparoAngle®, CambrigeEndo, Framingham, MA, USA; and Roticulator®, Autosuture, Norwalk, CT, USA) were inserted through the remaining trocars (Fig. 1C). In cases in

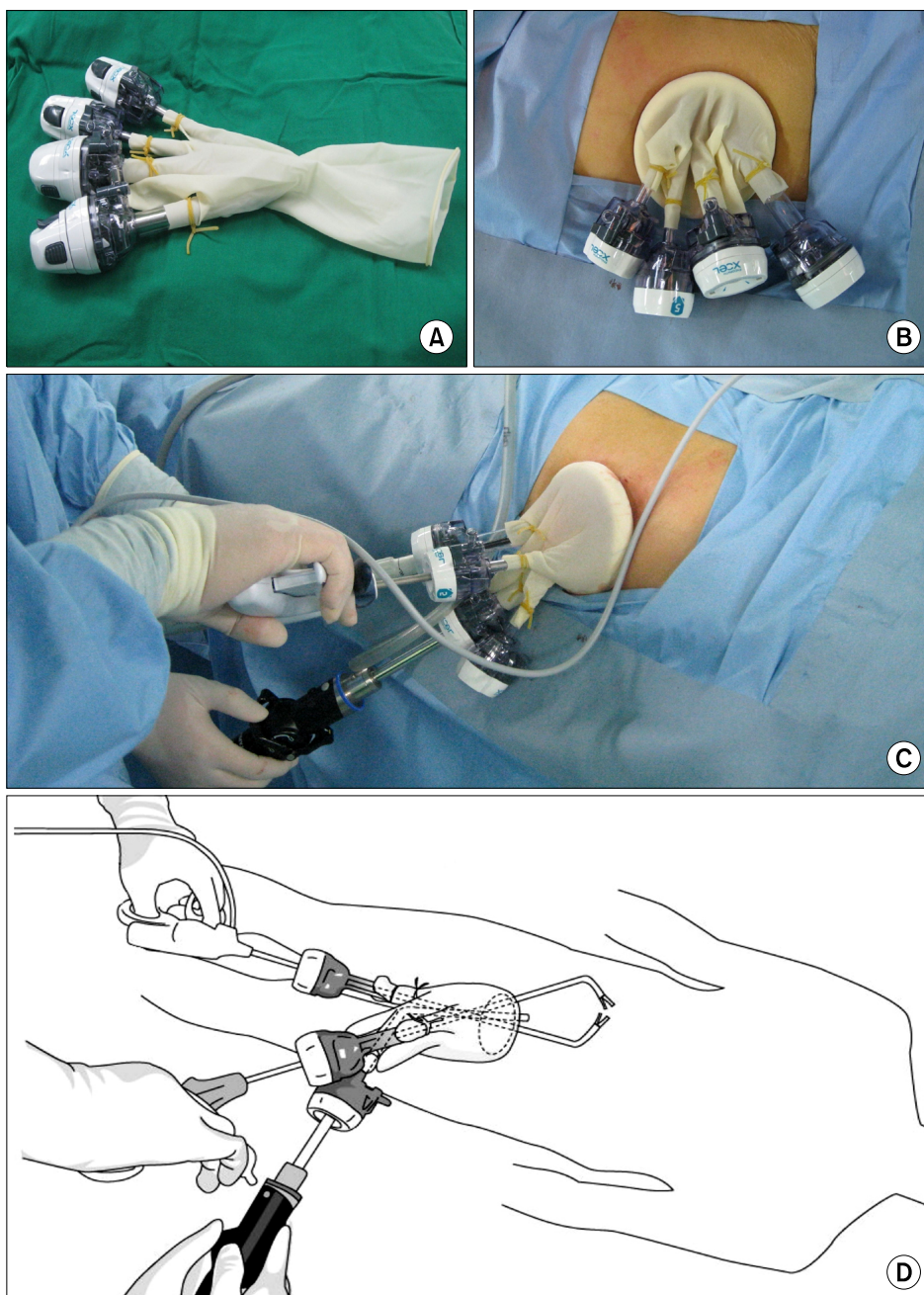


FIG. 1. Homemade single-port device (A). Inlet of surgical glove put on the outer ring as the plastic sleeve is turned inside out (B). Instruments and laparoscope positioning during laparoendoscopic single-site surgery (LESS) (C). Schematic illustration showing intraperitoneal positioning of instruments and laparoscope through the port device. Homemade single-port device was made by tying fingers of size 6 1/2 surgical glove to the ends of 4 trocars with rubber bands (D).

TABLE 1. Perioperative surgical results of 30 patients who underwent laparoendoscopic single-site surgery in the urological field

Sex	Age (years)	Final diagnosis	Operation name	Op. time (min)	EBL (ml)	Incision length (cm)	Hospital day	Pain scale (op. day)	Pain scale (POD#1)	Complications
1	F	60	Xanthogranulomatosis pyelonephritis, Rt.	Simple nephrectomy, Rt.	405	2,050	4	7	5	Laparoscopic conversion
2	M	65	Renal cyst, Lt.	Marsupialization, Lt.	115	400	2.5	3	2	
3	M	30	Varicocele, Lt.	Varicolectomy, Lt.	105	0	2.5	3	4	
4	M	69	Renal cyst, Lt.	Marsupialization, Lt.	170	300	2.5	3	2	
5	M	63	Renal cyst, Lt.	Marsupialization, Lt.	90	100	2.5	3	1	
6	M	66	Renal pelvis stone, Rt. with horseshoe kidney	Ureterolithotomy, Rt.	205	300	2.5	5	2	
7	M	52	Ureteropelvic junction stone, Rt.	Ureterolithotomy, Rt.	170	50	2.5	4	3	
8	M	71	Renal cell carcinoma, Rt.	Radical nephrectomy, Rt.	265	500	4	5	3	
9	M	54	Renal cyst, Lt.	Marsupialization, Lt.	60	50	2	4	2	
10	F	81	Ureteropelvic junction stone, Lt.	Ureterolithotomy, Lt.	130	100	2	6	2	
11	F	56	Renal pelvis tumor, Lt.	Nephroureterectomy with bladder cuff excision, Lt.	385	100	4	3	2	
12	F	80	Distal ureter stricture, Rt.	Nephroureterectomy with bladder cuff excision, Rt.	350	300	4	14	9	Ileus
13	F	71	Renal cyst, Rt.	Marsupialization, Rt.	95	0	2	6	2	
14	M	51	Renal cell carcinoma, Rt.	Radical nephrectomy, Rt.	145	500	4	8	2	
15	F	66	Renal cyst, Rt.	Marsupialization, Rt.	75	50	2	4	3	
16	M	46	Renal cell carcinoma, Lt.	Radical nephrectomy, Lt.	235	200	5	8	3	
17	M	58	Ureter tumor, Rt.	Nephroureterectomy with bladder cuff excision, Rt.	330	300	6	4	3	Open conversion
18	M	51	Ureter stone, Rt.	Ureterolithotomy, Rt.	195	500	3	5	3	
19	M	16	Varicocele, Lt.	Varicolectomy, Lt.	110	0	2	3	2	
20	M	54	Ureter tumor, Lt.	Nephroureterectomy with bladder cuff excision, Lt.	415	800	8	8	4	Open conversion
21	M	60	Renal cyst, Rt.	Marsupialization, Rt.	115	50	2	3	2	
22	M	57	Renal cell carcinoma, Rt.	Radical nephrectomy, Rt.	155	100	4	8	6	
23	F	83	Renal cell carcinoma, Lt.	Radical nephrectomy, Lt.	85	300	4	6	1	
24	M	23	Varicocele, Lt.	Varicolectomy, Lt.	45	0	2	3	5	
25	M	29	Varicocele, Lt.	Varicolectomy, Lt.	75	0	2	3	5	
26	F	69	Nonfunction kidney, Rt.	Simple nephrectomy, Rt.	150	300	3	5	4	
27	M	34	Varicocele, Lt.	Varicolectomy, Lt.	40	0	2	3	5	
28	F	41	Renal cyst, Bilat.	Marsupialization, Bilat.	155	500	3	4	3	
29	M	18	Varicocele, Bilat.	Varicolectomy, Bilat.	65	0	2	3	5	
30	F	72	Renal pelvis tumor, Lt.	Nephroureterectomy with bladder cuff excision, Lt.	200	100	4	13	2	Ileus

Op.: operation, EBL: estimated blood loss, POD#: the first postoperative day, F: female, M: male, Rt.: right, Lt.: left, Bilat.: bilateral

which a nephrectomy or nephroureterectomy was performed, a 4.0 cm incision was made. Resected specimens of renal cell carcinoma (RCC) or renal pelvis tumor were entrapped by use of a Lap-bag[®] (Sejong Medical, Paju, Korea) and extracted along the longitudinal axis, and there were no morcellated specimens in our cases. In cases with right-sided disease, the liver was retracted by use of a Diamond Flex[®] angled circular retractor (Snowden Pencer, Cardinal Health, Dublin, OH, USA) through a 5 mm port. In other cases, a 2.0 to 2.5 cm incision was made. For the methods in which the instruments were crossed in both hands, a laparoscopic triangle was secured. The surgical procedure was performed by using laparoscopic instruments that can be flexed (Fig. 1D) and those that are generally used. The surgical methods followed a conventional laparoscopic procedure and order. After the surgical procedure was completed, the homemade single-port device and Alexis[®] wound retractor were removed. Then, using 2-0 Vicryl, the peritoneum and fascia were sutured. The subcutaneous fascia was sutured with 4-0 Vicryl. The surgical procedure was completed after the application of Dermabond[®] (Ethicon, Somerville, NJ, USA).

RESULTS

Perioperative surgical outcomes are presented in Table 1. Mean patient age was 54.8 years. Mean operative time was 171.2±109.1 minutes. Mean estimated blood loss was 265.0±395.5 ml. Mean incision length was 3.2±1.4 cm. Mean length of hospitalization was 5.2±2.9 days. There were two cases of transient ileus that improved with conservative treatment. Mean visual analogue pain scales on the operative day and the first postoperative day were 6.3/10 and 3.1/10, respectively. There was one laparoscopic conversion and two open conversions. Cases that were converted to conventional surgery were found to correspond to patients who concurrently had xanthogranulomatosis and a ureteropelvic junction stone in the right kidney. In these patients, a simple nephrectomy was attempted. Because of the severe adhesion to the adjacent tissues and the persistent

presence of bleeding, however, no further surgical procedures were available. Accordingly, surgical procedures progressed after the additional insertion of two ports. The operative time was 405 minutes, and the estimated blood loss was 2,050 ml. This patient required a blood transfusion. Two cases that were converted to open surgery were cases of nephroureterectomy for a ureteral tumor. One incision extension was performed because of complete renal hilar lymphadenectomy by the open technique, and one open conversion with Gibson's incision was performed because of severe adhesion around the distal ureter. Lymphadenectomy around the renal pedicles and external iliac vessels, which was similar to conventional laparoscopic surgery, was performed in most cases. However, we did not perform lymphadenectomy in our first nephroureterectomy case. Bladder cuff excision was performed by the extravesical approach and the bladder repair was performed by suture with a conventional laparoscopic needle holder using 3-0 Vicryl with LaparoTy clips (Ethicon Endosurgery, Cincinnati, OH, USA) in 4 cases. Cumulative perioperative outcomes for each operation are presented in Table 2. In all surgical cases, there were no accidents or complications in association with the use of a homemade single-port device during the surgery. For cases in which surgery was performed for more than 2 hours, however, the surgical glove was stretched in three cases. In one case of ureterolithotomy, the glove was pierced by a needle.

DISCUSSION

LESS via an umbilicus was first performed by Piskun in 1999 for a cholecystectomy [1]. Since then, it has been frequently performed in the field of urology as well as in the field of surgery. Kaouk et al reported that LESS was successfully performed in a total of 10 cases [2]. LESS was also reported to be successfully performed in the first 100 cases of a single center [3].

The conventional type of laparoscopic surgery requires 3 to 6 ports, and as a result many patients complain of transient pain at the incision site. Besides, in cases of pelvic sur-

TABLE 2. Cumulative perioperative surgical outcomes of laparoendoscopic single-site surgery in the urological field

Op. name	Op. time (min)	EBL (ml)	Incision length (cm)	Hospital day	Pain scale (Op. day)	Pain scale (POD#1)	Comments
Simple nephrectomy (n=2)	277.5	1,175.0	3.5	6.0	8.0	4.5	1 laparoscopic conversion 1 transfusion
Radical nephrectomy (n=5)	177.0	320.0	4.2	7.0	5.8	3.0	Mean size of renal masses: 4.1 cm (range, 3.5-5 cm)
Nephroureterectomy (n=5)	336.0	320.0	5.2	8.4	6.2	3.6	2 open conversion 2 ileus
Marsupialization (n=8)	109.4	181.3	2.3	3.6	5.5	2.1	
Varicocelelectomy (n=6)	73.3	0.0	2.1	3.0	7.3	4.3	
Ureterolithotomy (n=4)	175.0	237.5	2.5	5.0	6.5	2.5	

Op.: operation, EBL: estimated blood loss, POD#1: the first postoperative day

gery, damage to the inferior epigastric artery sometimes occurs after the insertion of a lateral port. In the case of LESS via an umbilicus, however, a single port only is used while maintaining the advantages of the conventional type of laparoscopic surgery. LESS is therefore advantageous in minimizing the incision site and reducing the pain [2]. In addition, it is also excellent from a cosmetic perspective compared with the open technique. LESS leaves almost no operative scars. Besides, because an incision is made via the umbilicus, damage to the organs on the peritoneal wall can be minimized. Furthermore, it may also be effective for bilateral cases. In the cases reported here, patients who had a bilateral lesion were also able to undergo bilateral LESS by using a single incision via a single umbilicus. This implies that a single incision can be maximally used as compared with cases in which a laparoscopic port must be inserted, including those with a bilateral ureteral stone or bilateral renal tumor, which are often encountered in the field of urology.

Despite these advantages, however, the laparoscopic instruments are crossed in an X-shape as compared with the conventional types of laparoscopic surgery. Accordingly, because it is difficult to manipulate the laparoscopic instruments, the surgical time is prolonged and refined surgery is difficult; there are therefore some patients who are unwilling to undergo single-incision laparoscopic surgery. In our 30 patients, the first one underwent a conversion to conventional laparoscopy. This patient was found to have xanthogranulomatosis pyelonephritis and was suspected of having an adhesion to the adjacent tissue. Actually, in the operation field, the adhesion was more severe than what was expected. Within 3 hours, the surgery was converted to a conventional laparoscopy.

The learning curve for LESS can be overcome within a relatively short time. In all surgical cases, it was found to be decreased without a great difference from the surgical time of conventional laparoscopic procedures. In cases in which the surgical procedure was difficult due to adhesion or to difficulty in manipulating the laparoscopic instruments after a single incision was attempted, the scope of the surgical procedure could be widened because a conversion to conventional laparoscopy could be made at any time.

The laparoscopic ports that were used herein have been used overseas as well as in Korea [4]. Currently in Korea, various reports have been made about LESS. Only one type of LESS port is approved for human use in Korea, and this is commercially available only in Korea. In association with this, Park et al first reported nephrectomy in pediatric patients [5]. Han et al reported their initial experiences with nephrectomy by using a homemade single-port device [6]. Jeong et al compared the surgical outcomes of conventional laparoscopic adrenalectomy with those of LESS adrenalectomy [7]. Park et al first reported their initial experiences with nephroureterectomy for a renal pelvis tumor [8]. All of these reports included surgery using a homemade single-port device. There were no cases of delayed surgery or

postoperative complications. In overseas countries, the R-port™ (Advanced Surgical Concepts, Dublin, Ireland) is the representative LESS port. In addition, other various types of single ports have also been used. The homemade single-port device that was used herein has advantages compared with the conventional types of R-port™ in that it is less expensive (R-port™ vs. LESS port, 550,000 KRW vs 350,000 KRW), the instruments can be manipulated more freely, and a maximal number of five ports can be used. Based on these advantages, various types of laparoscopic ports can be designed according to the surgery or individual preferences. However, there are also disadvantages as follows. The glove can become bulged following a long-term surgery and this may interfere with the surgical procedure. The glove can also be pierced while a needle is inserted and then pulled out. This creates a risk of delaying the surgical procedure or introducing foreign substances. Compared with the commercially available LESS port, there are additional processes where a port is made and then placed. We did not perform LESS in patients with a history of previous abdominal surgery. LESS for thin patients might be easier than for obese patients.

CONCLUSIONS

LESS is a relatively safe, effective treatment technique in benign disease. For malignant disease, however, prospective study of LESS with large samples is needed. LESS was very difficult to perform in advanced disease in our cases as compared with conventional laparoscopic surgery. Various types of single-port devices have now become commercially available, but we consider the homemade single-port device to be a relatively cost-effective and convenient device. If various types of surgical instruments for LESS and appropriate ports specified for LESS are developed, LESS should be an alternative to the conventional types of laparoscopic surgery.

Conflicts of Interest

The authors have nothing to disclose.

REFERENCES

1. Piskun G, Rajpal S. Transumbilical laparoscopic cholecystectomy utilizes no incisions outside the umbilicus. *J Laparoendosc Adv Surg Tech A* 1999;9:361-4.
2. Kaouk JH, Haber GP, Goel RK, Desai MM, Aron M, Rackley RR, et al. Single-port laparoscopic surgery in urology: initial experience. *Urology* 2008;71:3-6.
3. White WM, Haber GP, Goel RK, Crouzet S, Stein RJ, Kaouk JH. Single-port urological surgery: single-center experience with the first 100 cases. *Urology* 2009;74:801-4.
4. Tai HC, Lin CD, Wu CC, Tsai YC, Yang SS. Homemade transumbilical port: an alternative access for laparoendoscopic single-site surgery (LESS). *Surg Endosc* 2010;24:705-8.
5. Park YH, Kang MY, Jeong MS, Choi H, Kim HH. Laparoendoscopic single-site nephrectomy using a homemade single-port device for single-system ectopic ureter in a child: initial case report. *J Endourol*

2009;23:833-5.

6. Han WK, Park YH, Jeon HG, Jeong W, Rha KH, Choi H, et al. The feasibility of laparoendoscopic single-site nephrectomy: initial experience using home-made single-port device. *Urology* 2009;Epub ahead of print
7. Jeong BC, Park YH, Han DH, Kim HH. Laparoendoscopic single-site and conventional laparoscopic adrenalectomy: a matched case-control study. *J Endourol* 2009;23:1957-60.
8. Park YH, Park SY, Kim HH. Laparoendoscopic single-site nephroureterectomy with bladder cuff excision for upper urinary tract transitional-cell carcinoma: technical details based on oncologic principles. *J Endourol* 2010;24:563-6.

EDITORIAL COMMENT

This study was a retrospective review of a 12-month, single surgeon experience with laparoendoscopic single-site surgery (LESS). The authors should be congratulated on performing 30 cases, which is a large number within such a short period of time. A few words of caution should be exercised, however.

First, this procedure requires unique surgical expertise; among 30 cases, 10 percent (3 cases) were converted. This

suggests that those who first attempt the LESS procedure should always bear in mind that this is a technique in revolution that can also be performed by conventional open or laparoscopic methods. Secondly, this procedure is not in its final form. The authors used a flexible laparoscope and flexible laparoscopic instruments. There are other methods such as the use of robotic technologies [1]. There should be easier ways to do these procedures in the near future.

Urology has always been an exciting, cutting-edge field of surgery in which new techniques and new devices are used. LESS procedures may be the harbinger of a surgical revolution, on the way to single incision or maybe no incisions in the future!

Koon Ho Rha

Associate Professor, Urology

Director, Severance daVinci Training Center

Yonsei University, Seoul, Korea

1. White MA, Haber GP, Autorino R, Khanna R, Forest S, Yang B, et al. Robotic laparoendoscopic single-site radical prostatectomy: technique and early outcomes. *Eur Urol* 2010;Epub ahead of print