

## Clinical Article

# Localization of Broca's Area Using Functional MR Imaging: Quantitative Evaluation of Paradigms

Chi Heon Kim, M.D., Ph.D.,<sup>1,3,4</sup> Jae-Hun Kim, B.S.,<sup>2</sup> Chun Kee Chung, M.D., Ph.D.,<sup>1,3,4</sup> June Sic Kim, Ph.D.,<sup>1,3,4</sup> Jong-Min Lee, Ph.D.,<sup>2</sup> Sang Kun Lee, M.D., Ph.D.<sup>6</sup>

*Departments of Neurosurgery,<sup>1</sup> Radiology,<sup>5</sup> Neurology,<sup>6</sup> Clinical Research Institute,<sup>4</sup> Seoul National University Hospital, Seoul, Korea*

*Department of Biomedical Engineering,<sup>2</sup> Hanyang University, Seoul, Korea*

*Neuroscience Research Institute,<sup>3</sup> Seoul National University Medical Research Center, Seoul, Korea*

**Objective** : Functional magnetic resonance imaging (fMRI) is frequently used to localize language areas in a non-invasive manner. Various paradigms for presurgical localization of language areas have been developed, but a systematic quantitative evaluation of the efficiency of those paradigms has not been performed. In the present study, the authors analyzed different language paradigms to see which paradigm is most efficient in localizing frontal language areas.

**Methods** : Five men and five women with no neurological deficits participated (mean age, 24 years) in this study. All volunteers were right-handed. Each subject performed 4 tasks, including fixation (Fix), sentence reading (SR), pseudoword reading (PR), and word generation (WG). Fixation and pseudoword reading were used as contrasts. The functional area was defined as the area(s) with a t-value of more than 3.92 in fMRI with different tasks. To apply an anatomical constraint, we used a brain atlas mapping system, which is available in AFNI, to define the anatomical frontal language area. The numbers of voxels in overlapped area between anatomical and functional area were individually counted in the frontal expressive language area.

**Results** : Of the various combinations, the word generation task was most effective in delineating the frontal expressive language area when fixation was used as a contrast ( $p < 0.05$ ). The sensitivity of this test for localizing Broca's area was 81% and specificity was 70%.

**Conclusion** : Word generation versus fixation could effectively and reliably delineate the frontal language area. A customized effective paradigm should be analyzed in order to evaluate various language functions.

**KEY WORDS** : Functional MRI · Language · Paradigm · Quantitative evaluation.

## INTRODUCTION

Functional magnetic resonance imaging (fMRI) has been frequently used to localize language areas in the brain in a non-invasive manner<sup>1-8,12,13,15,16,18,19,24-26</sup>. Various paradigms for the presurgical localization of language areas have been developed to replace invasive brain mapping. However, a systematic quantitative evaluation of the efficiency of those paradigms has not been performed<sup>1-8,12,13,15,16,18,19,24-26</sup>. The aim of this study was to evaluate the efficacy of different paradigms for localizing the expressive language area.

## MATERIALS AND METHODS

### Subjects

Ten healthy volunteers with no neurological diseases were recruited. Five men and five women were included, and their mean age was 24 years (22-26). All volunteers were from the professional or academic sector and enjoyed leading a normal social life. All of the volunteers had a good understanding of the procedure of fMRI and successfully performed a variety of tasks. All volunteers were strongly right-handed, as determined by the Edinburgh Handedness Inventory. This study was approved by the Institutional Review Board of Seoul National University Hospital (Number; H-0712-007-227).

### Image acquisition

fMRI was performed using a GE Signa 1.5 Tesla clinical

• Received : January 20, 2009 • Accepted : April 5, 2009

• Address for reprints : Chun Kee Chung, M.D., Ph.D.  
Department of Neurosurgery, Seoul National University College of  
Medicine, 101 Daehak-ro, Jongno-gu, Seoul 110-744, Korea  
Tel : +82-2-2072-2352, 2358, Fax : +82-2-744-8459  
E-mail : chungc@snu.ac.kr

scanner equipped with a standard head coil (General Electric Medical System, Milwaukee, WI). A neck-collar (MJ-200, USA) was used to reduce movement, and ear plugs were used to dampen scanner noise. Twenty axial slices with a matrix size of  $64 \times 64$  and a field of view of  $240 \times 240$  mm were collected. For each run, we acquired 96 T2-weighted, gradient-echo (GRE) planar imaging (EPI) scans with the following parameters: slice thickness, 6 mm; interslice gap, 0 mm; TR, 3,000 ms; TE, 50 ms. In addition, a high-resolution structural T1-weighted image was acquired using a flow-sensitive conventional gradient echo sequence with 120 slices (slice thickness, 1.4 mm; interslice gap, 0 mm; TR, 50 ms; TE, 4 ms; flip angle,  $60^\circ$ ).

### Experimental design

All experiments used an alternating block format with a duration of 24 seconds, and the duration of each trial was 3 seconds (8 trials per block) to ensure equivalent sampling across language activation conditions. Each run had four tasks, including fixation (eye fixation at dot on screen; Fix), simple sentence reading (read an easily interpretable sentence; SR), pseudoword reading (read meaningless word; PR), and word generation (generate a semantically related word to complete a simple blanked sentence; WG) task. All subjects performed four runs, and a different type of stimulus was used for each run. A total of 96 time points were acquired for each task. All stimuli were presented visually in Korean on a projected screen. A covert response was used rather than an overt response in order to reduce artifacts from jaw movement. Before the actual experiment, the subjects were trained on each task outside the scanner to ensure that they understood the instructions and to test whether they were able to perform each task completely. All stimuli in the simple sentence reading and word generation tasks were controlled at the level of a 6-year-old child.

### General functional MRI analyses

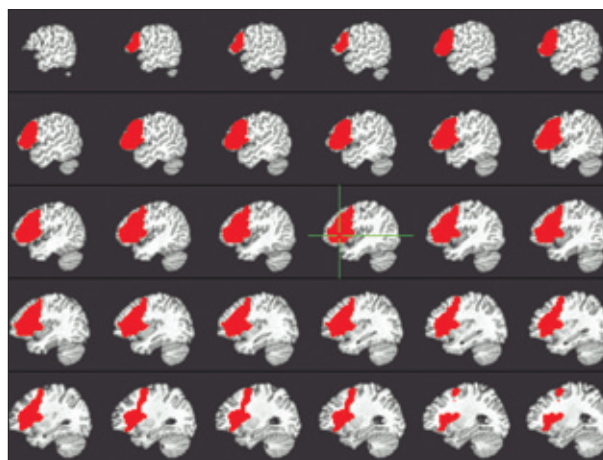
Functional data were analyzed within the framework of the general linear model in the Analysis of Functional Neuroimages program (AFNI, <http://afni.nimh.nih.gov/afni>), and the following preprocessing steps were performed<sup>9)</sup>. 1) The first four volumes in each scan series, collected before equilibrium magnetization was reached, were discarded. 2) Of the remaining volumes, all were spatially realigned to the first to correct for head movement after accounting for different signal-acquisition times. 3) The structural image was coregistered to the fMRI image using a 7-parameter linear transformation, and the inverse matrix applied to the fMRI data to minimize distortion effects. 4) The data were then spatially normalized onto the Talairach space.

Structural data was normalized onto the Talairach space and then functional data were warped by the parameters acquired from structural data normalization. 5) All normalized images were spatially smoothed using a Gaussian kernel of 8-mm full-width half-maximum (FWHM), and resampled to  $3 \times 3 \times 3$  mm<sup>3</sup> isotropic voxels. 6) The signal magnitude for each scan series was adjusted to normalize the global signal for between-subject comparison.

After preprocessing, the fMRI experiment was modeled in a box-car design with the regressor entered into the design matrix with a canonical hemodynamic response function to represent the brain physiology. Other covariates of no interest included the realignment parameters used to account for motion artifacts. Four runs were concatenated into one big run, and this was considered to be an individual activation map. Magnitude estimates for effects of interest were computed for each subject based on an implementation of the general linear model (3dDeconvolve in AFNI). A random-effect model was used to create group activation maps. The regression model provided a single magnitude estimate of the response to each stimulus type in each voxel for each subject.

### Region of interest analysis

The individual activation maps were analyzed. In the present study, the fixation and pseudoword reading was used for contrast. Group activation maps of the ten subjects were also created for each combination (PR-Fix, SR-Fix, WG-Fix, SR-PR and WG-PR). The functional area was defined as an area with a t-value of more than 3.92 in fMRI. The functional areas were calculated in each subject and group activation map. To apply an anatomical constraint, we used a brain atlas mapping system<sup>10)</sup>, which is available



**Fig. 1.** Anatomical region of interest of expressive language areas. This includes most of the middle and inferior frontal gyrus (<http://afni.nimh.nih.gov/afni>).

in AFNI, to define the anatomical frontal language area (anatomical ROI) (Fig. 1)<sup>11,13,17</sup>. Voxel counts of functional areas within an anatomical ROI were calculated individually using the AFNI program<sup>9</sup>. The same anatomical ROI in AFNI was compared with individual patients.

The probabilistic mapping of group data was overlapped onto the T1 template in the AFNI program and aligned with the Talairach atlas<sup>9</sup>. The sensitivity and specificity of each combination was calculated also.

Sensitivity : A/C  
Specificity : B/D

A : activated voxel count in anatomical ROI

B : non activated voxel count in left hemisphere except anatomical ROI area

C : total voxel count in anatomical ROI

D : total voxel count in left hemisphere except anatomical ROI area

### Statistical analysis

All analyses were performed using the independent sample t-test and one way ANOVA to determine whether there was a significant difference between combinations of different tasks. A *p*-value of less than 0.05 was considered statistically significant. All analyses were performed using commercially available software (SPSS version 12.0, SPSS Inc, Chicago, IL).

### RESULTS

Total voxel count in anatomical ROI was 504 and voxel count in left hemisphere was 25949. Individual voxel counts for each combination of tasks in each functional area within each anatomical constraint are presented in Table 1. Statistical analysis revealed a significant difference between combinations ( $p < 0.001$ , one way ANOVA). Four combinations (PR-Fix, SR-Fix, WG-Fix and WG-PR), which showed more than 100 voxels in anatomical constraints, were compared with each other. The expressive language area was most well-delineated by the word generation task when fixation was used as a contrast ( $p < 0.05$ , independent sample t-test) (Table 2, Fig. 2). The probabilistic image of the group activation map with the WG-Fix combination was overlapped on the T1 template in the AFNI

**Table 1.** Voxel number in overlapped area between functional and anatomical region of interest

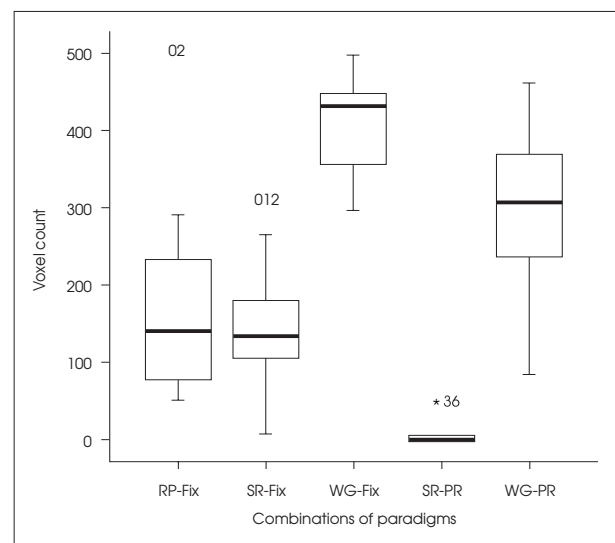
Case no.	PR-Fix	SR-Fix	WG-Fix	SR-PR	WG-PR
1	78	105	449	0	369
2	499	309	498	0	85
3	51	7	376	0	359
4	291	143	432	0	325
5	111	110	351	0	237
6	61	123	443	48	462
7	131	265	448	5	406
8	233	89	431	0	289
9	194	167	356	0	260
10	149	180	297	5	100
Mean±SD	179±135	149±87	408±61	6±15	289±123
Sensitivity (%)	35.7	29.7	81.0	1.2	57.4
Specificity (%)	78.8	84.3	70.3	99.2	88.5

Each score represents the voxel number in the overlapped area between anatomical and functional ROI. Fix : fixation, PR : pseudoword reading, ROI : region of interest, SR : sentence reading, WG : word generation, SD : standard deviation

**Table 2.** Statistical analysis between multiple combinations of tasks

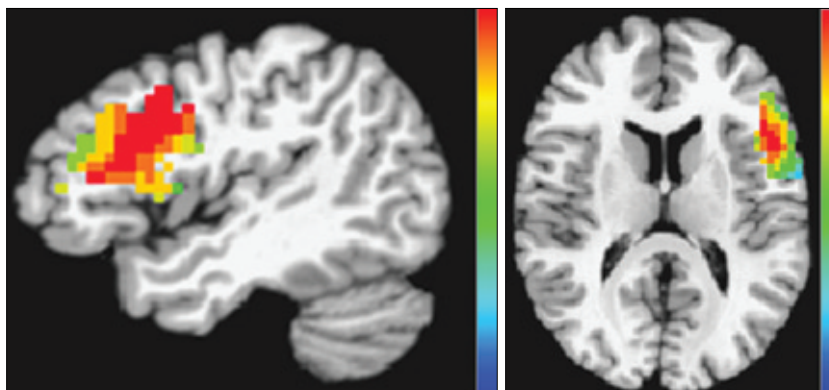
Combinations	<i>p</i> -value*
WG-Fix vs. PR-Fix	< 0.000
WG-Fix vs. SR-Fix	< 0.000
WG-Fix vs. WG-PR	0.014
SR-Fix vs. WG-PR	0.009
PR-Fix vs. SR-Fix	0.564
PR-Fix vs. WG-PR	0.076

Abbreviations are the same as in Table 1. \*Independent sample t-test. Fix : fixation, PR : pseudoword reading, ROI : region of interest, SR : sentence reading, WG : word generation, SD : standard deviation.



**Fig. 2.** Voxel count in overlapped area between functional and anatomical region of interest. Box graph shows mean and standard deviation values.

program. This mapping corresponded well to Brodmann's areas 44, 45 and 47 with reference to the anatomical information in the Talairach atlas equipped in the AFNI program (Fig. 3).



**Fig. 3.** Probabilistic map of WG-Fix in frontal language area. Probabilistic mapping was overlapped on a T1 template in the Analysis of Functional Neuroimages program. The red area (upper of scale bar) represents strong activation area. Frontal activation area (red area) was well correlated with Brodmann's areas 44, 45, 47.

The sensitivity of WG-Fix combination for localizing expressive language area was 81% and specificity was 70% (Table 1).

## DISCUSSION

### Overview

Brain mapping with direct cortical stimulation is still a gold standard method for language mapping<sup>4,7,14</sup>. However this is not always possible due to invasive nature and many different methods have been developed. Various modalities, such as the Wada test, fMRI, functional PET, and magnetoencephalography, can be used for non-invasive localization or lateralization of language area(s) for presurgical purposes. The Wada test and fMRI are the most popular of these modalities<sup>5,6,12,24</sup>. Although the Wada test can serve as a useful index of language laterality, it is less useful for localizing language areas. Although this modality has been a gold standard for lateralizing language hemispheres, the major drawback of the Wada test is that it is invasive with inherent risks<sup>1</sup>. Many studies have shown that fMRI is at least comparable to the Wada test in terms of lateralizing language function<sup>5,6,12,25</sup>. Thus, fMRI appears to be a promising modality for the evaluation of language function, especially in terms of preoperative planning in order to preserve essential language areas. Various paradigms have been developed for preoperative language mapping in fMRI<sup>1-7,12,15,16,18,20,21</sup>. However, a systemic study of the efficacy of those paradigms has not been performed<sup>1,2</sup>.

### The value of finding a paradigm that can localize expressive language areas

There are reports that fMRI is well correlated with the Wada test if the frontal language area is selected for language lateralization<sup>5,13</sup>. In this regard, it is important to

identify an effective paradigm for representing expressive language areas. We know that Broca's area is activated by paradigms such as naming or word generation<sup>1-7,12,15,16,18,20,21,25,27</sup>. Word generation with the use of fixation as a control is a commonly used paradigm due to its simplicity and ease of task<sup>1-7,12,15,16,18,20,21,25,27</sup>. The authors quantitatively analyzed the individual data in order to determine which combination would be better for visualization of expressive language areas and showed that the word generation paradigm is an effective paradigm for

functionally outlining the frontal language area if fixation is used as a contrast.

We focused on an area other than the hot spot in fMRI. The frontal expressive language area is larger than expected, and there is individual variation<sup>22,23</sup>. Thus, it is important to avoid damaging the whole language area rather than to save only the hot spot in fMRI in surgical planning. This is why we did not choose a spot but rather chose an area. However, setting the threshold to  $t > 3.92$  is somewhat arbitrary. Much data should be collected in order to differentiate essential versus non-essential activation in fMRI.

### The limitation of this study

We verified an effective paradigm for localizing the frontal language area. However, there are several limitations to this study. First, we assumed that all volunteers had left hemispheric dominance for language because all volunteers were right-handed, and this was verified by the Edinburgh Handedness Inventory. Second, although there are various paradigms for language mapping, our paradigms were restricted to five combinations. Third, this result was not verified with direct brain mapping method. However, the purpose of the present study is not presenting expressive language area but effective paradigm that is well correlated with expressive language area. Fourth, the number of subjects was small, and further studies with various paradigms for large subjects should be conducted. Fifth, application of such specific language tasks may lead to different results in Asian and e.g. North American or European volunteers and patients due to the calligraphically elements of written Asian words and their respective association with visual information. Nonetheless, we presented an effective language paradigm and its diagnostic value for localization of frontal expressive language area with individual quantitative analysis. We hope this study to be a stepping stone for developing



effective paradigms for different language areas.

## CONCLUSION

Different language paradigms in functional MR image have different effective expression of language area. Word generation versus fixation could effectively and reliably delineate the frontal language area. A customized effective paradigm should be analyzed in order to evaluate various language functions.

### • Acknowledgement

This study was supported in part by the Korea Science and Engineering Foundation (KOSEF) grant funded by the Korean government (MOST) (M1064400009-06N4400-00900) and by a grant (M103KV010016-06K2201-01610) from the Brain Research Center of the 21<sup>st</sup> Century Frontier Research Program funded by the Ministry of Science and Technology of the Republic of Korea.

## References

- Adcock JE, Wise RG, Oxbury JM, Oxbury SM, Matthews PM : Quantitative fMRI assessment of the differences in lateralization of language-related brain activation in patients with temporal lobe epilepsy. *Neuroimage* 18 : 423-438, 2003
- Alario FX, Chainay H, Lehericy S, Cohen L : The role of the supplementary motor area (SMA) in word production. *Brain Res* 1076 : 129-143, 2006
- Anderson DP, Harvey AS, Saling MM, Anderson V, Kean M, Abbott DF, et al : fMRI lateralization of expressive language in children with cerebral lesions. *Epilepsia* 47 : 998-1008, 2006
- Balsamo LM, Xu B, Gaillard WD : Language lateralization and the role of the fusiform gyrus in semantic processing in young children. *Neuroimage* 31 : 1306-1314, 2006
- Benke T, Köylü B, Visani P, Karner E, Brenneis C, Bartha L, et al : Language lateralization in temporal lobe epilepsy : a comparison between fMRI and the Wada Test. *Epilepsia* 47 : 1308-1319, 2006
- Briellmann RS, Labate A, Harvey AS, Saling MM, Sveller C, Lillywhite L, et al : Is language lateralization in temporal lobe epilepsy patients related to the nature of the epileptogenic lesion? *Epilepsia* 47 : 916-920, 2006
- Burton MW, Small SL : Functional neuroanatomy of segmenting speech and nonspeech. *Cortex* 42 : 644-651, 2006
- Chung SH, Jung JM, Paek SH, Shin T, Kim JH : Development of a system for functional mapping of the human brain using 1.5-tesla magnet, and its applications. *J Korean Neurosurg Soc* 26 : 1635-1643, 1997
- Cox RW : AFNI : software for analysis and visualization of functional magnetic resonance neuroimages. *Comput Biomed Res* 29 : 162-173, 1996
- Eickhoff SB, Stephan KE, Mohlberg H, Grefkes C, Fink GR, Amunts K, et al : A new SPM toolbox for combining probabilistic cytoarchitectonic maps and functional imaging data. *Neuroimage* 25 : 1325-1335, 2005
- Fernandez G, de Greiff A, von Oertzen J, Reuber M, Lun S, Klaver P, et al : Language mapping in less than 15 minutes : real-time functional MRI during routine clinical investigation. *Neuroimage* 14 : 585-594, 2001
- Grummich P, Nimsky C, Pauli E, Buchfelder M, Ganslandt O : Combining fMRI and MEG increases the reliability of presurgical language localization : a clinical study on the difference between and congruence of both modalities. *Neuroimage* 32 : 1793-1803, 2006
- Harrington GS, Buonocore MH, Farias ST : Intrasubject reproducibility of functional MR imaging activation in language tasks. *AJNR Am J Neuroradiol* 27 : 938-944, 2006
- Hickok G, Poeppel D : The cortical organization of speech processing. *Nat Rev Neurosci* 8 : 393-402, 2007
- Hugdahl K, Gundersen H, Brekke C, Thomsen T, Rimol LM, Erslund L, et al : fMRI brain activation in a Finnish family with specific language impairment compared with a normal control group. *J Speech Lang Hear Res* 47 : 162-172, 2004
- Jansen A, Deppe M, Schwindt W, Mohammadi S, Sehlmeier C, Knecht S : Interhemispheric dissociation of language regions in a healthy subject. *Arch Neurol* 63 : 1344-1346, 2006
- Jansen A, Menke R, Sommer J, Forster AF, Bruchmann S, Hempelman J, et al : The assessment of hemispheric lateralization in functional MRI—robustness and reproducibility. *Neuroimage* 33:204-217, 2006
- Joseph JE, Cerullo MA, Farley AB, Steinmetz NA, Mier CR : fMRI correlates of cortical specialization and generalization for letter processing. *Neuroimage* 32 : 806-820, 2006
- Kamada K, Todo T, Masutani Y, Aoki S, Ino K, Morita A, et al : Visualization of the frontotemporal language fibers by tractography combined with functional magnetic resonance imaging and magnetoencephalography. *J Neurosurg* 106 : 90-98, 2007
- Kraut MA, Pitcock JA, Calhoun V, Li J, Freeman T, Hart J Jr : Neuroanatomic organization of sound memory in humans. *J Cogn Neurosci* 18 : 1877-1888, 2006
- Mikuni N, Miyamoto S, Ikeda A, Satow T, Taki J, Takahashi J, et al : Subtemporal hippocampectomy preserving the basal temporal language area for intractable mesial temporal lobe epilepsy : preliminary results. *Epilepsia* 47 : 1347-1353, 2006
- Ojemann JG, Ojemann GA, Lettich E : Cortical stimulation mapping of language cortex by using a verb generation task : effects of learning and comparison to mapping based on object naming. *J Neurosurg* 97 : 33-38, 2002
- Quinones-Hinojosa A, Ojemann SG, Sanai N, Dillon WP, Berger MS : Preoperative correlation of intraoperative cortical mapping with magnetic resonance imaging landmarks to predict localization of the Broca area. *J Neurosurg* 99 : 311-318, 2003
- Rutten GJ, Ramsey NF, van Rijen PC, van Veelen CW : Reproducibility of fMRI-determined language lateralization in individual subjects. *Brain Lang* 80 : 421-437, 2002
- Schäffler L, Lüders HO, Morris HH, Wyllie E : Anatomic distribution of cortical language sites in the basal temporal language area in patients with left temporal lobe epilepsy. *Epilepsia* 35 : 525-528, 1994
- Suzuki K, Sakai KL : An event-related fMRI study of explicit syntactic processing of normal/anomalous sentences in contrast to implicit syntactic processing. *Cereb Cortex* 13 : 517-526, 2003
- Tremblay P, Gracco VL : Contribution of the frontal lobe to externally and internally specified verbal responses : fMRI evidence. *Neuroimage* 33 : 947-957, 2006