

Case Report

Orbital Apex Syndrome in a Patient with Sphenoid Fungal Balls

Seok Hyun Cho, MD · Bong Joon Jin, MD · Yong Seop Lee, MD · Seung Sam Paik, MD¹ · Myung Kyoo Ko, MD²
Hyeong-Joong Yi, MD³

Departments of Otorhinolaryngology-Head and Neck Surgery, ¹Pathology, ²Ophthalmology, and ³Neurosurgery, College of Medicine, Hanyang University, Seoul, Korea

Orbital apex syndrome (OAS) is a rare disease that presents with a complex of symptoms, including ophthalmoplegia, ptosis and visual loss. Due to the poor prognosis, making a prompt diagnosis and administering the appropriate treatment must be initiated without delay if OAS is suspected. We report here on a case of a patient with sphenoid fungal balls, and he presented with acute visual loss and ophthalmoplegia.

Key Words. Orbit, Sphenoid sinus, Fungi, Aspergillosis, Sterioids

INTRODUCTION

Neuro-ophthalmic emergencies such as giant cell arteritis, orbital apex syndrome (OAS), cavernous sinus thrombosis, intracranial aneurysm and pituitary apoplexy require urgent recognition and management due to their vision-threatening and potentially life-threatening nature. Patients suffering with OAS have complete ophthalmoplegia, ptosis, decreased corneal sensation and visual loss (1). This serious ocular complication may be the result of paranasal sinus diseases and especially disease in the posterior ethmoid and sphenoid sinuses (2). Early intervention and careful selection of the optimal therapeutic modalities must be considered according to the underlying causes and the extent of disease. We report here on a case of a diabetic patient who presented with acute visual loss and ophthalmoplegia that were complicated by sphenoid fungal balls.

CASE REPORT

A 64-yr-old man presented to the emergency room with right visual loss after a 5-day history of rhinorrhea, diplopia and severe

headache. The body temperature was 36.5°C and the white blood cell count was 9,100/mm³. He had a 10-yr history of poorly controlled type II diabetes mellitus. The initial blood sugar was measured and it was too high to register by a blood glucose test strip and it was decreased to 485 mg/dL after an IV infusion of normal saline. His right eye showed ptosis, mild eyelid swelling and total ophthalmoplegia. His visual acuity in the right eye was counting fingers (50 cm) and it was 20/40 in the left eye. The pupillary light reflex was lost with an afferent defect. The anterior chamber, the intraocular pressure and the fundi were normal. Endoscopic examination detected edematous mucosa, brown-colored fungal balls and there was a mucopurulent discharge from the sphenothmoidal recess. The ophthalmologic and nasal examinations of the left side showed no abnormal findings.

Computed tomography showed unilateral sphenothmoidal sinusitis along with signs of orbital invasion. Most of the orbital lesions were located at the retrobulbar area and the orbital apex, and inferior and medial rectus muscles were thickened. Even though there was bony erosion of the posterior wall of the sphenoid sinus, there was no evidence of intracranial extension. Increased signal intensities were noted at the same regions on brain MRI with gadolinium enhancement (Fig. 1). The initial clinical diagnosis was OAS due to invasive fungal sinusitis. Therefore, we immediately started systemic amphotericin B (50 mg/day for 21 days and 25 mg/day for 10 days) and insulin therapy to control his blood sugar. The patient was also started on intravenous ampicillin/sulbactam (6.0 g/day) and ceftriaxone sodium (2.0 g/day) to cover any possible bacterial infection.

The patient elected to undergo endoscopic sinus surgery under

• Received October 30, 2008
Accepted after revision December 15, 2008

• Corresponding author : **Seok Hyun Cho, MD**
Department of Otorhinolaryngology-Head and Neck Surgery, College of Medicine, Hanyang University, 17 Haengdang-dong, Seongdong-gu, Seoul 133-792, Korea
Tel : +82-2-2290-8591, Fax : +82-2-2293-3335
E-mail : shcho@hanyang.ac.kr

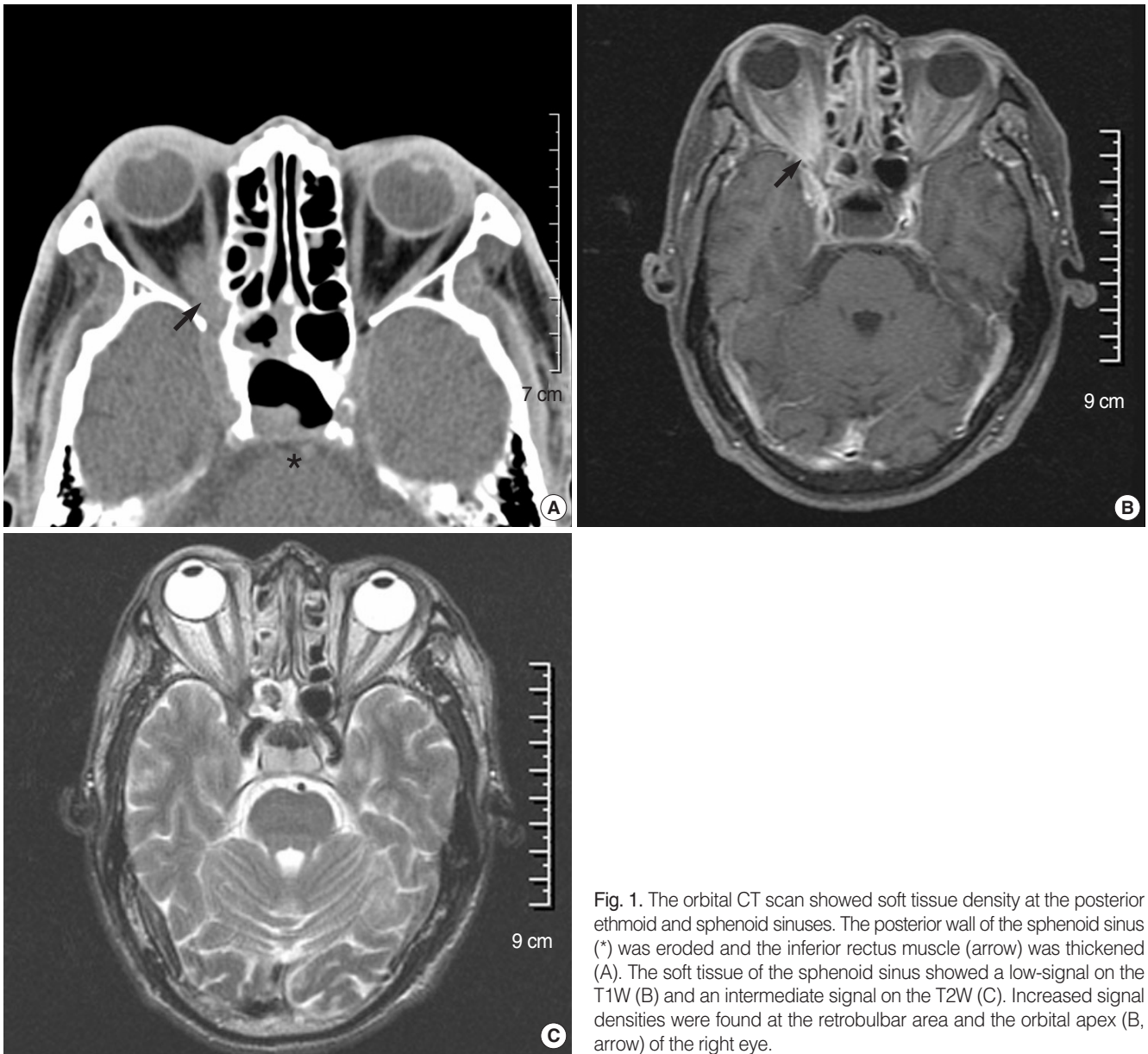


Fig. 1. The orbital CT scan showed soft tissue density at the posterior ethmoid and sphenoid sinuses. The posterior wall of the sphenoid sinus (*) was eroded and the inferior rectus muscle (arrow) was thickened (A). The soft tissue of the sphenoid sinus showed a low-signal on the T1W (B) and an intermediate signal on the T2W (C). Increased signal densities were found at the retrobulbar area and the orbital apex (B, arrow) of the right eye.

local anesthesia on the 3rd hospital day. The sphenoid sinus was filled with thick mucus and brown-colored matted fungal balls. All the fungal materials were removed using curettes and sinus irrigation. The mucosa around the ostium and the fungal materials were sent to the Department of Pathology for the determination of invasiveness.

By the 4th postoperative day (POD), there was no improvement and the visual acuity decreased from finger count to light perception. The patient complained of severe headache, nausea and vomiting; the follow-up computed tomography and cerebrospinal fluid (CSF) study showed no evidence of meningitis or intracranial invasion. The histopathology showed aspergillosis without evidence of tissue invasion. Therefore, empirical corticosteroid

therapy with prednisolone (PDS, 55 mg for 7 days, 40 mg for 7 days, and 20 mg for 7 days) was started on the 9th POD. After the 3rd day of PDS therapy, his headache and ophthalmic symptoms began to improve. With the exception of the ophthalmoplegia, the ptotic upper eyelid completely recovered and the visual acuity improved to 20/100 by the day of discharge (the 28th POD). The patient's blood sugar was not well controlled with fluctuations being noted during the hospitalization. By 3 months, the right visual acuity improved to 20/63 and the extraocular muscle movement was completely normalized. After 8 months, there was no recurrence of the nasal and orbital symptoms.

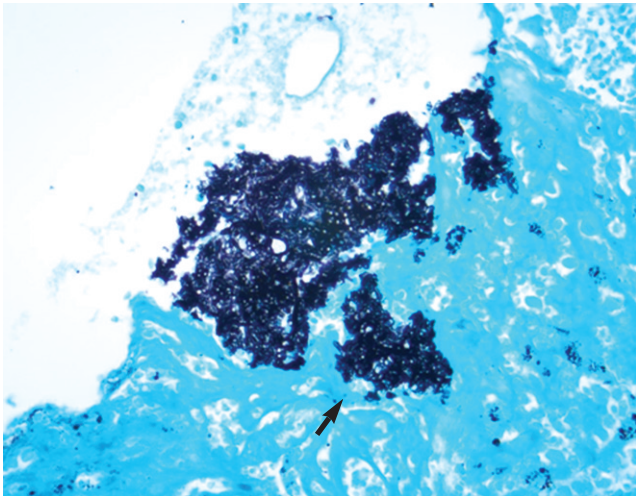


Fig. 2. Mucosal biopsy was performed during endoscopic sphenoidotomy. Gomori methenamine silver stain showed minimal tissue invasion of the fungal balls (arrow, $\times 400$).

DISCUSSION

A fungal ball is defined as the non-invasive accumulation of dense fungal hyphae in the sinus cavity (3). Typically, this occurs in immunocompetent patients; however, if immunodeficiency develops, then this fungal infection may become invasive (4). The treatment for invasive fungal sinusitis whether acute or chronic, is first reversing the source the patient's immunocompromised status, if present, followed by systemic antifungal therapy and surgical debridement (3). Because of the rare incidence of OAS that's caused by fungal infection, there has been no consensus on the proper therapeutic strategy when there has been no response to the aforementioned therapy. For this current case, the initial pathologic report was aspergillosis. With knowing that the fungus was non-invasiveness, an empirical trial of prednisolone (PDS) therapy was started due to the aggravated symptoms and the lack of a response to both amphotericin B and surgical drainage. After that, the patient's orbital symptoms began to improve. However, a detailed review of the slides that was done by a pathologist after patient's discharge showed evidence of minimal tissue invasion (Fig. 2), and we were quite surprised by this. Therefore, we believed that the invasive fungi was eliminated by amphotericin B and surgery, so the PDS therapy that was administered later didn't aggravate the fungal infection, but it had a critical role for controlling the orbital apex lesions, which may have been a secondary inflammatory reaction. Accurate assessment of the orbital apex pathology is very important when choosing the therapeutic modalities, but this is sometimes very difficult in clinical practice.

Although we did not perform orbital apex biopsy, we considered the orbital apex lesion to be non-invasive disease for the following reasons: 1) the lack of response to amphotericin B and surgical drainage, and 2) the dramatic improvement after systemic corticosteroid treatment. We believe that previous antifungal and surgical treatments might reverse the becoming invasive to non-invasive form of fungal balls.

The prognosis of OAS secondary to fungal infection is poor, and neurological sequelae and fatal outcomes have been reported in the majority of the cases (3, 5-8). When reviewing the case reports, the possible causes of a poor prognosis include a delayed presentation, preexisting lateral sphenoid bony dehiscence, advanced tissue invasion, misdiagnosis and the inappropriate use of systemic corticosteroids.

Fungal balls may become invasive depending on the host's immunity. There was histopathological evidence of minimal tissue invasion in this case, and if treatment had been delayed, then fulminate invasion may have occurred. Systemic corticosteroids at that stage are absolutely contraindicated. In conclusion, the changing characteristics and clinical behavior of fungal infection should be closely monitored to select the optimal therapeutic modalities. A future study on the proper clinical tools to identify a residual fungal infection after treatment is needed to help save the vision and often the life of patients who suffer with OAS secondary to fungal infection.

REFERENCES

1. Yeh S, Foroozan R. Orbital apex syndrome. *Curr Opin Ophthalmol.* 2004 Dec;15(6):490-8.
2. Tarazi AE, Shikani AH. Irreversible unilateral visual loss due to acute sinusitis. *Arch Otolaryngol Head Neck Surg.* 1991 Dec;117(12):1400-1.
3. Ferguson BJ. Fungus balls of the paranasal sinuses. *Otolaryngol Clin North Am.* 2000 Apr;33(2):389-98.
4. Gungor A, Adusumilli V, Corey JP. Fungal sinusitis: progression of disease in immunosuppression-a case report. *Ear Nose Throat J.* 1998 Mar; 77(3):207-10, 215.
5. Pieroth L, Winterkorn JM, Schubert H, Millar WS, Kazim M. Concurrent sino-orbital aspergillosis and cerebral nocardiosis. *J Neuroophthalmol.* 2004 Jun;24(2):135-7.
6. Thiagalingam S, Fernando GT, Tan K, O'Donnell BA, Weeks K, Branley M. Orbital apex syndrome secondary to *Pseudallescheria boydii* fungal sinusitis in an immunocompetent patient. *Clin Experiment Ophthalmol.* 2004 Oct;32(5):545-7.
7. Marcet MM, Yang W, Albert DM, Salamat MS, Appen RE. Aspergillus infection of the orbital apex masquerading as Tolosa-Hunt syndrome. *Arch Ophthalmol.* 2007 Apr;125(4):563-6.
8. Fernandes YB, Ramina R, Borges G, Queiroz LS, Maldaun MV, Maciel JA Jr. Orbital apex syndrome due to aspergillosis: case report. *Arq Neuro-psiquiatr.* 2001 Sep;59(3-B):806-8.