

Cystic Lymphangioma of the Breast in an Adult Woman

Kyueng-Whan Min · Si-Hyong Jang
Woong Na · Se Min Jang
Young Jin Jun · Ki-Seok Jang
Seung Sam Paik

Department of Pathology, College of
Medicine, Hanyang University, Seoul,
Korea

Received : May 29, 2008
Accepted : June 12, 2008

Corresponding Author

Seung Sam Paik, M.D.
Department of Pathology, College of Medicine,
Hanyang University, 17 Haengdang-dong,
Seongdong-gu, Seoul 133-792, Korea
Tel: 02-2290-8252
Fax: 02-2296-7502
E-mail: sspaik@hanyang.ac.kr

Cystic lymphangioma is also known as cystic hygroma, and this is a congenital malformation of the lymphatic system. Most lymphangiomas are present at birth and they are diagnosed by the age of 2. They are mostly located in the neck or axillary region. The breast as a site of origin is an extremely unusual location, and especially in adults. We report here on a case of cystic lymphangioma in a 36-year-old woman. Physical examination revealed a tender cystic mass in the upper outer quadrant of the right breast. Ultrasonography revealed an irregular hypoechoic mass lesion that was associated with irregular duct dilatation and several enlarged axillary lymph nodes. After the operation, the mass was revealed to be a cystic lymphangioma. Although it is very rare, cystic lymphangioma should be considered in the differential diagnosis of a breast mass in adults.

Key Words : Cystic lymphangioma; Adult; Breast

Cystic lymphangioma is a vascular malformation rather than a true neoplasm, and this lesion is believed to result from a failure of the lymphatic system to connect with the venous system.¹ This malady predominantly occurs in children and most cases present by the second year of life.² Ninety percent of the cases show occurrence of lesion in the neck or axillary region.^{1,3} Those lesions existing in the breast, and especially in adults, are quite rare. To the best of our knowledge, only 11 cases of lymphangioma in the breast have been reported in the English literature¹⁻¹¹ and 2 cases have been reported in the Korean literature.^{12,13} Here we report on an additional case of cystic lymphangioma in a 36-year-old woman.

CASE REPORT

A 36-year-old woman visited to our hospital with a progressively enlarged mass located in the upper outer quadrant of her right breast. There was no associated nipple discharge or other clinical symptoms. The past medical history included appendectomy in 1989 and 2 Cesarean sections in 1994 and 1999. The

physical examination revealed a tender, slightly movable multicystic mass in the upper outer quadrant of the right breast. The overlying skin and areola were unremarkable. Ultrasonography and mammography of the breast showed multiple irregular hypoechoic lesions associated with irregular duct dilatation (Fig. 1) and there were several enlarged lymph nodes in the right axilla. The breast lesion was radiologically suspicious for breast cancer and so the fine needle aspiration cytology (FNAC) was performed. FNAC showed a few lymphocytes in the background of pinkish white amorphous aspirated fluid, and so this was considered to be a benign cystic lesion. Mass excision was performed after obtaining the consent of the patient.

On gross examination, the cut surface of the breast showed an ill-demarcated grayish-white multicystic lesion that contained light yellow fluid. There was a large central cystic lesion that measured 4 × 3 cm at the diameter. Microscopically, the central cystic lesion showed an empty space lined by attenuated endothelial cells. The periphery of the cystic lesion showed many dilated thin-walled and thick-walled lymphatic spaces that were lined by endothelial cells. The lymphatic lumina were empty or they were filled with proteinaceous material, lymphocytes and rare

red blood cells. In the surrounding stroma, there was a mild patchy infiltration of lymphocytes, and lymphoid follicles were rarely noted. On immunohistochemical staining, the lining cells of the lymphatic spaces were strongly positive for CD34 (Fig. 2). The final diagnosis was a cystic lymphangioma of the breast. The patient's postoperative recovery was uneventful. The patient was asymptomatic, but recurrent cystic lesions around the previous excision site were found on ultrasonography after 11 months of follow-up.

DISCUSSION

Cystic lymphangioma is a malformation that arises from sequestration of lymphatic tissue that fails to communicate in a normal fashion with the lymphatic system; that is believed to result from a failure of the lymphatic system to connect with the venous

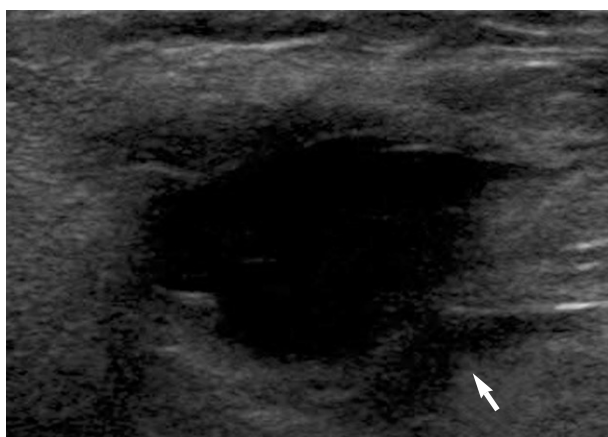


Fig. 1. The ultrasonography shows an irregular cystic lesion in the upper outer quadrant of the right breast (arrow).

system.^{1,3,11} The other etiologic factors of cystic lymphangioma include obstruction of the lymphatic channels with secondary dilatation, congenital weakness of the lymphatic wall and proliferation of the lymphatic vessels.⁵ Cystic lymphangioma is often associated with chromosomal abnormalities and other anatomical anomalies including Turner's syndrome, trisomy 21 and trisomy 18, as well as mosaic trisomy.¹

More than 90% of cystic lymphangiomas are presented in childhood and they are diagnosed by the age of 2. In almost all cases, the lesions are predominantly located in the neck or axillary region.^{1,3} The breast as an origin site of lymphangioma, and especially in adults, is an extremely unusual location. A review of the literature revealed only a few documented cases of cystic lymphangioma of the breast.¹⁻¹³ The age distribution of the reported cases was from 4 months to 49 years, and most cases were mainly located in the upper outer quadrant of the breast such as our case. This anatomical pattern of distribution is related to the drainage pattern of the lymphatics in the breast, which is mainly towards the tail and the axilla.^{2,3} Our case presented with a progressively enlarged mass located in the upper outer quadrant of the right breast in a 36-year-old woman.

Lymphangiomas are classified into the three subtypes, and these include simple lymphangioma, cavernous lymphangioma and cystic lymphangioma. The cystic lymphangioma is characterized by large, cyst-like spaces filled with clear lymph fluid and the spaces are lined by flat endothelial cells. The cyst lumen is empty or filled with proteinaceous fluid, lymphocytes and sometimes red blood cells.¹ The differential diagnosis of cystic lymphangioma includes simple cyst, a post-surgical liquid collection, hematoma, abscess and hemangioma. Simple cysts are usually bilateral and they often occur in other regions of the breast.

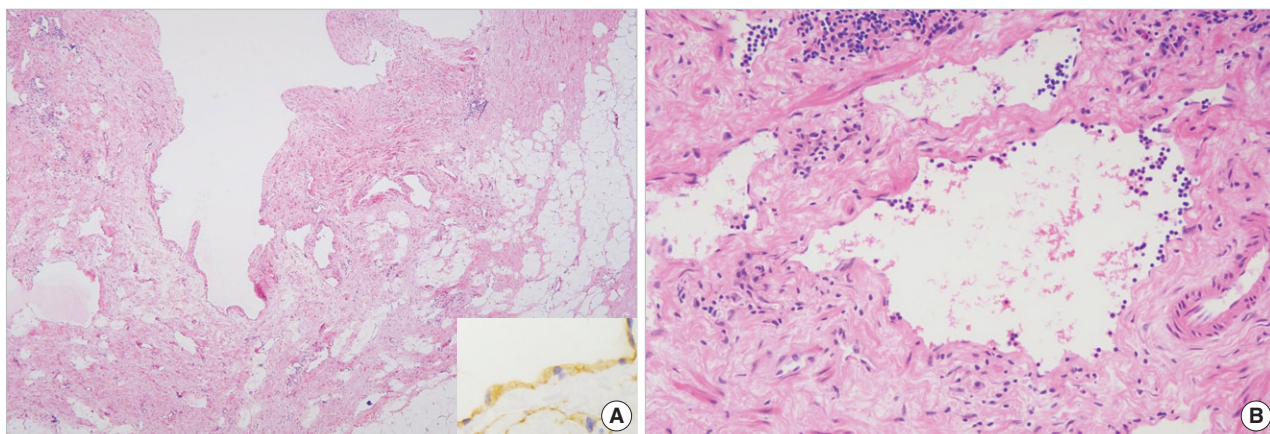


Fig. 2. The lesion shows a central large cyst lined by attenuated endothelial cells (A) and the lining cells of the spaces are strong positive of CD34 immunostaining (Inset). The periphery shows cystic spaces which are filled with proteinaceous fluid and some lymphocytes (B).

They show a cyst with turbid yellow or greenish fluid without lining cells. Hemangiomas generally appear with thick walled blood vessels with many red blood cells.^{1,3,5} There was no history of breast surgery, trauma or infection in our case.

The treatment choice for cystic lymphangioma is surgical removal, but there may be difficulty in obtaining safe margins due to the tendency of these lesions to infiltrate the surrounding tissues.¹ There is a high risk of incomplete excision, and this can possibly lead to rapid recurrence such as in our case. Our case showed cystic lesions that were considered to be a recurrent lymphangioma around the previous excision site at 11 months postoperatively.

In conclusion, we report here on a rare case of cystic lymphangioma of the breast in a 36-year-old woman, and we include a review of the relevant literature. Although the incidence of this disease is extremely rare in the adult breast, cystic lymphangioma should be considered in the differential diagnosis of an irregular cystic mass of the breast.

REFERENCES

1. Torcasio A, Veneroso S, Amabile MI, *et al.* Cystic hygroma of the breast: a rare lesion. *Tumori* 2006; 92: 347-50.
2. Ogun GO, Oyetunde O, Akang E. Cavernous lymphangioma of the breast. *World J Surg Oncol* 2007; 5: 69-72.
3. Chung SY, Oh KK, Kim DJ. Mammographic and sonographic findings of a breast cystic lymphangioma. *J Ultrasound Med* 2003; 22: 307-9.
4. de Guerke L, Baron M, Dessogne P, Callonnec F, d'Anjou J. Cystic lymphangioma of the breast. *Breast J* 2005; 11: 515-6.
5. Sa EJ, Choi YH. Cystic lymphangioma of the breast. *J Clin Ultrasound* 1999; 27: 351-2.
6. Kangesu T. Cystic hygroma of the breast in childhood. *Br J Clin Pract* 1990; 44: 787-8.
7. Sieber PR, Sharkey FE. Cystic hygroma of the breast. *Arch Pathol Lab Med* 1986; 110: 353.
8. Kurosumi M, Nomoto C, Suemasu K, *et al.* Cavernous lymphangioma of the breast-case report with electron microscopic and immunohistochemical investigations. *Jpn J Clin Oncol* 1991; 21: 129-34.
9. Chiba T, Ibrahim M. Cavernous lymphangioma of the breast-case report of an infant. *Nippon Geka Hokan* 1995; 64: 23-6.
10. Waqar SN, Khan H, Mekan SF, Kayani N, Raja AJ. Cystic breast lymphangioma. *J Pak Med Assoc* 2004; 54: 531-3.
11. Aryya NC, Rastogi AN, Kumar K, Shukla VK. Giant lymphangioma of the breast in an adult female. *Aust N Z J Surg* 1999; 69: 891-2.
12. Kook SH, Keum JS. Mammography, US and MR findings of cystic lymphangioma of the breast: a case report. *J Korean Radiol Soc* 1996; 35: 279-81.
13. Shin HJ, Yun EJ, Lee JK, Kim JR. Cystic lymphangioma of breast: a case report. *J Korean Radiol Soc* 1995; 32: 347-9.