

# World Journal of *Clinical Cases*

*World J Clin Cases* 2022 August 26; 10(24): 8432-8807



**EDITORIAL**

- 8432 Evolution of *World Journal of Clinical Cases* over the past 5 years  
*Muthu S*

**OPINION REVIEW**

- 8436 NF- $\kappa$ B: A novel therapeutic pathway for gastroesophageal reflux disease?  
*Zhang ML, Ran LQ, Wu MJ, Jia QC, Qin ZM, Peng YG*

**MINIREVIEWS**

- 8443 Obligate aerobic, gram-positive, weak acid-fast, nonmotile bacilli, *Tsukamurella tyrosinosolvans*: Minireview of a rare opportunistic pathogen  
*Usuda D, Tanaka R, Suzuki M, Shimozawa S, Takano H, Hotchi Y, Tokunaga S, Osugi I, Katou R, Ito S, Mishima K, Kondo A, Mizuno K, Takami H, Komatsu T, Oba J, Nomura T, Sugita M*
- 8450 Diffusion tensor imaging pipeline measures of cerebral white matter integrity: An overview of recent advances and prospects  
*Safri AA, Nassir CMNCM, Iman IN, Mohd Taib NH, Achuthan A, Mustapha M*
- 8463 Graft choices for anterolateral ligament knee reconstruction surgery: Current concepts  
*Chalidis B, Pitsilos C, Kitridis D, Givissis P*
- 8474 Overview of the anterolateral complex of the knee  
*Garcia-Mansilla I, Zicaro JP, Martinez EF, Astoul J, Yacuzzi C, Costa-Paz M*
- 8482 Complication of lengthening and the role of post-operative care, physical and psychological rehabilitation among fibula hemimelia  
*Salimi M, Sarallah R, Javanshir S, Mirghaderi SP, Salimi A, Khanzadeh S*

**ORIGINAL ARTICLE****Clinical and Translational Research**

- 8490 Pyroptosis-related genes play a significant role in the prognosis of gastric cancer  
*Guan SH, Wang XY, Shang P, Du QC, Li MZ, Xing X, Yan B*

**Retrospective Study**

- 8506 Effects of propofol combined with lidocaine on hemodynamics, serum adrenocorticotrophic hormone, interleukin-6, and cortisol in children  
*Shi S, Gan L, Jin CN, Liu RF*
- 8514 Correlation analysis of national elite Chinese male table tennis players' shoulder proprioception and muscle strength  
*Shang XD, Zhang EM, Chen ZL, Zhang L, Qian JH*

- 8525** Clinical value of contrast-enhanced ultrasound in early diagnosis of small hepatocellular carcinoma ( $\leq 2$  cm)

*Mei Q, Yu M, Chen Q*

- 8535** Identification of predictive factors for post-transarterial chemoembolization liver failure in hepatocellular carcinoma patients: A retrospective study

*Yuan M, Chen TY, Chen XR, Lu YF, Shi J, Zhang WS, Ye C, Tang BZ, Yang ZG*

- 8547** Clinical significance of half-hepatic blood flow occlusion technology in patients with hepatocellular carcinoma with cirrhosis

*Liu D, Fang JM, Chen XQ*

- 8556** Which octogenarian patients are at higher risk after cholecystectomy for symptomatic gallstone disease? A single center cohort study

*D'Acapito F, Solaini L, Di Pietrantonio D, Tauceri F, Mirarchi MT, Antelmi E, Flamini F, Amato A, Framarini M, Ercolani G*

#### Clinical Trials Study

- 8568** Computed tomography combined with gastroscopy for assessment of pancreatic segmental portal hypertension

*Wang YL, Zhang HW, Lin F*

#### Observational Study

- 8578** Psychological needs of parents of children with complicated congenital heart disease after admitting to pediatric intensive care unit: A questionnaire study

*Zhu JH, Jin CD, Tang XM*

#### Prospective Study

- 8587** Quantitative differentiation of malignant and benign thyroid nodules with multi-parameter diffusion-weighted imaging

*Zhu X, Wang J, Wang YC, Zhu ZF, Tang J, Wen XW, Fang Y, Han J*

#### Randomized Controlled Trial

- 8599** Application of unified protocol as a transdiagnostic treatment for emotional disorders during COVID-19: An internet-delivered randomized controlled trial

*Yan K, Yusufi MH, Nazari N*

- 8615** High-flow nasal cannula oxygen therapy during anesthesia recovery for older orthopedic surgery patients: A prospective randomized controlled trial

*Li XN, Zhou CC, Lin ZQ, Jia B, Li XY, Zhao GF, Ye F*

#### SYSTEMATIC REVIEWS

- 8625** Assessment tools for differential diagnosis of neglect: Focusing on egocentric neglect and allocentric neglect

*Lee SH, Lim BC, Jeong CY, Kim JH, Jang WH*

**CASE REPORT**

- 8634** Exome analysis for Cronkhite-Canada syndrome: A case report  
*Li ZD, Rong L, He YJ, Ji YZ, Li X, Song FZ, Li XA*
- 8641** Discrepancy between non-invasive prenatal testing result and fetal karyotype caused by rare confined placental mosaicism: A case report  
*Li Z, Lai GR*
- 8648** Paroxysmal speech disorder as the initial symptom in a young adult with anti-N-methyl-D-aspartate receptor encephalitis: A case report  
*Hu CC, Pan XL, Zhang MX, Chen HF*
- 8656** Anesthetics management of a renal angiomyolipoma using pulse pressure variation and non-invasive cardiac output monitoring: A case report  
*Jeon WJ, Shin WJ, Yoon YJ, Park CW, Shim JH, Cho SY*
- 8662** Traumatic giant cell tumor of rib: A case report  
*Chen YS, Kao HW, Huang HY, Huang TW*
- 8667** Analysis of two naval pilots' ejection injuries: Two case reports  
*Zeng J, Liu XP, Yi JC, Lu X, Liu DD, Jiang YQ, Liu YB, Tian JQ*
- 8673** Beware of the DeBakey type I aortic dissection hidden by ischemic stroke: Two case reports  
*Chen SQ, Luo WL, Liu W, Wang LZ*
- 8679** Unilateral lichen planus with Blaschko line distribution: A case report  
*Dong S, Zhu WJ, Xu M, Zhao XQ, Mou Y*
- 8686** Clinical features and progress of ischemic gastritis with high fatalities: Seven case reports  
*Shionoya K, Sasaki A, Moriya H, Kimura K, Nishino T, Kubota J, Sumida C, Tasaki J, Ichita C, Makazu M, Masuda S, Koizumi K, Kawachi J, Tsukiyama T, Kako M*
- 8695** Retinoblastoma in an older child with secondary glaucoma as the first clinical presenting symptom: A case report  
*Zhang Y, Tang L*
- 8703** Recurrent herpes zoster in a rheumatoid arthritis patient treated with tofacitinib: A case report and review of the literature  
*Lin QX, Meng HJ, Pang YY, Qu Y*
- 8709** Intra-abdominal ectopic bronchogenic cyst with a mucinous neoplasm harboring a *GNAS* mutation: A case report  
*Murakami T, Shimizu H, Yamazaki K, Nojima H, Usui A, Kosugi C, Shuto K, Obi S, Sato T, Yamazaki M, Koda K*
- 8718** Effects of intravascular photobiomodulation on motor deficits and brain perfusion images in intractable myasthenia gravis: A case report  
*Lan CH, Wu YC, Chiang CC, Chang ST*

- 8728** Spontaneous acute epidural hematoma secondary to skull and dural metastasis of hepatocellular carcinoma: A case report  
*Lv GZ, Li GC, Tang WT, Zhou D, Yang Y*
- 8735** Malignant melanotic nerve sheath tumors in the spinal canal of psammomatous and non-psammomatous type: Two case reports  
*Yeom JA, Song YS, Lee IS, Han IH, Choi KU*
- 8742** When should endovascular gastrointestinal anastomosis transection Glissonian pedicle not be used in hepatectomy? A case report  
*Zhao J, Dang YL*
- 8749** VARS2 gene mutation leading to overall developmental delay in a child with epilepsy: A case report  
*Wu XH, Lin SZ, Zhou YQ, Wang WQ, Li JY, Chen QD*
- 8755** Junctional bradycardia in a patient with COVID-19: A case report  
*Aedh AI*
- 8761** Application of 3 dimension-printed injection-molded polyether ether ketone lunate prosthesis in the treatment of stage III Kienböck's disease: A case report  
*Yuan CS, Tang Y, Xie HQ, Liang TT, Li HT, Tang KL*
- 8768** High scored thyroid storm after stomach cancer perforation: A case report  
*Baik SM, Pae Y, Lee JM*
- 8775** Cholecystitis-an uncommon complication following thoracic duct embolization for chylothorax: A case report  
*Dung LV, Hien MM, Tra My TT, Luu DT, Linh LT, Duc NM*
- 8782** Endometrial squamous cell carcinoma originating from the cervix: A case report  
*Shu XY, Dai Z, Zhang S, Yang HX, Bi H*
- 8788** Type 2 autoimmune pancreatitis associated with severe ulcerative colitis: Three case reports  
*Ghali M, Bensted K, Williams DB, Ghaly S*
- 8797** Diffuse uterine leiomyomatosis: A case report and review of literature  
*Ren HM, Wang QZ, Wang JN, Hong GJ, Zhou S, Zhu JY, Li SJ*

**LETTER TO THE EDITOR**

- 8805** Comment on "Posterior reversible encephalopathy syndrome in a patient with metastatic breast cancer: A case report"  
*Kunić S, Ibrahimagić OĆ, Kojić B, Džananović D*

**ABOUT COVER**

Editorial Board Member of *World Journal of Clinical Cases*, Ahmed Mohamed Ahmed Al-Emam, PhD, Associate Professor, Department of Pathology, King Khalid University, Abha 62521, Saudi Arabia. amalemam@kku.edu.sa

**AIMS AND SCOPE**

The primary aim of *World Journal of Clinical Cases (WJCC, World J Clin Cases)* is to provide scholars and readers from various fields of clinical medicine with a platform to publish high-quality clinical research articles and communicate their research findings online.

*WJCC* mainly publishes articles reporting research results and findings obtained in the field of clinical medicine and covering a wide range of topics, including case control studies, retrospective cohort studies, retrospective studies, clinical trials studies, observational studies, prospective studies, randomized controlled trials, randomized clinical trials, systematic reviews, meta-analysis, and case reports.

**INDEXING/ABSTRACTING**

The *WJCC* is now abstracted and indexed in Science Citation Index Expanded (SCIE, also known as SciSearch®), Journal Citation Reports/Science Edition, Current Contents®/Clinical Medicine, PubMed, PubMed Central, Scopus, Reference Citation Analysis, China National Knowledge Infrastructure, China Science and Technology Journal Database, and Superstar Journals Database. The 2022 Edition of Journal Citation Reports® cites the 2021 impact factor (IF) for *WJCC* as 1.534; IF without journal self cites: 1.491; 5-year IF: 1.599; Journal Citation Indicator: 0.28; Ranking: 135 among 172 journals in medicine, general and internal; and Quartile category: Q4. The *WJCC*'s CiteScore for 2021 is 1.2 and Scopus CiteScore rank 2021: General Medicine is 443/826.

**RESPONSIBLE EDITORS FOR THIS ISSUE**

Production Editor: *Ying-Yi Yuan*; Production Department Director: *Xu Guo*; Editorial Office Director: *Jin-Lei Wang*.

**NAME OF JOURNAL**

*World Journal of Clinical Cases*

**ISSN**

ISSN 2307-8960 (online)

**LAUNCH DATE**

April 16, 2013

**FREQUENCY**

Thrice Monthly

**EDITORS-IN-CHIEF**

Bao-Gan Peng, Jerzy Tadeusz Chudek, George Kontogeorgos, Maurizio Serati, Ja Hyeon Ku

**EDITORIAL BOARD MEMBERS**

<https://www.wjgnet.com/2307-8960/editorialboard.htm>

**PUBLICATION DATE**

August 26, 2022

**COPYRIGHT**

© 2022 Baishideng Publishing Group Inc

**INSTRUCTIONS TO AUTHORS**

<https://www.wjgnet.com/bpg/gerinfo/204>

**GUIDELINES FOR ETHICS DOCUMENTS**

<https://www.wjgnet.com/bpg/GerInfo/287>

**GUIDELINES FOR NON-NATIVE SPEAKERS OF ENGLISH**

<https://www.wjgnet.com/bpg/gerinfo/240>

**PUBLICATION ETHICS**

<https://www.wjgnet.com/bpg/GerInfo/288>

**PUBLICATION MISCONDUCT**

<https://www.wjgnet.com/bpg/gerinfo/208>

**ARTICLE PROCESSING CHARGE**

<https://www.wjgnet.com/bpg/gerinfo/242>

**STEPS FOR SUBMITTING MANUSCRIPTS**

<https://www.wjgnet.com/bpg/GerInfo/239>

**ONLINE SUBMISSION**

<https://www.f6publishing.com>

# Anesthetics management of a renal angiomyolipoma using pulse pressure variation and non-invasive cardiac output monitoring: A case report

Woo Jae Jeon, Woo Jong Shin, Young Joon Yoon, Chan Woo Park, Jae Hang Shim, Sang Yun Cho

**Specialty type:** Medicine, research and experimental

**Provenance and peer review:**

Unsolicited article; Externally peer reviewed.

**Peer-review model:** Single blind

**Peer-review report's scientific quality classification**

Grade A (Excellent): 0  
Grade B (Very good): B  
Grade C (Good): C  
Grade D (Fair): D  
Grade E (Poor): 0

**P-Reviewer:** Bhushan S, China;  
Wong KL, Taiwan

**Received:** January 20, 2022

**Peer-review started:** January 20, 2022

**First decision:** May 11, 2022

**Revised:** May 23, 2022

**Accepted:** July 22, 2022

**Article in press:** July 22, 2022

**Published online:** August 26, 2022



**Woo Jae Jeon, Woo Jong Shin, Young Joon Yoon, Chan Woo Park, Jae Hang Shim, Sang Yun Cho**, Department of Anesthesiology and Pain Medicine, Hanyang University Guri Hospital, Guri-si 471-701, Gyeonggi-do, South Korea

**Corresponding author:** Sang Yun Cho, MD, PhD, Professor, Department of Anesthesiology and Pain Medicine, Hanyang University Guri Hospital, No. 249-1 Gyomun-dong, Guri-si 471-701, Gyeonggi-do, South Korea. [chosy@hanyang.ac.kr](mailto:chosy@hanyang.ac.kr)

## Abstract

### BACKGROUND

Hypovolemic shock can lead to life-threatening organ dysfunction, and adequate fluid administration is a fundamental therapy. Traditionally, parameters such as vital signs, central venous pressure, and urine output have been used to estimate intravascular volume. Recently, pulse pressure variation (PPV) and non-invasive cardiac monitoring devices have been introduced. In this case report, we introduce a patient with massive active bleeding from giant renal angiomyolipoma (AML). During emergent nephrectomy, we used non-invasive cardiac monitoring with CSN-1901 (Nihon Kohden, Tokyo, Japan) and PPV to evaluate the patient's intravascular volume status to achieve optimal fluid management.

### CASE SUMMARY

A 30-year-old male patient with giant AML with active bleeding was referred to the emergency room complaining of severe abdominal pain and spontaneous abdominal distension. AML was diagnosed by computed tomography, and emergent nephrectomy was scheduled. Massive bleeding was expected so we decided to use non-invasive cardiac monitoring and PPV to assist fluid therapy because they are relatively easy and fast compared to invasive cardiac monitoring. During the surgery, 6000 mL of estimated blood loss occurred. Along with the patient's vital signs and laboratory results, we monitored cardiac output, cardiac output, stroke volume, stroke volume index with a non-invasive cardiac monitoring device, and PPV using an intra-arterial catheter to evaluate intravascular volume status of the patient to compensate for massive bleeding.

### CONCLUSION

In addition to traditional parameters, non-invasive cardiac monitoring and PPV are useful methods to evaluate patient's intravascular volume status and provide

guidance for intraoperative management of hypovolemic shock patients.

**Key Words:** Renal angiomyolipoma; Pulse pressure variation; Cardiac output; Case report

©The Author(s) 2022. Published by Baishideng Publishing Group Inc. All rights reserved.

**Core Tip:** We present a giant ruptured renal angiomyolipoma (> 20 cm) with active bleeding. Emergent operation was performed. The successful fluid management was carried with pulse pressure variation and noninvasive cardiac output monitoring.

**Citation:** Jeon WJ, Shin WJ, Yoon YJ, Park CW, Shim JH, Cho SY. Anesthetics management of a renal angiomyolipoma using pulse pressure variation and non-invasive cardiac output monitoring: A case report. *World J Clin Cases* 2022; 10(24): 8656-8661

**URL:** <https://www.wjgnet.com/2307-8960/full/v10/i24/8656.htm>

**DOI:** <https://dx.doi.org/10.12998/wjcc.v10.i24.8656>

## INTRODUCTION

Angiomyolipoma (AML) is a benign tumor of the kidney that accounts for up to 3% of all renal masses [1]. Most of these masses are sporadic and incidentally diagnosed. However, large AMLs (> 4 cm) can present with symptoms such as hemorrhage, pain, a palpable mass and mass-associated symptoms. Giant AMLs > 20 cm in size are rare, and few cases have been reported. Enlarging giant AMLs can produce an aneurysm that can rupture and lead to massive peri-renal bleeding and hypovolemic shock, a condition known as Wunderlich syndrome[2]. The dynamic parameters of fluid responsiveness are related to cardiopulmonary interactions under general anesthesia with mechanical ventilation. Pulse pressure variation (PPV) has shown great advantage to optimize hemodynamic parameters using physiological data from non-invasive means. PPV can assist with fluid administration and hemodynamic stability in patients under general anesthesia receiving mechanical ventilation[3]. We used a CSM-1901 (Nihon Kohden, 15-Tokyo, Japan) to non-invasively monitor the patient's cardiac output (CO), stroke volume (SV), continuous cardiac index (CCI), and stroke volume index (SVI). Additionally, we monitored PPV using an arterial line to ensure adequate administration of fluid during the surgery.

## CASE PRESENTATION

### Chief complaints

Old male patient presented to the hospital complaining of severe abdominal pain and a palpable mass in the abdomen.

### History of present illness

Abdominal distension started at 2 pm and Lt. abdomen was distended severely on arrival to emergency room at 7:50 pm.

### History of past illness

The patient had been in good health without no-known underlying disease.

### Physical examination

Abdominal distension began at 2 p.m., and the left side of the abdomen was severely distended upon arrival to the emergency department at 7:50 p.m. His initial vital signs were blood pressure: 142/81 mmHg, heart rate: 112 beats/min, respiratory rate: 20 times/min, and body temperature: 36.3 °C.

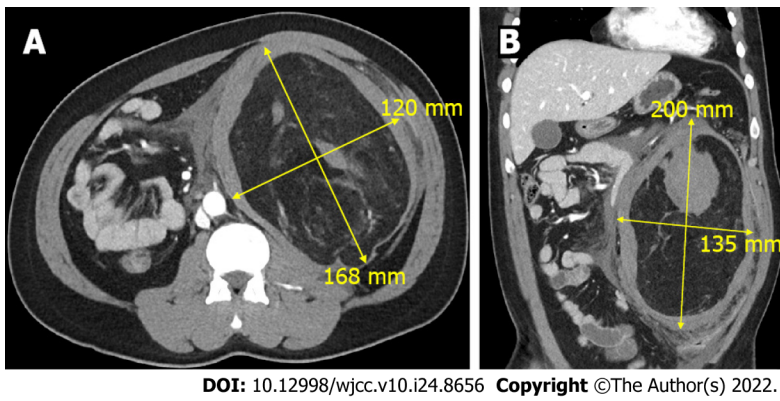
### Laboratory examinations

Initial laboratory tests showed hemoglobin 10.3 g/dL and hematocrit 29.8%.

### Imaging examinations

Abdominal computed tomography (CT) revealed a 22-cm AML with active bleeding near the left kidney, with a combined pseudoaneurysm (Figure 1).





**Figure 1** A 30-year-old male patient underwent computed tomography to reveal a 22 cm × 13 cm renal angiomyolipoma. A: The axial view; B: The coronal view.

---

## FINAL DIAGNOSIS

---

Left renal AML.

---

## TREATMENT

---

After considering the patient's vital signs and laboratory and CT findings, massive active bleeding was suspected, and emergent nephrectomy was scheduled. We expected a large amount of bleeding during surgery and used a non-invasive cardiac monitoring device (CSN-1901, Nihon Kohden, Tokyo, Japan) and PPV to assist evaluation of intravascular volume. These methods are relatively easy and fast to apply compared to invasive cardiac monitoring, which requires placement of a pulmonary catheter.

Upon arrival at the operating room, the patient's blood pressure was 150/100 mmHg, heart rate was 110 beats/min, and respiratory rate was 20 times/min. Anesthesia was induced through mask ventilation and 100% oxygen with 120 mg intravenous propofol and 50 mg rocuronium. Endotracheal intubation was achieved with a 7.5 endotracheal tube. Anesthesia was maintained with desflurane, nitric oxide, and remifentanyl. A right radial arterial cannula was inserted to monitor arterial pressure, and CSM-1901 (Nihon Kohden, Tokyo, Japan) was used to estimate CO, CCI, SV, and SVI. Hemoglobin and hematocrit levels were 10.8 g/dL and 32% at the initial arterial blood gas analysis, respectively.

Laparotomy began with a 15-cm left transverse subcostal incision. Immediately after opening the peritoneum, a huge renal mass with hematoma was observed; the mass was too big to approach all at once. Therefore, part of the mass was dissected, resulting in severe bleeding. A portion of the hematoma was removed, and the surgeon was better able to approach the mass. Nephrectomy was carried out along with removal of the mass.

During the surgery, the patient's CO, CCI, SV, SVI, and PPV were monitored (Figure 2). The patient was estimated to have lost 6000 mL of blood, for which 2950 mL of red blood cells and 953 mL of platelets were transfused. In addition, norepinephrine was administered to maintain proper vital signs. The patient's final hemoglobin level was 9.7 g/dL, while his hematocrit level was 29%. Prior to extubation, 200 mg of sugammadex was administered for neuromuscular blockade recovery. After extubation, the patient's vital signs were carefully monitored before transfer to the intensive care unit. Biopsy confirmed the mass to be a ruptured AML that measured 21 cm × 16 cm × 6 cm.

---

## OUTCOME AND FOLLOW-UP

---

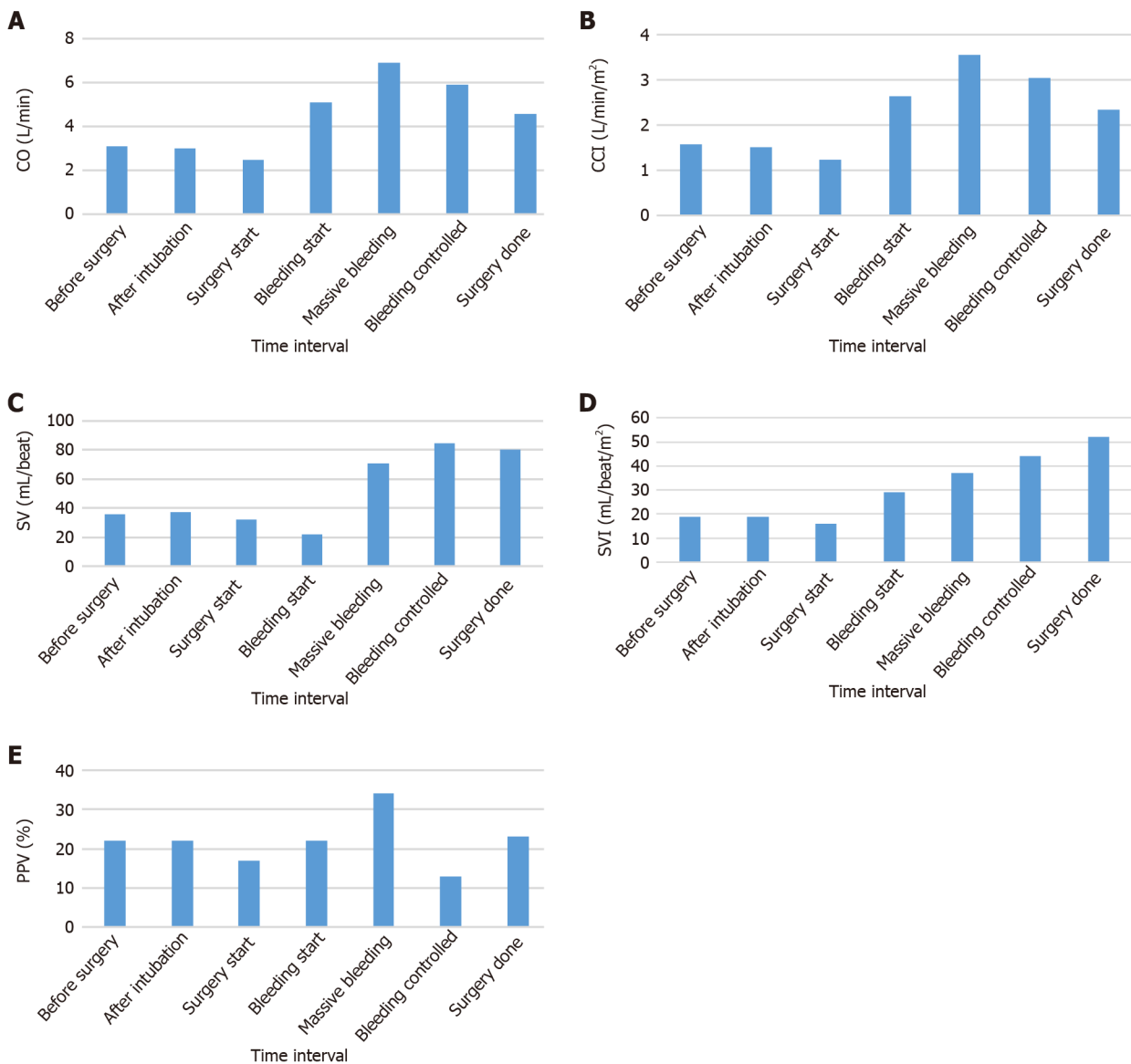
The patient was hospitalized for 9 d and left the hospital without a significant complication.

---

## DISCUSSION

---

Renal AML is a benign renal neoplasm. Small AMLs are usually asymptomatic and incidentally diagnosed on imaging. However, as the size increases, vascularity increases, resulting in vulnerability to rupture. In one study, the risk of bleeding was 13% with size < 4 cm and 51% with size > 4 cm[4]. Wunderlich syndrome is a spontaneous, non-traumatic renal hemorrhage that arises in the peri-renal space due to various medical conditions, including renal tumors, vascular disease, coagulation



DOI: 10.12998/wjcc.v10.i24.8656 Copyright ©The Author(s) 2022.

**Figure 2** Cardiac parameters were monitored non-invasively using CSN-1901 (Nihon Kohden, Tokyo, Japan) during nephrectomy of a 30-year-old male patients who was diagnosed with ruptured angiomyoliopoma. Additionally, pulse pressure variation was monitored by intra-arterial catheter. A: Cardiac output; B: Continuous cardiac output index; C: Stroke volume; D: Stroke volume index; E: Pulse pressure variation. CO: Cardiac output; CCI: Continuous cardiac index; SV: Stroke volume; SVI: Stroke volume index; PPV: Pulse pressure variation.

disorders, and idiopathic causes[5]. Urgent contrast-enhanced CT is recommended for diagnosis, and proper management is required because many cases present with hypovolemic shock due to massive hemorrhage. Although proper fluid management is critical, it is extremely difficult to determine the intravascular volume of patients with AML, especially those with active bleeding.

Traditionally, parameters such as blood pressure, heart rate, central venous pressure, and urine output have been used to estimate intravascular volume. However, recent studies support the use of hemodynamic parameters in patients undergoing major invasive surgery because large blood loss and fluid shifting are expected, and this method provides better volume responsiveness compared with traditional parameters[6,7]. The CO is especially important because it is a main determinant of oxygen delivery. CO can be measured invasively (*i.e.*, pulmonary artery and transpulmonary thermodilution), minimally invasively (*i.e.*, esophageal doppler, minimally invasive pulse wave analysis), or non-invasively (*i.e.*, non-invasive pulse wave analysis, pulse wave transit time, thoracic bioimpedance and bioreactance).

PPV was measured using intra-arterial catheter. During controlled mechanical ventilation, the intrathoracic pressure changes between inspiration and expiration, which affects the venous return to the heart and leads to change in SV and blood pressure variations. A PPV > 13% suggests fluid responsiveness and indicates that additional fluid administration might be required[8].

CSM-1901 is a modality based on pulse wave transit time and also utilizes R-waves from the electrocardiogram and pulse waves in the periphery (using a pulse oximeter) along with patient blood pressure and other biometric data to estimate CO and SV. Monitoring traditional parameters using PPV and CO is beneficial to determine intravascular volume[9].

---

## CONCLUSION

Adequate administration of fluid for patients with hemorrhage is a fundamental treatment. In addition to traditional parameters, non-invasive cardiac monitoring and PPV are useful methods to assist evaluation of patient's intravascular volume status and provide a guidance to anesthesiologist for intraoperative management of hypovolemic shock patients.

---

## ACKNOWLEDGEMENTS

The authors thank the Hanyang University E-world center for considerable help during preparation of the manuscript.

---

## FOOTNOTES

**Author contributions:** All authors including Jeon WJ, Shin WJ, Yoon YJ, Park CW, Shim JH and Cho SY participated in care of the patient, revised this manuscript, and have read and approved the final manuscript.

**Informed consent statement:** All study participants or their legal guardian provided informed written consent about personal and medical data collection prior to study enrolment.

**Conflict-of-interest statement:** All the authors report no relevant conflicts of interest for this article.

**CARE Checklist (2016) statement:** The authors have read the CARE Checklist (2016), and the manuscript was prepared and revised according to the CARE Checklist (2016).

**Open-Access:** This article is an open-access article that was selected by an in-house editor and fully peer-reviewed by external reviewers. It is distributed in accordance with the Creative Commons Attribution NonCommercial (CC BY-NC 4.0) license, which permits others to distribute, remix, adapt, build upon this work non-commercially, and license their derivative works on different terms, provided the original work is properly cited and the use is non-commercial. See: <https://creativecommons.org/licenses/by-nc/4.0/>

**Country/Territory of origin:** South Korea

**ORCID number:** Woo Jae Jeon 0000-0002-9662-4197; Woo Jong Shin 0000-0002-3786-2267; Young Joon Yoon 0000-0002-7351-3371; Jae Hang Shim 0000-0002-3533-6407; Sang Yun Cho 0000-0002-6593-1960.

**S-Editor:** Fan JR

**L-Editor:** A

**P-Editor:** Fan JR

---

## REFERENCES

- 1 **Alshehri M**, Hakami B, Aljameel N, Alayyaf M, Raheem AA. Sporadic giant renal angiomyolipoma: A case report and literature review of clinical presentation, diagnosis, and treatment options. *Urol Ann* 2020; **12**: 167-171 [PMID: 32565656 DOI: 10.4103/UA.UA\_26\_19]
- 2 **Chronopoulos PN**, Kaisidis GN, Vaiopoulos CK, Perits DM, Varvarousis MN, Malioris AV, Pazarli E, Skandalos IK. Spontaneous rupture of a giant renal angiomyolipoma-Wunderlich's syndrome: Report of a case. *Int J Surg Case Rep* 2016; **19**: 140-143 [PMID: 26764888 DOI: 10.1016/j.ijscr.2015.12.017]
- 3 **Cannesson M**, Aboy M, Hofer CK, Rehman M. Pulse pressure variation: where are we today? *J Clin Monit Comput* 2011; **25**: 45-56 [PMID: 20390324 DOI: 10.1007/s10877-010-9229-1]
- 4 **Nelson CP**, Sanda MG. Contemporary diagnosis and management of renal angiomyolipoma. *J Urol* 2002; **168**: 1315-1325 [PMID: 12352384 DOI: 10.1097/01.ju.0000028200.86216.b2]
- 5 **Bhatty T**, Zia A, Khan IA, Nawaz G. Wunderlich syndrome with spontaneous renal hemorrhage into renal angiomyolipoma. *Urol Ann* 2020; **12**: 392-393 [PMID: 33776340 DOI: 10.4103/UA.UA\_169\_19]
- 6 **Magder S**. Flow-directed vs. goal-directed strategy for management of hemodynamics. *Curr Opin Crit Care* 2016; **22**: 267-273 [PMID: 27078223 DOI: 10.1097/MCC.000000000000298]

- 7 **Funk DJ**, Moretti EW, Gan TJ. Minimally invasive cardiac output monitoring in the perioperative setting. *Anesth Analg* 2009; **108**: 887-897 [PMID: [19224798](#) DOI: [10.1213/ane.0b013e31818ffd99](#)]
- 8 **Cannesson M**, Le Manach Y, Hofer CK, Goarin JP, Lehot JJ, Vallet B, Tavernier B. Assessing the diagnostic accuracy of pulse pressure variations for the prediction of fluid responsiveness: a "gray zone" approach. *Anesthesiology* 2011; **115**: 231-241 [PMID: [21705869](#) DOI: [10.1097/ALN.0b013e318225b80a](#)]
- 9 **Saugel B**, Thiele RH, Hapfelmeier A, Cannesson M. Technological Assessment and Objective Evaluation of Minimally Invasive and Noninvasive Cardiac Output Monitoring Systems. *Anesthesiology* 2020; **133**: 921-928 [PMID: [32773696](#) DOI: [10.1097/ALN.0000000000003483](#)]



Published by **Baishideng Publishing Group Inc**  
7041 Koll Center Parkway, Suite 160, Pleasanton, CA 94566, USA  
**Telephone:** +1-925-3991568  
**E-mail:** [bpgoffice@wjgnet.com](mailto:bpgoffice@wjgnet.com)  
**Help Desk:** <https://www.f6publishing.com/helpdesk>  
<https://www.wjgnet.com>

