

Diagnostic Performance of Hybrid Cardiac Imaging Methods for Assessment of Obstructive Coronary Artery Disease Compared With Stand-Alone Coronary Computed Tomography Angiography



A Meta-Analysis

Asim Rizvi, MD,^{a,b} Donghee Han, MD,^{a,c} Ibrahim Danad, MD,^d Bríain Ó Hartaigh, PhD,^a Ji Hyun Lee, MD,^{a,c} Heidi Gransar, MSc,^e Wijnand J. Stuijzand, MD,^a Hadi Mirhedayati Roudsari, MD,^a Mahn Won Park, MD,^a Jackie Szymonifka, MA,^a Hyuk-Jae Chang, MD, PhD,^c Erica C. Jones, MD,^a Paul Knaapen, MD,^d Fay Y. Lin, MD,^a James K. Min, MD,^a Jessica M. Peña, MD, MPH^a

ABSTRACT

OBJECTIVES The current meta-analysis aimed to evaluate the diagnostic performance of hybrid cardiac imaging techniques compared with stand-alone coronary computed tomography angiography (CTA) for assessment of obstructive coronary artery disease (CAD).

BACKGROUND The usefulness of coronary CTA for detecting obstructive CAD remains suboptimal at present. Myocardial perfusion imaging encompasses positron emission tomography, single-photon emission computed tomography, and cardiac magnetic resonance, which permit the identification of myocardial perfusion defects to detect significant CAD. A hybrid approach comprising myocardial perfusion imaging and coronary CTA may improve diagnostic performance for detecting obstructive CAD.

METHODS PubMed and Web of Knowledge were searched for relevant publications between January 1, 2000 and December 31, 2015. Studies using coronary CTA and hybrid imaging for diagnosis of obstructive CAD (a luminal diameter reduction of >50% or >70% by invasive coronary angiography) were included. In total, 12 articles comprising 951 patients and 1,973 vessels were identified, and a meta-analysis was performed to determine pooled sensitivity, specificity, and summary receiver-operating characteristic curves.

RESULTS On a per-patient basis, the pooled sensitivity of hybrid imaging was comparable to that of coronary CTA (91% vs. 90%; $p = 0.28$). However, specificity was higher for hybrid imaging versus coronary CTA (93% vs. 66%; $p < 0.001$). On a per-vessel basis, sensitivity for hybrid imaging against coronary CTA was comparable (84% vs. 89%; $p = 0.29$). Notably, hybrid imaging yielded a specificity of 95% versus 83% for coronary CTA ($p < 0.001$). Summary receiver-operating characteristic curves displayed improved discrimination for hybrid imaging beyond coronary CTA alone, on a per-vessel basis (area under the curve: 0.97 vs. 0.93; $p = 0.047$), although not on a per-patient level (area under the curve: 0.97 vs. 0.93; $p = 0.132$).

CONCLUSIONS Hybrid cardiac imaging demonstrated improved diagnostic specificity for detection of obstructive CAD compared with stand-alone coronary CTA, yet improvement in overall diagnostic performance was relatively limited. (J Am Coll Cardiol Img 2018;11:589–99) © 2018 The Authors. Published by Elsevier on behalf of the American College of Cardiology Foundation. This is an open access article under the CC BY-NC-ND license (<http://creativecommons.org/licenses/by-nc-nd/4.0/>).

**ABBREVIATIONS
AND ACRONYMS**

AUC = area under the curve
CAD = coronary artery disease
CMR = cardiac magnetic resonance
CTA = computed tomography angiography
CT = computed tomography
DOR = diagnostic odds ratio
FFR = fractional flow reserve
ICA = invasive coronary angiography
LR = likelihood ratio
MPI = myocardial perfusion imaging
NPV = negative predictive value
PET = positron emission tomography
PPV = positive predictive value
QCA = quantitative coronary analysis
QUADAS-2 = Quality Assessment of Diagnostic Accuracy Studies
SPECT = single-photon emission computed tomography
sROC = summary receiver-operating characteristic

Coronary computed tomography angiography (CTA) represents a noninvasive imaging modality that permits direct visualization of coronary artery disease (CAD). Coronary CTA is a robust tool for identifying the presence or absence of CAD and provides a wealth of prognostic information (1). Although numerous studies have confirmed the high negative predictive value (NPV) and sensitivity of coronary CTA, the positive predictive value (PPV) and specificity of this modality are typically lower (2,3). Specifically, an overestimation of stenosis by coronary CTA is often observed (4,5). In light of this finding, a coronary CTA-guided coronary stenosis strategy should perhaps be considered a suboptimal indicator of obstructive CAD.

Myocardial perfusion imaging (MPI) encompasses positron emission tomography (PET), single-photon emission computed tomography (SPECT), and cardiac magnetic resonance (CMR). These modalities identify stress-induced wall motion abnormalities or regional myocardial perfusion defects, and they serve to identify individuals who may have flow-limiting coronary artery stenoses. A hybrid approach combining both modalities, MPI and coronary CTA, has the advantage of fusing the anatomic coronary CTA-derived

To understand the clinical utility of this approach, we conducted a systematic publication review and meta-analysis to evaluate the diagnostic performance of hybrid cardiac imaging techniques in comparison with stand-alone coronary CTA for assessment of obstructive CAD as determined by invasive coronary angiography (ICA), a reference standard.

METHODS

PUBLICATION SEARCH. The electronic databases PubMed and Institute for Scientific Information Web of Knowledge (now known as Web Science) were systematically examined to locate relevant articles in English by using predefined search criteria (Table 1) (2,6-16). The search was confined to investigations that were published between January 1, 2000, and December 31, 2015. The following search terms were used: positron emission tomography OR single photon emission computed tomography OR magnetic resonance imaging OR stress myocardial perfusion imaging OR functional AND (coronary computed tomography angiography OR anatomic) AND (combined or hybrid or comprehensive assessment) AND (diagnosis or detection) AND (coronary artery disease OR myocardial ischemia). Three investigators (A.R., D.H., and J.L.) independently scanned all manuscripts and performed data extraction. Abstracts were excluded because of insufficient data. All retrieved studies were examined, and any potential overlapping data were omitted. Two independent reviewers (A.R. and D.H.) performed the final screening of reports for inclusion in the meta-analysis. In the event of any discord, a general consensus was met between the reviewers after further extensive review of the full text articles.

STUDY ELIGIBILITY. The inclusion criteria for studies in the analysis were as follows: 1) symptomatic patients with suspected CAD who underwent both coronary CTA and MPI, using hybrid approach; 2) ICA with quantitative coronary analysis (QCA) that served as the reference standard for obstructive CAD with at least 50% luminal diameter reduction; and 3) absolute numbers of false-positive or false-negative results

SEE PAGE 600

data with functional MPI perfusion data. In doing so, a hybrid approach has the potential to overcome the limitations of coronary CTA. One potential benefit of using perfusion data is that these data may assist in differentiating artifact-driven stenosis from true coronary luminal diameter narrowing, a distinction that may facilitate in diminishing the false-positive rate of coronary CTA. This dual-modality approach could therefore improve diagnostic performance for detecting obstructive CAD by overcoming many of the drawbacks relative to stand-alone coronary CTA.

From the ^aDalio Institute of Cardiovascular Imaging, Department of Radiology, New York-Presbyterian Hospital and Weill Cornell Medicine, New York, New York; ^bDepartment of Radiology, Mayo Clinic, Rochester, Minnesota; ^cDivision of Cardiology, Severance Cardiovascular Hospital, Yonsei University Health System, Seoul, South Korea; ^dDepartment of Cardiology, VU University Medical Center, Amsterdam, the Netherlands; and the ^eDepartments of Imaging and Medicine, Cedars-Sinai Heart Institute, Cedars-Sinai Medical Center, Los Angeles, California. This study was funded by National Institutes of Health grants R01 HL111141 and R01 HL118019; and was also supported in part by generous gifts from the Dalio Institute of Cardiovascular Imaging and the Michael Wolk Foundation. Dr. Min serves on the advisory board of Arineta; has ownership in MDDX and Autoplaq; and has a research agreement with GE Healthcare. All other authors have reported that they have no relationships relevant to the contents of this paper to disclose. Drs. Rizvi and Han contributed equally to this work. Matthew Budoff, MD, served as the Guest Editor for this paper.

Manuscript received February 1, 2017; revised manuscript received May 23, 2017, accepted May 29, 2017.

TABLE 1 Study and Test Characteristics

First Author, Year (Ref. #)	Test Characteristics	Patients	Vessels	Age, yrs	Male	Criteria for Performing Hybrid Imaging	Reference Standard	Time Interval	QCA Threshold
Thomassen, 2013 (6)	PET/64-slice MDCT	44	176	66 ± 9	23 (52)	Patients with suspected CAD	QCA	1 day	≥50%
Groothuis, 2013 (7)	CMR/64-slice MDCT	88		56 ± 10	96 (49)	Patients with suspected CAD	QCA ± FFR	2 months	QCA >70% or FFR ≤0.75 if 30%-70% diameter stenosis, or QCA >50% if FFR was not available
Schaap, 2013 (8)	SPECT/64-slice MDCT	98		63 ± 10	67 (68)	Patients with suspected CAD	QCA + FFR	14 days	QCA ≥50% FFR <0.80
Li, 2013 (9)	SPECT/64-slice MDCT	54	216	57 ± 9	36 (67)	Patients with suspected or known CAD	QCA + MPI	30 days	≥50%
Danad, 2013 (10)	PET/64-slice MDCT	120	360	61 ± 10	77 (64)	Patients with suspected CAD	QCA ± FFR	70 days	QCA ≥50% FFR ≤0.80
Kadokami, 2012 (11)	SPECT/64-slice MDCT	49	145	70 ± 8	35 (71)	Patients with suspected or known CAD	QCA + MPI	3 months	≥50%
Kajander, 2010 (12)	PET/64-slice MDCT	107	416	63.6 ± 7	64 (60)	Patients with suspected CAD	QCA + FFR	2 weeks	QCA ≥50% FFR ≤0.80
Winther, 2015 (13)	SPECT/dual-source	138		54 (22-72)	94 (68)	Pre-renal transplant cardiac evaluation	QCA	34 days	≥50%
Scheffel, 2010 (14)	CMR/dual-source	43	129	63 ± 9	34 (79)	Patients with suspected or known CAD	QCA	20 days	>50%
Donati, 2010 (14)	CMR/dual-source	47	141	64 ± 9	38 (81)	Patients with suspected or known CAD	QCA	8 days	>50%
Sato, 2010 (16)	SPECT/64-slice MDCT	130	390	67 ± 11	91 (70)	Patients with suspected CAD	QCA	1 month	≥50%
Groves, 2009 (2)	PET/64-slice MDCT	33		62 (47-74)	28 (85)	Patients with suspected CAD	QCA		≥50%

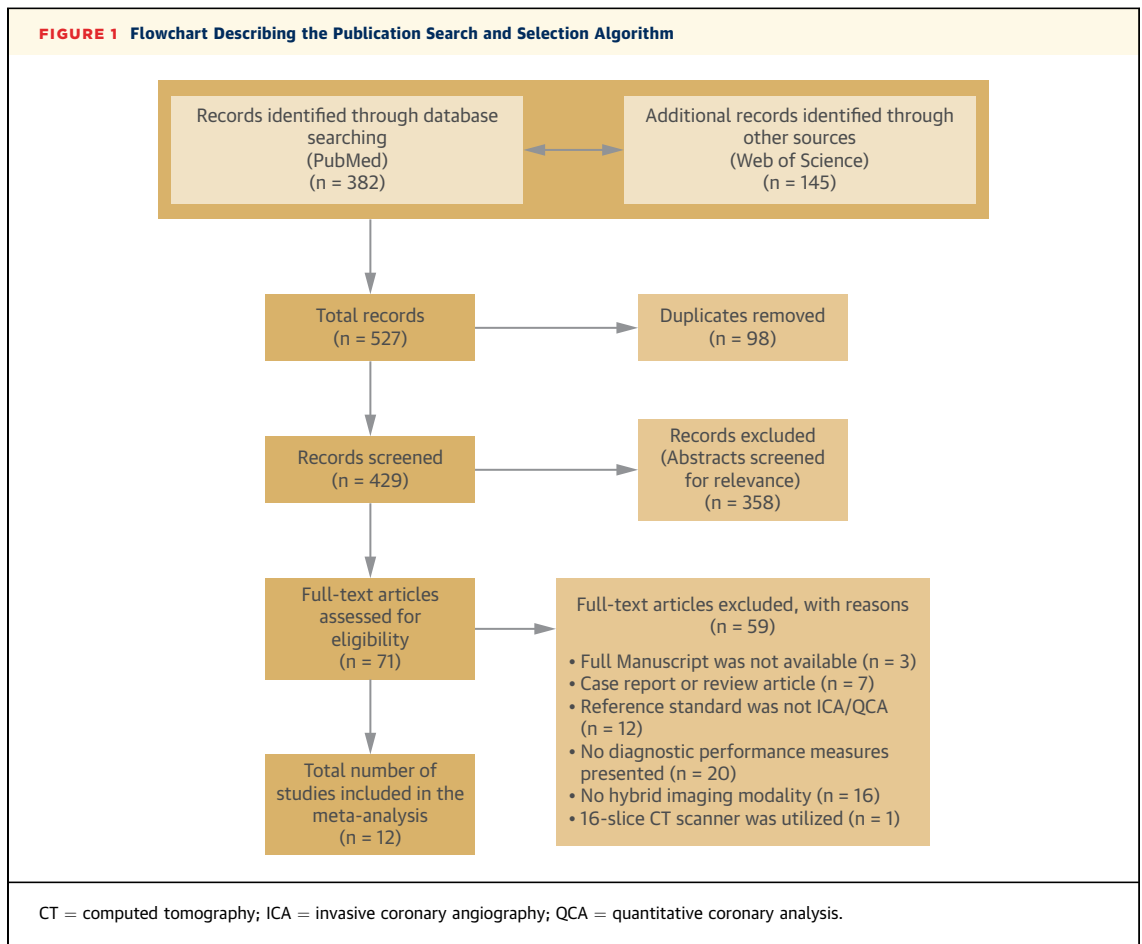
Values are N, mean ± SD, or n (%).
 CAD = coronary artery disease; CMR = cardiac magnetic resonance imaging; FFR = fractional flow reserve; MDCT = multidetector computed tomography; MPI = myocardial perfusion imaging; PET = positron emission tomography; QCA = quantitative coronary analysis; SPECT = single-photon emission computed tomography.

and true-positive or true-negative results when using both coronary CTA and hybrid cardiac imaging approaches that were reported in the article, or wherein sufficient data were available so that a 2×2 contingency table of results could be constructed. Studies were excluded from this meta-analysis if a computed tomography (CT) scanner with fewer than 64 slices was used. All patients in the studies selected for this meta-analysis underwent both noninvasive anatomic and functional imaging, regardless of the coronary CTA findings.

DATA COLLECTION. For the current meta-analysis, 3 independent authors (A.R., D.H., and J.L.) initially performed all data extraction, with subsequent verification independently performed by 2 of the authors (A.R. and D.H.). The following data were collected for each eligible investigation: year of publication, patients’ demographics, type of hybrid cardiac imaging methods, number of patients and vessels, criteria for hybrid imaging, and the QCA threshold used to describe obstructive CAD. The reference standard for the current meta-analysis was

obstructive CAD with a diameter reduction of >50% or >70%, as defined by ICA with QCA analysis. For the meta-analysis, absolute numbers of true- and false-positive results and true- and false-negative results were extracted from the articles or were otherwise calculated from data provided in these articles. The findings were then summarized in a 2×2 contingency table. The selected articles were also evaluated for included references to ensure complete inclusion of all studies. The methodological quality of the selected studies was independently assessed by 2 of the authors (A.R. and D.H.) according to the Quality Assessment of Diagnostic Accuracy Studies (QUADAS-2) scale (17). Any discrepancies in quality assessment were resolved by consensus discussion.

DATA ANALYSIS. Pooled measures for sensitivity, specificity, likelihood ratios (LRs), diagnostic odds ratio (DOR), and area under the curves (AUC) along with their 95% confidence intervals (CIs) were calculated using DerSimonian-Laird methodology (18). Calculation of DOR in this meta-analysis permitted

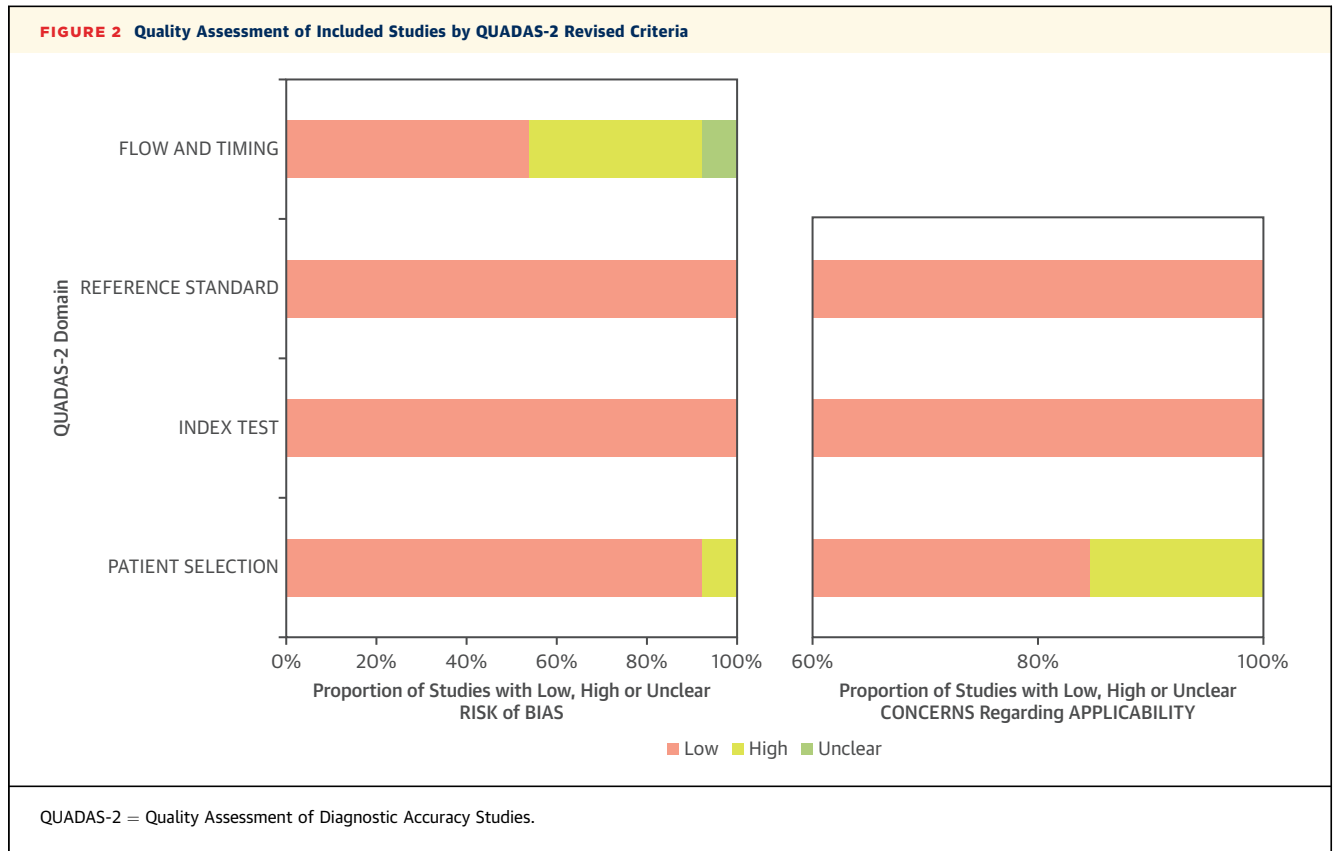


testing of the discriminatory ability of both hybrid cardiac imaging and stand-alone coronary CTA for detecting obstructive and nonobstructive CAD. Specifically, a DOR of 1 indicates that the test has no discriminative power, and a higher DOR is associated with improved diagnostic accuracy. The pooled diagnostic data were presented in test summary receiver-operating characteristic (sROC) curves, which were reconstructed using Moses-Shapiro-Littenberg methodology and having the pooled DOR of each index test as their basis (19). The Deeks method was used to test for possible publication bias (20). A Cochran Q statistic and the I^2 index were also used to test for any heterogeneity among the included studies. A substantial I^2 index indicates heterogeneity beyond sampling variation. The heterogeneity was defined as low, moderate, and high by an I^2 index of 25% to 50%, 50% to 75%, and >75%, respectively (21). Analyses were performed using STATA software version 14 (StataCorp LP, College Station, Texas) and Meta-DiSc 1.4 (22); p values <0.05 were considered statistically significant.

RESULTS

A systematic search revealed 527 potentially relevant articles. After removing 98 duplicates, 429 articles were screened by title and abstract. Of these, 71 articles were read in their full-text versions. Finally, a total of 12 studies met the inclusion criteria and were included in the meta-analysis. A flowchart of the search and selection process of the articles is shown in Figure 1.

Baseline characteristics of each study are listed in Table 1. Of a total 951 patients, 739 (72%) were male, and the mean age within studies ranged from 54 to 70 years. A total of 1,973 vessels were included in the current meta-analysis. Each study used at least 64-slice multidetector CT or dual-source CT scanners. Three articles did not report per-patient diagnostic performance of MPI (9,11,16). Per-vessel results of coronary CTA and the hybrid approach were available in only 8 articles (6,9-12,14-16), and per-vessel results of MPI were reported in only 6 articles (6,10,12,14-16).



QUALITY ASSESSMENT AND PUBLICATION BIAS. The methodological quality of the included studies as assessed by the QUADAS-2 score was generally good, although the quality for flow and timing was substantially poor, thus indicating a potential risk of introduced bias (Figure 2). A summary of the QUADAS-2 quality scores for each study is shown in Table 2. Using Deeks’ test, there was no evidence of publication bias on both a per-patient level and a per-vessel level when using the hybrid and stand-alone coronary CTA approaches ($p > 0.05$ for all) (Online Figures 1A and 1B).

DIAGNOSTIC PERFORMANCE OF CORONARY CTA AND MPI FOR ASSESSMENT OF OBSTRUCTIVE CAD. At the per-patient level, coronary CTA and MPI displayed comparable sensitivity ($p = 0.35$) (Table 3). However, coronary CTA showed lower specificity (66%) for predicting obstructive CAD compared with MPI (83%) ($p < 0.001$). At the per-vessel level, coronary CTA exhibited somewhat improved specificity, and results were similar compared with the MPI approach ($p = 0.02$) (Table 3). Sensitivity was higher for stand-alone coronary CTA (89%) at the per-vessel level when compared with MPI alone (78%) ($p < 0.001$). On both a per-patient level and a per-vessel level, sROC curves indicated that the

discriminatory power did not differ statistically between coronary CTA and MPI approaches (p value for difference > 0.05) (Figures 3A and 3B).

DIAGNOSTIC PERFORMANCE OF HYBRID AND CORONARY CTA IMAGING METHODS FOR ASSESSMENT OF OBSTRUCTIVE CAD. Pooled estimates of per-patient and per-vessel sensitivity, specificity, positive likelihood ratio (LR^+), negative likelihood ratio (LR^-), and

TABLE 2 Quality Assessment of the Studies Included in the Meta-Analysis Using the QUADAS-2 Tool

First Author, Year (Ref. #)	Risk of Bias				Applicability Concerns		
	Patient Selection	Index Test	Reference Standard	Flow And Timing	Patient Selection	Index Test	Reference Standard
Thomassen, 2013 (6)	Low	Low	Low	Low	Low	Low	Low
Groothuis, 2013 (7)	Low	Low	Low	High	Low	Low	Low
Schaap, 2013 (8)	Low	Low	Low	High	Low	Low	Low
Li, 2013 (9)	Low	Low	Low	Low	Low	Low	Low
Danad, 2013 (10)	Low	Low	Low	Low	High	Low	Low
Kadokami, 2012 (11)	Low	Low	Low	Low	Low	Low	Low
Kajander, 2010 (12)	Low	Low	Low	Low	Low	Low	Low
Winther, 2015 (13)	High	Low	Low	High	High	Low	Low
Scheffel, 2010 (14)	Low	Low	Low	Low	Low	Low	Low
Donati, 2010 (15)	Low	Low	Low	High	Low	Low	Low
Sato, 2010 (16)	Low	Low	Low	Low	Low	Low	Low
Groves, 2009 (2)	Low	Low	Low	Unclear	Low	Low	Low

TABLE 3 Meta-Analysis for the Diagnostic Performance of Coronary CTA Alone, MPI Alone, and Hybrid Cardiac Imaging

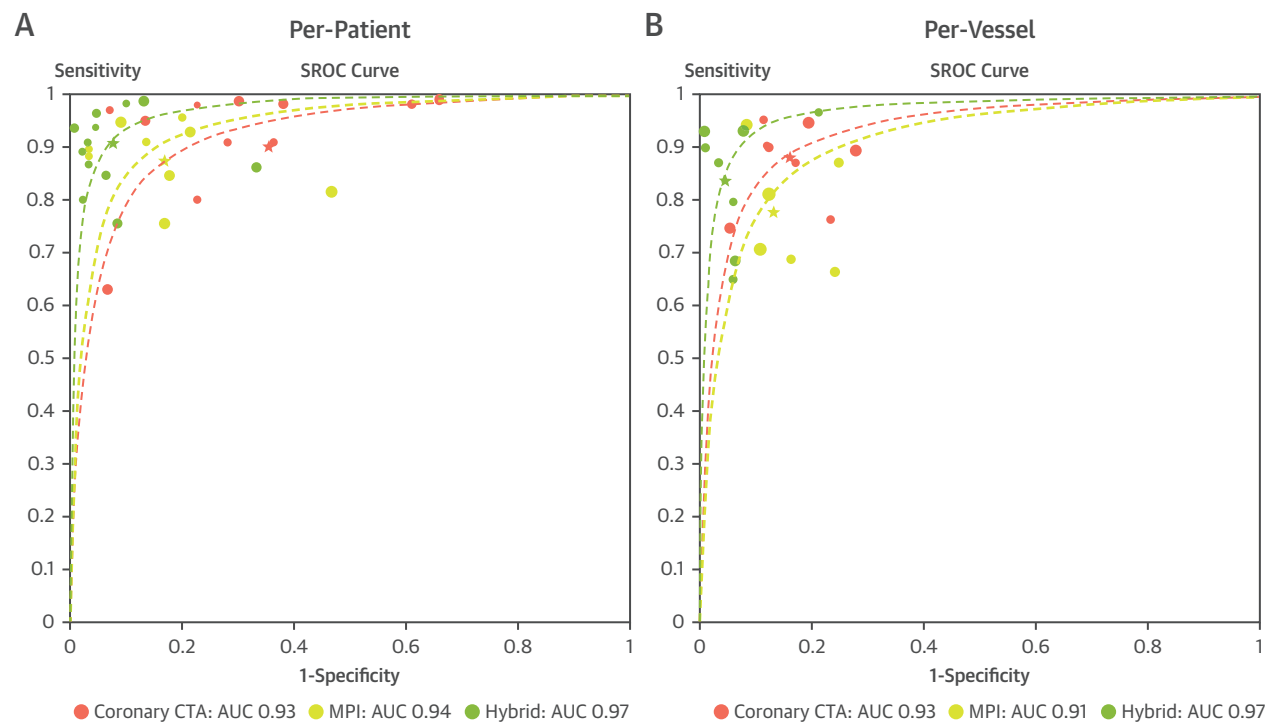
	N	Sensitivity (95% CI)	Specificity (95% CI)	Positive Likelihood Ratio (95% CI)	Negative Likelihood Ratio (95% CI)	Diagnostic Odds Ratio (95% CI)
Per-patient analysis						
Coronary CTA	12	0.90 (0.87-0.92)	0.66 (0.61-0.70)	3.39 (2.22-5.17)	0.06 (0.02-0.23)	53.80 (28.61-101.19)
MPI	9	0.87 (0.83-0.90)	0.83 (0.78-0.87)	5.02 (2.99-8.44)	0.15 (0.09-0.25)	39.55 (15.64-100.02)
Hybrid	12	0.91 (0.88-0.93)	0.93 (0.90-0.95)	12.80 (6.56-24.96)	0.11 (0.07-0.18)	159.00 (57.42-440.25)
Per-vessel analysis						
Coronary CTA	8	0.89 (0.86-0.91)	0.83 (0.81-0.85)	5.75 (4.00-8.26)	0.14 (0.09-0.22)	44.27 (25.39-77.20)
MPI	6	0.78 (0.74-0.81)	0.87 (0.84-0.89)	5.24 (3.52-7.82)	0.25 (0.16-0.39)	22.59 (10.41-49.03)
Hybrid	8	0.84 (0.81-0.87)	0.95 (0.94-0.96)	16.53 (9.14-29.90)	0.14 (0.07-0.26)	137.90 (53.93-352.66)

CI = confidence interval; CTA = computed tomography angiography; hybrid = hybrid cardiac imaging encompassing single-photon emission computed tomography, positron emission tomography, and cardiac magnetic resonance; MPI = myocardial perfusion imaging.

DOR according to coronary CTA, MPI, and hybrid approaches are reported in [Table 3](#). Forest plots for sensitivity and specificity on a per-patient level are reported in [Online Figure 2](#). On a per-patient level, sensitivity, LR⁻, and DOR of hybrid versus coronary CTA imaging techniques to detect obstructive CAD were 91%, 0.11, and 159.00, versus 90%, 0.06, and

53.80, respectively ($p > 0.05$ for all). Hybrid imaging displayed a higher specificity (93%) and LR⁺ (12.80) when compared with stand-alone coronary CTA (66% and 3.39; $p < 0.05$ for all). At the per-patient level, sROC curves revealed that the hybrid imaging approach did not exhibit a larger AUC value when compared with stand-alone coronary CTA (0.97 vs.

FIGURE 3 SROC Curves Displaying Diagnostic Performance of Hybrid Imaging Versus Stand-Alone Coronary CTA and MPI



(A) The p value difference at the per-patient level, coronary computed tomography angiography (CTA) versus hybrid, myocardial perfusion imaging (MPI) versus hybrid, and coronary computed tomography angiography versus myocardial perfusion imaging; all $p > 0.05$. (B) The p value difference at the per-vessel level, coronary computed tomography angiography versus hybrid $p = 0.046$, myocardial perfusion imaging versus hybrid and coronary computed tomography angiography versus myocardial perfusion imaging; both $p > 0.05$. AUC = area under the curve; sROC = summary receiver-operating characteristic.

TABLE 4 Meta-Analysis for the Diagnostic Performance of Various Hybrid Cardiac Imaging Modalities

	N	Sensitivity (95% CI)	Specificity (95% CI)	Positive Likelihood Ratio (95% CI)	Negative Likelihood Ratio (95% CI)	Diagnostic Odds Ratio (95% CI)
Per-patient analysis						
SPECT/coronary CTA	5	0.92 (0.88-0.95)	0.90 (0.85-0.93)	10.38 (3.60-29.94)	0.08 (0.03-0.27)	158.16 (21.11-1185.00)
PET/coronary CTA	4	0.87 (0.80-0.92)	0.96 (0.92-0.99)	22.12 (5.20-94.00)	0.12 (0.05-0.29)	213.68 (25.94-1760.10)
CMR/coronary CTA	3	0.91 (0.83-0.96)	0.94 (0.88-0.98)	12.86 (5.90-28.02)	0.13 (0.07-0.26)	120.36 (35.42-408.98)
Per-vessel analysis						
SPECT/coronary CTA	3	0.91 (0.86-0.95)	0.95 (0.93-0.96)	18.51 (8.01-42.76)	0.11 (0.05-0.24)	174.33 (52.59-577.89)
PET/coronary CTA	3	0.81 (0.75-0.86)	0.97 (0.95-0.98)	28.42 (7.68-105.17)	0.15 (0.04-0.51)	202.03 (19.51-2091.8)
CMR/coronary CTA	2	0.80 (0.73-0.87)	0.87 (0.79-0.92)	6.37 (2.69-15.07)	0.13 (0.01-2.07)	53.95 (13.48-215.83)

CMR = cardiac magnetic resonance; PET = positron emission tomography; SPECT = single-photon emission computed tomography; other abbreviations as in Table 3.

0.93, respectively; p value for difference = 0.132) (Figure 3A).

Forest plots for sensitivity and specificity on a per-vessel level are reported in Online Figure 3. On a per-vessel level, specificity (95%) and LR⁺ (16.53) were higher for the hybrid approach when compared with stand-alone coronary CTA (specificity: 83% and LR⁺: 5.75; p < 0.05 for all) (Table 3). Moreover, on a per-vessel basis, sROC curves showed a statistically significant and higher AUC value for the hybrid approach when compared with stand-alone coronary CTA (0.97 vs. 0.93, respectively; p value for difference = 0.047) (Figure 3B).

The I² index test indicated significant heterogeneity for sensitivity and specificity on both a per-patient level and a per-vessel level (Online Figures 2 and 3, Online Table 1). On a per-patient level, significant heterogeneity for sensitivity and specificity was observed for coronary CTA (I² index: 89% and 88%, respectively; p < 0.001). On a per-vessel level, significant heterogeneity for specificity was observed for coronary CTA (I² index: 91%; p < 0.001). The hybrid approach showed significant heterogeneity for sensitivity and specificity on a per-vessel level (I² index: 88% and 87%, respectively; p < 0.001) (Online Figures 2 and 3, Online Table 1).

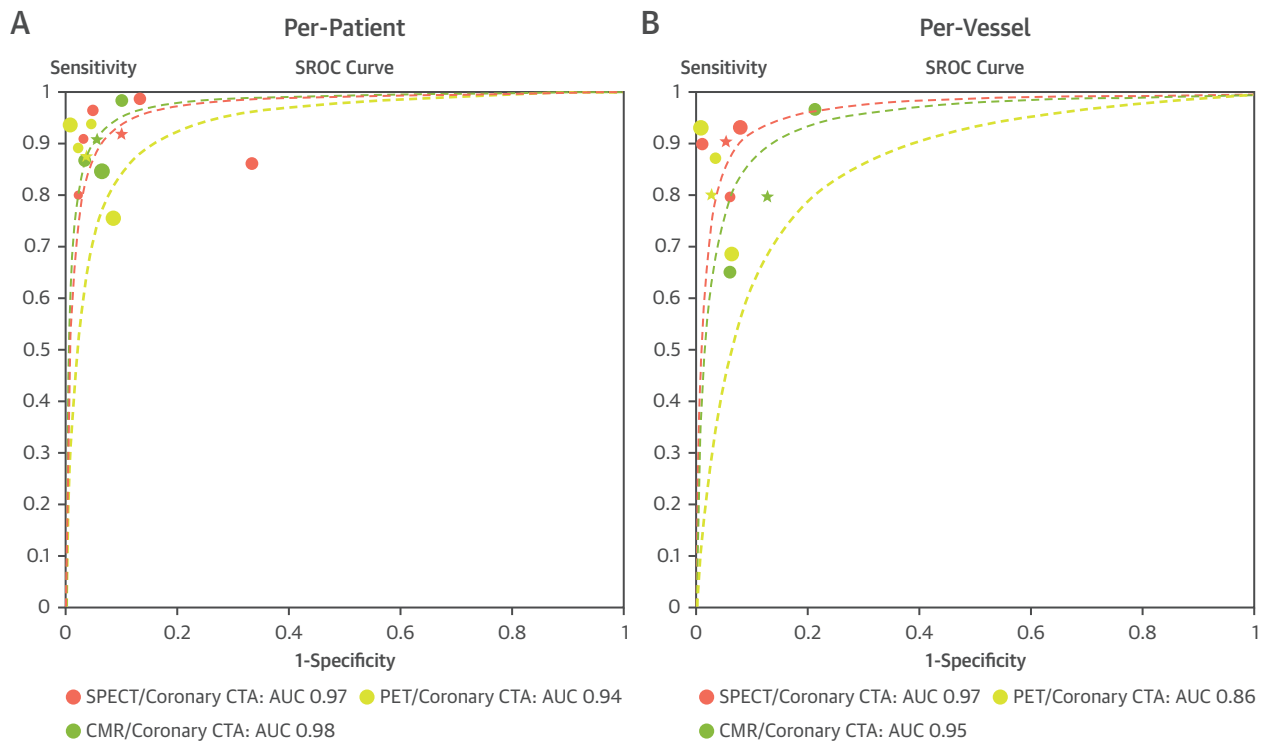
DIAGNOSTIC PERFORMANCE OF HYBRID SPECT AND CORONARY CTA, PET AND CORONARY CTA, AND CMR AND CORONARY CTA IMAGING MODALITIES FOR ASSESSMENT OF OBSTRUCTIVE CAD. Overall, hybrid SPECT and coronary CTA demonstrated the highest sensitivity at both a per-patient level (92%) and a per-vessel level (91%) for assessment of obstructive CAD as compared with PET and coronary CTA (87% and 81%, respectively; p < 0.05 for all) (Table 4). However, specificity was higher for PET and coronary CTA as compared with SPECT and coronary CTA. The specificity for PET and coronary CTA was 96% at the per-patient level and 97% at the

per-vessel level, as compared with SPECT and coronary CTA (90% and 95%, respectively; p < 0.05 for all). Despite this finding, there were no differences in the sROC curves among the various hybrid imaging modalities on either a per-patient level or a per-vessel level (p values for difference >0.05 for all) (Figures 4A and 4B).

DISCUSSION

In the current meta-analysis, we investigated the diagnostic performance of hybrid MPI and coronary CTA cardiac imaging compared with stand-alone coronary CTA for identifying obstructive CAD in patients who underwent both anatomic and functional testing. Overall, hybrid imaging techniques outperformed stand-alone coronary CTA with superior specificity and LR⁺. Moreover, at a per-vessel level, hybrid versus stand-alone coronary CTA imaging demonstrated improved discrimination on the basis of sROC curves for identifying obstructive CAD.

The current meta-analysis revealed that, at a per-patient level, even though pooled sensitivity was comparable for hybrid cardiac imaging modalities versus stand-alone coronary CTA, pooled specificity and LR⁺ were considerably higher for hybrid imaging as compared with stand-alone coronary CTA. Although the sROC curves demonstrated a trend toward improved discrimination for hybrid imaging for identifying obstructive CAD as compared with stand-alone coronary CTA, the difference was not statistically significant, most likely because of the relatively low per-patient sample size. Similarly, at a per-vessel level, pooled sensitivity was comparable for hybrid versus stand-alone coronary CTA imaging. However, both pooled specificity and LR⁺ were appreciably higher for hybrid versus stand-alone coronary CTA imaging at a per-vessel level. Similarly, at a per-vessel level, sROC curves for the hybrid

FIGURE 4 SROC Curves Displaying the Diagnostic Performance of Hybrid Imaging

The p value difference at **(A)** the per-patient level and **(B)** the per-vessel level, single-photon emission computed tomography (SPECT)/coronary computed tomography angiography (CTA) versus positron emission tomography (PET)/coronary computed tomography angiography, positron emission tomography/coronary computed tomography angiography versus cardiac magnetic resonance (CMR)/coronary computed tomography angiography, and single-photon emission computed tomography/coronary computed tomography angiography versus cardiac magnetic resonance/coronary computed tomography angiography; all $p > 0.05$. Abbreviations as in [Figure 3](#).

imaging approach displayed a significantly higher discriminatory ability for detecting CAD when compared with the stand-alone coronary CTA approach.

Previous individual studies showed that hybrid cardiac imaging techniques have yielded superior diagnostic performance for detecting obstructive CAD, along with additional information regarding hemodynamically significant coronary lesions, when compared with results of stand-alone coronary CTA (9-12,23). The largest study included in this meta-analysis demonstrated that hybrid imaging significantly improved specificity and overall accuracy (95% and 91%, respectively) for the detection of obstructive CAD compared with coronary CTA alone (39% and 57%, respectively; $p < 0.001$) (7). Although we did not evaluate clinical outcomes in this study, our overall findings are also in keeping with seminal data from invasive studies such as the multicenter FAME (Fractional Flow Reserve Versus Angiography

for Multivessel Evaluation) study, which demonstrated that simultaneous assessment of anatomic and physiological coronary lesions by ICA and fractional flow reserve (FFR) resulted in improved clinical outcomes over anatomic analysis alone (24). The current meta-analysis represents a systematic aggregation of hybrid noninvasive cardiac imaging using MPI and coronary CTA. It extends the findings of smaller studies, which may be limited by factors such as small sample size or single-center design, and it broadens generalizability.

The diagnostic performance of stand-alone coronary CTA is impeded by suboptimal image quality in cases with motion artifacts or heavy calcification. Indeed, previous data demonstrated a relatively low PPV of coronary CTA in the evaluation of CAD (25). These findings are of practical clinical importance because they can lead to increased downstream testing and unnecessary invasive procedures such as ICA. ICA assessment carries an associated risk of

complications and therapeutic interventions of nonischemic coronary artery lesions, particularly in patients with a low to intermediate pre-test likelihood of CAD (26,27). Stress MPI incorporating SPECT, PET, and CMR provides additive diagnostic benefit by assessment of the functional significance of coronary artery stenoses. In pooled analyses, the sensitivity and specificity of MPI to diagnose obstructive CAD is typically between 85% to 90% and 70% to 75%, respectively (28-30). However, despite the high reported diagnostic performance of MPI, its real-world accuracy is less sanguine. When corrected for referral bias (more positive studies undergo the gold standard test), the sensitivity and specificity for identifying individuals with obstructive CAD are approximately 65% and 67%, respectively (31). Numerous potential explanations exist to account for these findings, including patient motion artifacts, variable techniques for attenuation correction, true MPI abnormalities such as diffuse atherosclerosis, and variation by sites.

Given the aforementioned limitations of coronary CTA and MPI individually, hybrid imaging holds appeal as an efficient diagnostic strategy in the work-up of suspected CAD. In fact, the current consensus recommendation of the Society of Cardiac Computed Tomography and the American College of Radiology on coronary CTA reporting, the Coronary Artery Disease Reporting and Data System (CAD-RADS), is that physicians “consider functional assessment” in patients with CAD-RADS category 3, or 50% to 69% stenosis (32). Although a cost-effectiveness analysis was outside the scope of the current study, routine implementation of a hybrid anatomic-functional approach would necessitate further study of its benefits, harms (including radiation doses), costs, and unintended consequences. Although the addition of a second imaging examination would be expected to increase upfront costs, it must be balanced by consideration of its effect on downstream testing and procedures. Limited data suggest that hybrid SPECT and coronary CTA are associated with optimal resource use and improved selection for ICA and revascularization (33). Recognizing that the economic burden of hybrid imaging could be a significant practical barrier to implementation, further study could also focus on populations in which it may be most clinically meaningful—in patients with intermediate stenosis or suspected microvascular dysfunction. In routine practice, a logical approach would be sequential testing after an initial equivocal test result (34) or when questions remain about the presence of microvascular dysfunction.

The clinical utility of a hybrid imaging strategy is further supported by the recent multicenter EVINCI (Evaluation of INtegrated Cardiac Imaging for the Detection and Characterization of Ischaemic Heart Disease) hybrid substudy (35). In this study of 252 patients with suspected CAD, nearly 20% of patients undergoing hybrid imaging had a perfusion defect on myocardial perfusion scintigraphy reassigned to a different coronary artery. Matched abnormal coronary CTA and myocardial perfusion scintigraphy perfusion findings were associated with a relatively high rate of revascularization as compared with mismatched or discordant findings, thus emphasizing the clinical value of hybrid imaging (35). Further study of the clinical utility of a hybrid anatomic-functional approach could also consider the addition of newer CT applications such as noninvasive FFR derived by cardiac CT (FFR_{CT}) or atherosclerotic plaque features that could be performed without additional imaging requirements. In routine clinical practice, however, access issues and financial barriers remain around FFR_{CT}.

STUDY LIMITATIONS. Understanding which particular method of hybrid cardiac imaging may provide the highest diagnostic performance for the assessment of obstructive CAD was beyond the scope of this study, given the limited number of studies included in this analysis. Hence whether stand-alone coronary CTA provides improved diagnostic performance in combination with SPECT, PET, or CMR could not be adequately assessed on the basis of the current study findings. Although specificity was highest for PET and coronary CTA when compared with SPECT and coronary CTA or CMR and coronary CTA on both per-patient and per-vessel levels, the sROC curves displayed the lowest discriminatory ability for PET and coronary CTA against other hybrid modalities for identifying obstructive CAD, with a statistically nonsignificant p value for difference. Data from additional studies may elucidate the role of various imaging methods for detecting obstructive CAD (36).

The reference standard was not invasive FFR because not all pooled studies in this investigation used FFR as the reference standard. Consequently, given the paucity of available data, QCA was used as the reference standard in the current meta-analysis. Despite an observed 3-fold difference in the DOR when using a hybrid imaging approach rather than coronary CTA alone for assessing obstructive CAD, caution should be taken when interpreting these findings in light of the relatively few studies that were available for this meta-analysis; this small number of studies was likely responsible for the relatively wide 95% CIs. The statistical

nonsignificance of the hybrid imaging approach versus stand-alone coronary CTA at the per-patient and per-vessel levels may be attributed to the issue that not all included studies used invasive FFR as the reference standard. Finally, there was substantially high heterogeneity for sensitivity and specificity among included studies. Furthermore, the source of heterogeneity was not identified in the current meta-analysis because of the limited number of studies across each imaging modality. Therefore, our overall conclusions are limited by high heterogeneity and should be interpreted with caution. Despite these limitations, efforts were made to select high-quality studies, and the current meta-analysis represents a synthesis of hybrid cardiac imaging. These findings warrant further validation in larger prospective studies.

CONCLUSIONS

The current meta-analysis suggests improved diagnostic specificity of hybrid cardiac imaging techniques for identifying obstructive CAD as compared with stand-alone coronary CTA. However, the improvement in overall diagnostic performance was relatively limited.

ADDRESS FOR CORRESPONDENCE: Dr. Jessica M. Peña, Weill Cornell Medicine and New York-Presbyterian Hospital, Dalio Institute of Cardiovascular Imaging, 413 East 69th Street, Suite 108, New York, New York 10021. E-mail: jmp2003@med.cornell.edu.

PERSPECTIVES

COMPETENCY IN MEDICAL KNOWLEDGE: In the current meta-analysis, hybrid cardiac imaging using coronary CTA and MPI demonstrated superior specificity compared with stand-alone coronary CTA for identifying obstructive CAD at both the per-patient and the per-vessel level. However, the sensitivity of a hybrid cardiac imaging approach was comparable to that of stand-alone coronary CTA.

TRANSLATIONAL OUTLOOK: Additional studies are needed to determine the utility of hybrid cardiac imaging in situations where it could prove most clinically useful and its cost-effectiveness, as well as which particular combinations of MPI and coronary CTA have the most favorable diagnostic performance.

REFERENCES

- Min JK, Shaw LJ, Berman DS. The present state of coronary computed tomography angiography a process in evolution. *J Am Coll Cardiol* 2010;55:957-65.
- Groves AM, Speechly-Dick ME, Kayani I, et al. First experience of combined cardiac PET/64-detector CT angiography with invasive angiographic validation. *Eur J Nucl Med Mol Imaging* 2009;36:2027-33.
- Meijboom WB, Meijs MF, Schuijf JD, et al. Diagnostic accuracy of 64-slice computed tomography coronary angiography: a prospective, multicenter, multivendor study. *J Am Coll Cardiol* 2008;52:2135-44.
- Meijboom WB, Van Mieghem CA, van Pelt N, et al. Comprehensive assessment of coronary artery stenoses: computed tomography coronary angiography versus conventional coronary angiography and correlation with fractional flow reserve in patients with stable angina. *J Am Coll Cardiol* 2008;52:636-43.
- Gaemperli O, Husmann L, Schepis T, et al. Coronary CT angiography and myocardial perfusion imaging to detect flow-limiting stenoses: a potential gatekeeper for coronary revascularization? *Eur Heart J* 2009;30:2921-9.
- Thomassen A, Petersen H, Diederichsen AC, et al. Hybrid CT angiography and quantitative 15O-water PET for assessment of coronary artery disease: comparison with quantitative coronary angiography. *Eur J Nucl Med Mol Imaging* 2013;40:1894-904.
- Groothuis JG, Beek AM, Brinckman SL, et al. Combined non-invasive functional and anatomical diagnostic work-up in clinical practice: the Magnetic Resonance and Computed Tomography in Suspected Coronary Artery Disease (MARCC) study. *Eur Heart J* 2013;34:1990-8.
- Schaap J, Kauling RM, Boekholdt SM, et al. Incremental diagnostic accuracy of hybrid SPECT/CT coronary angiography in a population with an intermediate to high pre-test likelihood of coronary artery disease. *Eur Heart J Cardiovasc Imaging* 2013;14:642-9.
- Li JM, Shi RF, Zhang LR, Li T, Dong Z. Combined CT angiography and SPECT myocardial perfusion imaging for the detection of functionally relevant coronary stenoses. *Mol Med Rep* 2013;7:1391-6.
- Danad I, Rajmakers PG, Appelman YE, et al. Hybrid imaging using quantitative H215O PET and CT-based coronary angiography for the detection of coronary artery disease. *J Nucl Med* 2013;54:55-63.
- Kadokami T, Ando S, Momii H, et al. Diagnostic performance of cardiac fusion images from myocardial perfusion imaging and multislice computed tomography coronary angiography for assessment of hemodynamically significant coronary artery lesions: an observational study. *Nucl Med Commun* 2012;33:60-8.
- Kajander S, Joutsiniemi E, Saraste M, et al. Cardiac positron emission tomography/computed tomography imaging accurately detects anatomically and functionally significant coronary artery disease. *Circulation* 2010;122:603-13.
- Winther S, Svensson M, Jorgensen HS, et al. Diagnostic performance of coronary CT angiography and myocardial perfusion imaging in kidney transplantation candidates. *J Am Coll Cardiol Img* 2015;8:553-62.
- Scheffel H, Stolzmann P, Alkadhi H, et al. Low-dose CT and cardiac MR for the diagnosis of coronary artery disease: accuracy of single and combined approaches. *Int J Cardiovasc Imaging* 2010;26:579-90.
- Donati OF, Scheffel H, Stolzmann P, et al. Combined cardiac CT and MRI for the comprehensive workup of hemodynamically relevant coronary stenoses. *AJR Am J Roentgenol* 2010;194:920-6.
- Sato A, Nozato T, Hikita H, et al. Incremental value of combining 64-slice computed tomography angiography with stress nuclear myocardial perfusion imaging to improve noninvasive detection of coronary artery disease. *J Nucl Cardiol* 2010;17:19-26.
- Whiting P, Rutjes AW, Reitsma JB, Bossuyt PM, Kleijnen J. The development of QUADAS: a tool for the quality assessment of studies of diagnostic accuracy included in systematic reviews. *BMC Med Res Methodol* 2003;3:25.

18. DerSimonian R, Laird N. Meta-analysis in clinical trials. *Control Clin Trials* 1986;7:177-88.
19. Moses LE, Shapiro D, Littenberg B. Combining independent studies of a diagnostic test into a summary ROC curve: data-analytic approaches and some additional considerations. *Stat Med* 1993;12:1293-316.
20. Deeks JJ, Macaskill P, Irwig L. The performance of tests of publication bias and other sample size effects in systematic reviews of diagnostic test accuracy was assessed. *J Clin Epidemiol* 2005;58:882-93.
21. Higgins JP, Thompson SG, Deeks JJ, Altman DG. Measuring inconsistency in meta-analyses. *BMJ* 2003;327:557-60.
22. Zamora J, Abraira V, Muriel A, Khan K, Coomarasamy A. Meta-DiSc: a software for meta-analysis of test accuracy data. *BMC Med Res Methodol* 2006;6:31.
23. Rispler S, Keidar Z, Ghersin E, et al. Integrated single-photon emission computed tomography and computed tomography coronary angiography for the assessment of hemodynamically significant coronary artery lesions. *J Am Coll Cardiol* 2007;49:1059-67.
24. Tonino PA, De Bruyne B, Pijls NH, et al. Fractional flow reserve versus angiography for guiding percutaneous coronary intervention. *N Engl J Med* 2009;360:213-24.
25. Mollet NR, Cademartiri F, van Mieghem CA, et al. High-resolution spiral computed tomography coronary angiography in patients referred for diagnostic conventional coronary angiography. *Circulation* 2005;112:2318-23.
26. Redberg RF, Walsh J. Pay now, benefits may follow: the case of cardiac computed tomographic angiography. *N Engl J Med* 2008;359:2309-11.
27. Nielsen LH, Ortner N, Norgaard BL, Achenbach S, Leipsic J, Abdulla J. The diagnostic accuracy and outcomes after coronary computed tomography angiography vs. conventional functional testing in patients with stable angina pectoris: a systematic review and meta-analysis. *Eur Heart J Cardiovasc Imaging* 2014;15:961-71.
28. Klocke FJ, Baird MG, Lorell BH, et al. ACC/AHA/ASNC guidelines for the clinical use of cardiac radionuclide imaging—executive summary: a report of the American College of Cardiology/American Heart Association Task Force on Practice Guidelines (ACC/AHA/ASNC Committee to Revise the 1995 Guidelines for the Clinical Use of Cardiac Radionuclide Imaging). *J Am Coll Cardiol* 2003;42:1318-33.
29. Kim C, Kwok YS, Heagerty P, Redberg R. Pharmacologic stress testing for coronary disease diagnosis: A meta-analysis. *Am Heart J* 2001;142:934-44.
30. Fleischmann KE, Hunink MG, Kuntz KM, Douglas PS. Exercise echocardiography or exercise SPECT imaging? A meta-analysis of diagnostic test performance. *J Nucl Cardiol* 2002;9:133-4.
31. Miller TD, Hodge DO, Christian TF, Milavetz JJ, Bailey KR, Gibbons RJ. Effects of adjustment for referral bias on the sensitivity and specificity of single photon emission computed tomography for the diagnosis of coronary artery disease. *Am J Med* 2002;112:290-7.
32. Cury RC, Abbara S, Achenbach S, et al. CAD-RADS: Coronary Artery Disease-Reporting and Data System: an expert consensus document of the Society of Cardiovascular Computed Tomography (SCCT), the American College of Radiology (ACR) and the North American Society for Cardiovascular Imaging (NASCI). Endorsed by the American College of Cardiology. *J Am Coll Radiol* 2016;13:1458-66.e9.
33. Pazhenkottil AP, Nkoulou RN, Ghadri JR, et al. Prognostic value of cardiac hybrid imaging integrating single-photon emission computed tomography with coronary computed tomography angiography. *Eur Heart J* 2011;32:1465-71.
34. Kaufmann PA, Buechel RR. Cardiac SPECT/CCTA hybrid imaging: one answer to two questions? *Herz* 2016;41:391-7.
35. Liga R, Vontobel J, Rovai D, et al. Multicentre multi-device hybrid imaging study of coronary artery disease: results from the Evaluation of Integrated Cardiac Imaging for the Detection and Characterization of Ischaemic Heart Disease (EVINCI) hybrid imaging population. *Eur Heart J Cardiovasc Imaging* 2016;17:951-60.
36. VU University Medical Center. Prospective Comparison of Cardiac PET/CT, SPECT/CT Perfusion Imaging and CT Coronary Angiography With Invasive Coronary Angiography. Available at: <http://clinicaltrials.gov/show/NCT01521468>. Accessed January 5, 2017.

KEY WORDS coronary artery disease, coronary computed tomography angiography, myocardial perfusion imaging

APPENDIX For a supplemental table and figures, please see the online version of this paper.