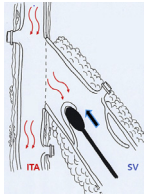


The authors reported no conflicts of interest.

The *Journal* policy requires editors and reviewers to disclose conflicts of interest and to decline handling or reviewing manuscripts for which they may have a conflict of interest. The editors and reviewers of this article have no conflicts of interest.



### REPLY FROM AUTHORS: AN OPEN-AND-SHUT CASE FOR SAPHEOUS VEIN VALVES: GOOD IN LOWER LIMBS BUT BAD IN CONDUITS

#### Reply to the Editor:

I thank Lobo Filho and associates<sup>1</sup> for their interest in our study demonstrating equivalent 10-year graft patency and long-term clinical results between saphenous vein (SV) composite grafts and arterial composite grafts.<sup>2</sup> In addition, I would like to commend them for their dedicated work for the past 30 years on arteriovenous composite Y grafts.

SV graft disease after myocardial revascularization results from complex pathophysiologic processes. The presence of a venous valve may be a cause of vein graft failure.<sup>3-5</sup> In our study, the SV was harvested with a no-touch technique without surrounding pedicle tissue, and the SV valves were destroyed after construction of a composite graft.<sup>2</sup> We assumed that leaving the SV valve intact might cause blood stagnation between the sequential distal anastomoses in the event of flow competition and result in early graft failure.

Although SV valves are fundamental elements that prevent blood regurgitation and stasis in the venous system of lower limbs, the presence of a valve in an SV graft may have an adverse effect on the graft function. The development of stasis, flow disturbance, and pressure trap in the SV segment distal to the valve may cause vein atherosclerosis.<sup>3,4</sup> In a previous study that examined 60 great SVs from 30 adult cadavers, the great SV had 2 to 9 valves commonly located below the tributaries.<sup>6</sup> However, it is difficult to evaluate SV valve sites preoperatively and locate a suitable length of valveless SV segment to use as a

conduit. We use preoperative ultrasound mapping as an aid in locating the needed length of SV with fewer tributaries.

In our study, the SV graft was dilated spontaneously by the native flow and pressure of the internal thoracic artery after the SV composite graft was constructed. We destroyed the SV valves by inserting a 2-mm round-edge vessel dilator, which was much smaller than the diameter of the dilated SV. Destruction of the valve may cause endothelial injury in the SV graft; however, we believe a gain with valve destruction is greater than losses without valve destruction. This minimized endothelial damage of the SV trunk into the reversed SV lumen, thus preventing blood stagnation in the event of flow competition. Factors such as a no-touch SV harvesting technique, the advantage of composite grafting based on the internal thoracic artery, and the destruction of valves in the SV composite graft may be reasons for improved long-term graft patency in our study.

Ki-Bong Kim, MD, PhD<sup>a</sup>

Min-Seok Kim, MD, PhD, MSc<sup>b</sup>

<sup>a</sup>Cardiovascular Center

Myongji Hospital

Goyang-si, Gyeonggi-do, Korea

<sup>b</sup>Department of Thoracic and Cardiovascular Surgery

Hanseo Hospital

Busan, Korea

### References

1. Lobo Filho HG, Lobo Filho JG, Pimentel MD. Left internal thoracic artery and saphenous vein composite grafts: the value of valveless veins. *J Thorac Cardiovasc Surg Open*. 2021;8:379.
2. Hwang HY, Lee Y, Sohn SH, Choi JW, Kim K-B. Equivalent 10-year angiographic and long-term clinical outcomes with saphenous vein composite grafts and arterial composite grafts. *J Thorac Cardiovasc Surg*. 2021;162:1535-43.e4.
3. Thubriker MJ, Robicsek F, Fowler BL. Pressure trap created by vein valve closure and its role in graft stenosis. *J Thorac Cardiovasc Surg*. 1994;107:707-16.
4. Chaux A, Ruan XM, Fishbein MC, Sandhu M, Matloff JM. Influence of vein valves in the development of arteriosclerosis in venoarterial grafts in the rabbit. *J Thorac Cardiovasc Surg*. 1995;110:1381-9.
5. Monsefi N, Zierer A, Honarpisheh G, Bauer R, Kerl M, Beiras-Fernandez A, et al. One-year patency of valvulotomized vein grafts is similar to that of arterial grafts. *Thorac Cardiovasc Surg*. 2016;64:204-10.
6. Portugal IBM, Ribeiro IL, de Sousa-Rodrigues CF, Monte-Bispo RF, da Rocha AC. Distribution of saphenous vein valves and its practical importance. *Rev Bras Cir Cardiovasc*. 2014;29:564-8.

<https://doi.org/10.1016/j.xjon.2021.09.014>