

Contents lists available at [ScienceDirect](https://www.sciencedirect.com)

## Gynecology and Minimally Invasive Therapy

journal homepage: [www.e-gmit.com](http://www.e-gmit.com)

Short communication

## Single-port laparoscopic neosalpingostomy for hydrosalpinx

Jin-Sung Yuk <sup>a</sup>, Kye Hyun Kim <sup>b</sup>, Ji Kwon Park <sup>a</sup>, Jung Hun Lee <sup>a,\*</sup><sup>a</sup> Department of Obstetrics and Gynecology, Gyeongsang National University Changwon Hospital, Gyeongsang National University School of Medicine, Changwon, Republic of Korea<sup>b</sup> The Department of Obstetrics and Gynecology, Kangbuk Samsung Hospital, Sungkyunkwan University School of Medicine, Seoul, Republic of Korea

## ARTICLE INFO

## Article history:

Received 4 September 2016

Received in revised form

22 February 2017

Accepted 7 March 2017

Available online 11 April 2017

## Keywords:

fimbrioplasty

hydrosalpinx

laparoscopy

neosalpingostomy

single-port surgery

## ABSTRACT

**Background:** To describe the surgical technique and our initial experience of single-port laparoscopic neosalpingostomy (SP-LN) for treatment of hydrosalpinx.**Materials and methods:** This prospective observational study was carried out at University teaching hospitals. Ten women underwent SP-LN for hydrosalpinx between November 2012 and December 2015.**Results:** The mean (range) age and body mass index were 29.3 (21–36) years and 22.2 (17.7–27.1) kg/m<sup>2</sup>, respectively. Six women had a history of previous abdominal surgery; laparoscopic unilateral salpingectomy for tubal pregnancy in two, laparoscopic appendectomy in three, and laparotomy appendectomy in one. Six women underwent unilateral SP-LN and nine women underwent bilateral SP-LN. The mean (range) operating time, hemoglobin change, return of bowel activity, and length of hospital stay were 91.5 (70–120) minutes, 0.7 (0.1–1.6) g/dL, 19.9 (7.1–25.4) hours, and 3.7 (3–4) days, respectively. There was no conversion to multiport laparoscopy or laparotomy. There were no surgical or wound complications in any patient.**Conclusion:** SP-LN might be a feasible and safe alternative in women with hydrosalpinx. However, further study is needed to confirm this preliminary result and to explore the obstetric outcomes following SP-LN.Copyright © 2017, The Asia-Pacific Association for Gynecologic Endoscopy and Minimally Invasive Therapy. Published by Elsevier Taiwan LLC. This is an open access article under the CC BY-NC-ND license (<http://creativecommons.org/licenses/by-nc-nd/4.0/>).

## Introduction

Since laparoscopic salpingostomy was introduced by Gomel <sup>1</sup> in 1977, this procedure has become a surgical method for hydrosalpinx in women who desire to preserve fertility and has been advocated due to its relatively short hospitalization time and low morbidity.<sup>2</sup>

In addition, with the development of laparoscopic instruments and surgical techniques, single-port laparoscopic surgery (SP-LS) has been reported in various gynecologic fields and is becoming increasingly popular due to its many advantages, such as shorter hospital stays, faster recovery times, better cosmetic outcomes, and fewer wound complications.<sup>3–7</sup>

Conflicts of interest: The authors have no conflicts of interest relevant to this article.

\*Corresponding author. Division of Gynecologic Oncology and Gynecologic Minimally Invasive Surgery Center, Department of Obstetrics and Gynecology, Gyeongsang National University Changwon Hospital, Gyeongsang National University School of Medicine, 11, Samjeongja-ro, Seongsan-gu, Changwon-si, Gyeongsangnam-do, 51472, Republic of Korea.

E-mail address: [leemjgm@gmail.com](mailto:leemjgm@gmail.com) (J.H. Lee).

However, to our knowledge, there is no report on the use of single-port laparoscopic neosalpingostomy (SP-LN) for hydrosalpinx. In this study, the surgical technique of and our initial experience with SP-LN are described.

## Materials and methods

This prospective observational study was performed from November 2012 to December 2015. Ten women underwent SP-LN. Our institutional review board approved this study, and written informed consent was obtained from each patient.

The inclusion criteria were premenopausal women seeking to preserve fertility and a diagnosis of hydrosalpinx based on hysterosalpingogram or ultrasonogram. The exclusion criteria were women with tubal occlusion observed at chromopertubation or with hydrosalpinx not observed during the operation.

The operative time was defined as the time elapsed from skin incision to closure; the return of bowel activity was defined as the time elapsed from the end of anesthesia to the first occurrence of bowel gas passage; and postoperative fever was defined as body

<http://dx.doi.org/10.1016/j.gmit.2017.03.002>

2213–3070/Copyright © 2017, The Asia-Pacific Association for Gynecologic Endoscopy and Minimally Invasive Therapy. Published by Elsevier Taiwan LLC. This is an open access article under the CC BY-NC-ND license (<http://creativecommons.org/licenses/by-nc-nd/4.0/>).

temperature  $\geq 38^{\circ}\text{C}$  on two consecutive occasions at least 6 hours apart, except during the first 24 hours after surgery.<sup>8</sup>

### Operative techniques

The patient was placed in a dorsal lithotomy position under general anesthesia. Patient preparation and the port placement system were established in the same manner as described in our previous reports.<sup>5–7</sup> The patient was then placed in an approximately  $30^{\circ}$  Trendelenburg position, and a uterine manipulator was inserted. First, an abdominopelvic examination was performed to assess the uterus, ovaries, and tubes for pelvic adhesions and other associated pathologies. If necessary, adhesiolysis was performed, and the distal portion of the tube was freed. An incision was made at the distal end of the tube using a needle electrocoagulator. Tubal patency was confirmed via laparoscopic indigo carmine chromo-peritubation. The tube was anchored to the anterior pelvic peritoneum using an EndoGrab retractor (Virtual Ports, Inc., Misgav, Israel). The edge of the distal tube was sutured to the serosal surface using 4-0 polyglactin (Vicryl; Ethicon Inc., Somerville, NJ, USA) to maintain eversion of the fimbria.

Following intra-abdominal irrigation, the adnexa was covered with an absorbable adhesion barrier (Interceed; Gynecare, Somerville, NJ, USA) after removing the EndoGrab retractor. Then, the incision was dressed with povidone–iodine and closed.

### Results

During the study period, 48 women were eligible for enrollment. Fifteen women from this group fulfilled both the inclusion and exclusion criteria and consented to undergo SP-LN. The detailed clinical characteristics and operative results are shown in Tables 1 and 2, respectively.

Six women underwent unilateral SP-LN for the following reasons: three had a contralateral patent tube, two had a previous contralateral salpingectomy due to a tubal pregnancy, and one had received simple adhesiolysis in the contralateral tube.

Postoperative fever was resolved by conservative management, and no other complications were observed. No conversion to multiport laparoscopy or laparotomy occurred.

### Discussion

Since 2000, investigations of SP-LS began in earnest, and the surgical techniques for SP-LS have been reported in various gynecological fields.<sup>4–7,9</sup> Although the use of SP-LS for gynecologic malignancies has been published previously, the lack of studies on SP-LN appear to be due to the following factors: (1) The incidence of hydrosalpinx is low, and neosalpingostomy is less widely used

**Table 1**  
Clinical characteristics.

	n (%) / mean (range)
No. of patients	15
Age (y)	29.3 (21–36)
Parity	0.1 (0–1)
Body mass index (kg/m <sup>2</sup> )	22.2 (17.7–27.1)
No. of women with previous abdominal surgeries	6 (40)
Laparoscopic unilateral salpingectomy for tubal pregnancy	2 (13)
Laparoscopic appendectomy	3 (20)
Laparotomic appendectomy	1 (7)

Data are presented as n (%) or means (ranges).

**Table 2**  
Operative outcomes (n = 15).

	n (%) / mean (range)
Operative time (min)	91.5 (70–120)
Hemoglobin change (g/dL)	0.7 (0.1–1.6)
Return of bowel activity (h)	19.9 (7.1–25.4)
Hospital stay (d)	3.7 (3–4)
Primary surgery	
Unilateral SP-laparoscopic neosalpingostomy	6 (40)
Bilateral SP-laparoscopic neosalpingostomy	9 (60)
Concomitant surgeries	
SP-laparoscopic myomectomy	1 (7)
SP-laparoscopic ovarian cystectomy	3 (20)
Conversion to multiport laparoscopy or laparotomy	0 (0)

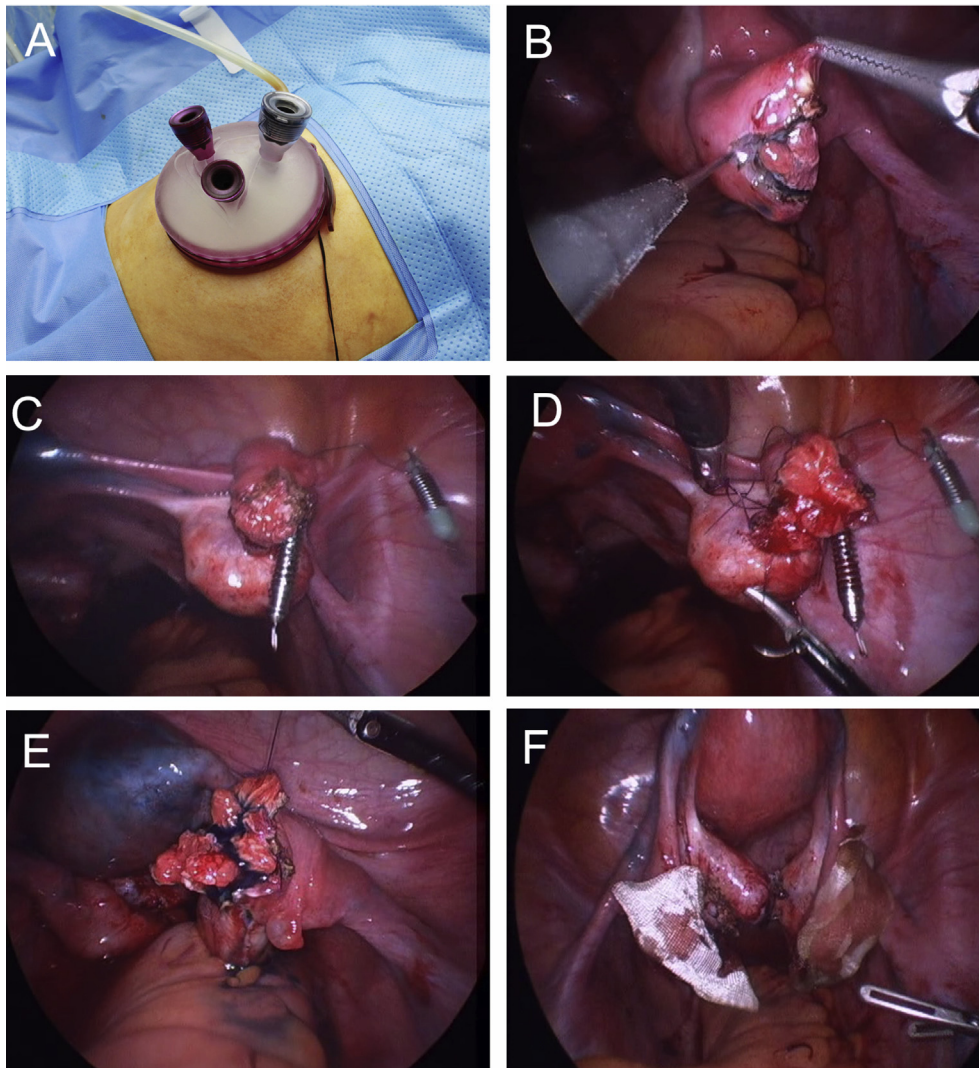
Data are presented as n (%) or means (ranges).

SD = standard deviation; SP = single port.

because of the development of assisted reproductive techniques.<sup>10</sup> (2) In contrast to most gynecologic surgeries, which are composed of destructive procedures, including excision and incision, neosalpingostomy requires meticulous adhesiolysis, incision, coagulation, and suturing. (3) SP-LS has inevitable technical constraints caused by space restriction, which limits the number of arms that can be used. Therefore, several novel methods were developed to overcome these problems.<sup>11</sup> The EndoGrab retractor and articulating laparoscopic instruments were found to be helpful for this procedure (Fig. 1C). In particular, the EndoGrab retractor permitted more comfortable suturing by anchoring the tube to the pelvic peritoneum. However, further improvements to new instruments for SP-LS and retractors that can obviate the need for the extra port are required for the complex steps of SP-LS because the currently available instruments are insufficient to overcome its drawbacks.

The mean operative time for multiport laparoscopic neosalpingostomy is 45–75 minutes<sup>12,13</sup>; thus, the mean operating time of SP-LN (91.5 minutes) was longer in this study. Previous authors have reported that SP-LS has a comparable operative time to single-port laparoscopically assisted vaginal hysterectomy, single-port laparoscopic myomectomy, and single-port laparoscopy for ectopic pregnancy.<sup>4,6,7</sup> Despite the technical difficulties and surgical space restrictions that inevitably occur with SP-LS, we believe that the reasons SP-LS does not require additional operative time compared with other surgeries are that SP-LS permits the rapid removal of specimens through a relatively large, transumbilical incision and that other surgeries do not require the meticulous operative techniques necessary for SP-LN. By contrast, the relatively longer operative time of SP-LN compared with multiport laparoscopic neosalpingostomy is believed to be caused by the fine suturing and adhesiolysis needed for neosalpingostomy, which further highlights the disadvantages of SP-LS. Additionally, the relatively large, transumbilical incision used for SP-LS does not reduce the operative time in SP-LN, which does not require specimen removal. However, instead of using fine sutures for everting the edges of the fimbrial ostium performed in the current study, the use of a CO<sub>2</sub> laser or bipolar coagulator for this step appears to be helpful for decreasing operative times.<sup>14,15</sup>

With respect to obstetric outcomes after neosalpingostomy, previous studies have reported that the overall intrauterine pregnancy and ectopic pregnancy rates following multiport laparoscopic neosalpingostomy were 2.7–42.7% and 0–16.5%, respectively.<sup>16,17</sup> We are unable to estimate the pregnancy rate after SP-LN because this preliminary study had only a small population and short follow-up. Additionally, predicting pregnancy in the participants included here is difficult because many factors, such as tubal wall pathology, tubal patency, eversion techniques, and



**Figure 1.** An image of single-port laparoscopic neosalpingostomy (SP-LN). (A) The GelPoint platform. (B) The incision is made at the distal end of the tube using a needle electrocoagulator. (C) The tube is anchored to the anterior pelvic peritoneum using the EndoGrab retractor (Virtual Ports, Inc., Misgav, Israel). (D) The edge of the distal tube is sutured to a serosal surface with 4-0 polyglactin to maintain eversion of the fimbria. (E) The tubal patency is confirmed via laparoscopic indigo carmine chromopertubation, and (F) following intraabdominal irrigation, the adnexa are covered with an absorbable adhesion barrier.

the surgeon's experience, affect the pregnancy rate following neosalpingostomy for hydrosalpinx.<sup>14</sup> However, we believe that the women who underwent SP-LN will have a comparable pregnancy rate to that of women who received multiport laparoscopic neosalpingostomy because the surgical techniques for SP-LN and multiport laparoscopic neosalpingostomy do not differ, except for the port placement system.

In addition, considering that relatively young, premenopausal women are candidates for neosalpingostomy for hydrosalpinx, SP-LN is believed to be an attractive alternative in women with hydrosalpinx due to its favorable cosmetic effects.<sup>3</sup>

In conclusion, SP-LN may be a feasible and safe alternative for women with hydrosalpinx. However, further research is needed to confirm this preliminary result and explore the obstetric outcomes following SP-LN.

#### Appendix A. Supplementary data

Supplementary data related to this article can be found at <http://dx.doi.org/10.1016/j.gmit.2017.03.002>.

#### References

- Gomel V. Salpingostomy by laparoscopy. *J Reprod Med.* 1977;18:265–268.
- Gomel V. Operative laparoscopy: time for acceptance. *Fertil Steril.* 1989;52:1–11.
- Eom JM, Ko JH, Choi JS, Hong JH, Lee JH. A comparative cross-sectional study on cosmetic outcomes after single port or conventional laparoscopic surgery. *Eur J Obstet Gynecol Reprod Biol.* 2013;167:104–109.
- Kim MK, Kim JJ, Choi JS, Eom JM, Lee JH. Prospective comparison of single port versus conventional laparoscopic surgery for ectopic pregnancy. *J Obstet Gynaecol Res.* 2014;41:590–595.
- Koh AR, Lee JH, Choi JS, Eom JM, Hong JH. Single-port laparoscopic appendectomy during pregnancy. *Surg Laparosc Endosc Percutan Tech.* 2012;22:e83–86.
- Lee JH, Choi JS, Jeon SW, Son CE, Hong JH, Bae JW. A prospective comparison of single-port laparoscopically assisted vaginal hysterectomy using transumbilical GelPort access and multiport laparoscopically assisted vaginal hysterectomy. *Eur J Obstet Gynecol Reprod Biol.* 2011;158:294–297.
- Lee JH, Choi JS, Jeon SW, Son CE, Lee SJ, Lee YS. Single-port laparoscopic myomectomy using transumbilical GelPort access. *Eur J Obstet Gynecol Reprod Biol.* 2010;153:81–84.
- Lyon D, Jones J, Sanchez A. Postoperative febrile morbidity in the benign gynecologic patient. Identification and management. *J Reprod Med.* 2000;45:305–309.
- Hahn HS, Kim YW. Single-port laparoscopic pelvic lymph node dissection with modified radical vaginal hysterectomy in cervical cancer. *Int J Gynecol Cancer.* 2010;20:1429–1432.

10. Trimbos JB, Trimbos-Kemper GC, Peters AA, van der Does CD, van Hall EV. Findings in 200 consecutive asymptomatic women, having a laparoscopic sterilization. *Arch Gynecol Obstet*. 1990;247:121–124.
11. Schlager A, Khalaileh A, Shussman N, et al. Providing more through less: current methods of retraction in SIMIS and NOTES cholecystectomy. *Surg Endosc*. 2010;24:1542–1546.
12. Shushan A, Mohamed H, Magos AL. How long does laparoscopic surgery really take? Lessons learned from 1000 operative laparoscopies. *Hum Reprod*. 1999;14:39–43.
13. Bellina JH. Microsurgery of the fallopian tube with the carbon dioxide laser: analysis of 230 cases with a two-year follow-up. *Lasers Surg Med*. 1983;3:255–260.
14. Sasse VV, Karageorgieva E, Keckstein J. Laparoscopic treatment of distal tubal occlusion-reocclusion and pregnancy rate. *J Am Assoc Gynecol Laparosc*. 1994;1: S32.
15. Sadoul G, Beuret T, Algava G, Serpeau D. Distal tubal microsurgery using the CO<sub>2</sub> laser. Experimental study and analysis of a series of 95 cases. *J Gynecol Obstet Biol Reprod (Paris)*. 1984;13:947–956 [Article in French].
16. Ahmad G, Watson AJ, Metwally M. Laparoscopy or laparotomy for distal tubal surgery? A meta-analysis. *Human Fertil (Cambridge, England)*. 2007;10:43–47.
17. Taylor RC, Berkowitz J, McComb PF. Role of laparoscopic salpingostomy in the treatment of hydrosalpinx. *Fertil Steril*. 2001;75:594–600.