

# A Modified Weaver-Dunn Procedure with or without Chip Bone Graft for the Treatment of Acromioclavicular Joint Separation

## Abstract

**Background:** In spite of frequent injuries to the acromioclavicular (AC) joint, there is no consensus regarding optimal technique to be used. This cohort study evaluated the clinical results of a modified Weaver-Dunn procedure with or without chip bone graft for the treatment of AC joint separation retrospectively. **Materials and Methods:** 60 consecutive patients with AC joint separation, between the age of 19-76 years (mean age 43 years), were enrolled between January 2005 and September 2011. Forty patients (35 men, 5 women) were treated with a modified Weaver-Dunn procedure, and did not receive bone graft during the procedure (Group 1), whereas twenty patients (19 men, 1 woman) received autogenous chip bone graft (Group 2). Stability of the AC joint was evaluated clinically and radiographically, and the clinical results were assessed by the Imatani evaluation system. **Results:** The mean duration of followup was 2 years and 2 months. The results were excellent in all patients except one. At final followup, roentgenographic measurement revealed that the mean coracoclavicular interval was 8.2 mm on the affected side, and 8.9 mm on the unaffected side in Group 1, and 9.5 mm on the affected side and 10.1 mm on the unaffected side in Group 2. For Group 1, there were significant differences between augmentation of the grafted coracoacromial (CA) ligament antero-posteriorly and laterally (Option B) and repair of the torn AC ligament with augmentation of the grafted CA ligament antero-inferiorly (option A;  $P = 0.0351$ ). **Conclusions:** The modified Weaver-Dunn procedure (Group 1 and 2) provides a stable and strong reconstruction for the treatment of AC joint separation. In addition, this modified Weaver-Dunn procedure with chip bone graft (Group 2) may lead to same or more secure healing of the grafted CA ligament-bone than the same procedure without chip bone graft ( $P = 0.9737$ ).

**Keywords:** Acromioclavicular joint, autogenous chip bone graft, modified Weaver-Dunn procedure, separation

Tae-Soo Park,  
Hyung Bin Park<sup>1</sup>

Department of Orthopaedic Surgery, College of Medicine, Hanyang University, Seoul, <sup>1</sup>Department of Orthopaedic Surgery, School of Medicine, Gyeongsang National University, Jinju, Korea

## Introduction

Previous studies have reported a high incidence of injury to the acromioclavicular (AC) joint,<sup>1-3</sup> but the treatment of AC joint injuries remains controversial, especially treatment in Rockwood Type III injuries.<sup>4</sup> Both static and dynamic structures are needed to maintain the stability of the AC joint.<sup>5-8</sup> Control of horizontal and vertical stability is provided by the AC and coracoclavicular (CC) ligaments, respectively.<sup>6,9</sup> If these ligaments are disrupted completely, the position of the scapular should be changed, which provokes scapular dyskinesia and impingement syndrome of the shoulder.<sup>10</sup> Hence, it comes to be difficult to move the shoulder girdle synchronously and coordinately. Active individuals, such as athletes who

participate in overhead throwing sports or heavy laborers, may not be able to recover their missions before AC joint injury. For these patients with residual symptoms after initial nonoperative treatment, surgery should be considered, even for patients with type III injuries. Although many operative procedures have been introduced, there is no consensus on which technique to use.

This study evaluates the clinical results of a modified Weaver-Dunn procedure with or without chip bone graft for the treatment of AC joint separation. We hypothesized that graft-bone healing was facilitated by autogenous chip bone graft, placed between the grafted coracoacromial (CA) ligament and the medullary canal of the resected distal end of the clavicle, and secure healing of the grafted CA ligament-bone contributed for stable reconstructed AC joint, especially in vertical stability, and augmentation of the CA ligament and/or

### Address for correspondence:

Prof. Hyung Bin Park,  
Department of Orthopaedic Surgery, Gyeongsang National University School of Medicine, Gyeongsang National University Changwon Hospital, 11 Samjeongja-ro Seongsan-gu, Changwon, Korea.  
E-mail: hbinpark@gnu.ac.kr

### Access this article online

Website: [www.ijoonline.com](http://www.ijoonline.com)

DOI:  
10.4103/ortho.IJOrtho\_394\_17

### Quick Response Code:



**How to cite this article:** Park TS, Park HB. A modified weaver-dunn procedure with or without chip bone graft for the treatment of acromioclavicular joint separation. Indian J Orthop 2019;53:111-6.

This is an open access journal, and articles are distributed under the terms of the Creative Commons Attribution-NonCommercial-ShareAlike 4.0 License, which allows others to remix, tweak, and build upon the work non-commercially, as long as appropriate credit is given and the new creations are licensed under the identical terms.

For reprints contact: [reprints@medknow.com](mailto:reprints@medknow.com)

repair of the torn AC ligament contributed the key role for stable AC joint in both vertical and horizontal planes.

## Materials and Methods

60 consecutive patients with AC joint separation treated with the modified Weaver-Dunn procedures were enrolled between January 2005 and September 2011. The patients included 54 men and 6 women with a mean age of 43 years (range 19–76 years). Twenty six patients had an AC joint injury on the dominant side, and 34 patients, on the non-dominant side. There were 15 cases of chronic type III injury (25%), and 45 cases of type V injury (75%). The surgical indications were medically-fit patients with Type IV, V, VI injuries and some chronic Type III injury. The surgical indications for Type III injury were as follows: persistent symptoms for more than 6 months, including pain, weakness, posterior instability with abutment between the posterior clavicle and the anterior scapular spine, and difficulty moving the arm into a cocking position while throwing. The mean age of the patients with Type III injuries was 35 years (range 19–46 years). Among them, 40 consecutive patients, 35 men and 5 women, did not receive bone graft during the procedure (Group 1), and 20 consecutive patients, 19 men and 1 woman, received autogenous chip bone graft (Group 2). There were no specific indications for additional chip bone graft, so the patients in Group 2 were selected as random sampling. The exclusion criteria were revision cases of failed AC joint separation, who already received the Weaver-Dunn procedure.

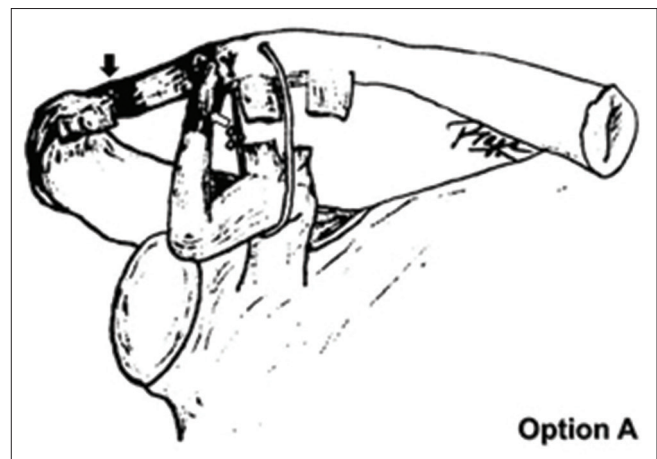
This study received approval from the Institutional Review Board at the first author's institution.

## Operative procedure

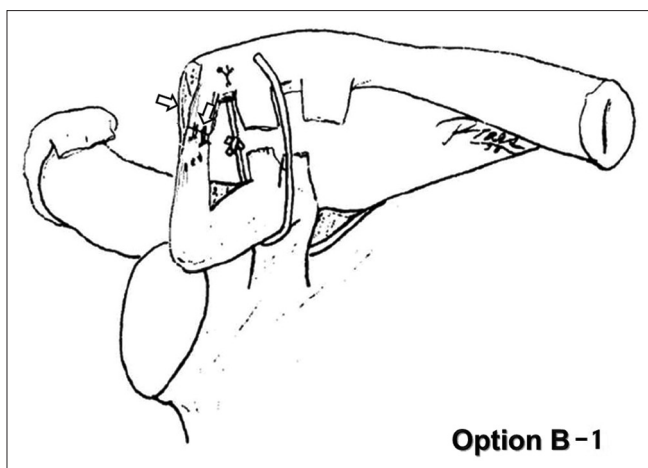
Under the general anesthesia, the patient was placed in the beach chair position. A 2–3cm curvilinear skin incision was made under the lateral AC joint and lateral to tip of the coracoid process. After the acromion and distal clavicle were exposed, the subperiosteal flaps were raised from the distal 15–20 mm of the clavicle. The remnant of the AC ligament, joint capsule, and periosteum of the medial aspect of the acromion and distal clavicle were dissected and carefully preserved. The soft tissues attached to the distal clavicle were divided into two flaps. The meniscal remnant and approximately 3–5 mm of distal clavicle were removed, with care taken to preserve the adjacent soft-tissue attachments to the clavicle and acromion. The CA ligament was mobilized from the acromion with #2 Ethibond; two to three modified Kessler sutures were passed through the free cut end. Mersilene tape (5 mm wide) was passed around the coracoid process in the medial to lateral direction behind the coracoid attachment of the CA ligament. Two small drill holes were made in the dorsal surface of the cut end of the clavicle. Through these holes, the Kessler sutures in the CA ligament were passed and tied firmly onto the cut end of

the clavicle while it was held reduced. The Mersilene tape was then passed through a separate drill hole in the clavicle and tied firmly to hold the clavicle in a little bit over-reduced position than the uninjured site. Care was taken to keep the tension balanced between the grafted CA ligament and the Mersilene tape during tying. If the length of the supero-posterior flap of the AC ligament was adequate, this portion was sutured to the remnants of the torn AC ligament attached to the medial aspect of the acromion, and the CA ligament was then augmented by the antero-inferior flap of the AC ligament antero-inferiorly [option A, Figure 1]. If the length of the supero-posterior flap of the AC ligament was inadequate [option B], the CA ligament was only augmented by the supero-posterior and antero-inferior flaps of the AC ligament attached to the cortices of the remaining clavicle antero-posteriorly [option B-1, Figure 2],<sup>11</sup> and/or by remnant of the torn AC ligament attached to the acromion laterally [option B-2, Figure 3]. Of the forty patients in Group 1, 31 were treated with option A, and 9, with option B, including option B-1 and B-2. Of the twenty patients in Group 2, 14 were treated with option A, and 6, with option B. In Group 1 and 2, option B contained both option B-1 and option B-2, and their clinical and radiological evaluations were checked together, because function of the AC joint is not so complex as to that of the glenohumeral joint [Table 1].

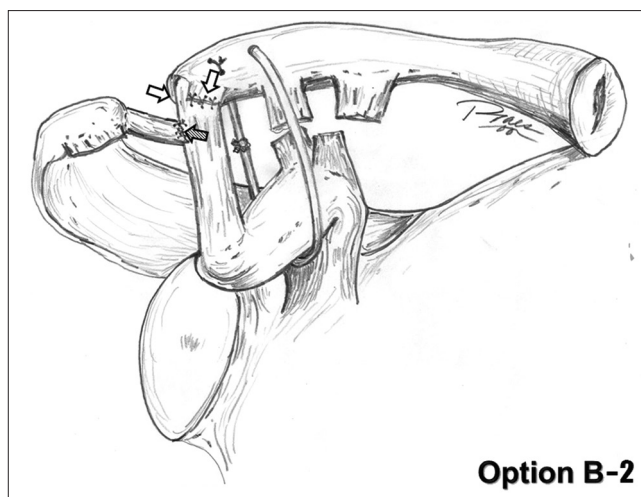
Twenty patients in Group 2 received autogenous chip bone graft in addition to option A or option B procedure. The chip bone graft was obtained from the resected distal clavicle and placed between the grafted CA ligament and the medullary canal of the resected distal end of the clavicle [Figure 4]. In Group 1, there were 12 patients with Type III injury and 28 with Type V injury; in Group 2, there were three patients with Type III injury and 17 with Type V injury.



**Figure 1:** If the length of the superoposterior flap of the acromioclavicular ligament was adequate, this portion was sutured to the remnants of the torn acromioclavicular ligament attached to the medial aspect of the acromion (black arrow). Anteromedially and posteriorly, the coracoclavicular ligament was augmented by the antero-inferior flap of the acromioclavicular ligament (white arrow). (Reprinted with permission of Park TS, Kim YH: Modification of the Weaver-Dunn procedure. *International Orthopaedics*. 23, 113, 1999)



**Figure 2:** If the length of the superoposterior flap of the acromioclavicular ligament was inadequate, the coracoacromial ligament was augmented by the superoposterior and anteroinferior flaps of the acromioclavicular ligament attached to the cortices of the remaining clavicle (white arrow). (Reprinted with permission of Park TS, Kim YH: Modification of the Weaver-Dunn procedure. *International Orthopaedics*. 23, 113, 1999)



**Figure 3:** The grafted coracoacromial ligament was additionally augmented by remnant of the torn acromioclavicular ligament attached to the acromion (strapped arrow)

**Table 1: Distribution of patients in each modified surgical techniques**

Procedure Group	Repair of torn AC ligament and augmentation of CA ligament (option A)	Augmentation of CA ligament with Torn AC ligament (option B)
1	31	9
2	15	5

The rehabilitation programs were same in Group 1 and 2. After the operation, patients were immobilized with a sling or brace for 6 weeks, because gravity influenced continuous stress to the AC and CA ligaments. If pain was tolerated, passive range of motion (ROM) exercise of the shoulder was begun the day after the surgery. Active ROM exercise with an unsupported arm was permitted at 6–8 weeks. At 12 weeks, strengthening exercise of the scapular stabilizers was begun. Return to work was allowed at 16–20 weeks only after full ROM and strength are gained.

Stability of the AC joint was evaluated clinically and radiographically. The clinical results were assessed by the Imatani evaluation system.<sup>12</sup> Vertical stability of the AC joint was evaluated by a radiograph with the stress maneuver. Horizontal stability of the AC joint was checked clinically and radiographically.<sup>13</sup> Plain radiographs were used in evaluating the status of injuries and reconstructions to the AC joint. For statistical analyses, the Wilcoxon signed rank test, and Wilcoxon rank sum test were performed with SAS version 9.2 (SAS Institute Inc, Cary, NC, USA). Results were considered statistically significant if the  $P < 0.05$ .

## Results

The mean duration of followup was 2 years and 2 months (range 1–2 years and 8 months). The results were excellent

in all patients, except one patient in Group 2 who had redislocation of the AC joint, and was graded as fair. The patient with recurrent dislocation of the AC joint was a 61-year-old man with Type V injury. After surgery, roentgenographic measurement revealed that he had a CC interval of 7.3 mm on the affected side and 10.3 mm on the unaffected side. However, the patient did not follow the rehabilitation protocol, and he chose to move his shoulder at 2 weeks after surgery, against our recommendations. On followup X-ray, the CC interval was 14.0 mm on the affected side, and 9.8 mm on the unaffected side.

At final followup, the mean CC interval was 8.2 mm on the affected side and 8.9 mm on the unaffected side in Group 1 ( $P = 0.1297$ ) [Figure 5], and 9.5 mm on the affected side and 10.1 mm on the unaffected side in Group 2 [Figure 6], when excluding the one patient with re-dislocation of the AC joint in Group 2 ( $P = 0.2895$ ) [Table 2]. These data indicated that vertical stability of the AC joint was well maintained in both groups.

For Group 1, there was a significant difference between options A and B ( $P = 0.0351$ ), which suggested that only augmented the CA ligament (option B) could contribute to better vertical stability of the AC joint than repair of the torn AC ligament and augmentation of the grafted CA ligament (option A) [Table 3]. The CC interval did not differ significantly between Type III and Type V injuries ( $P = 0.4568$ ). These results suggest that this procedure successfully stabilized the AC joint regardless of the type of injury or the operative method (i.e., Groups 1 or 2; options A or B). At final followup, detection of any changes of grafted chip bone in clavicle on simple X-ray was difficult. However, at final followup X-ray, there was no enlargement of the medullary canal of the distal clavicle at the site of the grafted ligament.

There were no complications in any other patients.

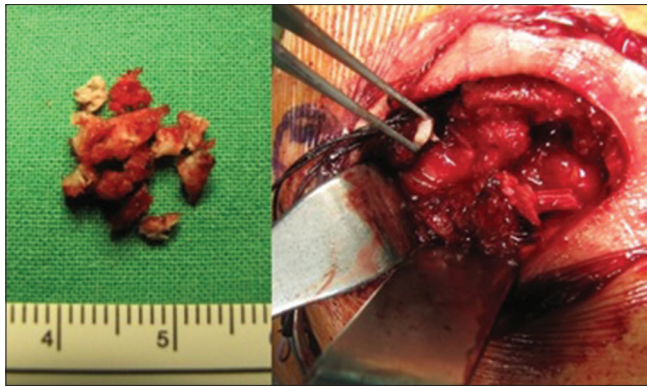


Figure 4: Autogenous chip bone graft was obtained from the resected distal clavicle and placed between the grafted coracoacromial ligament and the medullary canal of the resected distal end of the clavicle

Table 2: CC interval in unaffected side and affected side after the surgery (mm)

Procedure Group	Unaffected side Mean±SD	Affected side Mean±SD	P
1	8.93±2.53	8.19±1.84	0.1297
2	10.10±2.62	9.50±2.03	0.2895

Table 3: Differences in CC interval between unaffected side and affected side after the surgery (mm)

Procedure Group	Option A Mean±SD	Option B Mean±SD	P
1	1.21±1.87	-0.21±1.76	0.0351
2	-0.06±1.85	1.16±2.38	0.8436
1 + 2	0.55±1.84	0.41±2.08	0.2293

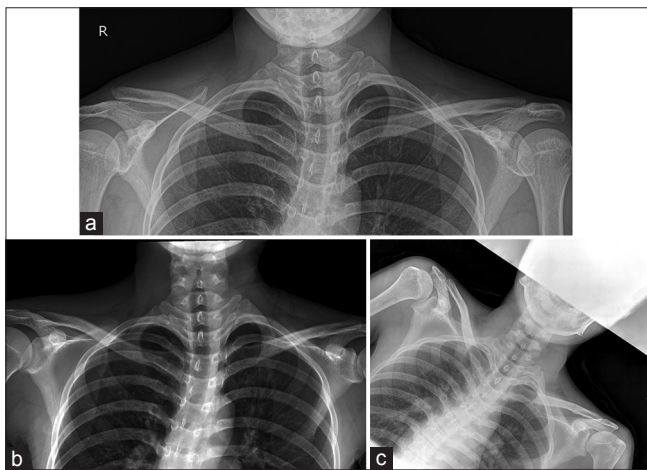


Figure 5: (a) Anteroposterior standing radiograph with the stress maneuver of 21-year-old male patient shows the right AC joint separation with Type V before the operation, (b) which is reduced by combined option B-1 and B-2 procedure, (c) and maintained well at final followup

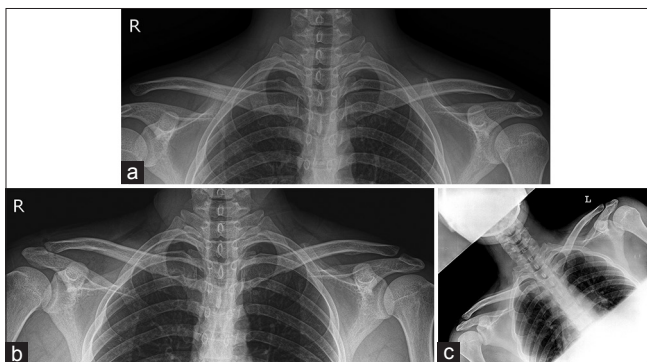


Figure 6: (a) Anteroposterior standing radiograph with the stress maneuver of 19-year-old male patient shows the right AC joint separation with Type V before the operation, (b) which is reduced by option A procedure, (c) and maintained well with calcification under the lateral resected clavicle at final followup

## Discussion

Injuries to the AC joint represent approximately 9%–15% of all shoulder,<sup>2,3</sup> and 40%–50% of athletic shoulder injuries.<sup>1,3</sup> These injuries begin with the AC ligaments, and

progress to the CC ligaments, deltoid muscle, trapezius muscle, and finally, the fascia.<sup>4</sup>

Although most recent studies recommend conservative treatment of Type III injuries, surgery should be considered after evaluation of the patient's age, activity, hand dominance, sports requirements, the occupations of heavy laborer and athlete. Many operative methods with different modifications and combinations have been used to treat AC joint injuries.

It has been known that graft-bone healing has not been able to replicate the normal soft tissue-to-bone entheses,<sup>14</sup> and healing of reconstructed ligament might elongate more than a normal ligament with each increase in load.<sup>15</sup> Hence, strong healing of the grafted ligament-bone is important for the successful result after the surgery. Biomechanical studies demonstrated that the initial strength of the CA ligament after the transfer was only 25% of normal, and stability in the anteroposterior plane was not restored.<sup>16,17</sup>

In the current study, we tried to facilitate the reconstructed graft-bone healing by autogenous chip bone graft, placed between the grafted CA ligament and the medullary canal of the resected distal end of the clavicle (Group 2).

The biomechanical study showed Mersilene tape reconstruction provided superior initial fixation strength compared with CA ligament transfer.<sup>17</sup> Extra-articular circle of the Mersilene tape, a tough and strong loop to maintain reduction of the dropped scapula during healing of grafted CA ligament in the distal clavicle, played additional roles in the vertical stability of the AC joint. To avoid the complications related to the Mersilene tape, it was important to maintain balanced tension between the grafted CA ligament and the Mersilene tape during tying.

At final followup, the mean CC interval was 8.2 mm on the affected side and 8.9 mm on the unaffected side in Group 1 ( $P = 0.1297$ ), and 9.5 mm on the affected side and 10.1 mm on the unaffected side in Group 2 ( $P = 0.2895$ ). So at final followup, the CC interval on the affected side

in both Group 1 and 2 showed shorter than those on the unaffected side in both groups after the operation, but this difference between both groups was not statistically significant ( $P = 0.9737$ ). These data indicated that the vertical stability of the AC joint was well maintained in both Groups 1 and 2. In Group 1, option B provided better vertical stability than option A for patients ( $P = 0.0351$ ).

At final followup, it was very difficult to detect any changes in chip bone graft in clavicle on simple X-ray. Even though slightly denser images in distal clavicle were observed, it was hard to say that this kind of minute changes were results of healing of chip bone graft or delicate changes of position of the clavicle during checking X-ray. Hence, the integrity of grafted ligament and union of chip bones were evaluated by X-ray and physical examination as indirect manners. Moreover at final followup X-ray, there was no enlargement of the medullary canal of the distal clavicle at the site of the grafted ligament. Coupled with AC ligament repair, augmentation of the CA ligament might add horizontal stability of the AC joint.

Clinical and radiological results of this study showed superior to other studies using the Weaver-Dunn procedure, demonstrating up to a 30% failure rate,<sup>18,19</sup> and anatomic reconstruction technique with TightRope system, demonstrating 34.8% radiographic failure rate<sup>20</sup> and 43% radiographic anteroposterior instability.<sup>21</sup>

The amount of clavicle to be resected in this study was 3–5 mm range that has been shown to be adequate to prevent bone to bone contact with the rotation of the scapula<sup>22,23</sup> or abutment between the posterior clavicle and the anterior scapular spine. In the current study, there were no complications, such as early or late fracture, osteolysis of the coracoid process or clavicle, enlargement of medullary canal of the distal clavicle, residual scapular dyskinesia and impingement syndrome of the shoulder, injury to the brachial plexus or axillary artery, infection, or aseptic foreign body reaction.

The major limitation of this study was the unequal sample size between groups, which might weaken the statistical support for the positive effect of chip bone graft.

## Conclusions

Even though we could not find any superiority of the effect of chip bone graft, theoretically the use of chip bone graft (Group 2) might be expected to facilitate firm healing of the grafted CA ligament into the clavicle. This modified Weaver-Dunn procedure with or without autogenous chip bone graft appeared to be effective both biomechanically and clinically, and it provided a stable and strong reconstruction of the AC joint with both horizontal and vertical stability for the treatment of AC joint separation, regardless of the type of injury. At last followup, the CC interval of both groups were maintained well compared to those of both groups just after the operation, and there was

no significant differences statistically between Group 1 and 2 ( $P = 0.9737$ ). This procedure is recommended for patients with Type IV, V, VI injuries and some Type III injury, who are active patients, such as heavy laborers or athletes who participate in overhead throwing sports.

## Declaration of patient consent

The authors certify that they have obtained all appropriate patient consent forms. In the form, the patient(s) has/have given his consent for his images and other clinical information to be reported in the journal. The patients understand that their names and initials will not be published and due efforts will be made to conceal their identity, but anonymity cannot be guaranteed.

## Financial support and sponsorship

There are neither financial support nor sponsorship.

## Conflicts of interest

There are no conflicts of interest.

## References

- Kaplan LD, Flanigan DC, Norwig J, Jost P, Bradley J. Prevalence and variance of shoulder injuries in elite collegiate football players. *Am J Sports Med* 2005;33:1142-6.
- Mazzocca AD, Arciero RA, Bicos J. Evaluation and treatment of acromioclavicular joint injuries. *Am J Sports Med* 2007;35:316-29.
- Thorndike A Jr., Quigley TB. Injuries to the acromioclavicular joint: A plea for conservative treatment. *Am J Surg* 1942;55:250-61.
- Williams GR Jr., Nguyen VD, Rockwood CA Jr. Classification and radiographic analysis of acromioclavicular dislocations. *Appl Radiol* 1989;18:29-34.
- Fukuda K, Craig EV, An KN, Cofield RH, Chao EY. Biomechanical study of the ligamentous system of the acromioclavicular joint. *J Bone Joint Surg Am* 1986;68:434-40.
- Klimkiewicz JJ, Williams GR, Sher JS, Karduna A, Des Jardins J, Iannotti JP, *et al.* The acromioclavicular capsule as a restraint to posterior translation of the clavicle: A biomechanical analysis. *J Shoulder Elbow Surg* 1999;8:119-24.
- Lizaur A, Marco L, Cebrian R. Acute dislocation of the acromioclavicular joint. Traumatic anatomy and the importance of deltoid and trapezius. *J Bone Joint Surg Br* 1994;76:602-6.
- Salter EG Jr., Nasca RJ, Shelley BS. Anatomical observations on the acromioclavicular joint and supporting ligaments. *Am J Sports Med* 1987;15:199-206.
- Urist MR. Complete dislocations of the acromioclavicular joint; the nature of the traumatic lesion and effective methods of treatment with an analysis of forty-one cases. *J Bone Joint Surg Am* 1946;28:813-37.
- Kibler WB, Sciascia A. Current concepts: Scapular dyskinesia. *Br J Sports Med* 2010;44:300-5.
- Park TS, Kim YH. Modification of the weaver-dunn procedure. *Int Orthop* 1999;23:113.
- Imatani RJ, Hanlon JJ, Cady GW. Acute, complete acromioclavicular separation. *J Bone Joint Surg Am* 1975;57:328-32.
- Tauber M, Koller H, Hitzl W, Resch H. Dynamic radiologic evaluation of horizontal instability in acute acromioclavicular

- joint dislocations. *Am J Sports Med* 2010;38:1188-95.
14. Tei MM, Farraro KF, Woo SL. Ligament and tendon enthesis: anatomy and mechanics. In: Thomopoulos S, Birman V, Genin GM, editors. *Structural Interfaces and Attachments in Biology*. New York: Springer Science and Business Media; 2013. p. 69-89.
  15. Thornton GM, Shrive NG, Frank CB. Healing ligaments have decreased cyclic modulus compared to normal ligaments and immobilization further compromises healing ligament response to cyclic loading. *J Orthop Res* 2003;21:716-22.
  16. Harris RI, Wallace AL, Harper GD, Goldberg JA, Sonnabend DH, Walsh WR, *et al.* Structural properties of the intact and the reconstructed coracoclavicular ligament complex. *Am J Sports Med* 2000;28:103-8.
  17. Lee SJ, Nicholas SJ, Akizuki KH, McHugh MP, Kremenich IJ, Ben-Avi S, *et al.* Reconstruction of the coracoclavicular ligaments with tendon grafts: A comparative biomechanical study. *Am J Sports Med* 2003;31:648-55.
  18. Mazzocca AD, Santangelo SA, Johnson ST, Rios CG, Dumonski ML, Arciero RA, *et al.* A biomechanical evaluation of an anatomical coracoclavicular ligament reconstruction. *Am J Sports Med* 2006;34:236-46.
  19. Weinstein DM, McCann PD, McIlveen SJ, Flatow EL, Bigliani LU. Surgical treatment of complete acromioclavicular dislocations. *Am J Sports Med* 1995;23:324-31.
  20. Venjakob AJ, Salzmann GM, Gabel F, Buchmann S, Walz L, Spang JT, *et al.* Arthroscopically assisted 2-bundle anatomic reduction of acute acromioclavicular joint separations: 58-month findings. *Am J Sports Med* 2013;41:615-21.
  21. Scheibel M, Dröschel S, Gerhardt C, Kraus N. Arthroscopically assisted stabilization of acute high-grade acromioclavicular joint separations. *Am J Sports Med* 2011;39:1507-16.
  22. Corteen DP, Teitge RA. Stabilization of the clavicle after distal resection: A biomechanical study. *Am J Sports Med* 2005;33:61-7.
  23. Edwards SL, Wilson NA, Flores SE, Koh JL, Zhang LQ. Arthroscopic distal clavicle resection: A biomechanical analysis of resection length and joint compliance in a cadaveric model. *Arthroscopy* 2007;23:1278-84.

© 2019. This work is published under

<https://creativecommons.org/licenses/by-nc-sa/4.0/> (the “License”).

Notwithstanding the ProQuest Terms and Conditions, you may use this content  
in accordance with the terms of the License.