

Arthroscopic resection of the distal clavicle in osteoarthritis of the acromioclavicular joint

Tae-Soo Park, Kwang-Won Lee¹

ABSTRACT

Background: Symptomatic acromioclavicular joint (ACJ) lesions are a common cause of shoulder complaints that can be treated successfully with both conservative and surgical methods. There are several operative techniques, including both open and arthroscopic surgery, for excising the distal end of the clavicle. Here, we present a new modified arthroscopic technique for painful osteoarthritis of the ACJ and evaluate its clinical outcomes. Our hypothesis was that 4- to 7-mm resection of the distal clavicle in an *en bloc* fashion would have several advantages, including no bony remnants, maintenance of stability of the ACJ, and reduced prevalence of heterotopic ossification, in addition to elimination of the pathologic portion of the distal clavicle.

Materials and Methods: 20 shoulders of 20 consecutive patients with painful and isolated osteoarthritis of the ACJ who were treated by arthroscopic *en bloc* resection of the distal clavicle were included in the study. There were 10 males and 10 females with an average age of 56 years (range 42–70 years). The mean duration of followup was 6 years and 2 months (range 4–8 years 10 months). The results were evaluated using the University of California Los Angeles (UCLA) shoulder rating score.

Results: The overall UCLA score was 13.7 preoperatively, which improved to 33.4 postoperatively. All subscores were improved significantly ($P < 0.001$). There were no specific complications at the latest followup.

Conclusion: It is critical in this procedure to resect the distal clavicle evenly from superior to inferior in an *en bloc* fashion without any small bony remnants and to preserve the capsule and acromioclavicular ligament superoposteriorly. This arthroscopic procedure is a reliable and reproducible technique for painful osteoarthritis of the ACJ lesions in active patients engaged in overhead throwing sports and heavy labor.

Key words: Acromioclavicular joint, arthroscopic surgery, distal clavicle, *en bloc* resection, osteoarthritis

MeSH terms: Sports medicine, osteoarthritis, arthroscopes, clavicle, acromioclavicular joint

INTRODUCTION

Symptomatic acromioclavicular joint (ACJ) lesions are a common cause of shoulder complaints that can be treated successfully with both conservative and surgical methods.¹⁻⁶ Persistence of symptoms even after repair of the rotator cuff⁷⁻¹³ warrants excision of the ACJ. There are several operative techniques, including both

open and arthroscopic surgery, for excising the distal end of the clavicle. Arthroscopic excision of the distal clavicle has been popular but remains a technically demanding procedure. The purpose of this study was to present a new arthroscopic technique for painful osteoarthritis of the ACJ, either degenerative or posttraumatic, and to evaluate its clinical outcomes. Our hypothesis was that 4- to 7-mm resection of the distal clavicle in an *en bloc* fashion would have several advantages, including no bony remnants, maintenance of stability of the ACJ, and reduced prevalence of heterotopic ossification, in addition to elimination of the pathologic portion of the distal clavicle.

Department of Orthopaedic Surgery, Hanyang University College of Medicine, Guri Hospital, Guri, Gyunggi-do, ¹Department of Orthopaedic Surgery, Eulji University Hospital, Daejeon, Korea

Address for correspondence: Prof. Kwang-Won Lee, Department of Orthopaedic Surgery, Eulji University Hospital, 1306 Dunsan-dong, Seo-gu, Daejeon 302-799, Korea. E-mail: kwangwon@eulji.ac.kr

Access this article online	
Quick Response Code: 	Website: www.ijonline.com
	DOI: 10.4103/0019-5413.185601

This is an open access article distributed under the terms of the Creative Commons Attribution-NonCommercial-ShareAlike 3.0 License, which allows others to remix, tweak, and build upon the work non-commercially, as long as the author is credited and the new creations are licensed under the identical terms.

For reprints contact: reprints@medknow.com

How to cite this article: Park TS, Lee KW. Arthroscopic resection of the distal clavicle in osteoarthritis of the acromioclavicular joint. Indian J Orthop 2016;50:379-83.

MATERIALS AND METHODS

Twenty shoulders of 20 consecutive patients with isolated osteoarthritis of the ACJ, either degenerative or posttraumatic, who underwent arthroscopic *en bloc* resection of the distal clavicle were evaluated retrospectively. The patients with other associated pathology of the shoulder, including rotator cuff tears, were excluded. The study included 10 males and 10 females with an average age of 56 years (range 42–70 years). There were 19 cases of degenerative osteoarthritis and 1 of posttraumatic osteoarthritis of the ACJ. All patients had pain with passive horizontal adduction of the arm around the anterosuperior portion of the ACJ and tenderness on the ACJ.

Radiographic findings showed cystic changes, osteophyte formation of the distal end of the clavicle, and irregular shape and destructive changes on the articular surface of the distal clavicle in degenerative and posttraumatic osteoarthritis of the distal clavicle. All patients underwent bone scintigraphy 4 h after injection of 20–30 mg of technetium-99 (Tc-99m) hydroxymethylene diphosphate. Imaging was performed using a single-headed instrument (General Electric Infinia H 3000WT GP3, Milwaukee, WI, USA) fitted with a high-resolution parallel hole collimator and interfaced to a computer. All images were reported by one experienced nuclear medicine physician. All bone scintigraphy images showed increased uptake and hyperemia in the ACJ [Figure 1]. Injection tests in the ACJ showed positive findings in all patients. In some cases, magnetic resonance arthrographic findings showed large fluid collection around the ACJ and arthritic findings, as well as integrity of the rotator cuff. The indications for surgery of ACJ were osteoarthritis of the ACJ, either degenerative or posttraumatic, osteolysis of the distal clavicle and malunited distal end fracture of the clavicle, for which conservative treatment for 4–6 months had failed to return the patient to the desired level of activities of daily living.

The clinical results were evaluated using the University of California Los Angeles (UCLA) shoulder rating score. The average duration of followup was 6 years and

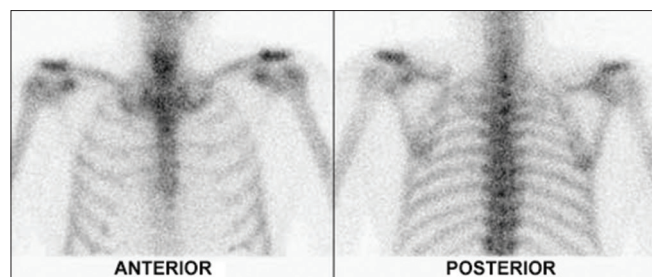


Figure 1: Bone scintigraphy showing focal increased uptake in both acromioclavicular joints

2 months (range 4–8 years 10 months). The Wilcoxon signed ranks test was used for statistical analysis. Results were considered significant if the $P < 0.05$.

This study received approval from the institutional review board at the first author's institution.

Operative procedure

Under general or a regional interscalene block anesthesia, the patient was placed in the beach chair position or in the lateral decubitus position. From a bursal approach, the posterior portal in the soft spot just medial and inferior to the posterolateral corner of the acromion, and the lateral portal in line with the posterior clavicle 2–3 cm below the tip of the acromion, were alternatively used as viewing portals, and the anterosuperior portal just medial and 1.0–1.5 cm directly anterior to the ACJ was used as a working portal. The ACJ was inspected with a standard 4.0 mm arthroscopy and almost all inflammatory and impinging soft tissues were removed using a tissue ablation device (Arthrocare®, Arthrocare Corporation, California, USA) and a 3.5–4.0 mm full radius resector. The distal end of the clavicle was then exposed antero-infero-superiorly. After exposing the ACJ, the superoposterior capsule and ligaments of the ACJ were elevated subperiosteally and preserved, but the meniscus, if present, and the anteroinferior capsule were resected. Amount of the bone to be resected, was marked on the inferior surface of the distal clavicle using a 5-mm elliptical bur [Figure 2]. This procedure was necessary when the thickness of the distal clavicle was >10 mm because the size of the saw blade was limited to 5–6 mm in width. *En bloc* resection of distal clavicle was performed using a reciprocating oscillating saw blade and an osteotome [Figure 3]. At this time, the distal clavicle was resected. Any bony remnants that were present, especially if attached to the superoposterior corner of the ACJ, were thoroughly removed [Figure 4]. We then checked the maintenance of the integrity of posterosuperior capsular and ligamentous structures of the ACJ [Figure 5]. The

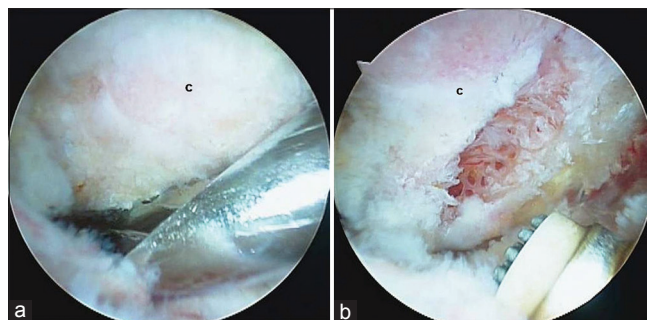


Figure 2: Arthroscopic views showing determination of the amount of the bone to be resected (a) This is marked on the inferior surface of the distal clavicle using a 5-mm elliptical bur (b). Resection of distal clavicle

length of resection of the distal clavicle ranged from 4 to 7 mm. A roentgenogram showed the spur in the distal clavicle before the operation [Figure 6 left: Black arrow], which was removed completely after the operation [Figure 6 right: White arrow].

Patient controlled analgesia and a Cryo/cuff® (Aircast Inc, Summit, NJ, USA) were applied for 3–4 days after surgery for control of pain. The patient began to perform gentle active and active assisted range of motion (ROM) exercises on the day after surgery. The level of physical therapy progressed to full active ROM exercise, isometric exercise, and strengthening exercise within the patient’s tolerance level by 1–3 months after surgery.

RESULTS

The overall UCLA shoulder rating score for pain improved from 2.0 (range 1–4) preoperatively to 9.4 (range 8–10) postoperatively. Typically, the pain improved within a short time after the operation. The function score improved from 4.3 (range 2–6) preoperatively to 9.4 (range 8–10) postoperatively, active forward flexion improved from

3.6 (range 3–4) to 4.9 (range 4–5), and strength improved from 3.8 (range 2–5) to 4.8 (range 4–5). All patients were satisfied with the results of the operation. All subscores were improved significantly ($P < 0.001$). The overall UCLA score improved from 13.7 preoperatively to 33.4 postoperatively. The overall results were excellent in 13 patients (65%) and good in 7 (35%). No patients had poor results. There was no limitation of motion of the shoulder, no heterotopic ossification or calcification, no bony remnants of the distal clavicle, and no superior and horizontal instability of the clavicle at the latest followup.

DISCUSSION

One of the most common causes of shoulder complaints is ACJ lesions with or without pain that are associated with impingement and rotator cuff tendinopathy.¹⁻⁶ The frequency of ACJ abnormalities in impingement syndrome of the

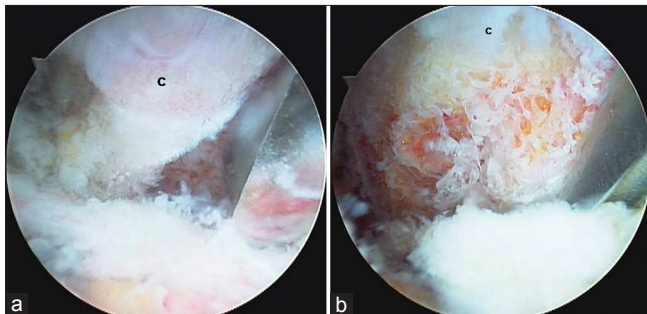


Figure 3: Arthroscopic views showing (a) Resection of the distal clavicle is performed using a reciprocating saw blade and osteotome. (b) Resected bone of the distal clavicle is removed in an *en bloc* fashion. [C=Distal clavicle]

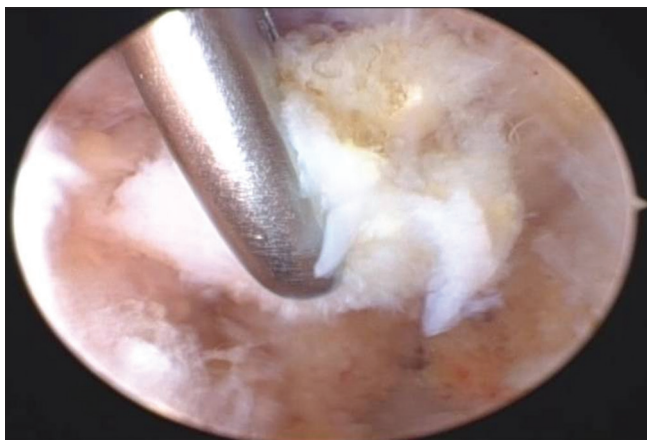


Figure 4: Arthroscopic view showing that any remnants of bone pieces that are present, especially those attached to the superoposterior corner of the acromioclavicular joint, are thoroughly removed

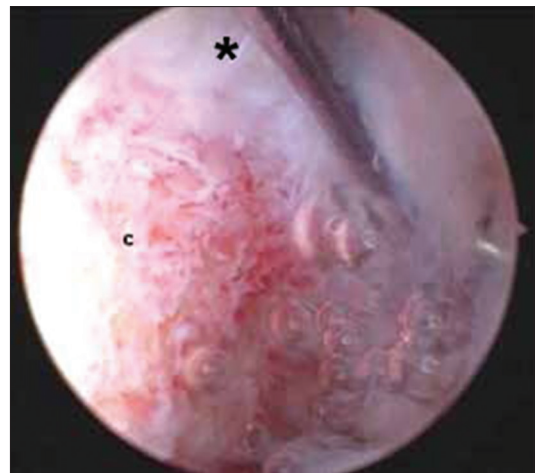


Figure 5: Arthroscopic view showing that the preservation of supporting posterosuperior capsular and ligamentous structures (*) of acromioclavicular joint is important. [C=Distal clavicle]

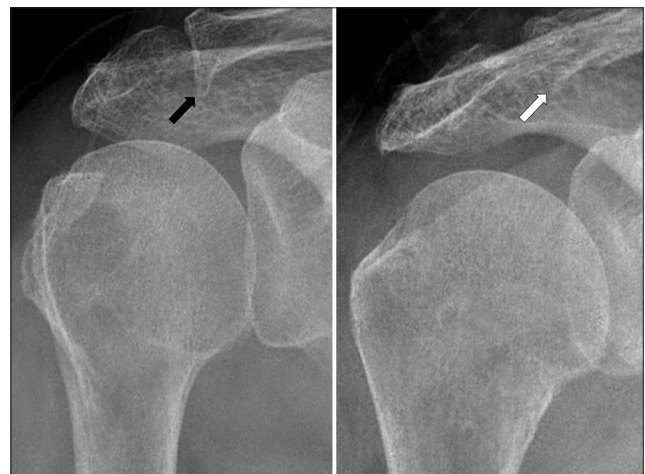


Figure 6: Roentgenogram shows the spur in the distal clavicle before the operation (left: Black arrow), which is completely removed after the operation (right: White arrow)

shoulder is variable.¹⁴⁻¹⁶ In advanced cases of ACJ lesions, destruction of the inferior joint capsule in degenerative arthropathy of the ACJ may be associated with a large to massive full-thickness rotator cuff tear. Rotator cuff repair is a common surgical procedure performed on the shoulder, but there are relatively few reports of ACJ resection. One of the most common causes of failure following rotator cuff repair is persistent painful ACJ lesions.¹⁷ Bone scintigraphy is an effective modality for early diagnosis of ACJ lesions, including osteoarthritis. Tc-99m-labeled phosphate esters are commonly used in bone scintigraphy. In this study, bone scintigraphy was used to confirm the early diagnosis of osteoarthritis and osteolysis of the distal clavicle with positive findings of tenderness, cross body adduction test, and injection test before radiographic changes. All cases showed increased uptake and hyperemia in the ACJ, which represented a single increase in bone turnover of the bone metabolism¹⁸ or increased blood flow. Although the role of scintigraphy in the diagnosis of osteoarthritis is not clear, scintigraphy has high sensitivity in detecting bony reaction to the pathology of osteoarthritis.¹⁹⁻²² Symptoms may be related to motion of the arthritic joint, either degenerative or posttraumatic, or outlet impingement between inferior projecting spurs and the underlying rotator cuff, causing narrowing of the subacromial space.

The pain originating from osteoarthritis of the ACJ can often be treated by conservative management; however, surgical methods are considered in cases where this fails. Excision of the distal clavicle is recognized as the treatment of choice. The surgical indications of arthroscopic *en bloc* resection of the distal clavicle include osteoarthritis of the ACJ (either degenerative or posttraumatic), osteolysis of the distal end of the clavicle, and malunion of the distal end fracture of the clavicle that fail to respond to conservative treatment for 4–6 months. In the literature, it is well known that arthroscopic treatment of the AC joint lesion is an acceptable alternative to open excision of the distal clavicle.²³⁻³¹ The arthroscopic procedure has several advantages, including precise and reproducible resection of bone, a shortened recovery time, preservation of the deltoid from the trapezius, diagnosis of the glenohumeral joint and subacromial space, minimal scar formation, and cosmetic merits. Arthroscopic *en bloc* resection of the distal clavicle is technically demanding. It is critical to perform even resection of the distal clavicle from superior to inferior and to remove all the small bony remnants attached to the capsule, both of which can be performed more easily and thoroughly with this approach as compared to previous arthroscopic procedures. Arthroscopic *en bloc* resection of the distal clavicle might reduce the chances of heterotopic ossification or calcification and obtain an even resection margin of the distal clavicle as compared to piecemeal resection performed in previous arthroscopic

procedures. It is also important to preserve the capsule and AC ligament superoposteriorly. However, even though these structures may be disrupted partially during operative procedures, clinical results, including horizontal instability of the clavicle, are not influenced because of healing of damaged structures. At the latest followup, specific complications, including bony remnants, heterotopic ossification or calcification, and superior and horizontal instability of the clavicle, were not observed in this study. As the length of clavicle to be resected varies, ranging from 4 mm to 15 mm,³²⁻³⁶ the optimal amount of resection is still controversial. In this study, it was 4–7 mm which has been shown to be adequate to prevent bone-to-bone contact with rotation of the scapula³⁷ and to preserve the insertion of the superior AC ligament. The sample size in this study was small because it was restricted to isolated ACJ lesions without rotator cuff injuries.

To conclude, arthroscopic *en bloc* resection of the distal clavicle resulted in no or mild pain and good to excellent results in all patients at the latest followup. The results of this procedure were reproducible and well documented hence this procedure is acceptable option for treating painful ACJ lesions.

Financial support and sponsorship

This work was supported by the research fund of Hanyang University (HY-2006-C).

Conflicts of interest

There are no conflicts of interest.

REFERENCES

1. Cook FF, Tibone JE. The Mumford procedure in athletes. An objective analysis of function. *Am J Sports Med* 1988;16:97-100.
2. Grimes DW, Garner RW. The degeneration of the acromioclavicular joint: Treatment by resection of distal clavicle. *Orthop Rev* 1980;9:41-4.
3. Gurd FB. The treatment of complete dislocation of the outer end of the clavicle: An hitherto undescribed operation. *Ann Surg* 1941;113:1094-8.
4. Mumford EB. Acromioclavicular dislocation: A new operative treatment. *J Bone Joint Surg Am* 1941;23:799-802.
5. Petersson CJ. Resection of the lateral end of the clavicle. A 3 to 30-year follow-up. *Acta Orthop Scand* 1983;54:904-7.
6. Worcester JN Jr, Green DP. Osteoarthritis of the acromioclavicular joint. *Clin Orthop Relat Res* 1968;58:69-73.
7. Bigliani LU, Cordasco FA, McLlveen SJ, Musso ES. Operative repair of massive rotator cuff tears: Long term results. *J Shoulder Elbow Surg* 1992;1:120-30.
8. Cofield RH. Tears of rotator cuff. In: *The American Academy of Orthopaedic Surgeons, editors. Instructional Course Lectures*. St. Louis: C.V. Mosby; 1981. p. 258-73.
9. DeOrto JK, Cofield RH. Results of a second attempt at surgical repair of a failed initial rotator-cuff repair. *J Bone Joint Surg Am* 1984;66:563-7.

10. Neer CS 2nd. Impingement lesions. *Clin Orthop Relat Res* 1983;173:70-7.
11. Neer CS 2nd, Flatow EL, Lech O. Tears of the rotator cuff: Long term results of anterior acromioplasty and repair. *Orthop Trans* 1988;12:735.
12. Petersson CJ, Gentz CF. Ruptures of the supraspinatus tendon. The significance of distally pointing acromioclavicular osteophytes. *Clin Orthop Relat Res* 1983;174:143-8.
13. Watson M. The refractory painful arc syndrome. *J Bone Joint Surg Br* 1978;60-B: 544-6.
14. Morrison DS. Arthroscopic distal clavicle excision. In: Craig EV, editor. *Master Techniques in Orthopaedic Surgery. The Shoulder*. New York: Raven Press, Ltd.; 1995. p. 417-27.
15. Taylor GM, Tooke M. Degeneration of the acromioclavicular joint as a cause of shoulder pain. *J Bone Joint Surg Br* 1977;59:507.
16. Watson M. The impingement syndrome in sportsmen. In: Bateman JE, Welsh RP, Decker BC, editors. *Surgery of the Shoulder*. New York: Churchill Livingstone; 1984. p. 140-2.
17. Bigliani LU, Cordasco FA, McIlveen SJ, Musso ES. Operative treatment of failed repairs of the rotator cuff. *J Bone Joint Surg Am* 1992;74:1505-15.
18. Park JY, Park SG, Keum JS, Oh JH, Park JS. The diagnosis and prognosis of impingement syndrome in the shoulder with using quantitative SPECT assessment: A prospective study of 73 patients and 24 volunteers. *Clin Orthop Surg* 2009;1:194-200.
19. Merrick MV. Investigation of joint disease. *Eur J Nucl Med* 1992;19:894-901.
20. Hutton CW, Higgs ER, Jackson PC, Watt I, Dieppe PA. 99mTc HMDP bone scanning in generalized nodal osteoarthritis. II. The four hour bone scan image predicts radiographic change. *Ann Rheum Dis* 1986;45:622-6.
21. Buckland-Wright C. Current status of imaging procedures in the diagnosis, prognosis and monitoring of osteoarthritis. *Baillieres Clin Rheumatol* 1997;11:727-48.
22. Mazzuca SA, Brandt KD, Schauwecker DS, Buckwalter KA, Katz BP, Meyer JM, *et al*. Bone scintigraphy is not a better predictor of progression of knee osteoarthritis than Kellgren and Lawrence grade. *J Rheumatol* 2004;31:329-32.
23. Bigliani LU, Nicholson GP, Flatow EL. Arthroscopic resection of the distal clavicle. *Orthop Clin North Am* 1993;24:133-41.
24. Ellman H. Arthroscopic subacromial decompression. A preliminary report. *Orthop Trans* 1985;9:49.
25. Flatow EL, Cordasco FA, Bigliani LU. Arthroscopic resection of the outer end of the clavicle from a superior approach: A critical, quantitative, radiographic assessment of bone removal. *Arthroscopy* 1992;8:55-64.
26. Flatow EL, Duralde XA, Nicholson GP, Pollock RG, Bigliani LU. Arthroscopic resection of the distal clavicle with a superior approach. *J Shoulder Elbow Surg* 1995;4 (1 Pt 1):41-50.
27. Gartsman GM. Arthroscopic resection of the acromioclavicular joint. *Am J Sports Med* 1993;21:71-7.
28. Gartsman GM, Combs AH, Davis PF, Tullos HS. Arthroscopic acromioclavicular joint resection. An anatomical study. *Am J Sports Med* 1991;19:2-5.
29. Madsen B. Osteolysis of the acromial end of the clavicle following trauma. *Br J Radiol* 1963;36:822-8.
30. Meyers FJ. Arthroscopic debridement of the acromioclavicular joint and distal clavicle resection. In: McGinty JB, Caspari RB, Jackson RW, Poehling GG, editors. *Operative Arthroscopy*. New York: Raven Press; 1991. p. 557-60.
31. Tolin BS, Snyder SJ. Our technique for the arthroscopic Mumford procedure. *Orthop Clin North Am* 1993;24:143-51.
32. Levine WN, Barron OA, Yamaguchi K, Pollock RG, Flatow EL, Bigliani LU. Arthroscopic distal clavicle resection from a bursal approach. *Arthroscopy* 1998;14:52-6.
33. Martin SD, Baumgarten TE, Andrews JR. Arthroscopic resection of the distal aspect of the clavicle with concomitant subacromial decompression. *J Bone Joint Surg Am* 2001;83-A:328-35.
34. Matthews LS, Parks BG, Pavlovich LJ Jr, Giudice MA. Arthroscopic versus open distal clavicle resection: A biomechanical analysis on a cadaveric model. *Arthroscopy* 1999;15:237-40.
35. Snyder SJ. Arthroscopic surgery of the acromioclavicular joint. In: Snyder SJ, editor. *Shoulder Arthroscopy*. New York: McGraw-Hill, Inc.; 1994. p. 87-113.
36. Zawadsky M, Marra G, Wiater JM, Levine WN, Pollock RG, Flatow EL, *et al*. Osteolysis of the distal clavicle: Long term results of arthroscopic resection. *Arthroscopy* 2000;16:600-5.
37. Urist MR. Complete dislocations of the acromioclavicular joint; the nature of the traumatic lesion and effective methods of treatment with an analysis of forty-one cases. *J Bone Joint Surg Am* 1946;28:813-37.

Reproduced with permission of the copyright owner. Further reproduction prohibited without permission.