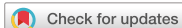



## Case Report



# A Case of Human Immunodeficiency Virus -triggered Hemophagocytic Lymphohistocytosis Presenting with Severe Bleeding Tendency

Bongyoung Kim , Yeon Woo Choi , Hyunjoo Pai , and Jieun Kim

Department of Internal Medicine, Hanyang University College of Medicine, Seoul, Korea

## OPEN ACCESS

Received: Oct 18, 2017

Accepted: Nov 27, 2017

### Corresponding Author:

Jieun Kim, MD, PhD

Department of Internal Medicine, Hanyang University College of Medicine 222-1, Wangsimni-ro, Seongdong-gu, Seoul 04763, Korea.

Tel: +82-31-560-2249

Fax: +82-31-553-7369

E-mail: quidam76@naver.com

Copyright © 2021 by Copyright © 2020 by The Korean Society of Infectious Diseases, Korean Society for Antimicrobial Therapy, and The Korean Society for AIDS

This is an Open Access article distributed under the terms of the Creative Commons Attribution Non-Commercial License (<https://creativecommons.org/licenses/by-nc/4.0/>) which permits unrestricted non-commercial use, distribution, and reproduction in any medium, provided the original work is properly cited.

### ORCID iDs

Bongyoung Kim

<https://orcid.org/0000-0002-5029-6597>

Yeon Woo Choi

<https://orcid.org/0000-0002-7417-9686>

Hyunjoo Pai

<https://orcid.org/0000-0003-4143-035X>

Jieun Kim

<https://orcid.org/0000-0002-6214-3889>

### Conflict of Interest

No conflicts of interest.

## ABSTRACT

Human immunodeficiency virus (HIV) is one of the less common triggers of secondary hemophagocytic lymphohistiocytosis (HLH) in which coagulation disorder is a frequent manifestation. Here, we present a case of HIV-triggered secondary HLH presenting with severe bleeding tendency and fever. Despite high-dose dexamethasone infusion (10 mg/body surface area/day), progressive disseminated intravascular coagulation and thrombocytopenia resulted in massive hematochezia: the bleeding episode ceased after endoscopic hemoclippping. After then, he took a highly-active antiretroviral therapy (HAART). Eventually, body temperature and overall laboratory findings normalized in response to HAART. Clinicians should not overlook HIV infection as a possible trigger of secondary HLH. In such cases, HAART is the core treatment.

**Keywords:** Human immunodeficiency virus; Acquired immune deficiency syndrome; Antiviral

## INTRODUCTION

Hemophagocytic lymphohistiocytosis (HLH) is a rare disease caused by an unusually strong immune response and unregulated activated macrophages and overproduction of inflammatory cytokines frequently result in life-threatening conditions [1]. It typically has a rapidly-progressing course and is often confused with sepsis because the two have similar clinical manifestations and laboratory findings [1]. Coagulation disorders due to disseminated intravascular coagulation (DIC) and thrombocytopenia are also common in HLH patients and are associated with adverse outcome [2].

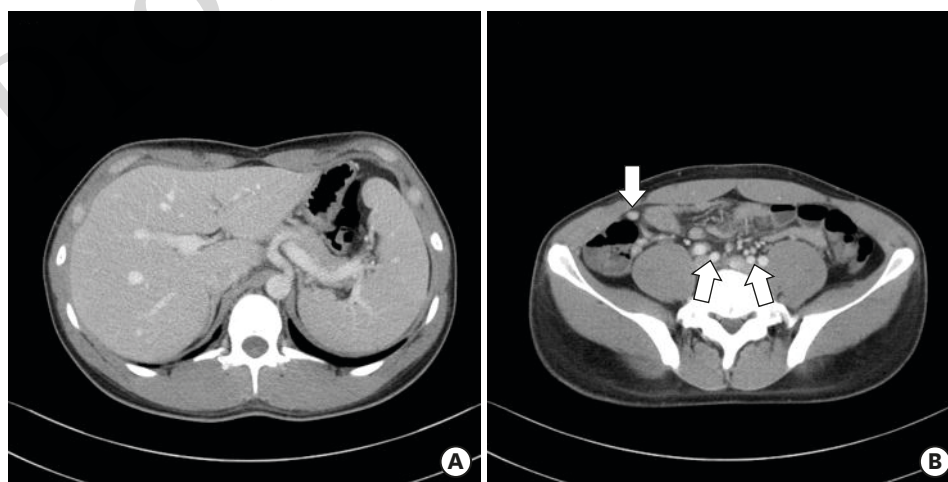Secondary HLH can be provoked by infections, malignancies, and autoimmune diseases [1]. A French study found that hematological malignancies (in particular non-Hodgkin lymphomas) were the main trigger of HLH, accounting for 56.8% of cases and infections were considered as trigger in 24.7% of cases [3]. In the same study, 6.1% of 162 HLH patients were provoked by virus [3]. In comparison, a Japanese study described Epstein-Barr virus (EBV) was the most common trigger, followed by other infections or lymphomas [4]. Indeed, various viral agents such as EBV, cytomegalovirus, parvovirus B19, *etc.* play a role in the origin of secondary HLH [3-5]. Human immunodeficiency virus (HIV) is also a less common trigger [5].

The overall mortality rate of HLH exceeds 50% [3]. In particular, HLH patients with hematological malignancies have a marked poorer outcome compared with those with infections or autoimmune diseases [5]. When triggers are adequately controlled, the better outcomes could be achieved [3]. Here, we present a case of HIV-triggered secondary HLH that presented with severe bleeding tendency and was successfully treated by highly-active antiretroviral therapy (HAART).

## CASE REPORT

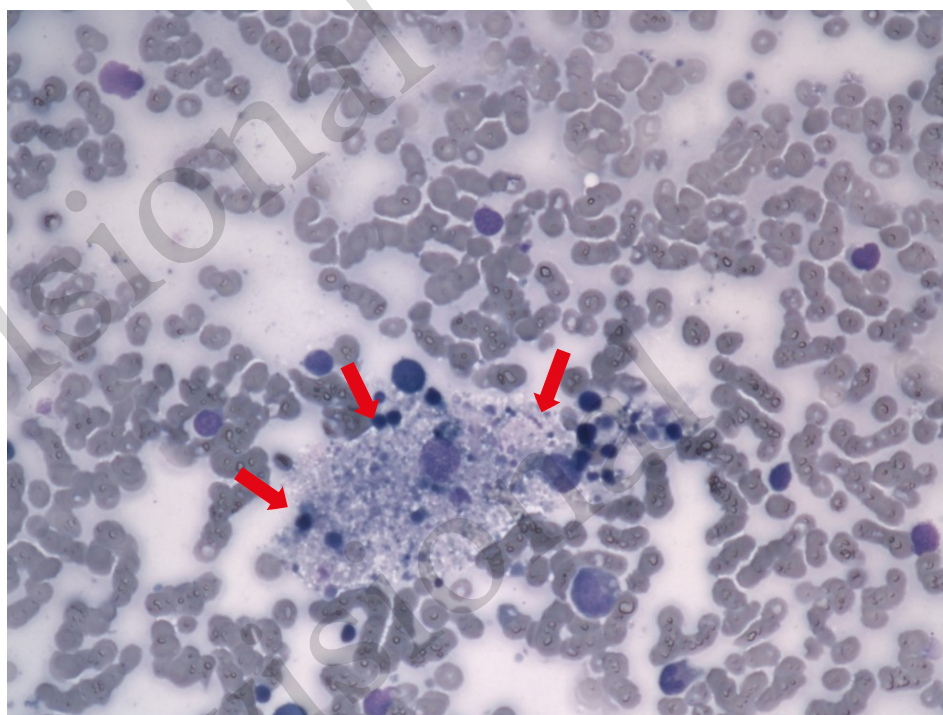
A 25-year-old man was referred to a university-affiliated hospital with one week-long fever, myalgia, and sore throat. He had no medical history except for childhood appendectomy. On admission his vital signs were: blood pressure 130/65 mmHg, body temperature 37.4°C, pulse 78 beats/min, respiratory rate 18 breaths/min, with awake and alert. On physical examination, multiple lymph node enlargement was observed. Initial complete blood count and blood chemistry were: leukocytes 5,600/mm<sup>3</sup> (segmented neutrophil 41%, lymphocyte 43.7%), hemoglobin 14.0 g/dL, platelets 159,000/mm<sup>3</sup>, blood urea nitrogen 14.4 mg/dL, creatinine 0.79 mg/dL, aspartate transaminase 748 U/L, alanine transaminase 609 U/L, alkaline phosphatase 52 U/L, total bilirubin 0.42 mg/dL, lactate dehydrogenase 1,654 U/L, creatine phosphokinase 112 U/L, c-reactive protein 1.75 mg/dL, ferritin 51,059 ng/mL, and triglyceride 136 mg/dL. On abdominal computed tomography examination, hepatosplenomegaly and enlargement of multiple intra-abdominal lymph nodes were observed (**Fig. 1**). In additional laboratory tests to differentiate other infectious diseases. the results were as follows: serum cytomegalovirus polymerase chain reaction (PCR) negative, EBV IgM negative, Hepatitis A virus (HAV) IgM negative, HBsAg negative, HBcAb IgM negative, Hepatitis C virus (HCV) antibody negative, *S. typhi* O <1:20, *S. typhi* H 1:20, blood culture negative, and HIV enzyme-linked immunosorbent assay positive. Based on these findings we suspected acute HIV syndrome, maintained conservative treatment and waited for the result of western blot tests.

On hospital day 4, ecchymoses developed on the dorsa of both feet where peripheral venous catheters were inserted and his body temperature was still above 38.5°C. In addition, thrombocytopenia, hyperferritinemia, and DIC were observed in follow-up laboratory tests: platelets 75,000 /mm<sup>3</sup>, ferritin 181,875 ng/mL, fibrinogen 106 mg/dL, d-dimer 34.28 mg/L,

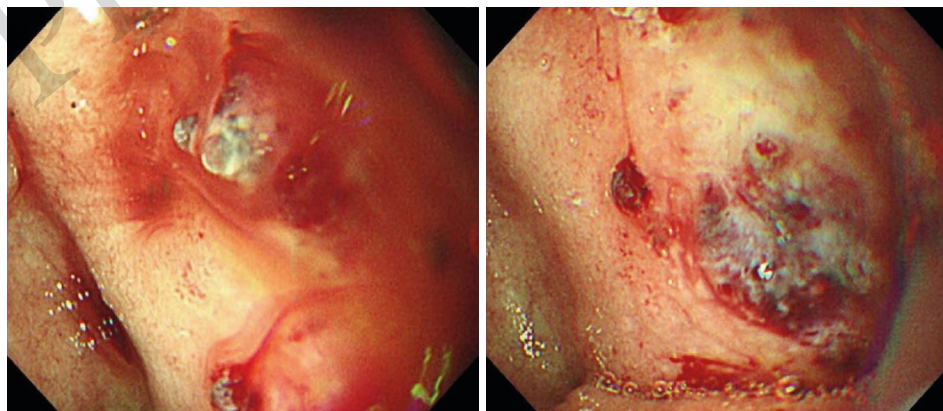


**Figure 1.** Abdominal computed tomography findings (on hospital day 1). (A) hepatosplenomegaly (B) enlargement of multiple intra-abdominal lymph nodes (white arrows)

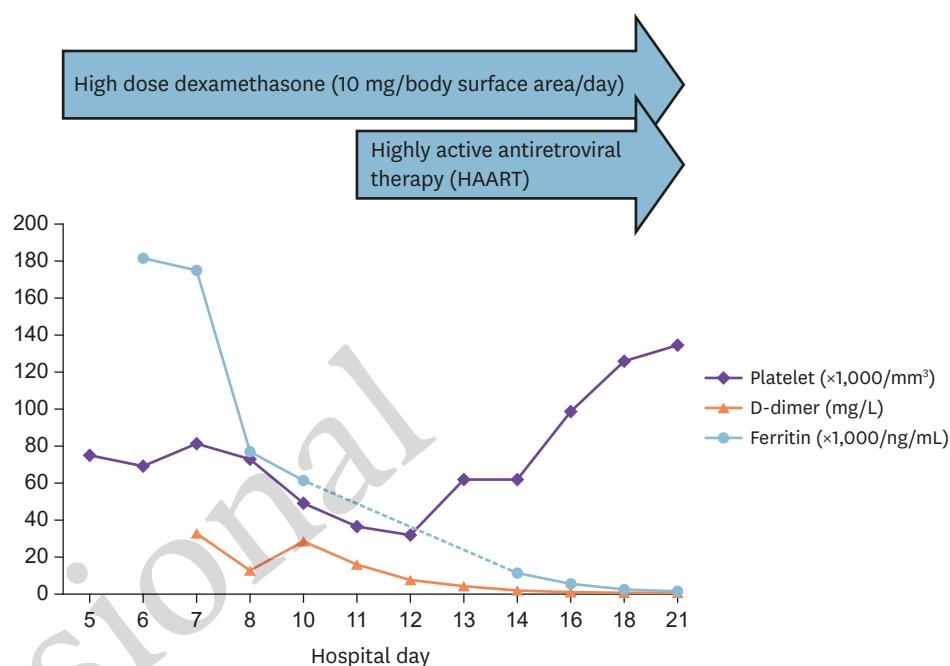
prothrombin time 1.52 (international normalized ratio), and fibrin degradation product 207.4  $\mu\text{g/mL}$ . To identify the cause of the hematologic abnormality we performed a bone marrow biopsy the following day. The findings were compatible with HLH: Wright-Giemsa staining revealed six percent histiocytes, which phagocytize erythrocytes, along with segmented neutrophils and platelets (Fig. 2). Intravenous high-dose dexamethasone (10mg/body surface area/day) infusion was started, but the patient complained of massive hematochezia, and hemoglobin declined from 10.6 g/dL to 6.8 g/dL on hospital day 6. Upper endoscopy was immediately performed and showed arterial bleeding with an ulcerative lesion on the duodenal bulb (Fig. 3). After endoscopic hemoclipping, the bleeding episode ceased, and the patient's general condition improved gradually, although high fever and thrombocytopenia persisted.



**Figure 2.** Histopathologic features of the bone marrow of the 25-year-old man with HLH associated with acute human immunodeficiency virus (HIV) syndrome (Wright-Giemsa stain, x400): microscopic examination revealed the presence of six percent histiocytes, which phagocytize erythrocytes (red arrows), along with segmented neutrophils and platelets.



**Figure 3.** Upper endoscopy findings (on hospital day 6): submucosal arterial bleeding with ulcerative lesions on the duodenal bulb.



**Figure 4.** The sequence of laboratory findings. High-dose dexamethasone (10 mg/body surface area/day) and highly active antiretroviral therapy (HAART) were initiated on hospital days 5 and 11, respectively.

The results of HIV tests were reported on hospital day 11: the western blot assay was positive and HIV ribonucleic acid PCR was 4,920,000 copies/mL, with 237 CD4+ T lymphocytes/ $\mu\text{L}$ . Elvitegravir/cobicistat/emtricitabine/tenofovir disoproxil fumarate was started. By the following day the patient's body temperature had normalized and overall laboratory findings had improved significantly (Fig. 4). On hospital day 21, he was switched from intravenous dexamethasone to oral prednisolone with a tapering plan, and was discharged without complications.

## DISCUSSION

The most common symptoms in HLH patients are fever and progressive hepatosplenomegaly [6]. Bleeding is also a common manifestation. Thrombocytopenia and coagulopathy from liver invasion are possible explanations for the bleeding episodes in HLH patients [2]. When lymphohistiocytes invade the gastrointestinal wall ulcerative lesions develop, leading to gastrointestinal bleeding. Transmural lymphohistiocytic infiltration of macrophages was observed in some case reports [7]. Unfortunately, we could not obtain duodenal tissue in this case because of the possibility that its removal would promote bleeding. According to a literature review, most gastrointestinal bleeding cases in HLH patients result in death (12 deaths in 18 cases) [8].

Most reported cases of HLH with HIV infection are triggered by concomitant opportunistic infections and malignancies, rather than HIV itself [9]. Table 1 shows cases of HIV-triggered HLH worldwide written in English [5, 10-18]. Fever was the most common clinical manifestation (100%, 11/11), followed by lymphadenopathy (72.7%, 8/11), splenomegaly (54.5%, 6/11) and hepatomegaly (36.4%, 4/11); no case presented with bleeding tendency except our case. The median CD4+ T lymphocyte was 98 cells/ $\mu\text{L}$  (range: 13-309) and most of cases (72.7%, 8/11) had lower than 200 cells/ $\mu\text{L}$  at the time of diagnosis. It means that HIV-triggered HLH has been rarely found in early-stage HIV infection.

**Table 1.** Clinical characteristics of reported Human immunodeficiency virus (HIV)-triggered hemophagocytic lymphohistiocytosis

Author/Country	Year	Age/Sex	Initial CD4+ T lymphocyte (cells/mm <sup>3</sup> )	Initial HIV viral load (copies/mL)	Clinical manifestations	Treatment	Outcome
Sasadeusz et al./Australia [10]	1990	30/male	63	N/A	Fever, lymphadenopathy, hepatosplenomegaly	Splenectomy	Survived
Rule et al./UK [11]	1991	30/male	N/A	N/A	Confusion	Corticosteroid	Died
Martínez-Escribano et al./Spain [12]	1996	31/male	300	N/A	Fever, lymphadenopathy, hepatosplenomegaly	Corticosteroid	Survived
Sproat et al./USA [13]	2003	32/male	100	>100,000	Fever, lymphadenopathy splenomegaly	Splenectomy, HAART	Survived
Chen et al./Taiwan [14]	2003	18/male	63	522,105	Fever, blurred vision, lymphadenopathy, splenomegaly	Intravenous immunoglobulin	Survived
Miyahara et al./Japan [15]	2007	17/male	309	190,000	Fever, lymphadenopathy, splenomegaly	Corticosteroid	Survived
Park et al./Korea [5]	2008	44/male	157	>1,000,000,000	Fever, lymphadenopathy, hepatomegaly	HAART	Survived
Adachi et al./Japan [16]	2013	48/male	98	3,000,000	Fever	HAART	Survived
Topiwala et al./USA [17]	2015	48/male	24	630,000	Fever, confusion	HAART	Survived
Ferrez et al./Portugal [18]	2016	27/female	13	384,687	Fever, lymphadenopathy	Corticosteroid, HAART	Survived
Our case/Korea	2017	25/male	237	4,920,000	Fever, lymphadenopathy, hepatosplenomegaly, hematochezia	Corticosteroid, HAART	Survived

We included cases written in English and excluded cases which have concomitant systemic infections other than HIV. HAART, highly-active antiretroviral therapy.

In the present case the patient's overall symptoms were improved by immunomodulation therapy (high-dose dexamethasone), but complete clinical recovery was only achieved by HAART. As mentioned previously, HLH is the result of an extraordinarily excessive immune response, and therefore the goal of treatment is to control life-threatening inflammation [1]. Corticosteroids, with or without cytotoxic drugs that suppress cytokine release, are commonly used to treat HLH [6]. Control of triggering, and removing stimuli that induce immune responses, are also important in treating secondary HLH [6]. There are several reports of dramatic clinical improvement in secondary HLH triggered by HIV infection after initiation of HAART [5, 16-18].

As the incidence of newly infected HIV patients is gradually increasing in Korea [19], clinicians may encounter more HLH cases among HIV patients in the near future. They should not overlook HIV infection as a possible trigger of secondary HLH. In such cases, proper HAART is the core treatment.

## REFERENCES

1. Mehta RS, Smith RE. Hemophagocytic lymphohistiocytosis (HLH): a review of literature. *Med Oncol* 2013;30:740. [PUBMED](#) | [CROSSREF](#)
2. Valade S, Azoulay E, Galicier L, Boutboul D, Zafrani L, Stepanian A, Canet E, Lemiale V, Venot M, Veyradier A, Mariotte E. Coagulation disorders and bleedings in critically ill patients with hemophagocytic lymphohistiocytosis. *Medicine (Baltimore)* 2015;94:e1692. [PUBMED](#) | [CROSSREF](#)
3. Rivière S, Galicier L, Coppo P, Marzac C, Aumont C, Lambotte O, Fardet L. Reactive hemophagocytic syndrome in adults: a retrospective analysis of 162 patients. *Am J Med* 2014;127:1118-25. [PUBMED](#) | [CROSSREF](#)
4. Ishii E, Ohga S, Imashuku S, Yasukawa M, Tsuda H, Miura I, Yamamoto K, Horiuchi H, Takada K, Ohshima K, Nakamura S, Kinukawa N, Oshimi K, Kawa K. Nationwide survey of hemophagocytic lymphohistiocytosis in Japan. *Int J Hematol* 2007;86:58-65. [PUBMED](#) | [CROSSREF](#)

5. Park KH, Yu HS, Jung SI, Shin DH, Shin JH. Acute human immunodeficiency virus syndrome presenting with hemophagocytic lymphohistiocytosis. *Yonsei Med J* 2008;49:325-8.  
[PUBMED](#) | [CROSSREF](#)
6. Henter JL, Tondini C, Pritchard J. Histiocyte disorders. *Crit Rev Oncol Hematol* 2004;50:157-74.  
[PUBMED](#) | [CROSSREF](#)
7. Klein S, Schmidt C, La Rosée P, Pletz M, Harz S, Dirsch O, Fritzenwanger M, Stallmach A. Fulminant gastrointestinal bleeding caused by EBV-triggered hemophagocytic lymphohistiocytosis: report of a case. *Z Gastroenterol* 2014;52:354-9.  
[PUBMED](#) | [CROSSREF](#)
8. Popeskou S, Gavillet M, Demartines N, Christoforidis D. Hemophagocytic lymphohistiocytosis and gastrointestinal bleeding: what a surgeon should know. *Case Rep Surg* 2015;2015:745848.  
[PUBMED](#) | [CROSSREF](#)
9. Bansal N, Aggarwal A, Wadhwa N. HIV infection in child presenting as hemophagocytic lymphohistiocytosis. *Ann Clin Case Rep* 2016;1:1069.
10. Sasadeusz J, Buchanan M, Speed B. Reactive haemophagocytic syndrome in human immunodeficiency virus infection. *J Infect* 1990;20:65-8.  
[PUBMED](#) | [CROSSREF](#)
11. Rule S, Reed C, Costello C. Fatal haemophagocytic syndromes in HIV-antibody positive patient. *Br J Haematol* 1991;79:127.  
[PUBMED](#) | [CROSSREF](#)
12. Martínez-Escribano JA, Pedro F, Sabater V, Quecedo E, Navarro V, Aliaga A. Acute exanthem and pancreatic panniculitis in a patient with primary HIV infection and hemophagocytic syndrome. *Br J Dermatol* 1996;135:804-7.  
[PUBMED](#) | [CROSSREF](#)
13. Sproat LO, Pantanowitz L, Lu CM, Dezube BJ. Human immunodeficiency virus-associated hemophagocytosis with iron-deficiency anemia and massive splenomegaly. *Clin Infect Dis* 2003;37:e170-3.  
[PUBMED](#) | [CROSSREF](#)
14. Chen TL, Won WW, Chiou TJ. Hemophagocytic syndrome: an unusual manifestation of acute human immunodeficiency virus infection. *Int J Hematol* 2003;78:450-2.  
[PUBMED](#) | [CROSSREF](#)
15. Miyahara H, Korematsu S, Nagakura T, Iwata A, Suenobu S, Izumi T. Hemophagocytic lymphohistiocytosis in a human immunodeficiency virus-positive homosexual high school student. *Pediatr Int* 2007;49:997-9.  
[PUBMED](#) | [CROSSREF](#)
16. Adachi E, Koibuchi T, Imai K, Kikuchi T, Shimizu S, Koga M, Nakamura H, Iwamoto A, Fujii T. Hemophagocytic syndrome in acute human immunodeficiency virus infection. *Intern Med* 2013;52:629-32.  
[PUBMED](#) | [CROSSREF](#)
17. Topiwala KK, Eaton EF, Franco RA. Dramatic response to HAART in HIV-induced hemophagocytic lymphohistiocytosis. *Int J Case Rep Images* 2015;6:65-9.  
[CROSSREF](#)
18. Ferraz RV, Carvalho AC, Araújo F, Koch C, Abreu C, Sarmiento A. Acute HIV infection presenting as hemophagocytic syndrome with an unusual serological and virological response to ART. *BMC Infect Dis* 2016;16:619.  
[PUBMED](#) | [CROSSREF](#)
19. Kim NJ. Trend in CD4+ cell counts at diagnosis in human immunodeficiency virus-infected persons in Korea. *Infect Chemother* 2017;49:155-7.  
[PUBMED](#) | [CROSSREF](#)